

Histopathological Alterations of Ceca in Broiler Chickens (*Gallus gallus*) Exposed to Chronic Heat Stress

by Hani Plumeriastuti

Submission date: 07-Jun-2023 01:42PM (UTC+0800)

Submission ID: 2110823093

File name: Histopathological_Alterations_of_Ceca_in_Broiler_Chickens.pdf (876.79K)

Word count: 4700

Character count: 25427



Histopathological Alterations of Ceca in Broiler Chickens (*Gallus gallus*) Exposed to Chronic Heat Stress

Antonius Vania Adji¹, Hani Plumeriastuti², Anwar Ma'ruf^{3*} and Djoko Legowo²

¹Faculty of Veterinary Medicine, Airlangga University, Surabaya 60115, Indonesia

²Department of Veterinary Pathology, Faculty of Veterinary Medicine, Airlangga University, Surabaya 60115, Indonesia

³Department of Basic Veterinary Medicine Science, Faculty of Veterinary Medicine, Airlangga University, Surabaya 60115, Indonesia

*Corresponding author's E-mail: anwarunair@gmail.com; ORCID: 0000-0001-7158-9156

ABSTRACT

Heat stress has been found to cause adverse effects on small intestinal microstructure, but little is known about its impact on chicken's cecum. In this research, the histopathological alterations of broiler chicken's cecum following chronic heat stress were evaluated. 20 broiler chickens were randomly divided into control group and treatment group containing 10 replicates, respectively. Both groups were reared under standard conditions until 21 days of age. From day 22 to day 42, the control group was kept at 24-28°C as well as relative humidity of 40-55%, while the treatment group was exposed to high temperature of 36-40°C and relative humidity of 45-65% for eight hours per day. At the end of the period, proximal part of each chicken's cecum was collected and made into histopathological slides with Hematoxylin and Eosin staining. Villus height, villus width, crypt depth, villus surface area, and villus height to crypt depth ratio were examined from 10 villi per replicate. Results analysis revealed that chronic heat stress profoundly ($P < 0.05$) reduced the crypt depth. Insignificant ($P > 0.05$) changes of the villus despite the long-term heat exposure might imply that the damage is at its early phase. In conclusion, chronic heat stress can produce morphological alterations in the ceca of broiler chickens, though requiring longer duration due to cecum's durability.

Key words: Broiler chicken, Cecum, Heat stress, Intestinal morphology

INTRODUCTION

Heat Stress (HS) is defined as biological response to high ambient temperature which disrupts the heat exchange equilibrium (Lara and Rostagno, 2013). Over the past decades, the Earth's surface temperature has gone beyond the former baseline, going as far as nominating 2016 as the warmest year since the recording was initiated in 1880. Consequently, the risk of HS' emergence in livestock projects to a higher level (Thornton et al., 2009). Broiler chickens are particularly more prone to contract heat stress because their cardiovascular and respiratory systems, which are vital for heat loss mechanisms, are unable to cope with their heavier body weight and high metabolism rate resulting from genetic selection (Sozcu, 2019).

HS has generally been found to be detrimental to small intestine's morphology in broiler chickens (Al-Fataftah and Abdelqader, 2014; Yi et al., 2016). The underlying mechanisms involve hypothalamic-pituitary-adrenal (HPA) axis activation, ischemia, oxidative stress, or perturbation of intestinal microbiota (Bolek, 2013; Song et al., 2014; Yi et al., 2016). The activated HPA axis subsequently elevates corticosterone level which in turn undermines immunity (Mishra and Jha, 2019). It has also been discovered that HS can suppress the number of goblet cells and the mRNA expression of tight junctions and adherence junctions in broiler chickens subjected to 33°C, 10 hours/day for 21 consecutive days (Zhang et al., 2017). These occurrences along with the impaired immune system facilitate the penetration of both toxins and pathogenic bacteria into the circulation afflicting various organs. Meanwhile, cecum is a part of chicken's intestine with the most abundant and diverse microorganisms colonizing its lumen (Ijaz et al., 2018). Furthermore, cecum regularly receives the backflow of urine rendering potentially more severe damage by the pathogens trespassing (Kum et al., 2015).

The available research on the influence of HS on cecal morphology produced conflicting results. Reduction in villus length and crypt size in the ceca of Japanese quails (*Coturnix coturnix japonica*) exposed to chronic HS was demonstrated by El-Daly et al. (2014). In contrast, negative results were obtained in Jaafar (2013)'s research. Other experiments, for the most part, are concerned with the microbiome in cecum, for instance HS was proven to be able to restrain the growth of normal flora colonies, like *Lactobacillus* sp., while enhancing the colonies of *Escherichia* sp., *Salmonella* sp., and aerobic bacteria in the cecum of broiler chickens (Park et al., 2013).

It was proposed that HS influenced the intestine variably in compliance with susceptibility level of each segment and the duration of HS occurrence (acute or chronic) (Loyau et al., 2015; Varasteh et al., 2015). This was borne out by analogous findings in Cherry-Valley ducks exhibiting no substantial crypt depth discrepancy in the cecum despite pronounced changes in the jejunum and ileum (He et al., 2013). Taking into account the lack of consistent and adequate number of results, the current research had an objective to evaluate the impact of chronic HS for 21 days on the microstructure of broiler chicken's cecum.

MATERIALS AND METHODS

Ethical approval

This experiment was performed on the basis of approval by the laboratory animals use research ethics committee of faculty of veterinary medicine, Airlangga University, Indonesia.

Experimental animals

In this research, 20 one day old Cobb broiler chicks were housed at the cage of laboratory animals, Faculty of Veterinary Medicine, Airlangga University, Surabaya, Indonesia. The chicks marketed as Wonchick originated from Wonokoyo Jaya Corporindo Ltd. (Limited Company, Surabaya, Indonesia). The rearing temperature followed the guidelines provided by the referred company, namely the leaflet containing Wonchick broiler chicken rearing guide. The chicks were allowed *ad libitum* access to feed and water. This went on up to 21 days.

Experimental design

The chickens were randomly allocated to two groups ($n=10$, respectively), the control (C) group and the treatment (T) group, from day 22 onwards. This starting point was chosen because broilers in the later age of life have greater sensitivity to high surrounding temperature than the younger birds (He et al., 2018). In that, true experimental design, specifically the post-test-only control group design, was applied. The C group was maintained on thermoneutral conditions (24-28°C and relative humidity (RH) 40-55%), while the T group was exposed to high ambient temperature and humidity (36-40°C and RH 45-65%) for eight hours/d then returned to 24-28°C and RH 40-55% for the rest of the day. On day 42, all the chickens were humanely slaughtered as affirmed by the research ethics committee and organ collection was carried out.

Cecal histopathology

The proximal part of cecum was dissected from 23.59% - 23.65% proximal of its length for all chickens. About one cm of the segment was fixed in neutral buffered formalin 10% and then routinely processed into slides with Hematoxylin and Eosin (H&E) stain. The sections were analyzed under light microscope with computer-assisted digital image analyzer (NIS Elements) for Villus Height (VH), Villus Width (VW), and Crypt Depth (CD) (Figure 1). Measurements of VH, VW, CD were based on the methods used by Abdelqader and Al-Fataftah (2016); Godwin et al. (2016) and Shokryazdan et al. (2017). The Villus Surface Area (VSA) was calculated from the formula $= \pi \times VW \times VH$. The Villus Height to Crypt Depth (VH:CD) ratio is a comparison of VH to CD (Santos et al., 2015). Collection of all the variables was done on 10 intact and the longest villi with their associated crypts in one cecal cross section per chicken. These values were averaged to obtain mean value of each variable for each chicken.

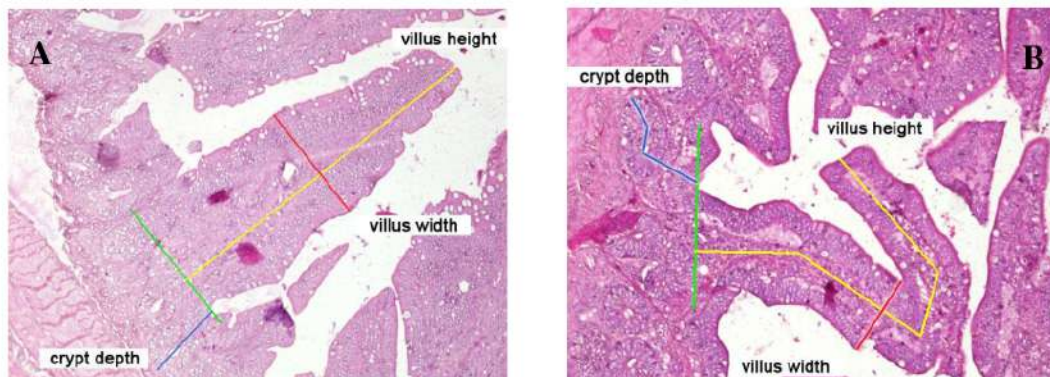


Figure 1. Methodology for morphometric assessment of villus-crypt unit of cecum in broiler chickens, A: in straight unit and B: in irregularly-oriented unit (H&E, 200 \times). Villus height (yellow line) was measured from the tip of the villi to the villus-crypt junction (green line), Villus width (red line) was measured from side to side of the villi at its half height, Crypt depth (blue line) measurement was based on the depth of invagination between adjacent villi.

Statistical analysis¹⁵

Data analysis used the two-tailed T Test for independent²⁴ samples, and $p < 0.05$ was the accepted significant value. It was conducted with SPSS (Version, 24) for Windows OS (SPSS, Chicago, IL, USA). The results are presented in mean \pm standard error.

RESULTS AND DISCUSSION

From the five dependent variables examined, profound decline of CD ($p < 0.05$)⁸ was observed in t¹⁹ chickens of T group compared to C group (Figure 2 and figure 3). The remaining variables did not express significant difference between the two groups ($p > 0.05$) (Table 1).

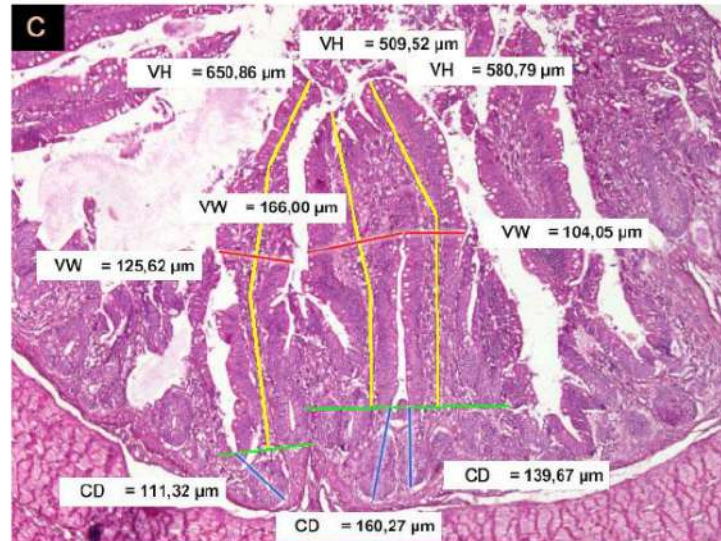


Figure 2. Cecal morphology measurements of broiler chickens of control group from the² study in Surabaya, Indonesia between August and September 2017. ⁶ The yellow lines, red lines, and blue lines represent villus height, villus width, and crypt depth respectively (H&E, $\times 100$). VH: villus height; VW: villus width; CD: crypt depth

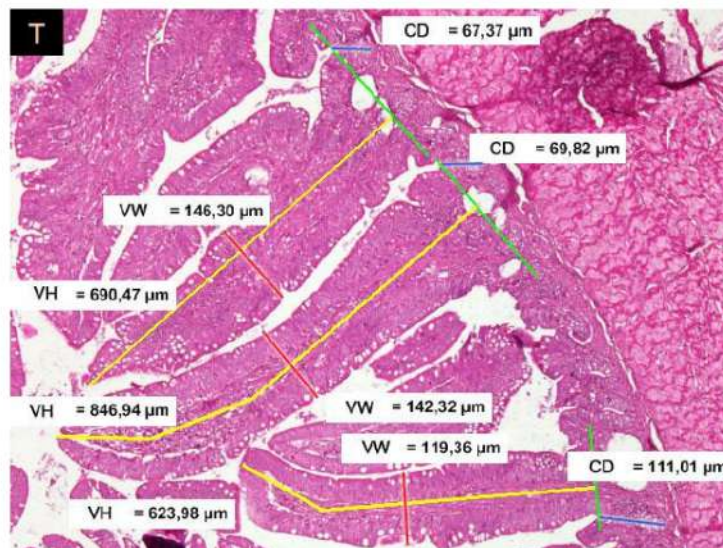


Figure 3. Cecal morphology measurements of broiler chickens from treatment group which were exposed to high ambient temperature and humidity from 22 to 42 days of age during the study in Surabaya, Indonesia between August and September 2017. The² yellow lines, red lines, and blue lines represent villus height, villus width, and crypt depth respectively (H&E, $\times 100$). VH: villus height; VW: villus width; CD: crypt depth.

Table 1. The effect of heat stress on histopathology of ceca in broiler chickens in Surabaya, Indonesia between August and September 2017

Variable	Group C	Group T
VH (μm)	518.66 \pm 31.44	493.22 \pm 45.01
VW (μm)	115.23 \pm 2.86	122.92 \pm 5.25
CD (μm)	116.67 \pm 4.65 ^a	98.84 \pm 5.83 ^b
VSA (μm^2)	189,980.84 \pm 14,538.90	195,195.07 \pm 22,117.80
VH:CD	4.75 \pm 0.28	5.38 \pm 0.56

C: control; T: chickens were exposed to high ambient temperature and humidity from 22-42 days of age; VH: villus height; VW: villus width; CD: crypt depth; VSA: villus surface area; Values are provided with mean \pm standard error; ^{a,b} Different superscripts within the same row mark significantly different means ($p < 0.05$).

HS is able to delay epithelial turnover by means of decreasing feed intake as a result of HPA axis activation (Hu and Guo, 2008). Elevated plasma corticosterone in broiler chickens is indirectly held responsible for the decrease in VH and CD in duodenum and jejunum, but this only occurs in the acute phase instead of chronic (Aggarwal and Upadhyay, 2013). Another proposed mechanism is ischemia in the event of blood diversion to heat-releasing organs, such as the turbinates, the respiratory muscles (Song et al., 2014). Ischemia will lead to vacuolation, rapid sloughing, and loss of microvilli in the intestinal epithelium (Al-Fataftah and Abdelqader, 2014). Moreover, ischemia is also reported to cause oxidative and nitrosative stress which implicated damaged cell membrane, disrupted cellular ion homeostasis, opened tight junctions, and reduced integrity of intestinal mucosa (Al-Fataftah and Abdelqader, 2014). This may proceed to shorter villi but deeper crypts to compensate (Song et al., 2014). The injured mucosa also disables the attachment of commensal bacteria. In addition, the expression of Heat Shock Protein (HSP) may act as receptor for pathogens, while lack of goblet cells which equals falling mucin production promotes the adhesion of pathogens to mucosa (Burkholder et al., 2008; Shah et al., 2019).

The VH, VW, VSA, and VH:CD ratio in present research were barely affected by the heat exposure (36-40°C and RH 45-65%) for eight hours/day along 21 days. Similar findings were attributed by Quinteiro-Filho et al. (2010) to the rapid periodical re-epithelization of intestinal mucosa in the absence of structural adaptation. This explanation is however inappropriate for this case given that it normally occurs in acute or shorter period of cyclic chronic HS, i.e. (seven days). Chronic HS for over one week has been recorded to consistently diminish VH in the absence of adaptation or compensation, although temperature exceeding 36 \pm 1°C could accelerate this process into less than a week (Santos et al., 2015; Abdelqader and Al-Fataftah, 2016; Yi et al., 2016). Meanwhile, CD showed variable responses to HS (decreased, increased, or no difference) regardless of the HS duration. This denoted that there are different sequences of alterations, and their progression is dependent on the level of temperature and internal variation of the organisms subjected to HS. Within the earlier period of HS when the CD of cecum and small intestine have recovered their VH often did not reach to a similar state, in other words changes in villi are initiated by the crypts (Deng et al., 2012; Abdelqader and Al-Fataftah, 2016).

Crypt of Lieberkühn, being the location of stem cells, is the center for proliferation of intestinal epithelium. The newly generated enterocytes then migrate up and are ejected at the villus tip. Because crypts merely grow in length, the activity level of crypts is proportional to CD (Cummins et al., 2011). Significantly ($p < 0.05$) shallower CD in the T group thus indicated less proliferation rate. The crypts due to proliferative property, were the first part of intestine observed to suffer from stress as remarked by Burkholder et al. (2008). By combining this fact with current results, it can be interpreted that the cecum of chickens in T group is on early phase of damage despite the prolonged HS. The possibility that injury on the cecum of T group was a start can also explain the insignificant ($p > 0.05$) alterations of other variables besides CD. This idea is reinforced by the inference that colon (including cecum) is one of the segments more resistant to HS characterized by lower expression of HSP70 and HSP90 mRNA (Varasteh et al., 2015). If the order of segment susceptibility is to be associated with epithelial migration time, they may lay the basics for cecum's resistance against HS. The proximal cecum of Leghorns had demonstrated longer turnover time than duodenum (four days compared with 72 hours) in the research performed by Takeuchi et al. (1998). Similarly, epithelial migration time in the ceca of Japanese quails was much higher than in their small intestine, and it was second only to rectum, as noted by Starck (1998).

The development of adaptations by the chickens subjected to present study can be considered as another reason. It takes longer period to impair the intestinal compensatory mechanisms in adaptive birds according to Santos et al. (2015). This was reflected by the zero mortality of the Cobb broiler chickens taking part in comparison to 12.5% death of Hubbard chickens following a shorter period of HS with slightly lower temperature applied in Al-Fataftah and Abdelqader (2014)'s research. The adaptive trait might have originated from the Cobb strain itself or from inherited

adaptation subsequent to breeding attempts in the warm climate of Indonesia. Warm ambience could unknowingly perform an act termed as thermal manipulation on chickens prior to hatching which is capable of assisting thermotolerance acquisition (Al-Zghoul et al., 2019). Likewise, it is known that poultry are very likely to develop acclimatization when kept under tropical and subtropical climates with over two months of high temperature (He et al., 2018). Therefore, it can be deduced that the chickens in this study did not need deep crypts in their ceca to preserve their villi from potential casualties because they had created such an effective mechanism enabling them to withstand the lengthy HS (Biasato et al., 2018).

These results contradict those obtained by Deng et al. (2012) which found that the CD of layer hens' ceca was initially reduced by chronic HS on day six but returned to normal on day 12 (last day) while VH remained low throughout the experiment. This difference may be linked to breed, implying that broilers are more resistant than layers, or age of the chicken at the time of HS.

The retarded crypt activity might bring about decreased VH later as the HS progresses (Al-Fatafiah and Abdelqader, 2014). CD, VW, and VSA can be enhanced in order to compensate the increased destruction, but still providing sufficient absorption area for nutrients (Santos et al., 2015). The VH:CD ratio inversely portrays the rate of epithelial turnover in the intestine, its value is smaller in heat stressed chickens due to induced inflammatory reaction (Laudadio et al., 2012; Shah et al., 2019). When the value is constant, the number of villi per unit area is required to be taken into account. It is recommended to eliminate the possibility that HS has reduced the number of villi instead of the villus morphometry (Marchini et al., 2016).

CONCLUSION

The resilience of broiler chickens' ceca to chronic HS was confirmed in this research. This feature can be credited to intestinal segment-specific resistance which may be explained by the slower epithelial turnover rate in cecum than in small intestine. Additionally, the current findings also suggest that broiler chickens in Indonesia have undergone an adaptation process to the high daily temperature. Nevertheless, it did not remove the possibility of damage progression if the heat exposure is extended.

DECLARATIONS

Acknowledgements

The authors are most grateful to the lecturers and staff of Veterinary Pathology Department, Faculty of Veterinary Medicine, Airlangga University for the technical assistance and facilities that were prepared. Also, the authors appreciate all participants who contributed to the completion of this work.

Competing interests

The authors have declared that no competing interests exist.

Consent to publish

All the authors approved and agreed to publish the manuscript and declared that this work has not been previously published elsewhere.

Authors' contributions

Hani Plumeriastuti drafted and revised the manuscript while monitoring the course of the study. Anwar Ma'ruf was involved in revising the manuscript, also data analysis, presentation, and interpretation. Djoko Legowo devised the study and participated in its design and coordination, as well as guided the examination and analysis of the histopathological slides. Antonia Vania Adji participated in the execution of the study, data analysis, composition and revision of the manuscript. All authors read and approved the final manuscript.

REFERENCES

- Abdelqader A and Al-Fatafiah A-R (2016). Effect of Dietary Butyric Acid on Performance, Intestinal Morphology, Microflora Composition, and Intestinal Recovery of Heat-stressed Broilers. *Livestock Science*, 183: 78-83. DOI: <https://doi.org/10.1016/j.livsci.2015.11.026>
- Aggarwal A and Upadhyay R (2013). *Heat Stress and Animal Productivity*. Springer, New Delhi, p. 32. DOI: <https://doi.org/10.1007/978-81-322-0879-2>
- Al-Fatafiah A-R and Abdelqader A (2014). Effects of Dietary *Bacillus subtilis* on Heat-stressed Broilers Performance, Intestinal Morphology and Microflora Composition. *Animal Feed Science and Technology*, 198: 279-285. DOI: <https://doi.org/10.1016/j.anifeedsci.2014.10.012>

- Al-Zghoul MB, Allifitawi AREs, Saleh KMM and Jaradat ZW (2019). Expression of Digestive Enzyme and Intestinal Transporter Genes during Chronic Heat Stress in the Thermally Manipulated Broiler Chicken. *Poultry Science*, 98 (9): 4113-4122. DOI: <https://doi.org/10.3382/ps/pez249>
- Biasato I, Ferrocino I, Biasibetti E, Grego E, Dabbou S, Sereno A, Gai F, Gasco L, Schiavone A, Cocolin L et al. (2018). Modulation of Intestinal Microbiota, Morphology and Mucin Composition by Dietary Insect Meal Inclusion in Free-Range Chickens. *BMC Veterinary Research*, 14: 383. DOI: <https://doi.org/10.1186/s12917-018-1690-y>
- Bolek KJ (2013). Mitigation Strategies to Ameliorate Acute and Chronic Heat Stress Utilizing Supplemental Methionine or Embryonic Thermal Conditioning in Chickens. M.Sc. Thesis, Nutritional Sciences, Iowa State University, Iowa, pp. 11-12.
- Burkholder KM, Thompson KL, Einstein ME, Applegate TJ and Patterson JA (2008). Influence of Stressors on Normal Intestinal Microbiota, Intestinal Morphology, and Susceptibility to *Salmonella Enteritidis* Colonization in Broilers. *Poultry Science*, 87: 1734-1741. DOI: <https://doi.org/10.3382/ps.2008-00107>
- Cummins AG, Alexander BG, Chung A, Teo E, Woenig JA, Field JBJ, Thompson FM and Roberts-Thomson IC (2011). Morphometric Evaluation of Duodenal Biopsies in Celiac Disease. *The American Journal of Gastroenterology*, 106: 145-150. DOI: <https://doi.org/10.1038/ajg.2010.313>
- Deng W, Dong XF, Tong JM and Zhang Q (2012). The Probiotic *Bacillus licheniformis* Ameliorates Heat Stress-Induced Impairment of Egg Production, Gut Morphology, and Intestinal Mucosal Immunity in Laying Hens. *Poultry Science*, 91: 575-582. DOI: <https://doi.org/10.3382/ps.2010-01293>
- El-Daly EF, El-Azcm NAA, El-Wardany I, Gawad AHAE and Hemid AEA (2014). Effect of Different Anti-Stress Feed Additives on Some Blood Metabolites and Lymphoid Organs Histology in Laying Japanese Quail. *World Applied Sciences Journal*, 29 (12): 1574-1585. DOI: <https://doi.org/10.5829/dosi.wasj.2014.29.12.8238>
- Godwin OC, Clifford AN and Agatha A (2016). Evaluation of the Morphological Adaptations of the Small Intestine of the African Pied Crow (*Corvus albus*). *The Journal of Basic and Applied Zoology*, 75: 54-60. DOI: <https://doi.org/10.1016/j.jobaz.2016.12.002>
- He J, He Y, Pan D, Cao J, Sun Y and Zeng X (2019). Associations of Gut Microbiota with Heat Stress-Induced Changes of Growth, Fat Deposition, Intestinal Morphology, and Antioxidant Capacity in Ducks. *Frontiers in Microbiology*, 10: 903. DOI: <https://doi.org/10.3389/fmicb.2019.00903>
- He X, Lu Z, Ma B, Zhang L, Li J, Jiang Y, Zhou G and Gao F (2018). Effects of Chronic Heat Exposure on Growth Performance, Intestinal Epithelial Histology, Appetite-Related Hormones and Genes Expression in Broilers. *Journal of the Science of Food and Agriculture*, 98 (12): 4471-4478. DOI: <https://doi.org/10.1002/jsfa.8971>
- Hu X and Guo Y (2008). Corticosterone Administration Alters Small Intestinal Morphology and Function of Broiler Chickens. *Asian-Australasian Journal of Animal Sciences*, 21 (12): 1773 - 1778.
- Ijaz UZ, Sivaloganathan L, McKenna A, Richmond A, Kelly C, Linton M, Stratakos AC, Lavery U, Elmi A, Wren BW et al. (2018). Comprehensive Longitudinal Microbiome Analysis of the Chicken Cecum Reveals a Shift From Competitive to Environmental Drivers and a Window of Opportunity for *Campylobacter*. *Frontiers in Microbiology*, 9: 2452. DOI: <https://doi.org/10.3389/fmicb.2018.02452>
- Jaafar NS (2013). Histopathological Changes of Lymphoid System in Broiler Chicks After Treatment with *Lactobacillus acidophils* under Heat Stress. *Al-Anbar Journal of Veterinary Sciences*, 6 (1): 163-171.
- Kum S, Eren U, Korkmaz D, Sandikci M and Aydemir I (2015). Effects of Vitamin E on T Cells in Gut-Associated Lymphoid Tissue (GALT) of Broiler Chickens under Heat Stress. *Veterinarija Ir Zootechnika*, 71 (93): 39-47.
- Lara LJ and Rostagno MH (2013). Impact of Heat Stress on Poultry Production. *Animals*, 3: 356-369. DOI: <https://doi.org/10.3390/ani3020356>
- Laudadio V, Passantino L, Perillo A, Lopresti G, Passantino A, Khan RU and Tufarelli V (2012). Productive Performance and Histological Features of Intestinal Mucosa of Broiler Chickens Fed Different Dietary Protein Levels. *Poultry Science*, 91: 265-270. DOI: <https://doi.org/10.3382/ps.2011-01675>
- Loyau T, Bedrani L, Berri C, Métayer-Coustard S, Praud C, Coustham V, Mignon-Grasteau S, Duclos MJ, Tesseraud S, Rideau N et al. (2015). Cyclic Variations in Incubation Conditions Induce Adaptive Responses to Later Heat Exposure in Chickens: A Review. *Animal*, 9 (1): 76-85. DOI: <https://doi.org/10.1017/S1751731114001931>
- Marchini CFP, Café MB, Araújo EG and Nascimento MRBM (2016). Physiology, Cell Dynamics of Small Intestinal Mucosa, and Performance of Broiler Chickens under Heat Stress: A Review. *Revista Colombiana de Ciencias Pecuarias*, 29: 159-168. DOI: <https://doi.org/10.17533/udea.rccp.v29n3a01>
- Mishra B and Jha R (2019). Oxidative Stress in the Poultry Gut: Potential Challenges and Interventions. *Frontiers in Veterinary Science*, 6: 60. DOI: <https://doi.org/10.3389/fvets.2019.00060>
- Park S-O, Hwangbo J, Ryu C-M, Park B-S, Chae H-S, Choi H-C, Kang H-K, Seo O-S and Choi Y-H (2013). Effects of Extreme Heat Stress on Growth Performance, Lymphoid Organ, IgG, and Cecum Microflora of Broiler Chickens. *International Journal of Agriculture and Biology*, 15 (6): 1204-1208.

- Quinteiro-Filho WM, Ribeiro A, Ferraz-de-Paula V, Pinheiro ML, Sakai M, Sá LRM, Ferreira AJP and Palermo-Neto J (2010). Heat Stress Impairs Performance Parameters, Induces Intestinal Injury, and Decreases Macrophage Activity in Broiler Chickens. *Poultry Science*, 89: 1905-1914. DOI: <https://doi.org/10.3382/ps.2010-00812>
- Santos RR, Awati A, Hil PJR-vd, Tersteeg-Zijderveld MHG, Koolmees PA and Fink-Gremmels J (2015). Quantitative Histo-Morphometric Analysis of Heat-Stress-Related Damage in the Small Intestines of Broiler Chickens. *Avian Pathology*, 44 (1): 19-22. DOI: <https://doi.org/10.1080/03079457.2014.988122>
- Shah M, Zaneb H, Masood S, Khan RU, Mobashar M, Khan I, Din S, Khan MS, Rehman HU and Tinelli A (2019). Single or Combined Applications of Zinc and Multi-strain Probiotic on Intestinal Histomorphology of Broilers Under Cyclic Heat Stress. Probiotics and Antimicrobial Proteins, (Online First): 1-8. DOI: <https://doi.org/10.1007/s12602-019-09561-6>
- Shokryazdan P, Jahromi MF, Liang JB, Ramasamy K, Sico CC and Ho YW (2017). Effects of A *Lactobacillus salivarius* Mixture on Performance, Intestinal Health, and Serum Lipids of Broiler Chickens. *PLoS ONE*, 12 (5): e0175959. DOI: <https://doi.org/10.1371/journal.pone.0175959>
- Song J, Xiao K, Ke YL, Jiao LF, Hu CH, Diao QY, Shi B and Zou XT (2014). Effect of A Probiotic Mixture on Intestinal Microflora, Morphology, and Barrier Integrity of Broilers Subjected to Heat Stress. *Poultry Science*, 93: 581–588. DOI: <https://doi.org/10.3382/ps.2013-03455>
- Sozcu A (2019). Intestinal Integrity of Broilers Exposed to Heat Stress. *Acta Scientific Agriculture*, 3 (1): 59-61.
- Starck JM (1998). Structural Variants and Invariants in Avian Embryonic and Postnatal Development. In: Starck JM and Ricklefs RE (Editors), *Avian Growth and Development: Evolution within the Altricial-Precocial Spectrum*. Oxford University Press, New York, p. 84.
- Takeuchi T, Kitagawa H, Imagawa T and Uehara M (1998). Proliferation and Cellular Kinetics of Villous Epithelial Cells and M Cells in the Chicken Caecum. *Journal of Anatomy*, 193: 233-239.
- Thornton PK, Steeg Jvd, Notenbaert A and Herrero M (2009). The Impacts of Climate Change on Livestock and Livestock Systems in Developing Countries: A Review of What We Know and What We Need to Know. *Agricultural Systems*, 101: 113–127. DOI: <https://doi.org/10.1016/j.agsy.2009.05.002>
- Varasteh S, Braber S, Akbari P, Garssen J and Gremmels JF- (2015). Differences in Susceptibility to Heat Stress along the Chicken Intestine and the Protective Effects of Galacto-Oligosaccharides. *PLoS ONE*, 10 (9): e0138975. DOI: <https://doi.org/10.1371/journal.pone.0138975>
- Yi D, Hou Y, Tan L, Liao M, Xie J, Wang L, Ding B, Yang Y and Gong J (2016). N-Acetylcysteine Improves the Growth Performance and Intestinal Function in The Heat-Stressed Broilers. *Animal Feed Science and Technology*, 220: 83-92. DOI: <https://doi.org/10.1016/j.anifeeds.2016.07.014>
- Zhang C, Zhao XH, Yang L, Chen XY, Jiang RS, Jin SH and Geng ZY (2017). Resveratrol Alleviates Heat Stress-Induced Impairment of Intestinal Morphology, Microflora, and Barrier Integrity in Broilers. *Poultry Science*, 96: 4325–4332. DOI: <https://doi.org/10.3382/ps/pex266>

Histopathological Alterations of Ceca in Broiler Chickens (Gallus gallus) Exposed to Chronic Heat Stress

ORIGINALITY REPORT

17%

SIMILARITY INDEX

13%

INTERNET SOURCES

13%

PUBLICATIONS

0%

STUDENT PAPERS

PRIMARY SOURCES

- | | | |
|---|---|----|
| 1 | link.springer.com
Internet Source | 1% |
| 2 | Seyed Morteza Eftekhari, Ahmad Hassanabadi, Abdolmansour Tahmasebi, Abolghasem Golian, Hassan Nassiri-Moghaddam. " The effect of hydroalcoholic extract of angelica (fruit on performance, immune responses, small intestine histology, haematological parameters and carcass characteristics of broiler chickens ", Journal of Applied Animal Research, 2018
Publication | 1% |
| 3 | www.e-journal.unair.ac.id
Internet Source | 1% |
| 4 | Cristina Ullrich, Marion Langeheine, Ralph Brehm, Venja Taube, Diana Siebert, Christian Visscher. "Influence of Reduced Protein Content in Complete Diets with a Consistent Arginine–Lysine Ratio on Performance and | 1% |

Nitrogen Excretion in Broilers", Sustainability, 2018

Publication

5	irep.ntu.ac.uk Internet Source	1 %
6	coek.info Internet Source	1 %
7	www.mdpi.com Internet Source	1 %
8	www.veterinaryworld.org Internet Source	1 %
9	ejournals.epublishing.ekt.gr Internet Source	<1 %
10	jwpr.science-line.com Internet Source	<1 %
11	www.frontiersin.org Internet Source	<1 %
12	Marcos H Rostagno. "Effects of heat stress on the gut health of poultry", Journal of Animal Science, 2020 Publication	<1 %
13	Saman Alam, Saima Masood, Hafsa Zaneb, Imtiaz Rabbani, Rifat Ullah Khan, Muqader Shah, Saima Ashraf, Ibrahim A. Alhidary. "Effect of <i>Bacillus cereus</i> and Phytase on the Expression of Musculoskeletal Strength and	<1 %

Gut Health in Japanese Quail (*Coturnix japonica*)", *The Journal of Poultry Science*, 2019

Publication

14

[researcherslinks.com](https://www.researcherslinks.com)

Internet Source

<1 %

15

www.nature.com

Internet Source

<1 %

16

Haohang Fang, Jiajun Xie, Shiyu Liao, Tianyu Guo, Shiwei Xie, Yongjian Liu, Lixia Tian, Jin Niu. "Effects of Dietary Inclusion of Shrimp Paste on Growth Performance, Digestive Enzymes Activities, Antioxidant and Immunological Status and Intestinal Morphology of Hybrid Snakehead (*Channa maculata* ♀ × *Channa argus* ♂)", *Frontiers in Physiology*, 2019

Publication

<1 %

17

Parviz Allahdo, Javad Ghodraty, Heydar Zarghi, Zohre Saadatfar, Hassan Kermanshahi, Mohammad Reza Edalatian Dovom. "Effect of probiotic and vinegar on growth performance, meat yields, immune responses, and small intestine morphology of broiler chickens", *Italian Journal of Animal Science*, 2018

Publication

<1 %

18

Danish Sharafat Rajput, Dong Zeng, Abdul Khalique, Samia Sharafat Rajput, Hesong

<1 %

Wang, Ying Zhao, Ning Sun, Xueqin Ni.
"Pretreatment with probiotics ameliorate gut health and necrotic enteritis in broiler chickens, a substitute to antibiotics", AMB Express, 2020

Publication

19

docksci.com

Internet Source

<1 %

20

eprints.qut.edu.au

Internet Source

<1 %

21

www.european-poultry-science.com

Internet Source

<1 %

22

J. Song, L.F. Jiao, K. Xiao, Z.S. Luan, C.H. Hu, B. Shi, X.A. Zhan. "Cello-oligosaccharide ameliorates heat stress-induced impairment of intestinal microflora, morphology and barrier integrity in broilers", Animal Feed Science and Technology, 2013

Publication

<1 %

23

R Y Vitanti, M Lamid, W P Lokapirnasari, M Amin. "Dry matter, crude fiber and nitrogen free extract contents of Seligi leaf (Phyllanthus buxifolius) powder fermented with different duration and probiotic's dose as a fish feed ingredient", IOP Conference Series: Earth and Environmental Science, 2021

Publication

<1 %

24

peerj.com
Internet Source

<1 %

25

E. A. Awad, Z. Idrus, A. Soleimani Farjam, A. U. Bello, M. F. Jahromi. "Growth performance, duodenal morphology and the caecal microbial population in female broiler chickens fed glycine-fortified low protein diets under heat stress conditions", *British Poultry Science*, 2018

Publication

<1 %

26

E. Jahanian, A.H. Mahdavi, R. Jahanian. "Silymarin Improved the Growth Performance via Modulating the Microbiota and Mucosal Immunity in Escherichia coli-Challenged Broiler Chicks", *Livestock Science*, 2021

Publication

<1 %

27

Muhammad U. Sohail, Michael E. Hume, James A. Byrd, David J. Nisbet, Muhammad Z. Shabbir, Ahmad Ijaz, Habib Rehman. "Molecular analysis of the caecal and tracheal microbiome of heat-stressed broilers supplemented with prebiotic and probiotic", *Avian Pathology*, 2015

Publication

<1 %

28

Peng Xu, Hai Lin, Hongchao Jiao, Jingpeng Zhao, Xiaojuan Wang. "Advances in epigenetic mechanisms of chick embryo heat

<1 %

29 Sbardella, M.. "Rice oil as a soybean oil replacement in weanling pig diets", Livestock Science, 201205 $<1\%$
Publication

30 Wen-Chao Liu, Yan Guo, Li-Long An, Zhi-Hui Zhao. "Protective effects of dietary betaine on intestinal barrier function and cecal microbial community in indigenous broiler chickens exposed to high temperature environment", Environmental Science and Pollution Research, 2020 $<1\%$
Publication

31 ddd.uab.cat $<1\%$
Internet Source

32 jasbsci.biomedcentral.com $<1\%$
Internet Source

33 weiwei wang, Huiyi Cai, Anrong Zhang, Zhimin Chen, Wenhuan Chang, Guohua Liu, Xuejuan Deng, Wayne L. Bryden, Aijuan Zheng. "Enterococcus Faecium Modulates the Gut Microflora of Broilers and Enhances Phosphorus Absorption and Utilization", Research Square, 2020 $<1\%$
Publication

34

www.cambridge.org

Internet Source

<1 %

35

www.scielo.br

Internet Source

<1 %

36

www.springerprofessional.de

Internet Source

<1 %

37

G.A. Chishti, T.L. Felix. "Effects of supplemental calcium butyrate on lamb growth, plasma metabolites, and hepatic gluconeogenic and inflammatory gene expression changes", *Animal Feed Science and Technology*, 2020

Publication

<1 %

38

Sugiharto Sugiharto, Turrini Yudiarti, Isroli Isroli, Endang Widiastuti, Endang Kusumanti. "Dietary supplementation of probiotics in poultry exposed to heat stress – a review", *Annals of Animal Science*, 2017

Publication

<1 %

39

assets.researchsquare.com

Internet Source

<1 %

40

cjascience.com

Internet Source

<1 %

41

repository.stikim.ac.id

Internet Source

<1 %

42

"Poster presentations", Advances in Animal Biosciences, 2011

Publication

<1 %

43

Alhanof Alhenaky, Anas Abdelqader, Mohannad Abuajamieh, Abdur-Rahman Al-Fataftah. "The effect of heat stress on intestinal integrity and Salmonella invasion in broiler birds", Journal of Thermal Biology, 2017

Publication

<1 %

44

W.M. Quinteiro-Filho, A.S. Calefi, D.S.G. Cruz, T.P.A. Aloia et al. "Heat stress decreases expression of the cytokines, avian β -defensins 4 and 6 and Toll-like receptor 2 in broiler chickens infected with Salmonella Enteritidis", Veterinary Immunology and Immunopathology, 2017

Publication

<1 %

45

"Heat Shock Proteins in Veterinary Medicine and Sciences", Springer Science and Business Media LLC, 2017

Publication

<1 %

Exclude quotes Off

Exclude matches Off

Exclude bibliography On

Histopathological Alterations of Ceca in Broiler Chickens (Gallus gallus) Exposed to Chronic Heat Stress

GRADEMARK REPORT

FINAL GRADE

/0

GENERAL COMMENTS

Instructor

PAGE 1

PAGE 2

PAGE 3

PAGE 4

PAGE 5

PAGE 6

PAGE 7
