

Long-term albendazole therapy for diffuse parenchymal neurocysticercosis in an immunocompetent patient: A case report

by Paulus Sugianto


Submission date: 16-Jun-2023 11:52AM (UTC+0800)

Submission ID: 2117063628

File name: Long-term_albendazole_therapy.pdf (752.38K)

Word count: 2027

Character count: 11570



Case Report

Asian Pacific Journal of Tropical Medicine



doi: 10.4103/1995–7645.368014

Impact Factor: 3.041

Long-term albendazole therapy for diffuse parenchymal neurocysticercosis in an immunocompetent patient: A case report

Paulus Sugianto[✉], Abdulloh Machin, Wardah Rahmatul Islamiyah, Cindy Cecilia

Department of Neurology, Faculty of Medicine–Universitas Airlangga / Dr. Soetomo General–Hospital, Surabaya, Indonesia

ABSTRACT

Rationale: Neurocysticercosis is a neglected tropical disease caused by the larvae of *Taenia solium* and may occur in immunocompetent people. We report a case of diffuse parenchymal neurocysticercosis mimicking tuberculous meningitis in an immunocompetent patient.

Patient concerns: A 24-year-old immunocompetent woman presented with serial focal to generalized seizure, left body weakness, left abducens palsy, chronic cough, and body weight loss. She came from an area where she was unlikely to have contact with *Taenia solium*.

Diagnosis: Diffuse parenchymal neurocysticercosis.

Intervention: Valproic acid, dexamethasone and 15 months of albendazole therapy.

Outcome: Complete recovery without any neurological sequelae.

Lessons: Prolonged anthelmintic treatment may benefit neurocysticercosis patients with multiple cerebral parenchymal lesions.

KEYWORDS: Albendazole; Corticosteroid; Neurocysticercosis; Prognosis; *Taenia solium*; Tuberculous meningitis

1. Introduction

Neurocysticercosis (NCC) is the most severe form of parasitic cysticercosis disease affecting the brain. The World Health Organization (WHO) states that NCC is a neglected tropical disease caused by ingesting *Taenia solium* from raw or undercooked meat and vegetables[1]. The prevalence rate of NCC in Asia ranges from 0.8% to 41.8%, depending on each country's socioeconomic culture, diet and hygiene. Thailand, Vietnam, and the Philippines have the highest prevalence[1]. Indonesia is an archipelago country with a total NCC prevalence from 1985 to 2006, which is 5.2%–21.0%[1]. According to WHO, cysticercosis leads to 2.8 million

disability-adjusted life-years. The major manifestations are seizures, headaches, and focal neurological deficits. Anthelmintics, steroid, antiepileptic drug, or surgical approach varies depending on the stage of the disease[2]. The prognosis for NCC is generally good, but in severe cases, it can lead to sequelae or death[3].

2. Case report

A 24-year-old immunocompetent woman was referred from secondary healthcare with serial right focal to secondary generalized seizure with suspicion of tuberculous meningoencephalitis.

The first seizure was noted five months before admission, with progressive headache, fever, chronic cough, and loss of body weight two months before the first seizure. Due to a lack of healthcare facilities, the patient was referred to a tertiary hospital for further diagnosis and treatment.

She was a local-born Muslim Indonesian lady who was currently a university student. She was living in a rural area in east Java. This housing residence was not near an agricultural or animal husbandry area. She had previously not traveled to the domestic or overseas area and had no contact with NCC patients or with similar symptoms. She has proper hygiene and no history of eating raw or undercooked porcine products. Her risk factor for getting NCC was eating raw vegetables. Her Housing area had a poor public water system, which is also a possible risk factor for getting NCC.

[✉]To whom correspondence may be addressed. E-mail: paulus.sugianto@fk.unair.ac.id
This is an open access journal, and articles are distributed under the terms of the Creative Commons Attribution-Non Commercial-Share Alike 4.0 License, which allows others to remix, tweak, and build upon the work non-commercially, as long as appropriate credit is given and the new creations are licensed under the identical terms.

For reprints contact: reprints@medknow.com

©2023 Asian Pacific Journal of Tropical Medicine Produced by Wolters Kluwer Medknow.

How to cite this article: Sugianto P, Machin A, Islamiyah WR, Cecilia C. Long-term albendazole therapy for diffuse parenchymal neurocysticercosis in an immunocompetent patient: A case report. Asian Pac J Trop Med 2023; 16(2): 89-91.

Article history: Received 26 October 2022
Accepted 5 January 2023

Revision 20 December 2022
Available online 27 February 2023

On the examination, blood pressure was 110/80 mmHg, heart rate was 80 times per minut regular, and temperature 38.5 °C. Her previous body weight before the illness was 59 kg, and she was present with 39 kg on examination. Head and neck, lung, heart, and gastrointestinal examination were normal.

Neurological examination showed higher mental function and was normal with Glasgow Coma Scale (GCS) 4/5, no meningeal sign, and left abducens palsy. An additional laboratory test, tuberculosis screening such as acid-fast-bacillus test, faces examination, chest X-ray, and contrast brain-MRI were performed. Laboratory findings were slight leukopenia, increase in eosinophils, normal neutrophils, negative for HIV test, and normal CD4 levels. The tuberculosis test and feces examination were unremarkable. Head MRI with contrast showed multiple vesicular cystic lesions throughout the brain parenchyma. The largest size was length 1.65 cm and width 1.73 cm which was hypointense on T1W1 hyperintensity T2W1, accompanied by leptomeningeal enhancement with scolex appearance. This result was consistent with active neurocysticercosis

(Figure 1A). Electroencephalogram (EEG) revealed epileptogenicity on the left temporo-occipital. The patient received valproic acid 500 mg twice daily, folic acid, and albendazole 400 mg/day for 15 months.

The patient was re-admitted to the emergency room 4 months after initial treatment due to status epilepticus, decreased consciousness, left hemiparesis, and increased intracranial pressure (ICP). A brain CT scan showed massive brain edema. Dexamethasone 10 mg intravenously, continued by 5 mg three times daily, was administered for five days. She was discharged with oral dexamethasone and tapered off for 2 months. Left hemiparesis and abducens palsy was improving with GCS 15. Albendazole continued until 15 months. The patient has gained 27 kg with left abducens palsy, and hemiparesis was resolved entirely after 11 months of initial treatment. The seizure was controlled after 13 months of anthelmintic treatment. Valproic acid tapered off when the EEG test showed no epileptogenicity after 2 years of therapy and no further clinical seizure. Treatment duration and timeline can be seen in Figure 2.

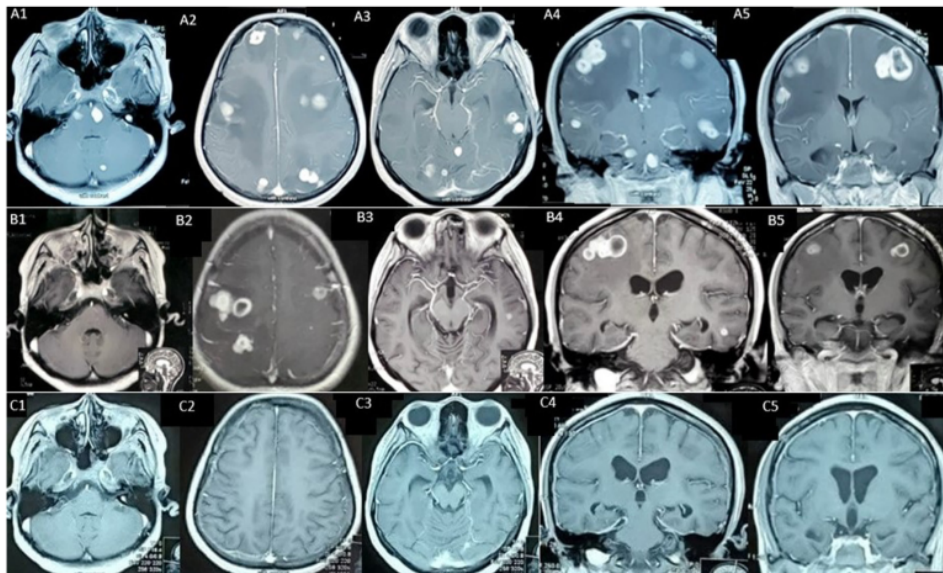


Figure 1. (A) A1-A5 initial head MRI with contrast showed multiple parenchymal cystic lesions with scolex. (B) B1-B5 head MRI with contrast after 6.5 months after initial treatment showed multiple parenchymal cystic lesions. (C) C1-C5 head MRI with contrast after 15 months of albendazole therapy showed almost diminished nodule.

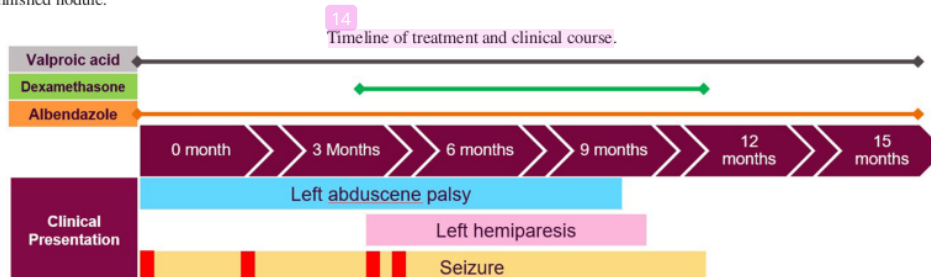


Figure 2. Timeline of treatment and clinical course. Steroids were given during the 4 months treatment period due to cerebral oedema and tapered off until 3 months. Left hemiparesis was present after 4 months, accompanied by a status epilepticus attack (shown by the red box colored).

3. Discussion

Clinical presentation of NCC might mimic other brains infectious diseases[4]. In developing tropical countries such as Indonesia, tuberculosis is endemic[5]. Muslims, as the major population of Indonesia consisting of 87.2%, usually do not eat uncooked meat. Taeniasis is only prevalent in certain districts, such as Bali province, with the majority being Hindu, North Sulawesi and Papua. Therefore, she was suspected of having tuberculous meningoencephalitis[6,7]. Due to a lack of healthcare facility, she was referred to the nearest tertiary health center. Diagnosis of NCC was made after Del-Bruto criteria with the result of definite NCC. It met 1 absolute and 2 major criteria, multiple cystic lesions with scolex showed on MRI, which was highly suggestive of NCC, and cystic resolution after albendazole administration[2].

Anthelmintic therapy, oral albendazole, was initiated with a dose of 15 mg/kg/day. Monotherapy was chosen over dual antiparasitic treatment due to the risk of raised ICP. A study showed that dual antiparasitic therapy could lead to more parasitic cell death and a shorter resolution time. Single albendazole could reach the same result with a higher dose[2].

As the active cyst was still present on brain MRI, albendazole was continued for 15 months. Adverse reactions during treatment, such as headache, dizziness, transaminitis and urticaria, were not found. This adverse reaction was uncommon in monotherapy compared to dual therapy[2]. There is no standard recommendation on the duration of treatment, repeating antihelmintic therapy. Most cases depend on clinical and imaging data.

Studies suggest steroids can accelerate seizure control and cyst resolution[8,9]. Other studies have used this steroid as a priming 3 days before albendazole treatment to prevent a sudden inflammatory brain reaction. The duration and timing of steroid administration vary depending on the patient clinical presentation[8]. The patient was given dexamethasone during readmission in the Emergency Room. There was massive brain edema with increased ICP due to parasite inflammatory response. It was switched into an oral regimen and tapered until 3-month period. It was discontinued after the patient's neurological deficit improved. Long term steroids medication can cause opportunistic infections such as *Strongyloides stercoralis*, which is co-endemic with *Taenia solium* and *Mycobacterium tuberculosis*[8,10].

There were no seizures after 13 months of anthelmintic treatment and 500 mg of valproic acid twice daily. Epileptogenicity in EEG returned to normal 2 years after treatment, and the neurological deficit resolved after 11 months without any sequelae. The patient also gained 27 kg body weight.

Appropriate treatment and monitoring in cases of NCC can provide a good outcome. Long-term use of albendazole, in this case, did not give an adverse reaction and was still proven to be effective in treating severe NCC.

In conclusion, in countries where cysticercosis is endemic, diagnosis and screening for NCC in a low-probability individual still have to be considered. There are no absolute guidelines on NCC's duration and combination of antiparasitic treatment. Different doses and duration of therapy have been applied differently, and most cases are based on expert or individual recommendations. Further study should be carried out for the patient's benefit and safety.

Conflict of interest statement

The authors declare that there is no conflict of interests.

Funding

The authors received no extramural funding for the study.

Authors' contributions

PS conceptualized the global case. WRI and CC performed diagnostic tools. PS, AM and CC monitored and collected patient data. PS and AM analysed and interpreted the case. PS, AM and CC drafted the manuscript.

References

- [1] Bizhani N, Hashemi SH, Mohammadi N, Rezaei M, Rokni MB. Human cysticercosis in Asia: A systematic review and meta-analysis. *Iran J Public Health* 2020; **49**(10): 1839-1847.
- [2] Jaime F, Randy GO, Sandra PC, Javier MF, Liliana M, Alfonso TC, et al. Long-term follow-up of patients with neurocysticercosis and the development of seizures. *J Transl Sci* 2016; **1**(2): 49-54.
- [2] Butala C, Brook TM, Majekodunmi AO, Welburn SC. Neurocysticercosis: Current perspectives on diagnosis and management. *Front Vet Sci* 2021; **8**(5): 1-10.
- [4] Garcia HH, Nash TE, Del Brutto OH. Clinical symptoms, diagnosis, and treatment of neurocysticercosis. *Lancet Neurol* 2014; **13**(12): 1202-1215.
- [5] Bintari DC, Ardiansyah D, Sugianto P. *Mycobacterium tuberculosis* infection in the central nervous system mimicking metastatic process. *Ann Rom Soc Cell Biol* 2021; **25**(6): 20360-20365.
- [6] Cupertino M, Resende M, Mayer N, Carvalho L, Siqueira-Batista R. Emerging and re-emerging human infectious diseases: A systematic review of the role of wild animals with a focus on public health impact. *Asian Pac J Trop Med* 2020; **13**(3): 99.
- [7] Garg R, Kumar N, Rizvi I, Malhotra H. Disseminated cysticercosis presenting with bilateral proptosis: A case report. *Asian Pac J Trop Med* 2019; **12**(7): 337.
- [8] Pandey S, Malhotra HS, Garg RK, Malhotra KP, Kumar N, Rizvi I, et al. Quantitative assessment of lesion load and efficacy of 3 cycles of albendazole in disseminated cysticercosis: A prospective evaluation. *BMC Infect Dis* 2020; **20**(1): 220.
- [9] Carpio A, Romo ML, Hauser WA, Kelvin EA. New understanding about the relationship among neurocysticercosis, seizures, and epilepsy. *Seizure* 2021; **90**: 123-129.
- [10] Yuzawa H, Hirose Y, Kimura T, Kimura S, Sugawara K, Yanagisawa A, et al. A case of cerebral tuberculoma mimicking neurocysticercosis. *Acute Med Surg* 2017; **4**(3): 329-333.

Publisher's note

The Publisher of the *Journal* remains neutral with regard to jurisdictional claims in published maps and institutional affiliations.

Long-term albendazole therapy for diffuse parenchymal neurocysticercosis in an immunocompetent patient: A case report

ORIGINALITY REPORT

9%

SIMILARITY INDEX

7%

INTERNET SOURCES

8%

PUBLICATIONS

1%

STUDENT PAPERS

PRIMARY SOURCES

- 1 Min Cheol Chang, Yoo Jin Choo, Sohyun Kim. "Effect of prehabilitation on patients with frailty undergoing colorectal cancer surgery: a systematic review and meta-analysis", *Annals of Surgical Treatment and Research*, 2023
Publication 1%
- 2 www.thefreelibrary.com
Internet Source 1%
- 3 repository.unair.ac.id
Internet Source 1%
- 4 doaj.org
Internet Source 1%
- 5 Padma Youron, Surbhi Mahajan, Neeraj Balaini, Sahil Mehta, Vivek Lal. " Fulminant Presenting as a Hyperkinetic Movement Disorder ", *Movement Disorders Clinical Practice*, 2023
Publication 1%

6	ijph.tums.ac.ir Internet Source	1 %
7	www.nornesk.no Internet Source	1 %
8	jbnc.emnuvens.com.br Internet Source	1 %
9	Li-Chao Yang, Guo-Tao Wu, Qiang Wu, Liang-Xin Peng, Ya-Wei Zhang, Bao-Jia Yao, Gang-Lei Liu, Lian-Wen Yuan. "Surgical management of duodenal Crohn's disease", <i>World Journal of Gastrointestinal Surgery</i> , 2023 Publication	1 %
10	Florian Cherik, Mathis Lepage, Ganaelle Remerand, Christine Francannet et al. "Further refining the critical region of 10q26 microdeletion syndrome: A possible involvement of INSYN2 and NPS in the cognitive phenotype", <i>European Journal of Medical Genetics</i> , 2021 Publication	<1 %
11	Indar Kumar Sharawat, Prateek Kumar Panda, Vinod Kumar, Poonam Sherwani. "Comparative Efficacy and Safety of Lacosamide and Oxcarbazepine for Seizure Control in Children with Newly Diagnosed Solitary Neurocysticercosis", <i>Journal of Tropical Pediatrics</i> , 2022	<1 %

12

Meritxell Donadeu, Anna S. Fahrion, Piero L. Olliaro, Bernadette Abela-Ridder. "Target product profiles for the diagnosis of *Taenia solium* taeniasis, neurocysticercosis and porcine cysticercosis", PLOS Neglected Tropical Diseases, 2017

Publication

<1 %

13

journals.plos.org

Internet Source

<1 %

14

Piero Pavone, Raffaele Falsaperla, Martino Ruggieri, Alberto Verrotti et al. "Clinical Course of N-Methyl-D-Aspartate Receptor Encephalitis and the Effectiveness of Cyclophosphamide Treatment", Journal of Pediatric Neurology, 2017

Publication

<1 %

Exclude quotes Off

Exclude matches Off

Exclude bibliography On

Long-term albendazole therapy for diffuse parenchymal neurocysticercosis in an immunocompetent patient: A case report

GRADEMARK REPORT

FINAL GRADE

/100

GENERAL COMMENTS

Instructor

PAGE 1

PAGE 2

PAGE 3
