

# Acute Limb Ischemia due to Arterial Thrombosis in a Patient with COVID-19 Pneumonia: A Case Report

*Renata Primasari<sup>1</sup>, Yetti Hernaningsih<sup>2</sup>, Hartono Kahar<sup>2</sup>, Bramantono<sup>3</sup>*

<sup>1</sup>Clinical Pathology Specialization Program, Faculty of Medicine Universitas Airlangga, Surabaya, Indonesia.

<sup>2</sup>Division of Hematology, Department of Clinical Pathology, Faculty of Medicine Universitas Airlangga, Dr. Soetomo Hospital, Surabaya, Indonesia.

<sup>3</sup>Division of Tropical and Infectious Diseases, Department of Internal Medicine, Faculty of Medicine Universitas Airlangga, Dr. Soetomo Hospital, Surabaya, Indonesia.

## **Corresponding Author:**

*Yetti Hernaningsih, MD, Clinical Pathologist (Consultant of Hematology), PhD. Department of Clinical Pathology, Faculty of Medicine Universitas Airlangga – Dr. Soetomo Hospital. Jl. Mayjen Prof. Dr. Moestopo No. 6-8, Surabaya 60285, Indonesia. Email: yetti-h@fk.unair.ac.id*

## **ABSTRACT**

*The COVID-19 pandemic has caused more than 4 million deaths worldwide to date. During the course of the COVID-19 pandemic, thrombotic complications due to hypercoagulable state have emerged as an important issue. Acute limb ischemia is one of emergency cases in vascular disease caused by a sudden decrease in arterial limbs perfusion. Here, we report a 53-year-old male patient with severe COVID-19 and a history of uncontrolled type 2 diabetes mellitus (T2DM) who developed extensive arterial thrombosis and limb ischemia despite being on therapeutic-dose anticoagulation, requiring surgical intervention. Right and left leg open thrombectomy was performed at day 7 after admission due to the excruciating pain and the worsening of the limb conditions. The patient was transferred to intensive care unit in emergency room because of the unstable hemodynamic and passed away a few hours after the surgery. For critically ill patients with COVID-19, special attention should be paid to abnormal coagulation dysfunction and microcirculatory disorders.*

**Keywords:** *acute limb ischemia, ALI, COVID-19, diabetes mellitus, hypercoagulable state.*

## **INTRODUCTION**

The respiratory disease from coronavirus disease 2019 (COVID-19) has caused over 230 million confirmed infections globally, including Indonesia, with over 4 million deaths as of September 2021.<sup>1</sup> Extra-pulmonary complications of COVID-19 are increasingly reported in the literature, including hypercoagulable state and thromboembolic events.<sup>2</sup>

Acute limb ischemia is one of emergency cases in vascular disease caused by a sudden decrease in arterial limbs perfusion. Patients with hypercoagulation state are at risk of

arterial thrombosis. The decision of surgical intervention must be determined quickly in patients with hypercoagulation state due to the clinical outcome. Many studies had shown an overall increase in mortality and amputation rate in hospitals.<sup>3</sup>

We described a case of acute limb ischemia due to arterial thrombosis associated with hypercoagulable state in a patient with COVID-19 pneumonia. The aim of this report is to report our first experience managing such case from a clinicopathological conference.

### CASE ILLUSTRATION

A 53-year-old male patient with past medical history of uncontrolled type 2 diabetes mellitus and hypertension came to Dr. Soetomo General Hospital in Surabaya, Indonesia during COVID-19 pandemic with shortness of breath and anosmia since 3 days before admission. Since 8 days before admission, he had experienced occasional dry cough and fever. Retroorbital pain, headache, and skin rash were absent. He had no problem with passing urine and bowel movement. There was history of close contact with his confirmed COVID-19 wife and son. History of COVID-19 vaccination was denied.

In the emergency room, he was alert. Temperature was 38°C, pulse 102 bpm, blood pressure 153/70 mmHg, respiratory rate 30 times/min, and pulse oximeter 86% saturation with 3 lpm nasal cannula supplemental oxygen. The chest, abdomen, and remainder of the physical examination was normal. He had a weight of 75 kg, height of 170 cm, and calculated body mass index (BMI) of 25.9%. Laboratory results revealed an elevated random blood glucose (294 mg/dL), elevated aspartate aminotransferase (89 U/L), elevated alanine aminotransferase (53 U/L), and elevated D-Dimer (1,094 ng/mL). Kidney function tests were normal (blood urea nitrogen 9 mg/dL and serum creatinine 0.71 mg/dL). The SARS-CoV-2 real time PCR examination showed positive results. Chest X-ray revealed bilateral pneumonia.

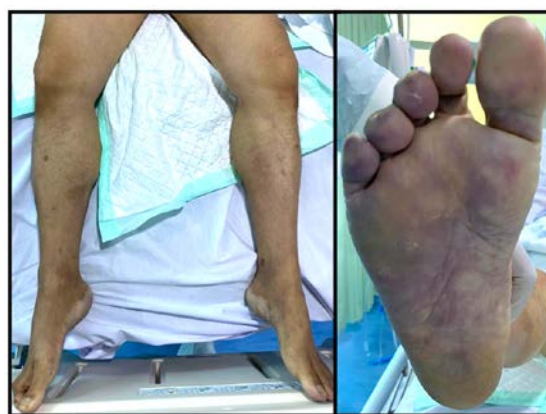The patient was transferred to the isolation ward (day 2 of treatment) for further evaluation and treatment. He was given intravenous fluid with NaCl 0.9%, oxygen supplementation 6 lpm, Remdesivir 200 mg i.v q.d, Lovenox 40mg s.c b.i.d, Novorapid 12 unit s.c t.i.d, Lantus 26 unit s.c q.d, Dexamethasone 6 mg i.v q.d, Amlodipine 5 mg p.o. q.d, N-acetylcysteine 600 mg p.o. b.i.d and Curcuma 20 mg p.o. b.i.d. On the second day in isolation ward (day 3 of treatment), laboratory results showed neutrophilia (74%), lymphocytopenia (16%), elevated D-Dimer (1,760 ng/mL), elevated random blood glucose (369 mg/dL), elevated HbA1c (12.3%), elevated CRP (14.5 mg/dL), and elevated Ferritin (5,346 ng/mL). Liver function tests remain abnormal. He also underwent plasma IL-6 level test and an

increase in IL-6 with a value of 11.04 pg/mL was found. Blood gas analysis showed a metabolic acidosis condition.

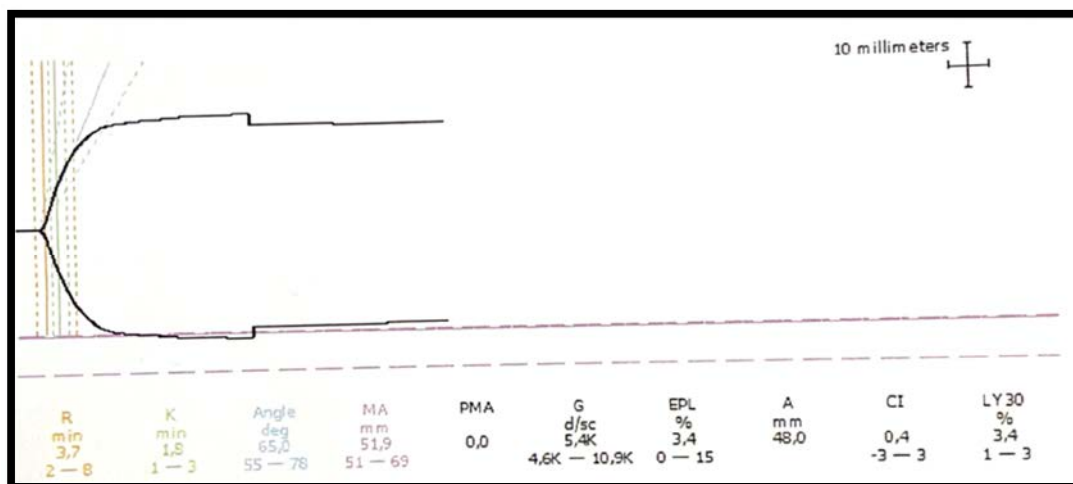
On the fourth day in isolation ward (day 5 of treatment), he developed bluish discoloration and worsening pain in both legs (**Figure 1**). His lower extremities were swollen and bluish in color, cold to the touch, and had a peripheral oxygen saturation of 75% (right foot) and 70% (left foot). The pulse of the right and left femoral artery, tibialis posterior artery, and dorsalis pedis artery were unpalpable bilaterally. He also still complained of difficulty breathing despite oxygen supplementation. Laboratory tests showed leukocytosis, with leukocyte value of 19,060 accompanied by increased Neutrophil Lymphocyte Ratio of 14.6 and elevated procalcitonin (3.78 ng/mL). Random blood glucose, liver function tests, and Ferritin remain high. D-Dimer was extremely elevated with D-Dimer value of 336,600 ng/mL.

Thromboelastography (TEG) assay was performed in this patient and the result showed increased coagulation activity, normal fibrinogen activity, normal platelet activity, and adequate fibrinolytic activity. TEG suggest hypercoagulability (enzymatic) factor (**Figure 2**).


He was consulted to the thoracic and vascular surgery department for thrombectomy. Preoperative doppler ultrasound was performed and showing thrombosis of left and right superficial femoral artery (**Figure 3**). Based on the examination, the patient was diagnosed with acute limb injury with modified Rutherford classification IIb. An emergency revascularization



**Figure 1.** Showed ischemia in the patient's limbs on September 1st, 2021



**Figure 2.** Thromboelastography (TEG) assay suggest a hypercoagulability (enzymatic) factor.



**Figure 3.** Doppler ultrasonography of left lower Limbs on September 1st, 2021 at Dr. Soetomo Hospital Surabaya indicated the presence of thrombus from left superficial femoral artery (filling >50% lumen).

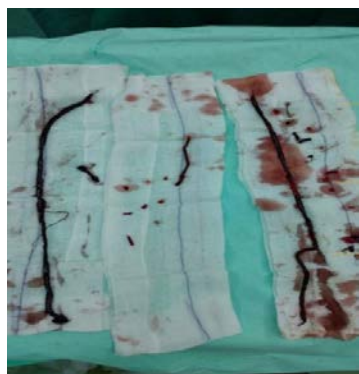
with open thrombectomy procedure was suggested. However, the procedure was delayed due to the concern of the patient and his family. Oxygen supplementation was changed to 30 lpm high flow nasal cannula, anticoagulant was changed to Heparin 5000 unit i.v. o.d and Heparin 24.000 unit i.v. q.d, antibiotic Cefoperazone Sulbactam 1 gram i.v. q.i.d was added.

On the fifth day in isolation ward (day 6 of treatment), he presented with hematuria. Laboratory results showed prolonged PT (26.8 seconds) and APTT (97.1 seconds). Heparin was stopped due to hematuria and the preparation of thrombectomy procedure. Chest x-ray showed bilateral pneumonia with decreased infiltrates.

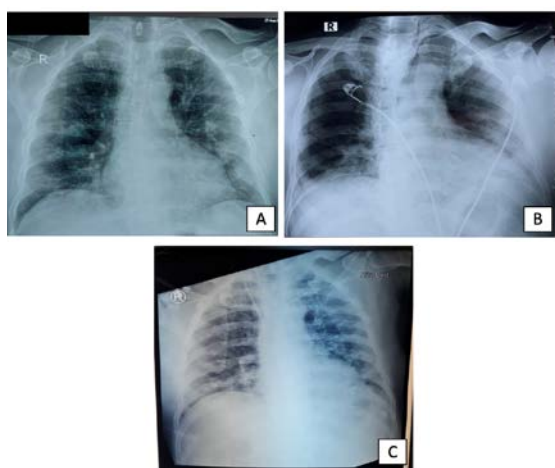
He underwent a thrombectomy on September 3rd, 2021. Preoperative laboratory results revealed a decrease in the value of PT (11.9 seconds), APTT (24.8) and D Dimer (23,990 ng/mL) compared to the previous day. Open thrombectomy procedure using Fogarty catheter was performed and thrombus of length 43 cm from the left leg and 40 cm from the right leg were removed (**Figure 4**). Post-operative evaluation was performed and the pulse of the right and left femoral artery, popliteal artery, tibialis posterior artery and dorsalis pedis artery were palpable bilaterally.

He was transferred to intensive care unit in emergency room after the procedure because of

unstable hemodynamics. He was still intubated and placed on a ventilator. Laboratory results revealed normochromic normocytic anemia (Hb 6.6 g/dL), leucocytosis (27.050/ $\mu$ L), thrombocytopenia (139,000/ $\mu$ L), hyperkalemia (6.5 mmol/L), hypocalcemia (8.1 mmol/L) and elevated lactic acid (9 mmol/L). Kidney function tests were abnormal (blood urea nitrogen 34 mg/dL and serum creatinine 1.7 mg/dL) and liver function tests were extremely elevated (aspartate aminotransferase 470 U/L alanine aminotransferase 783 U/L). Blood gas analysis showed worsening metabolic acidosis. Examination of serum ketones and urine ketones was not performed so that the possibility of diabetic ketoacidosis could not be ruled out.



**Figure 4.** Thrombus obtained from the total thrombectomy with a length of 40 cm and 43 cm (from right and left femoral artery respectively)



**Figure 5.** An overview of the development of chest x-ray during hospitalization from August 27, 2021 to September 3, 2021. A. Showed a bilateral pneumonia. B. Showed the improvement of patient's chest x-ray on September 2, 2021. C. Showed the worsening of patient's chest x-ray on September 3, 2021.

Chest x-ray showed bilateral pneumonia with increased infiltrates (The history of patient's chest x-ray results during hospitalization is shown in **Figure 5**). The patient passed away few hours after thrombectomy procedure.

## DISCUSSION

In this case, we presented an unusual case of COVID-19 infection with an initial stable period and a rapid deterioration leading to ICU admission, and eventual demise due to extensive arterial thrombosis. As described by recent studies, patients with COVID-19 have an increased risk of both venous and arterial thrombotic events.<sup>4,5</sup> The pathophysiology is complex and not yet fully understood.

Previous study mentioned the symptoms of acute limb ischemia are as following: pain, numbness, paresthesia, coldness, and irreversible purpura at extremities.<sup>6</sup> In this case, the patient showed clinical symptoms in the form of pain, paresthesia and bluish rash accompanied by legs that were cold to touch.

Several studies indicate that severe COVID-19 infections are associated with higher D-dimer levels, reflecting a more pronounced hypercoagulable state.<sup>7,8</sup> In this case, the patient had an increased level of D-dimer (336,600 ng/mL). The thromboelastography assay results confirmed the hypercoagulable state in this patient. Based on the clinical conditions, it can be presumed that the hypercoagulation state with clinical ischemia in this patient signified severe illness and required close monitoring and appropriate early intervention management.

SARS-CoV-2 directly attacks vascular endothelial cells and activates the coagulation cascade after causing endothelial injury. This pathologic insult is suggested to result in excessive cytokine release and storm from activating of widespread coagulation factors while inhibiting fibrinolysis causing extensive thrombosis similar to disseminated intravascular coagulation. IL-6 is a key factor in SARS-CoV-2 induced inflammatory storm. While IL-6 can stimulate the liver to synthesize fibrinogen and thrombopoietin, it also upregulates the expression of vascular endothelial growth factor to disrupt the stability of vascular barrier and

stimulate monocytes to express more tissue factors, thereby activating the extrinsic pathway of coagulation.<sup>9</sup> These coagulation abnormalities along with elevated D-dimers are likely indicators for higher mortality predisposing the patients to a variety of ischemic and thrombotic events.<sup>8</sup>

This patient had the history of uncontrolled type 2 diabetes mellitus. During hospitalization there was elevated random blood glucose (470 mg/dL) and HbA1c (12.3%). A study by Calvisi et al. showed diabetes, hyperglycemia and glycemic variability were strong risk factors for the development of thromboembolic complications in COVID-19 patients. Diabetes was associated with both inflammation and coagulopathy (elevated C reactive protein and D-dimer levels, mild prolongation of the prothrombin time and decreased antithrombin III), suggesting that a hyperglycaemia-related amplification of the pathobiological mechanisms of immunothrombosis could be responsible of the increased thrombotic risk.<sup>10</sup> COVID-19 is a disease that can trigger hypercoagulable conditions, so that it can increase the incidence of ALI in patients with a history of T2DM. Viral infiltration causes a process of cell disruption, leading to a disseminated intravascular coagulopathy (DIC)-like clinical feature, in which D-dimer breakdown products and fibrin/fibrinogen are significantly increased, and microvascular microthrombi are formed.<sup>11</sup>

In this case, the patient underwent thrombectomy. Thrombectomy was indicated in accordance to this patient stage being Rutherford stage IIB.<sup>12</sup> According to the guideline, grade IIB ALI should undergo an emergency revascularization procedure within 6 h after the diagnosis has been made.<sup>13</sup> Unfortunately, the procedure was delayed due to the concern of the patient and his family. Prolonged ischemia can cause muscle cell liquefactive necrosis and K<sup>+</sup> ion, myoglobin, creatine kinase, lactic acid, and superoxide accumulation in the affected limb. These metabolites perfuse throughout the body upon revascularization and cause hyperkalemia, arrhythmia, pulmonary edema, metabolic acidosis, and myoglobinuria, and in severe cases, it can cause sudden death from

heart and renal failure. The so-called ischemia-reperfusion injury is a severe complication that determines prognosis after the revascularization of ALI.<sup>6</sup> This ischemia-reperfusion injury could be the cause of death in this patient as we found hyperkalemia, worsening metabolic acidosis, elevated kidney test results, and elevated lactic acid after the thrombectomy procedure.

Open surgical techniques have been preferred because time to reperfusion is rapid especially when faced with class IIB ALI. Early operative intervention, however, result in considerable risk of perioperative mortality. Despite advances in resuscitative care, reports state mortality rates as high as 20% in patients undergoing operative revascularization for ALI.<sup>14</sup> A combined approach of mechanical and pharmacologic catheter-based techniques are becoming more prevalent as an alternative to more invasive and open surgical approaches that typically incur a higher morbidity and mortality, especially in patients with comorbidities.<sup>13</sup> Studies showed that intraoperative hyperglycemia will result in postoperative infections, cardiovascular and cerebrovascular accident, cognitive dysfunction, and other poor outcomes in diabetic patients. Effective glycemic management in patients with diabetes can improve their surgical outcomes.<sup>15</sup>

Several studies suggested that elevated aminotransferases is associated with higher mortality in COVID-19.<sup>16,17</sup> Multiple hypotheses such as direct viral cytotoxicity through ACE-2, drug-induced liver injury, immune-mediated damage, and passive congestion have been proposed.<sup>18</sup> The liver function tests of this patient were high upon the admission and got extremely elevated after the thrombectomy procedure. Systemic organ ischemia and hypoxia would occur in diabetic patients due to microvascular disorder. Related research shows that severe hypoxia results in increased metabolic activity of transaminases and bilirubin metabolism disorders in the hepatocytes, and even liver necrosis.<sup>19</sup> Operative blood loss, ischemia, and stress will aggravate the state of systemic organ ischemia and may be the reason for the further transaminase increase in the diabetic patients postoperatively.

## CONCLUSION

ALI accompanied with COVID-19 and type 2 Diabetes mellitus is a complex case. It requires comprehensive COVID-19 treatment, good management of glycemic control and immediate salvage limb treatment. The ischemia–reperfusion injury can be a cause of death in COVID-19 patients with limb ischemia undergoing thrombectomy. The prognosis for ALI with COVID-19 and T2DM is worse than in other patients and most cases ended with death. Further studies is needed to establish the optimal management of ALI with COVID-19 and T2DM.

## REFERENCES

1. John Hopkins University and Medicine. Johns Hopkins Coronavirus Resource Center - COVID-19 data in motion [Internet]. 2021. Available from: <https://coronavirus.jhu.edu/covid-19-daily-video%0Ahttps://coronavirus.jhu.edu/>
2. Levi M, Thachil J, Iba T, Levy JH. Coagulation abnormalities and thrombosis in patients with COVID-19. *Lancet Haematol*. 2020;7(6):e438–40.
3. Aboyans V, Ricco JB, Bartelink MLEL, et al. 2017 ESC guidelines on the diagnosis and treatment of peripheral arterial diseases, in collaboration with the European Society for Vascular Surgery (ESVS). *Eur Heart J*. 2018;39(9):763–816.
4. Nowroozpoor A, Bank MA, Jafari D. Limb ischemia due to extensive arterial thrombosis in the absence of venous occlusion as an unusual complication of critical illness from COVID-19. *Case Reports Acute Med*. 2021;4(1):23–31.
5. Dias LM, Martins J, Castro R, Mesquita A. Multiple arterial thrombosis in a patient with COVID-19. *BMJ Case Rep*. 2021;14(6):2–3.
6. McNally MM, Univers J. Acute limb ischemia. *Surg Clin North Am*. 2018;98(5):1081–96.
7. Yu HH, Qin C, Chen M, Wang W, Tian DS. D-dimer level is associated with the severity of COVID-19. *Thromb Res* [Internet]. 2020;195(April):219–25. Available from: <https://doi.org/10.1016/j.thromres.2020.07.047>
8. Zhou F, Yu T, Du R, et al. Clinical course and risk factors for mortality of adult inpatients with COVID-19 in Wuhan, China: a retrospective cohort study. *Lancet*. 2020;395(10229):1054–62. Available from: [http://dx.doi.org/10.1016/S0140-6736\(20\)30566-3](http://dx.doi.org/10.1016/S0140-6736(20)30566-3)
9. Zhou Y, Fu B, Zheng X, Wang D, Zhao C. Severe pulmonary syndrome patients of a new Coronavirus. *bioRxiv Prepr*. 2020;(February). Available from: <https://doi.org/10.1101/2020.02.12.945576>
10. Calvisi SL, Ramirez GA, Scavini M, et al. Thromboembolism risk is higher among patients with diabetes and COVID-19 and is associated to poor clinical outcome. *medRxiv*. 2021;2021.04.17.21255540. Available from: <http://medrxiv.org/content/early/2021/04/20/2021.04.17.21255540.abstract>
11. Kichloo A, Dettloff K, Aljadah M, et al. COVID-19 and hypercoagulability: A review. *Clin Appl Thromb*. 2020;26.
12. Olinic D-M, Stanek A, Tătaru D-A, Homorodean C, Olinic M. Acute limb ischemia: An update on diagnosis and management. *J Clin Med*. 2019;8(8):1215.
13. Björck M, Earnshaw JJ, Acosta S, et al. Editor's choice – European Society for Vascular Surgery (ESVS) 2020 Clinical practice guidelines on the management of acute limb ischaemia. *Eur J Vasc Endovasc Surg*. 2020;59(2):173–218. Available from: <https://doi.org/10.1016/j.ejvs.2019.09.006>
14. Lind B, Morcos O, Ferral H, et al. Endovascular strategies in the management of acute limb ischemia. *Vasc Spec Int*. 2019;35(1):4–9.
15. Wang J, Chen K, Li X, et al. Postoperative adverse events in patients with diabetes undergoing orthopedic and general surgery. *Med (United States)*. 2019;98(14):1–7.
16. Pozzobon FM, Perazzo H, Bozza FA, Rodrigues RS, de Mello Perez R, Chindamo MC. Liver injury predicts overall mortality in severe COVID-19: a prospective multicenter study in Brazil. *Hepatol Int*. 2021;15(2):493–501. Available from: <https://doi.org/10.1007/s12072-021-10141-6>
17. Taramasso L, Vena A, Bovis F, et al. Higher mortality and intensive care unit admissions in COVID-19 patients with liver enzyme elevations. *Microorganisms*. 2020;8(12):1–12.
18. Boregowda U, Aloysius MM, Perisetti A, Gajendran M, Bansal P, Goyal H. Serum activity of liver enzymes is associated with higher mortality in COVID-19: A systematic review and meta-analysis. *Front Med*. 2020;7(July):1–10.
19. Wang T, Fontenot RD, Soni MG, Bucci TJ, Mehendale HM. Enhanced hepatotoxicity and toxic outcome of thioacetamide in streptozotocin-induced diabetic rats. *Toxicol Appl Pharmacol*. 2000;166(2):92–100.