

Platelet-rich fibrin (PRF) graft and amniotic membrane graft on transforming growth factor- β (TGF- β) and type 1 collagen post conjunctival excision

by Paulus Budiono Notopuro

Submission date: 20-Jun-2023 05:08AM (UTC+0500)

Submission ID: 2119341145

File name: 129_-_3733_-_Evelyn_Komaratih_-_Galley.pdf (715.21K)

Word count: 5285

Character count: 28183

¹Resident of Department of Ophthalmology, Faculty of Medicine, Universitas Airlangga, Dr. Soetomo General Hospital, Surabaya, Indonesia;

²Staff of Department of Ophthalmology, Faculty of Medicine, Universitas Airlangga, Dr. Soetomo General Hospital, Surabaya, Indonesia;

³Staff of Department of Anatomical Pathology, Faculty of Veterinary Medicine, Universitas Airlangga, Dr. Soetomo General Hospital, Surabaya, Indonesia;

⁴Staff of Department of Clinical Pathology, Faculty of Medicine, Universitas Airlangga, Dr. Soetomo General Hospital, Surabaya, Indonesia;

⁵Staff of Department of Epidemiology, Biostatistics, population study and Health Promotion, Faculty of Public Health, Universitas Airlangga, Dr. Soetomo General Hospital, Surabaya, Indonesia;

*Corresponding author:

Evelyn Komaratih;
Ophthalmology Department, Dr. Soetomo General Hospital, Faculty of Medicine, Universitas Airlangga, Surabaya, Indonesia;
risetpublikasi@gmail.com

Received: 2022-09-23

Accepted: 2022-10-30

Published: 2022-11-28

Platelet-rich fibrin (PRF) graft and amniotic membrane graft on transforming growth factor- β (TGF- β) and type 1 collagen post conjunctival excision

Abdi Roy Nababan¹, Daniar Indah Suryowati¹, Evelyn Komaratih^{2*}, Yulia Primitasari², Djoko Legowo³, Paulus Budiono Notopuro⁴, Hari Basuki Notobroto⁵



ABSTRACT

Background: Conjunctiva, when injured, can heal spontaneously. However, in extensive wounds, wound healing is often accompanied by scarring and wound contraction. Currently, for cases of disease and trauma to the surface of the eyeball, it can be reconstructed using the amniotic membrane, but there are still weaknesses in the use of amnion. Platelet-rich fibrin (PRF) is currently being developed for the reconstruction of ocular surface wounds.

Methods: A total of 20 male New Zealand rabbits (20 eyes) were divided into two groups. In the first group, conjunctival excision and PRF membrane graft suturing were performed on the right eye conjunctival defect, while the second group had an amniotic membrane sutured on the right eye conjunctival defect. On the 14th day, enucleation was carried out and continued with histopathological examination using immunohistochemistry using TGF antibodies and type 1 collagen to evaluate the levels of TGF and type 1 collagen in the conjunctiva.

Results: The results after 14 days of treatment showed that there was a very significant difference in TGF Beta expression between the AMT group and the PRF group ($p = 0.007^*$; <0.05). However, in the expression of type 1 collagen, there was no significant difference in the expression of type 1 collagen between the AMT group and the PRF group ($p = 0.791$; >0.05).

Conclusion: There were differences in the expression of TGF- β and type 1 collagen in the administration of the PRF membrane compared to the administration of the amniotic membrane after conjunctival excision of experimental male New Zealand rabbits on day 14.

Keywords: amniotic membrane, collagen type 1, conjunctiva, PRF, TGF.

Cite This Article: Nababan, A.R., Suryowati, D.I., Komaratih, E., Primitasari, Y., Legowo, D., Notopuro, P.B., Notobroto, H.B. 2022. Platelet-rich fibrin (PRF) graft and amniotic membrane graft on transforming growth factor- β (TGF- β) and type 1 collagen post conjunctival excision. *Bali Medical Journal* 11(3): 1744-1750. DOI: 10.15562/bmj.v11i3.3733

INTRODUCTION

The conjunctiva can heal spontaneously if it is injured. However, in extensive wounds, wound healing is often accompanied by scarring and wound contraction, which can cause trichiasis, entropion, lagophthalmos, siltation of the fornix, and symblepharon, which can disrupt the integrity of the tear film and ocular surface, which in turn can lead to blindness due to clouding of the cornea.¹⁻³ The Wound healing process consists of several phases: homeostasis, inflammation, proliferation, and remodeling.⁴ Josset found that there are about 7,000 serious chemical splash injuries in France per year.⁵ From the data of patients who underwent pterygium excision in Taiwan from 2000 to 2014,

it was found that from 1787 pterygium cases, 928 were male and 859 female. Of these 1787 cases, 1435 (80.3%) cases underwent primary pterygium excision, while the others (19.7%) underwent secondary pterygium excision. 12% of patients who underwent secondary pterygium excision had a recurrence and required another operation.⁶ Several techniques have been developed to reconstruct the conjunctiva, such as conjunctival autograft and transplantation with amniotic membrane and mucous membrane. The ideal conjunctival replacement biomaterial should be stable, thin, tolerable, and consist of a matrix that carries a donor layer of epithelium, especially if there is a conjunctival stem cell deficiency. Amniotic membrane

transplantation (AMT) is a biomaterial that is often used for conjunctival reconstruction. AMT is mainly used for ocular surface reconstruction, accelerates epithelialization, relieves patient complaints, and reduces inflammation.^{1,7}

Platelet-rich fibrin membrane (PRF) is a second-generation platelet concentrate developed by Choukroun *et al.* from France, which is widely used in oral and maxillofacial, plastic surgery, orthopedic and ophthalmic surgery.⁸ The PRF membrane has a mechanical function as a framework for cell proliferation, differentiation, and migration that is important for tissue regeneration. The PRF membrane also contains many growth factors that are important in the wound healing process, such as transforming

growth factor (TGF- β), platelet-derived growth factors (PDGF), and vascular endothelial growth factor (VEGF), which are released gradually over 7 to 28 days.^{9,7} The combination of the mechanical and chemotactic functions of the PRF membrane makes it a good autologous biomaterial for tissue reconstruction. In the eye field, especially in the conjunctiva, the PRF membrane also helps the wound-healing process and conjunctival regeneration. This is following the Can *et al.* study on the use of PRF membranes for conjunctivoplasty in rabbit conjunctiva and a 2017 clinical study by Cakmak *et al.* in patients after pterygium excision. Because there are still few studies of PRF membranes in the eye field, and there are no studies that examine the effect of giving PRF membrane grafts compared to amniotic membrane administration on the expression of TGF and collagen type 1 in experimental rabbit animals. The aim of this study was to know the effect of platelet graft on rich fibrin (PRF) and amniotic membrane to an expression of TGF and type 1 collagen after conjunctival excision.^{10,11}

METHODS

Study design and sample collection

This study is a true experimental laboratory study with a randomized post-test-only design to evaluate differences in TGF Beta expression and the amount of type 1 collagen in adult New Zealand white rabbits (*Oryctolagus cuniculus*) after conjunctival excision and suturing of PRF membrane grafts and amniotic membranes in the laboratory.

The inclusion criteria of this study included adult New Zealand white rabbits aged 4-10 months with a body weight of 3000-3500 grams with healthy eyes and body conditions, with fibrinogen levels of 1.66 ± 0.39 g/L and blood levels of 1.66 ± 0.39 g/L. Platelets in the range of $390 - 821 \times 10^9$ /L. Meanwhile, the exclusion criteria for this study include animals that are declared by a veterinarian to have a disease or have the potential to transmit the disease during the study. Dropout criteria The tests of this study were sick rabbits, death, complications such as scleral perforation, vitreous prolapse, infection, and bleeding during and after

surgery. The independent variables in this study were the PRF membrane and the amniotic membrane, while the dependent variable in this study was the expression of TGF- β and type 1 collagen.

20 male New Zealand rabbits (20 eyes) that met the inclusion criteria were examined for the anterior segment using a handheld slit-lamp. The rabbits were divided into two groups of 10 each group. In group 1, 10 animals with conjunctival defects were closed with a PRF membrane graft made from rabbit whole blood samples, while in group 2, the amniotic membrane was sutured to close the defect. The left eye was not treated. Initially, the rabbit was anesthetized using an injection of ketamine 50 mg/kg and xylazine at a dose of 5 mg/kg mixed with 0.5 mL of balanced saline (BSS) into the subconjunctival area where excision of the bulbar conjunctiva on the temporal side with a size of 5×5 mm was made. Square and Tenon's tissue was cut with Westcott scissors at a distance of 3 mm from the limbus in the temporal interpalpebral bulbar conjunctiva. On the fourteenth day after surgery, all rabbits were enucleated under general anesthesia and IHC examination.

Preparation of amniotic membrane

Amniotic membranes were taken from pregnant women with informed consent and disease screening to donate the placenta.¹² The Placenta received from the maternity hospital is placed in a suitable container and then processed under sterile conditions. The placenta is washed with saline and antibiotics. The amniotic membrane is bluntly separated from the placenta and flattened. The upper surface of the epithelium (mesenchymal side below) is laid on a sheet of nitrocellulose paper. The human amniotic membrane was cut into several pieces of individually defined size in a sterile vial with the selected preservative medium and stored. There are 4 stages of preparing the amniotic membrane: isolation, cryopreservation, thawing, and culture.¹³⁻¹⁷

Preparation of platelet-rich fibrin

PRF membrane was made using blood from rabbit auricular vein as much as ± 10 cc, which was then stored in a glass tube without anticoagulant. After that, the

blood sample was immediately centrifuged at 2700 rpm for 12 minutes using a table centrifuge system (Choukroon protocol). From the results of the centrifuge, 3 layers will be formed, namely acellular plasma as the supernatant at the top, PRF clots in the middle, and red blood cells at the bottom. After the centrifugation process, the blood clot is removed from the tube, then the red blood cell portion at the bottom of the clot is separated. The PRF clot is then made into a membrane by compressing it using a PRF box.^{10,18}

On the 14th day, the eyeball was enucleated, then post-excision conjunctival tissue was performed immunohistochemical examination using anti-TGF- β and Collagen type 1 antibody. The enucleated rabbit eyes in each group were fixed in 10% buffered and 10% formalin to prevent tissue autolysis and decay for 24 h at room temperature and embedded in paraffin. The next process is post-excision conjunctival tissue that has been isolated and then fixed in a 10% neutral buffered formalin (NBF) solution for 48 hours at room temperature. The fixed tissue is 20 mm x 30 mm with a thickness of 2-4 mm, where every 100 mg of tissue is given 2 ml of formalin so that the fixation process is effective. After the paraffin block process was carried out, the total expression of TGF- β and Collagen type 1 was examined by histopathological examination.¹⁰

All data in this examination were obtained at 400x and 1000x magnification, using a light microscope (Nikon H600L microscope; 300 megapixels DS Fi2 camera) by one pathologist to analyze the TGF β and type 1 collagen cells. Histopathological examination to determine the expression of TGF- β and type 1 collagen in the conjunctiva healing area. In order to reduce bias, this technique was carried out by one pathologist on serial numbered slides in a blinded manner. The TGF- β expression score and type 1 collagen were obtained according to the modified Remmele method where the Remmele scale index (Immuno Reactive Score/IRS) is the result of multiplying the percentage score of cells or areas that are immunoreactive positive and the color intensity score of immunoreactive cells. The data for each sample is the average IRS

value observed in 5 (five) Fields of View (LP) at 400x magnification.¹⁹

Statistical analysis

Data on the percentage and expression of TGF- β and type 1 collagen have been collected, analyzed, and tested using the Kolgomorov test. Obtained data that is not normally distributed and then tested using the Mann-Whitney U test analysis test with $\alpha = 0.05$. The collected data was analyzed using SPSS version 18 (IBM corporation, New York, NY, U.S.A).

RESULTS

Research Sample Characteristics

20 male New Zealand rabbits (20 eyes) that met the inclusion criteria were examined for the anterior segment using a handheld slit-lamp. The rabbits were divided into two groups of 10 each. In group 1, as many as 10 rabbits with the right eye conjunctival defect were closed with a PRF membrane graft made from the rabbit's own whole blood sample, while in group 2, the amniotic membrane suturing procedure was performed to close the conjunctival defect in the right eye.

Before surgery, all rabbits were taken for ± 10 cc of blood, 5 cc for blood platelet

count, and another 5 cc for a fibrinogen blood examination. Based on Table 1 obtained from an examination of the amount of fibrinogen, shows that the average amount of fibrinogen is 330.18mg/dL with a coefficient of variation of 65.24%, and the data is normally distributed ($\alpha > 0.05$).

The number of replications is estimated by using the Lemeshow calculation formula found that the replication of $n = 7$. In this study, with a dropout factor of 30%, the amount of replication we used was 10. On examination using a handheld slit-lamp, it was found that in the PRF group, the Vicryl suture was not visible on the seventh day. There is a smooth, non-jagged transition between the edge of the PRF membrane and the surrounding conjunctiva. In addition, neovascularization across the PRF membrane was also found. Meanwhile, on day 14, both groups showed fine tissue with vascularity in the defect area that almost resembled the surrounding conjunctival tissue (Figure 1). During the observation period, there were no secondary infections, scleral necrosis, symblepharon, or any form of conjunctival or palpebral fornix retraction.

Effect of PRF graft and amniotic membrane on TGF- β expression

TGF beta expression was indicated by the brown color of the chromogen in the visual field, which appeared weak on the PRF B membrane (1000x magnification) compared to other treatments (Figure 2). Table 2 shows that the AMT group has a median value of TGF expression of 10.80 with an IQD of 0.6, while in the PRF group, the median value of TGF expression is 8.80 with an IQD of 0.85. In the Mann-Whitney U-Test statistical test, it was found that there was a significant difference in TGF Beta expression between the AMT group and the PRF group ($p = 0.007^*$; $\alpha < 0.05$).

Table 2 shows that the expression of TGF from the number of expressing cells had a median of 10.80 in the AMT group with an IQD of 0.6, while in the PRF group, the median value was 8.80 with an IQD of 0.85 (Figure 3). The Mann-Whitney U-Test statistical test showed that there was a very significant difference in TGF Beta expression between the AMT group and the PRF group ($p = 0.0035^*$; $\alpha < 0.05$).

Effect of PRF graft and amniotic membrane on Type 1 Collagen expression

In the wound-healing process, collagen in the tissue is produced by fibroblasts. Fibroblasts in synthesizing collagen require various growth factors, cytokines, and chemokines which are produced by fibroblasts, keratinocytes, endothelial cells, and inflammatory cells, among others.²⁰ Type I collagen expression was carried out by immunohistochemical examination using monoclonal antibodies against type I collagen. Type I collagen expression was seen between fibroblast cells, and chromogen-brown color appeared to be found in the intercellular spaces in the healing area. In this histopathological examination, the expression of type 1 collagen in the conjunctival healing area can be observed, where the expression of type 1 collagen in the PRF B membrane is slightly higher than in the amniotic membrane (Figure 4).

Table 3 shows that the number of cells expressing type 1 Collagen has a median of 8.20 in the AMT group with an IQD of 1.35. In the PRF group, the median value

Table 1. Distribution of rabbit platelet count and fibrinogen.

| Variable | Result | | | | |
|------------|--------|---------|---------------|---------|---------|
| | n | Mean | Std Deviation | Minimum | Maximum |
| Platelet | 20 | 323.45 | 62.94 | 200 | 437.00 |
| Fibrinogen | 20 | 330.185 | 215.41 | 60 | 990.80 |

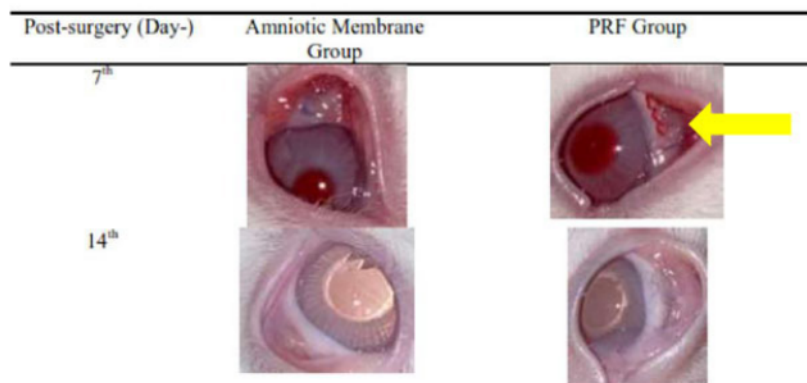


Figure 1. Examination of post-excision conjunctival defects on days 7 and 14. In the PRF group (arrows), the vicryl sutures were no longer visible on the seventh day, and there was a smooth transition between the PRF membrane and the surrounding conjunctiva.

was 8.80, with an IQD of 1.35.

The Mann-Whitney U-Test statistical test showed that there was no significant difference in the expression of type 1 collagen between the AMT group and the PRF group ($p = 0.395; > 0.05$). Examination of type 1 collagen expression using a Nikon H600L light microscope equipped with a 300-megapixel DS Fi2 digital camera and image processing software Nikon Image System (Figure 5).

DISCUSSION

In our study on the 14th day of the conjunctiva, it was found that TGF beta expression was less in the PRF membrane

than in the amnion membrane. This was due to inflammation in the amniotic membrane group. This was evidenced by the presence of various types of acute inflammatory cells (PMN) and chronic (macrophages). Empirically, TGF beta releases many cytokines that produce inflammatory cells ranging from PMNs to macrophages. In the PRF membrane epithelium, TGF beta expression was weaker than in the amniotic membrane. The presence of various kinds of inflammatory cells in the amniotic membrane causes more TGF beta expression to be released on the amniotic membrane. This indicates that the maturation of inflammatory cells at the cellular level that occurs in the PRF

membrane is faster than in the amnion membrane.^{20,21}

On examination of the various slides that we examined, we still found $\pm 50\%$ of the remaining implant (scaffold), such as threads and other materials on the amniotic membrane, that had not been absorbed. Many scaffolds, such as threads that have not been absorbed, can cause a rejection reaction in the form of inflammation which causes inflammatory cells to appear, which results in the release of TGF beta expression, which causes higher TGF beta expression in the amniotic membrane. Inflammation can also occur due to hematogenous processes or the process of cutting tissue (from the area around the conjunctiva). On examination of the various slides that we examined, we still found $\pm 50\%$ of the remaining implant (scaffold), such as threads and other materials on the amniotic membrane, that had not been absorbed. Many scaffolds, such as threads that have not been absorbed, can cause a rejection reaction in the form of inflammation which causes inflammatory cells to appear, which results in the release of TGF beta expression, which causes higher TGF beta expression in the amniotic membrane. Inflammation can also occur due to hematogenous processes or the process of cutting tissue (from the area around the conjunctiva).²²

In the study of Nakamura *et al.* in 2003 on 8 rabbits, it was found that within 3 weeks of ocular surface injury, corneal conjunctivalization in eight rabbits was reconstructed by transplantation of autologous corneal epithelial cells released into the amniotic membrane. Corneal epithelial cells begin to form upon the use of the amniotic membrane within 3 days. By day 7, corneal epithelial cells had grown under the amniotic membrane. At 3 to 4 weeks after the conjunctival defect, the conjunctival epithelium completely covered the damaged corneal surface in the eight albino rabbits with considerable neovascularization and subconjunctival inflammation. At 3 weeks, the corneal epithelial cells have formed four to five layers and are well differentiated.²³

A study conducted by Zhou *et al.* and Hsu *et al.* both studied conjunctival reconstruction after conjunctival excision in rabbit eyes. Both studies assessed

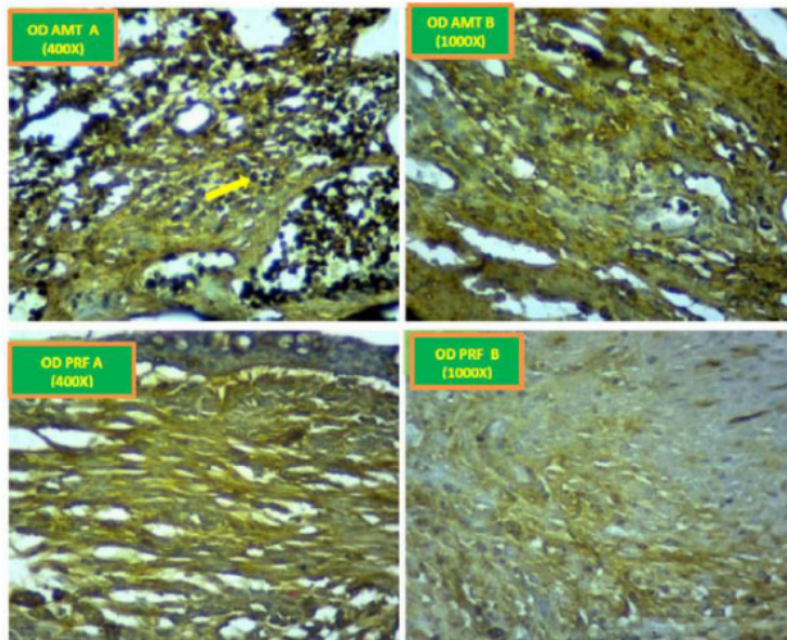


Figure 2. Comparison of TGF beta expression among treatment groups. OD AMT A: TGF beta expression at 400x magnification AMT; OD AMT B: TGF beta expression at 1000x magnification AMT; OD PRF A: TGF beta expression at 400x magnification PRF; OD PRF B: TGF beta expression at 1000x magnification PRF. TGF beta expression was indicated by the brown color of the chromogen, which appeared weak in the ODPRF B treatment compared to other treatments (immunohistochemical staining, 400x magnification; 1000x inlet; Nikon H600L microscope; 300 megapixels DS Fi2 camera).

Table 2. Distribution of TGF- β expression.

| | n | Median | Interquartile Deviation | Minimum | Maximum | p |
|--------|---|--------|-------------------------|---------|---------|--------|
| OD AM | 9 | 10.80 | 0.60 | 9.6 | 11.4 | 0.007* |
| OD PRF | 9 | 8.80 | 0.85 | 7.8 | 11.4 | |

Note: ** (significance = 0.007, < 0.05); SD: standard deviation; IQD: interquartile deviation

the presence of conjunctival scarring through the shortening of the fornices and deposition of collagen. In a study conducted by Hsu *et al.* using collagen-glycosaminoglycan implants as graft material, it showed that on the 14th postoperative day, the shortening of the fornices in the control group (without graft) ($23.3\% \pm 3.3\%$) was greater than in the treatment group ($6.9\% \pm 2.4\%$).²⁴ Meanwhile, research by Zhou *et al.* concluded that there was a significant inhibition of fornix shortening in the treatment group with vitrified collagen-based conjunctiva grafts.²⁵ In a study by Huang *et al.*, it was found that conjunctival scar tissue appeared on day 7 in the control group (without graft), while in the treatment group with amniotic membranes, it appeared on day 14. Fibroblast cells that produce collagen found > 95% on day 14 in the control group are larger than the amniotic membrane treatment group (69.6%).³

According to Sari *et al.* research in 2019, which examined the effect of biological membranes on fibroblast proliferation between Platelet-rich fibrin and the amniotic membrane, it was found that

PRF is a membrane that causes fibroblast proliferation to be higher than that of the amnion in the first 24 hours, but after that, there was no difference with significant between the two groups. From this study, it can be concluded that the PRF membrane and amniotic membrane can accelerate fibroblast proliferation but have different effects at the time of induction.²²

In the Can *et al.* study, which investigated the effect of PRF membrane on rabbit eye conjunctivoplasty, PRF membrane affected conjunctival wound healing due to its anatomical and physiological structure. In the early phase of wound healing, the PRF membrane releases a greater amount of growth factor than in normal conjunctival wound healing. However, growth factor expression started to disappear on the 7th postoperative day when the PRF membrane started to degrade. PRF membranes can also prevent scarring by modulating fibroblast activation by modifying TGF- β expression and suppressing its overexpression.¹⁰

On day 14 of our study, PRF membranes and amniotic membranes could express TGF- and type 1 collagen. We found that TGF- β expression in the

AMT group was better than that in the PRF group. As for the expression of type 1 collagen, the expression of type 1 collagen in the PRF group was better than in the AMT group. This follows the study of Sari *et al.*, where the PRF membrane can cause a higher proliferation of fibroblasts than the amnion, where the speed of induction distinguishes the two.²² In Can *et al.* study also proved that the PRF membrane modulates the expression of TGF and suppresses its overexpression.¹⁰ However, in our study, we found a better expression of TGF in the amniotic membrane group, which could be due to the suppression of fibroblast differentiation into myofibroblasts.

The results of this study on the effect of PRF membrane on the inflammatory process after conjunctival excision in experimental rabbit animals can be used as a basis for the application of PRF membrane as an alternative biomaterial for ocular surface reconstruction, especially the conjunctiva. In addition, it also opens up opportunities for the development of further research on PRF membranes in the field of ophthalmology.

This study has several limitations, including the observation period. This study was not carried out serially and on day 14 only, so it could not compare the expression of TGF beta and type 1 collagen on the PRF membrane and amniotic membrane according to the wound healing phase. In wound healing, many other variables play a role in the conjunctival wound healing process. Based on the results of this study, so that the results obtained can be better, it is recommended that further research be carried out with a longer research period and serially (3rd, 7th, 21st, 28th, to 3rd month). In addition, it is also necessary to examine other parameters, such as the shortening of the fornices and the number of inflammatory cells, so that they can evaluate the effectiveness of the PRF membrane in each phase of conjunctival wound healing.

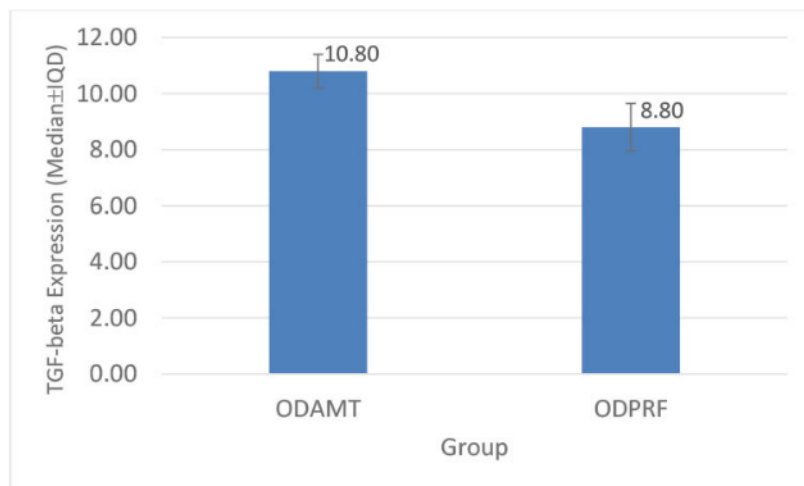


Figure 3. Comparison chart Median TGF Beta percentage expression on AMT and PRF groups.

Table 3. Expression distribution of type 1 collagen.

| | n | Median | IQD | Min. | Maks. | P |
|-------|---|--------|------|------|-------|-------|
| ODAMT | 9 | 8.20 | 1.35 | 5.2 | 10.6 | 0.791 |
| ODPRF | 9 | 8.80 | 1.35 | 5.0 | 10.8 | |

Note: (significance = 0.791, > 0.05); SD: standard deviation; IQD: interquartile deviation

CONCLUSIONS

There were differences in the expression of TGF- β and type 1 collagen in the administration of PRF membranes compared to the administration of

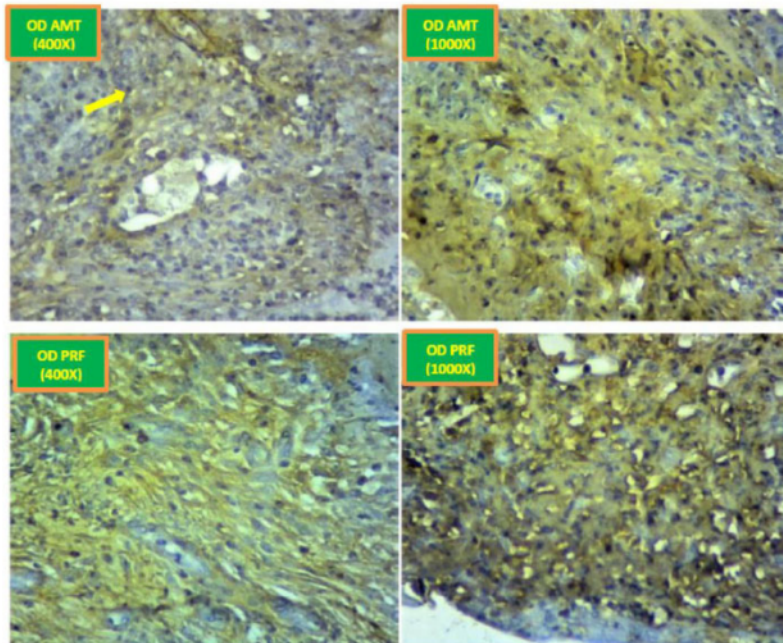


Figure 4. Comparison of Type 1 Collagen Expression among the treatment groups. OD AMT A: Collagen type 1 expression at 400x magnification AMT; OD AMT B: expression of collagen type 1 at 1000x magnification AMT; OD PRF A: expression of type 1 collagen at 400x magnification PRF; OD PRF B: expression of type 1 collagen at 1000x magnification PRF. Collagen type 1 expression was marked by brown chromogen that appeared to be found in the intercellular space in the healing area (immunohistochemical staining, 400x magnification; 1000x inlet; Nikon H600L microscope; 300 megapixels DS Fi2 camera).

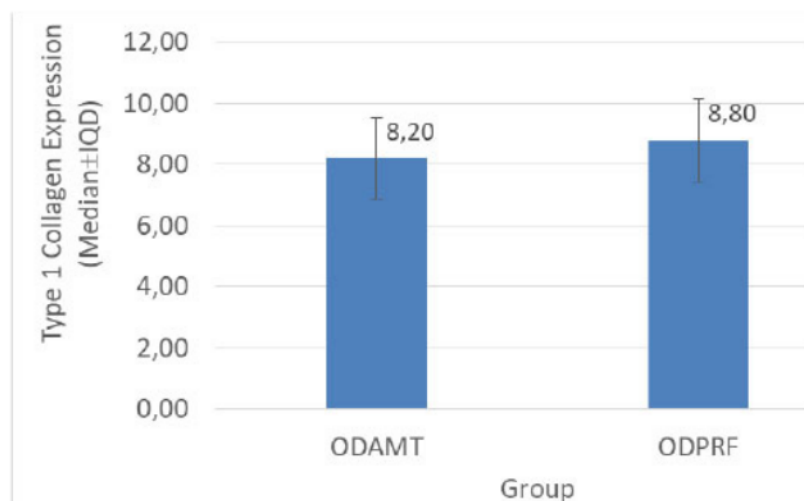


Figure 5. Comparative diagram of type 1 collagen expression in the AMT and PRF groups.

amniotic membranes after conjunctival excision of experimental male New Zealand rabbits on day 14.

ETHICAL CLEARANCE

Ethical eligibility was obtained from the Ethics Commission for Basic and Clinical Science Research at the Faculty of Veterinary Medicine, Universitas, Surabaya, before conducting the research (No. 2.KE.004.01.2020).

CONFLICT OF INTEREST

The authors declare no conflict of interest.

SOURCE OF FUNDING

Self-funding.

AUTHOR CONTRIBUTIONS

All authors equally contribute to the study from the conceptual framework, data acquisition, and data analysis until reporting the study results through publication.

ACKNOWLEDGMENTS

We want to say thank you to the staff of the Department of Ophthalmology and Department of Anatomical Pathology, Medical Faculty, Universitas Airlangga, Dr. Soetomo General Academic Hospital, Indonesia, and staff of the Veterinary Medicine Faculty, Universitas Airlangga, Surabaya, Indonesia.

REFERENCES

- Schrader S, Notara M, Beaconsfield M, Tuft SJ, Daniels JT, Geerling G. Tissue engineering for conjunctival reconstruction: established methods and future outlooks. *Curr Eye Res.* 2009;34(11):913-924. doi:10.3109/02713680903198045.
- Drechsler CC, Kunze A, Kureshi A, et al. Development of a conjunctival tissue substitute on the basis of plastic compressed collagen. *J Tissue Eng Regen Med.* 2017;11(3):896-904. doi:10.1002/term.1991.
- Huang D, Xu B, Yang X, Xu B, Zhao J. Conjunctival structural and functional reconstruction using acellular bovine pericardium graft (Normal GEN®) in rabbits. *Graefes Arch Clin Exp Ophthalmol.* 2016;254(4):773-783. doi:10.1007/s00417-015-3201-1.

4. Erkanan ST, Mustika A, Basuki NH, Hermawan D, and Komaratih E. Attenuation of Transforming Growth Factor- β Expression by Altepase in Anterior Lens Capsule Fibrosis Model with Fibrin Reaction In Vitro. *International Journal of Research Publications*. 2021;82(1). <https://doi.org/10.47119/ijrp100821820212177>.
5. Hall AH. Epidemiology of ocular chemical burn injuries. In: *Chemical Ocular Burns: New Understanding and Treatments*. Springer Berlin Heidelberg. 2011. p9–15.
6. Hung KH, Hsiao CH, Tan HY, et al. Clinical demographics of pterygium excision and prevalence of conjunctival intraepithelial neoplasia: a 15-year review. *Int Ophthalmol*. 2020;40(7):1781-1788. doi:10.1007/s10792-020-01347-y.
7. Meller D, Pauklin M, Thomasen H, Westekemper H, Steuhl KP. Amniotic membrane transplantation in the human eye. *Dtsch Arztebl Int*. 2011;108(14):243-248. doi:10.3238/arztebl.2011.0243.
8. Sudrajat N, Nurhidayat BR, Putra OS, Loebis R, Zuhria I. Relation between Blood Parameters and Platelet-Rich Fibrin Membrane Size for Ocular Graft. *NeuroQuantology*. 2022;20(4). p454–9. DOI:10.14704/nq.2022.20.4.NQ22258.
9. Permatasari D, Soebagjo HD, Zuhria I, Kurniasari N, Notobroto HB, Nandini C. Cryotherapy Has No Significant Effect on MMP-9 and TGF- β 1 Expression in Fungal Corneal Ulcer. *Indones Biomed J*. 2021;13(3). p295–302. DOI:10.18585/inabj.v13i3.1516.
10. Can ME, Çakmak HB, Dereli Can G, Ünverdi H, Toklu Y, Hücemenoğlu S. A Novel Technique for Conjunctivoplasty in a Rabbit Model: Platelet-Rich Fibrin Membrane Grafting. *J Ophthalmol*. 2016;2016:1965720. doi:10.1155/2016/1965720.
11. Arta WS and Komaratih E. Inhibition of Type I Collagen Expression in Fibrosis Prevention after Trabeculectomy: *Oryctolagus cuniculus*. *Sys Rev Pharm*. 2020;11(6). p972-978.
12. Chopra T, Biomim Biomater J, Biomim J, Eng BT. The Preparation of Silk Fibroin Modified Pbt-Co-Pbs/Peg Composite Films and their Effects on Clinical Human Salivary Epithelial Cells Transplantation. *Tissue Eng*. 2013;18(1). DOI:10.4172/1662-100X.1000106
13. Costa E, Neto Murta J. Amniotic membrane in ophthalmology. In: *Amniotic Membrane: Origin Characterization and Medical Applications*. Springer Netherlands. 2015. p105–22.
14. Laranjo M. Preservation of amniotic membrane. In: *Amniotic Membrane: Origin Characterization and Medical Applications*. Springer Netherlands; 2015. p. 209–30.
15. Paolin A, Cogliati E, Trojan D, et al. Amniotic membranes in ophthalmology: long term data on transplantation outcomes. *Cell Tissue Bank*. 2016;17(1):51-58. doi:10.1007/s10561-015-9520-y.
16. Liu J, Sheha H, Fu Y, Giegengack M, Tseng SC. Oral mucosal graft with amniotic membrane transplantation for total limbal stem cell deficiency. *Am J Ophthalmol*. 2011;152(5):739-47.e1. doi:10.1016/j.ajo.2011.03.037.
17. Burman S, Tejwani S, Vemuganti GK, Gopinathan U, Sangwan VS. Ophthalmic applications of preserved human amniotic membrane: a review of current indications. *Cell Tissue Bank*. 2004;5(3):161-175. doi:10.1023/B:CATB.0000046067.25057.0a.
18. Dohan Ehrenfest DM. How to optimize the preparation of leukocyte- and platelet-rich fibrin (L-PRF, Choukroun's technique) clots and membranes: introducing the PRF Box. *Oral Surg Oral Med Oral Pathol Oral Radiol Endod*. 2010;110(3):275-280. doi:10.1016/j.tripleo.2010.05.048.
19. Nowak M, Madej JA, Dziegiel P. Intensity Of Cox2 Expression In Cells Of Soft Tissue Fibrosarcromas In Dogs As Related To Grade Of Tumour Malignancy. *Bull Vet Inst Pulawy*. 2007;51. p275-279.
20. Biernacka A, Dobaczewski M, Frangogiannis NG. TGF- β signaling in fibrosis. *Growth Factors*. 2011;29(5):196-202. doi:10.3109/08977194.2011.595714.
21. Zada M, Pattamatta U, White A. Modulation of Fibroblasts in Conjunctival Wound Healing. *Ophthalmology*. 2018;125(2):179-192. doi:10.1016/j.ophtha.2017.08.028.
22. Sari R, Lastianny SP, Fadhilah AN. The Effect Of Biological Membranes to Fibroblast Proliferation: Platelet-Rich Fibrin Releasate Vs. Amniotic (Research report). *Dentino*. 2019;4(1). p83-86.
23. Nakamura T, Yoshitani M, Rigby H, et al. Sterilized, freeze-dried amniotic membrane: a useful substrate for ocular surface reconstruction. *Invest Ophthalmol Vis Sci*. 2004;45(1):93-99. doi:10.1167/iovs.03-0752.
24. Hsu WC, Spilker MH, Yannas IV, Rubin PA. Inhibition of conjunctival scarring and contraction by a porous collagen-glycosaminoglycan implant. *Invest Ophthalmol Vis Sci*. 2000;41(9):2404-2411.
25. Zhou H, Lu Q, Guo Q, et al. Vitriified collagen-based conjunctival equivalent for ocular surface reconstruction. *Biomaterials*. 2014;35(26):7398-7406. doi:10.1016/j.biomaterials.2014.05.024.



This work is licensed under a Creative Commons Attribution

Platelet-rich fibrin (PRF) graft and amniotic membrane graft on transforming growth factor- β (TGF- β) and type 1 collagen post conjunctival excision

ORIGINALITY REPORT

15%

SIMILARITY INDEX

13%

INTERNET SOURCES

10%

PUBLICATIONS

4%

STUDENT PAPERS

PRIMARY SOURCES

| | | |
|---|---|----|
| 1 | Submitted to Universitas Muhammadiyah Yogyakarta Student Paper | 1% |
| 2 | scholar.unair.ac.id Internet Source | 1% |
| 3 | iovs.arvojournals.org Internet Source | 1% |
| 4 | www.ektodermaldisplazi.com Internet Source | 1% |
| 5 | pure.rug.nl Internet Source | 1% |
| 6 | Aynur Demir, Dilek O. Erdikmen, Zeynep T. Sevim, Yusuf Altundağ. "The use of an autologous platelet-rich fibrin (PRF) membrane for the treatment of deep corneal ulcers in dogs", Veterinarski arhiv, 2022 Publication | 1% |
| 7 | phcogj.com | |

Internet Source

1 %

8

repository.poltekeskupang.ac.id

Internet Source

1 %

9

Amniotic Membrane, 2015.

Publication

1 %

10

Mehmet Erol Can, Gamze Dereli Can, Nurullah Cagil, Hasan Basri Cakmak, Nuran Sungu.

"Urgent Therapeutic Grafting of Platelet-Rich Fibrin Membrane in Descemetocoele", Cornea, 2016

Publication

1 %

11

Submitted to University of Bristol

Student Paper

1 %

12

garuda.kemdikbud.go.id

Internet Source

1 %

13

Betul Tugcu, Havvanur Bayraktar, Cansu Ekinci, Zafer Kucukodaci, Mustafa Tunali, Fadime Nuhoglu. "The effect of platelet-rich fibrin on wound healing following strabismus surgery", Cutaneous and Ocular Toxicology, 2022

Publication

1 %

14

ijbs-udayana.org

Internet Source

1 %

www.dovepress.com

| | | |
|----|---|------|
| 15 | Internet Source | 1 % |
| 16 | www.ncbi.nlm.nih.gov Internet Source | 1 % |
| 17 | www.sysrevpharm.org Internet Source | <1 % |
| 18 | Napaporn Tananuvat, Kanokkan Bumroongkit, Chainarong Tocharusa, Umnat Mevatee, Aphisek Kongkaew, Somsanguan Ausayakhun. "Limbal stem cell and oral mucosal epithelial transplantation from ex vivo cultivation in LSCD-induced rabbits: histology and immunologic study of the transplant epithelial sheet", International Ophthalmology, 2016 Publication | <1 % |
| 19 | journal.um-surabaya.ac.id Internet Source | <1 % |
| 20 | Namrata Sharma, S.A. Thenarasun, Manpreet Kaur, Neelam Pushker, Neena Khanna, Tushar Agarwal, Rasik B. Vajpayee. "Adjuvant Role of Amniotic Membrane Transplantation in Acute Ocular Stevens–Johnson Syndrome", Ophthalmology, 2016 Publication | <1 % |
| 21 | Rezmelia Sari, Grace Sekar Larasati, Nurul Ghoutsiyah Kuncorowati, Ahmad Syaify. | <1 % |

"Platelet-Rich Fibrin (PRF) Membranes Accelerate Open Wound Healing Better Than Amniotic Membranes: A Histological Study on the Proliferation Phase", Wound Medicine, 2020

Publication

22

science-line.com

Internet Source

<1 %

Exclude quotes Off

Exclude matches Off

Exclude bibliography On