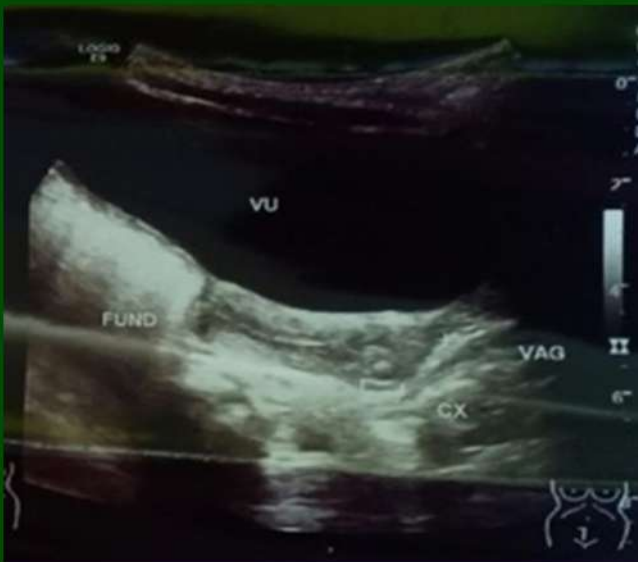


Majalah Obstetri & Ginekologi



JOURNAL OF OBSTETRICS & GYNECOLOGY SCIENCE

Vol. 30 No. 3 December 2022



USG of the cervix of a patient with organic Central Precocious Puberty (CPP)

Original Research

- The coping process and acceptance among women with cervical cancer
- Cobas® 4800 HPV test is accurate for detecting high risk Human Papillomavirus from urine samples at dr. Cipto Mangunkusumo National Central General Hospital, Jakarta, Indonesia
- Maternal and neonatal outcomes in delivery with diagnosis of antepartum hemorrhage due to placenta previa at a tertiary hospital in Surabaya, Indonesia
- Serological description of neonatal umbilical cord blood from pregnant women confirmed with positive COVID-19 by RT-PCR at Rumah Sakit Umum Pusat H. Adam Malik, Medan, Indonesia

Case Reports

- Comprehensive management of pregnant woman with Sjögren's syndrome
- Psychological aspects of precocious puberty child during the COVID-19 pandemic

Review Article

- The role of antihypertensive drugs in patients with preeclampsia and how to prevent it

Systematic Review

- The role of adequate vitamin D levels in the menstrual cycle of reproductive-age women

Published by

Department of Obstetrics and Gynecology, Faculty of Medicine, Universitas Airlangga
In Collaboration with Indonesian Society of Obstetrics and Gynecology

Accredited by Ministry of Education, Culture, Research, and Technology, Republic of Indonesia
No. 105/E/KPT/2022

Majalah
Obstetri & Ginekologi

JOURNAL OF OBSTETRICS & GYNECOLOGY SCIENCE

ACCREDITED

Ministry of Education, Culture, Research, and Technology, Republic of Indonesia
No. 105/E/KPT/2022

EDITORIAL TEAM

Founding Editor

Prof. Soehartono Ds, dr, SpOG(K)

Editor-in-Chief

Prof. Dr. Hendy Hendaro, dr, SpOG(K)

Associate Editor

Dr. M. Aldika Akbar, dr, SpOG(K)

Editorial Board

Prof. Gustaaf Dekker, MD, PhD, FDCOG, FRANZCOG (The University of Adelaide, Northern Campus, Australia),
Dr. J. van der Velden PhD (Academic Medical Center, Amsterdam, Netherlands), Prof Dr med Michael D Mueller (Department of
Obstetrics and Gynecology, Bern University, Switzerland), Dr Roy Ng Kwok Weng, MBMS, LRCPS, FRCOG, MOG, FAMS (Division of
Urogynaecology and Pelvic Reconstructive Surgery, National University Hospital, Singapore), Dr Mohammad Afzal Mahmood, MB, BS, PhD
(School of Public Health, University of Adelaide, Australia), Prof. Togas Tulandi, MD., MHCM., FRCSC., FACOG (Department of
Obstetrics and Gynecology, Milton Leong Chair in Reproductive Medicine, Faculty of Medicine and Health Sciences, McGill University,
Montreal, Canada), Prof. Delvac Oceandy, MD, PhD (University of Manchester, Manchester, United Kingdom), Satria Arief Prabowo, MD,
PhD (Faculty of Infectious and Tropical Diseases, Tuberculosis Centre and Vaccine Centre, London School of Hygiene and Tropical
Medicine, London, United Kingdom), Prof James Robert, MD, PhD (Department of Obstetrics, Gynecology, and Reproductive Sciences,
University of Pittsburgh, United States), Prof Dr Budi Iman Santoso, dr, SpOG(K), (Department of Obstetrics and Gynecology, Faculty of
Medicine, Universitas Indonesia, Jakarta, Indonesia), Prof Dr Johannes C Mose, dr, SpOG(K) (Department of Obstetrics and Gynecology,
Faculty of Medicine, Padjadjaran University, Bandung, Indonesia), Prof Dr Sri Sulistyowati, dr, SpOG(K) (Department of Obstetrics and
Gynecology, Faculty of Medicine, Sebelas Maret University, Surakarta, Indonesia), Prof Dr Budi Santoso, dr, SpOG(K)
(Department of Obstetrics and Gynecology, Faculty of Medicine, Universitas Airlangga, Surabaya, Indonesia)

Managing Editors

MY Ardianta Widyanugraha, dr, SpOG, Hanifa Erlin Damayanti, dr, SpOG, Rizki Pranadyan, dr, SpOG,
Arif Tunjungseto, dr, SpOG, Nareswari Imanadha Cininta, dr, SpOG, Rozi Aditya, dr, SpOG,
Pandu Hanindito Habibie, dr, SpOG, Riska Wahyuningtyas, dr, SpOG, M.Ked.Klin

Assistant Editors

Mochammad Zuhdy, Priska Dwi Wahyurini

Address

Department of Obstetrics and Gynecology
Faculty of Medicine, Universitas Airlangga - Dr. Soetomo General Academic Hospital
Jl. Mayjen Prof dr Moestopo no. 6 – 8, Surabaya 60286, Indonesia. Phone: 62-31-5501185, Facs: 62-31-5037733
<https://e-journal.unair.ac.id/MOG/>
Email: mog@journal.unair.ac.id, mog.obgsby@gmail.com

Majalah *Obstetri & Ginekologi*

JOURNAL OF OBSTETRICS & GYNECOLOGY SCIENCE

CONTENT

ORIGINAL RESEARCH :

1. The coping process and acceptance among women with cervical cancer
Ummu Kulsum, Dwi Izzati, Eighty Mardiyani Kurniawati, Sulistiawati 108 – 115
2. Cobas® 4800 HPV test is accurate for detecting high risk Human Papillomavirus from urine samples at dr. Cipto Mangunkusumo National Central General Hospital, Jakarta, Indonesia
Indiarto Wityawan, Andrijono, Aria Kekalih 116 – 121
3. Maternal and neonatal outcomes in delivery with diagnosis of antepartum hemorrhage due to placenta previa at a tertiary hospital in Surabaya, Indonesia
Sarah Nia Amru, Indra Yuliati, Philia Setiawan 122 – 127
4. Serological description of neonatal umbilical cord blood from pregnant women confirmed with positive COVID-19 by RT-PCR at Rumah Sakit Umum Pusat H. Adam Malik, Medan, Indonesia
Benjamin Sihite, Makmur Sitepu, Khairani Sukatendel, Sarma Nursani Lumbanraja, Iman Helmi Effendi, Rizki Yaznil, Edy Ardiansyah 128 – 133

CASE REPORTS :

5. Comprehensive management of pregnant woman with Sjögren's syndrome
Giovanny Azalia Gunawan, Adinda Ayu Dyah Rahadina, Budi Prasetyo 134 – 138
6. Psychological aspects of precocious puberty child during the COVID-19 pandemic
Nurul Ima Suciwiati, Nur Rochmah, Muhammad Faizi, Fadhil Abiyyu 139 – 145

REVIEW ARTICLE :

7. The role of antihypertensive drugs in patients with preeclampsia and how to prevent it
I Gde Sastra Winata, I Wayan Agus Surya Pradnyana, Maria Septiana Parmonang Aroean 146 – 153

SYSTEMATIC REVIEW :

8. The role of adequate vitamin D levels in the menstrual cycle of reproductive-age women
Ahila Meliana, Hana Salsabila, Bendix Samarta Witarto, Manik Retno Wahyunitisari 154 – 160

Cover :
**USG of the cervix of a patient with
organic Central Precocious Puberty (CPP)**


CASE REPORT

Psychological aspects of precocious puberty child during the COVID-19 pandemic

Nurul Ima Suciwiwati¹, Nur Rochmah², Muhammad Faizi², Fadhil Abiyyu¹

¹Faculty of Medicine, Universitas Airlangga, Dr Soetomo General Academic Hospital, Surabaya, Indonesia.

²Department of Child Health, Faculty of Medicine, Universitas Airlangga, Dr Soetomo General Academic Hospital, Surabaya, Indonesia.

Article Info	ABSTRACT
<p>Received Apr 23, 2022 Revised Jun 17, 2022 Accepted Jul 20, 2022 Published Dec 1, 2022</p> <p>Corresponding author: Nur Rochmah nur-r@fk.unair.ac.id</p> <p>Keywords: Precocious Puberty (PP) Psychological aspect COVID-19 Mental health</p> <p>This is an open access article under the CC BY-NC-SA license (https://creativecommons.org/licenses/by-nc-sa/4.0/)</p> 	<p>Objective: To present a longitudinal case of a child with organic Central Precocious Puberty (CPP) that focused on medical, growth and development, and parent's psychological aspect during the COVID-19 pandemic.</p> <p>Case Report: A 14-month old girl attended with major complaints of breasts enlargement and menstruation. The Tanner's stage was at A1M3P1 and the vagina showed reddish-brown spots. The patient's bone age was advanced (3 years and 6 months). USG examination showed a corpus uterine: cervix ratio of 2:1. GnRH stimulation test showed an elevated of FSH/LH and estradiol. MRI showed an extra-axial dense mass that leads to Hypothalamic Hamartoma (HH). The definitive diagnosis of this patient was organic CPP with HH. The patient was managed with GnRH analog. Precocious puberty (PP) becomes a financial and psychosocial burden for parents. The COVID-19 pandemic adds a double burden for the parents.</p> <p>Conclusion: During the COVID-19 pandemic, parents with PP children had a good psychological aspect if the child was comprehensively handled with adequate motivation and psychoeducation.</p>

Cite this as : Suciwiwati, N.I., Rochmah, N., Faizi, M., et al. (2022). Psychological aspects of precocious puberty child during the COVID-19 pandemic. *Majalah Obstetri & Ginekologi*, 30(3), 139-145.
<https://doi.org/10.20473/mog.V30I32022.139-145>.

INTRODUCTION

Precocious puberty (PP) is a common condition in pediatric endocrinology cases. It is defined as the development of pubertal changes before 8 years old in girls. PP is responsible for early progression of secondary sexual characteristics, rapid bone maturation, final height reduction, inappropriate body appearance, and psychological behavioral abnormalities.^{1,2}

It is classified into central precocious puberty (CPP) and peripheral precocious puberty (PPP) types. CPP accounts for 80% of patients with PP. The frequency of CPP ranges between 1/5.000 – 1/10.000 and more frequent in girls. Gender ratio for girls:boys is between

3 : 1.³ Based on the data, 13 CPP cases were reported in Dr. Soetomo General Academic Hospital, Surabaya, Indonesia from January 2012 to June 2015 with girls : boys proportion was 10 : 3.

PP becomes a financial and psychosocial burdens for parents. Furthermore, the COVID-19 pandemic worsens the situation. An Italian study described that during and after the COVID-19 lockdown, the incidence of newly diagnosed and pubertal progression of CPP increased.⁴ A previous study explained that psychological stress caused by parents or parental conflicts could induce early puberty. The impact of COVID-19 increased stress and behavioral changes due to quarantine or social isolation.⁵ Parents may also pass their psychological



distress to children, leading to improper parenting behaviors, which may affect medical treatment and the outcome of children with PP.⁶

In this case report, we reported the monitoring of a child with organic CPP with Hypothalamic Hamartoma (HH) that focused on medical, growth and development, and parent's psychological aspect.

CASE REPORT

A 14-month-old girl attended the pediatric endocrinology outpatient, Dr. Soetomo General Hospital, on June 26, 2019 with major complaints of breasts enlargement and menstruation. The mother reported that she realized her daughter had breast development since six months of age and early menstruation was observed at 9-month of age for 3 days, then stopped, and happened again at 1-year of age. It started with brown blood and then bright red blood with mucus. Pubic and armpit hair were not found. There was no history of disease, trauma and drug or corticosteroid use in long time.

She was the third daughter and there was no history of taking any medicine nor radiation exposure during pregnancy. She was delivered spontaneously by midwife. The birth weight and length was 3100 gr and 49 cm. The patient had exclusive breastfeeding until 22-month-old then continued with formula milk. The immunization was up to date. She was able to stand at

age 11-month-old and walk by herself at age 13-month-old, talk fluently at age 17-month-old. The mother reported her first menstruating when she was 11-year-old and her father got bed wetting when he was 13-year-old. The father and the mother height are 160 cm and 150 cm. The mid parental height was 164 cm and the child predictive adult height was 140 – 157 cm.

Physical examination presented an alert girl, with body weight and height were 10 kg and 83 cm. Percentage of ideal body weight was classified as good nutrition. Growth velocity was 7.6 - 8.3 cm/year. Blood pressure was 90/50 mmHg, heart rate was 110 beats/minute, respiratory rate was 24 beats/minute, and axillary temperature was 36°C. Examination of head, neck, lungs, heart, abdomen and extremities were within normal limits. WHO Z-score plotting showed normal WAZ, WLZ, HcAZ and LAZ >2SD.

The patient had tanner stage 1 of armpit hair development, tanner stage 3 of breast development, and tanner stage 1 of pubic hair and genital development (A1M3P1). There were sign of vaginal discharge, labia minor development, and menstruation. Based on history taking and physical examination the working diagnose of this patient was suspicious PP. The patient was examined for bone age using Greulich and Pyle method and it was found that the predicted patient age was 3-year and 6-month with chronological age of 14 month. Ultrasonography (USG) showed a corpus uterine : cervix ratio was 2 : 1 (normal ratio <1).

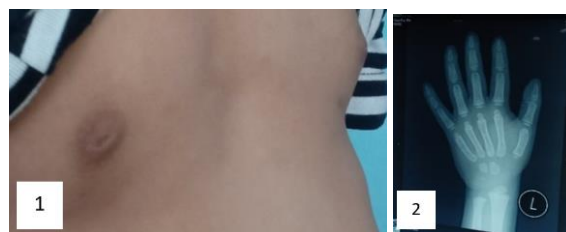


Figure 1 & 2. (1) Patient's breasts (Stage 3 breast development). (2) X-Ray of patient's left palm

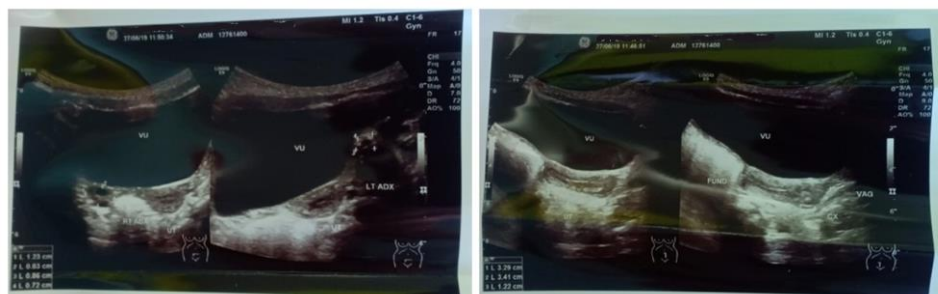

Figure 3. USG of patient's uterus and cervix

Table 1. Hormonal examination (GnRH Stimulation Test)

	Basal		2 hours after Leuprorelin		Normal value
	N	Interpretation	N	Interpretation	
LH	6.55	Elevated	23.33	Elevated	0.1 - 3.1
FSH	5.23	Normal	12.69	Elevated	0.46 - 5.98
Estradiol	28.67	Elevated	39.03	Elevated	6.00 - 27.00

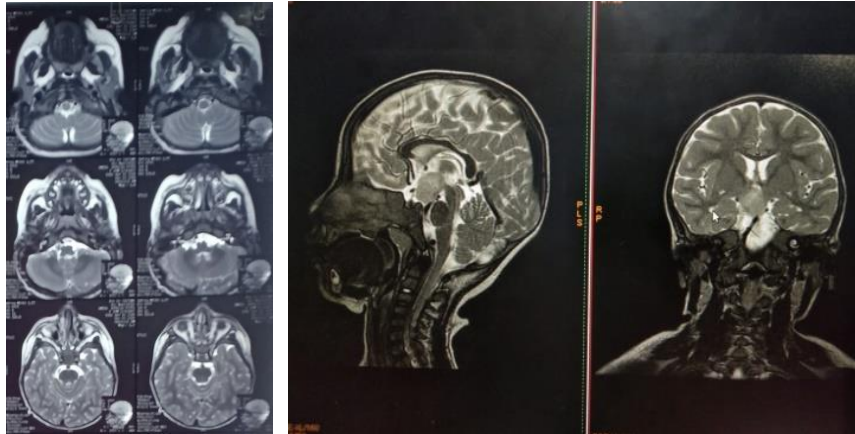


Figure 4. Patient's head MRI

A Gonadotropin-Releasing Hormone (GnRH) stimulation test is needed to differentiate CPP and PPP. CPP theoretically has hormonal abnormality and high level of estradiol, Follicle Stimulating Hormone (FSH) and Luteinizing Hormone (LH) after GnRH stimulation test.⁷ The genes GABRA1, LIN28B, NPYR, TAC3, and TACR3 are associated with CPP.⁸ Laboratory examination after GnRH stimulation test found a high level of FSH/LH, FSH and LH ratio >1, and high level of estrogen. Head Magnetic Resonance Imaging (MRI) showed an extra-axial dense mass, 2.2 x 1.5 x 1.7 cm, in supra-cellular (from tuburus cinereum) that leads to HH. The definitive diagnosis of this patient was organic CPP with HH. The patient was in good condition after medication, and no adverse event occurred. Moreover, the patient had an MRI for follow-up.

DISCUSSION

Medical aspect

The patient was monitored for medical aspects from February - August 2020. Diagnosis of PP underlies on the growth spurt, advanced bone age, secondary sexual characteristic and an elevated LH, FSH, estradiol after GnRH stimulation test.^{1,9} At the final follow-up at 28-month, the patient had a good treatment compliance, LH

and FSH level was 0.16 and 1.15, and 4-year old of bone age (chronological age was 28-month).

Puberty is the developmental process that causes the secondary sexual characteristics and the capacity to reproduce. Breast development is one of the secondary sexual characteristics which normally (thelarche: the onset of breast buds) starts between 8 and 13 years of age, followed within a few years by pubic hair growth (pubarche: the onset of pubic hair).^{1,9} It begins with the activation of the hypothalamic-pituitary-gonadal axis and ends with the attainment of reproductive capability and the acquisition of adult body in terms of composition and habitus.

Pathological conditions in which puberty occurs early are divided into PP, premature adrenarache, McCune-Albright syndrome, and premature thelarche.¹⁰ Menstruation is an important phase which is influenced by the psychological (signs of adulthood, female identity) and physiological factors (normal hypothalamus-pituitary-ovarian axis, basis for fertility and reproduction).¹¹ Early menarche is menarche which occurs at the age before 10-year old and part of PP. Early menarche increases the risk of obesity, hypertension, type 2 diabetes mellitus, ischemic heart disease, stroke, cardiovascular disease, and cancer.^{11,12}

Table 2. Patient’s medical aspect monitoring schedule

Parameters	Month of observation					
	1	2	3	4	5	6
Patient’s complaints	✓	✓	✓	✓	✓	✓
Vital signs and clinical symptoms	✓	✓	✓	✓	✓	✓
Bone age	✓					✓
Laboratory Results						
LH	✓					✓
FSH	✓					✓
Estradiol						✓
Regularity of drug injection	✓	✓	✓	✓	✓	✓
No drug side effect	✓	✓	✓	✓	✓	✓

The patient’s bone age (3-year and 6-month) increased because the increasing bone age in PP is $\geq 2,5$ SD or ≥ 2 years from chronological age and bone age/chronological age ratio is >1 .⁹ Sex steroid hormone (estradiol) influences growth stimulation in girls. Hence, it stimulates bone maturation and at the end of the puberty, the bone stops growing. To assess the extent a child has grown, it is necessary to calculate the stage of sexual development, height, and bone age.^{7,13}

GnRH stimulation test is a gold standard to identify CPP. The results of the GnRH stimulation test that showed a LH and FSH ratio >1 and an increase in LH 5-8 IU/liter confirmed the diagnosis of CPP.¹⁴ Head MRI intends to evaluate intracranial lesion in CPP. Most causes of CPP are idiopathic and in selective cases are resulted by organic causes.^{15,16} HH is a disorder of the central nervous system (CNS) and relates to endocrinological and neurological disorders. HH as progenitor hypothalamus-pituitary-gonad axis, which contains normal neuron (astrocytes), expresses TgF alpha and beta to produce GnRH. The appearance of endocrinology symptoms are PP, obesity, acromegaly, and hypopituitarism.¹⁷ The incidence of HH has increased with the use of MRI.¹⁰ Kumar et al., mentioned that the HH prevalence on CPP was around 21% - 49%.¹⁸

HH without neurological symptoms does not require surgery, thus long-term medical therapy is a must. Medical therapy is a GnRH analog to suppress the hypothalamus-pituitary-gonad pathway by giving constant stimulation to gonadotroph pituitary cells. The stimulation will result in the desensitization of gonadotroph cells and the suppression of gonadotropin (LH and FSH) production which in the end will reduce sex hormone production from gonad (ovarium).¹⁹ The goals of the therapy are to slow down the growth rate and the bone maturation, prevent short adult height, avoid emotional and psychological stress.⁷ The patient

received an intramuscular injection of leuporelin acetate 1.8 mg every 4 weeks. In general, the treatment can be stopped at the age of physiological puberty (10 – 11 years old for girls). Development of puberty will reoccur about one year (\pm 18-month) after stopping the treatment. In idiopathic CPP, the earlier therapy is started, the better the prognosis will be. In organic CPP, the prognosis depends on the cause and location of the lesion in the CNS.²⁰

Growth and development aspect

The patient was monitored for growth and development aspects from February - August 2020. During the observation, it showed that the patient's height did not increase significantly (<5 cm/year) and the height curve started to slope and corresponded to the mid parental height. Tanner’s stage regressed to A1M2P1. The aspects of language development, fine and gross motor skills, social personal, and cognitive-intelligence functions were good.

Growing up is a hallmark of puberty with the height rate becomes sudden (height spurt). Premature puberty will lead to a decrease in adult height to compensate for premature maturation of the bones. PP shortens the duration of prepubertal and pubertal growth so that they can not reach the maximum peak amplitude. The therapy is aimed to restore the duration of prepubertal in order to reach the target of the height prediction.^{20,21} Tanner's stage is a parameter that is used to determine the sex maturity rating from a value of 1 to 5.¹⁴ The development of breasts and pubic hair is the main concern in girls during puberty. Development of secondary sex characteristics, which are ovarian and uterine size, growth rate, and bone maturation are monitored by clinically, sonographically, and radiologically. In most of the patients, the reduction occurred after 6 months of treatment.²²



Table 3. Patient’s growth and development aspect monitoring schedule

Parameters	Month of observation					
	1	2	3	4	5	6
Growth Aspect						
Height	✓	✓	✓	✓	✓	✓
Weight	✓	✓	✓	✓	✓	✓
Head Circumference	✓					✓
Development Aspect						
Denver II	✓			✓		✓
CAT CLAMS	✓			✓		✓

Developmental Quotient (DQ) is a scoring system that describes the proportion of normal children’s development at that age. The development of children is said to be normal if DQ in language and visual-motor skills and Full Scale DQ are >85.²³ The patient has Denver II and FSDQ >85. According to some studies, there is no intellectual function and academic score difference between PP patient and normal child. However, there is a difference in performance IQ, which the former scores lower. This is presumably because early maturation is associated with lower spatial development due to weakness in the function of the right hemisphere.²⁴ Early puberty is linked with a higher risk of mental health and behavior problems. Maturation abnormality due to early puberty is influenced by sudden hormonal changes that lead to emotional overload and behavioral changes.²⁵

Parent’s psychological aspect in COVID-19 pandemic era

The parent’s psychological aspect was measured by the Parental Stress Scale (PSS). The PSS is developed by Berry and Jones in 1995 to measure the levels of stress experienced by the parents. The tool consists of 18 self-report scale items that represent positive and negative themes of parenthood. Respondents agree or disagree in terms of their typical relationship with their children with a 5-point scale. Overall possible score on the scale range from 18 – 90 and the higher the score, the higher the level of parental stress. Higher level of parental stress relates to lower level of parental sensitivity to the child, poorer child behavior, and lower quality of parent-child relationships. The validity of PSS scores was supported by predicted correlations with measures of relevant emotions and role satisfaction and significant discrimination between mothers of children in treatment for emotional/behavioral problems and developmental disabilities and mothers of children not receiving treatment.²⁶ COVID-19 pandemic led to community-wide measures, affecting parents and

children. Parents of children with PP were reported having a higher level of stress, worse mental health, and a financial burden.^{27,28} Psychoeducation and motivation from health workers at all levels of health facilities are urgently needed.

In this case, the PSS is presented. The questionnaire was filled out by the patient’s parents (parent-reported). The result of PSS score was 24 which is a low level of PSS. It indicates that PP patients who are treated have a good influence on the psychosocial condition of the parents. The existence of good psychoeducation and government health insurance to get the convenience of treatment have an effect on the psychology of the parents. Children with abnormal puberty may have an early evaluation to improve patients prognosis and quality of life. The limitation of this case report was that it only presented one case, so there was a lack of ability to generalize.

CONCLUSION

We presented a longitudinal case of 14-month old girl with organic CPP with HH, in which long term GnRH analog was chosen as the main therapy. From the result of 6-month observation, it obtained a good medical and growth and development aspect outcomes. The parent’s psychological aspect which measured by the PSS score showed a good score when the PP patient handled comprehensively with good motivation and psycho-education during the COVID-19 pandemic.

DISCLOSURES

Acknowledgment

Thanks to all the study participants and the endocrine team of Dr. Soetomo General Academic Hospital, Surabaya, Indonesia, for their support.



Conflict of interest

The authors report there are no competing interests to declare.

Patient's consent for publication

The patient's parents signed the informed consent form and agreed that this case report is published.

Funding

This research has received no external funding.


Author contribution

All authors have contributed to all processes in this research, including preparation, data gathering and analysis, drafting and approval for publication of this manuscript.

REFERENCES

1. Fuqua JS. Treatment and outcomes of precocious puberty: an update. *J Clin Endocrinol Metab.* 2013;98(6):2198-207. doi: 10.1210/jc.2013-1024. Epub 2013 Mar 20. PMID: 23515450.
2. Berberoğlu M. Precocious puberty and normal variant puberty: definition, etiology, diagnosis and current management. *J Clin Res Pediatr Endocrinol.* 2009;1(4):164-74. doi: 10.4274/jcrpe.v1i4.3. Epub 2009 May 2. PMID: 21274291; PMCID: PMC3005651.
3. Phillip M, Lazar L. Precocious puberty: growth and genetics. *Horm Res.* 2005;64 Suppl 2:56-61. doi: 10.1159/000087760. PMID: 16286772.
4. Stagi S, De Masi S, Bencini E, et al. Increased incidence of precocious and accelerated puberty in females during and after the Italian lockdown for the coronavirus 2019 (COVID-19) pandemic. *Ital J Pediatr.* 2020;46(1):165. doi: 10.1186/s13052-020-00931-3. PMID: 33148304; PMCID: PMC7609833.
5. Chioma L, Bizzarri C, Verzani M, et al. Sedentary lifestyle and precocious puberty in girls during the COVID-19 pandemic: an Italian experience. *Endocr Connect.* 2022;11(2):e210650. doi: 10.1530/EC-21-0650. PMID: 35029543; PMCID: PMC8859940.
6. Demaria F, Vicari S. COVID-19 quarantine: Psychological impact and support for children and parents. *Ital J Pediatr.* 2021;47(1):58. doi: 10.1186/s13052-021-01005-8. PMID: 33750452; PMCID: PMC7941406.
7. Kim HK, Kee SJ, Seo JY, et al. Gonadotropin-releasing hormone stimulation test for precocious puberty. *Korean J Lab Med.* 2011;31(4):244-9. doi: 10.3343/kjlm.2011.31.4.244. Epub 2011 Oct 3. PMID: 22016677; PMCID: PMC3190002.
8. Shim YS, Lee HS, Hwang JS. Genetic factors in precocious puberty. *Clin Exp Pediatr.* 2022;65(4):172-81. doi: 10.3345/cep.2021.00521. Epub 2021 Oct 18. PMID: 34665958; PMCID: PMC8990949.
9. Faizi M, Artati RD, Pulungan AB. Diagnosis dan tata laksana pubertas prekoks sentral. *Pedoman Praktek Klinik Ikatan Dokter Anak Indonesia.* [Internet]. 2017. Available from: <http://spesialis1.ika.fk.unair.ac.id/wp-content/uploads/2018/03/PPK-Pubertas-Prekoks-Sentral.pdf>
10. Kotwal N, Yanamandra U, Menon AS, et al. Central precocious puberty due to hypothalamic hamartoma in a six-month-old infant girl. *Indian J Endocrinol Metab.* 2012;16(4):627-30. doi: 10.4103/2230-8210.98027. PMID: 22837930; PMCID: PMC3401770.
11. Manjila S, Vogel TW, Chen Y, et al. Hypothalamic hamartoma simulating a suprasellar arachnoid cyst: resolution of precocious puberty following microsurgical lesion resection. *J Neurosurg Pediatr.* 2014;14(1):101-7. doi: 10.3171/2014.4.PEDS.13371. Epub 2014 May 16. PMID: 24835046.
12. Batubara JR, Bambang Tridjaja AAP, Pulungan AB. *Buku ajar endokrinologi anak [Textbook on pediatric endocrinology].* Edisi I. Jakarta: Badan Penerbit IDAI; 2010.
13. Caillet P, Laurent M, Bastuji-Garin S, et al. Optimal management of elderly cancer patients: usefulness of the Comprehensive Geriatric Assessment. *Clin Interv Aging.* 2014;9:1645-60. doi: 10.2147/CIA.S57849. PMID: 25302022; PMCID: PMC4189720.
14. Hochberg Z. *Practical algorithms in pediatric endocrinology.* Karger Medical and Scientific Publishers; 2007.
15. Chalumeau M, Chemaitilly W, Trivin C, et al. Central precocious puberty in girls: an evidence-based diagnosis tree to predict central nervous system abnormalities. *Pediatrics.* 2002;109(1):61-7. doi: 10.1542/peds.109.1.61. PMID: 11773542.
16. Brown JJ, Warne GL. Growth in precocious puberty. *Indian J Pediatr.* 2006;73(1):81-8. doi: 10.1007/BF02758267. PMID: 16444068.
17. García H, Youlton R, Burrows R, et al.; Rama de Endocrinología Pediátrica de la Sociedad Chilena de Pediatría. Consenso sobre el diagnóstico y tratamiento de la pubertad precoz central [Consensus on the diagnosis and treatment of central early puberty]. *Rev Med Chil.* 2003;131(1):95-110. Spanish. PMID: 12643227.

18. Ng SM, Kumar Y, Cody D, et al. Cranial MRI scans are indicated in all girls with central precocious puberty. *Arch Dis Child*. 2003;88(5):414-8; discussion 414-8. doi: 10.1136/adc.88.5.414. PMID: 12716713; PMCID: PMC1719560.
19. Léger J, Reynaud R, Czernichow P. Do all girls with apparent idiopathic precocious puberty require gonadotropin-releasing hormone agonist treatment? *J Pediatr*. 2000;137(6):819-25. doi: 10.1067/mpd.2000.109201. PMID: 11113839.
20. Léger J, Carel JC. Central Precocious Puberty - Management and Long-term Outcomes. *Eur Endocrinol*. 2015;11(1):45-6. doi: 10.17925/EE.2015.11.01.45. Epub 2015 Apr 11. PMID: 29632569; PMCID: PMC5819064.
21. Xhrouet-Heinrichs D, Lagrou K, Heinrichs C, et al. Longitudinal study of behavioral and affective patterns in girls with central precocious puberty during long-acting triptorelin therapy. *Acta Paediatr*. 1997;86(8):808-15. doi: 10.1111/j.1651-2227.1997.tb08602.x. PMID: 9307158.
22. Stoppelbein L, Greening L, Moll G, et al. Factor analyses of the Pediatric Symptom Checklist-17 with African-American and Caucasian pediatric populations. *J Pediatr Psychol*. 2012;37(3):348-57. doi: 10.1093/jpepsy/jsr103. Epub 2011 Dec 14. PMID: 22171075.
23. Mensah FK, Bayer JK, Wake M, et al. Early puberty and childhood social and behavioral adjustment. *J Adolesc Health*. 2013;53(1):118-24. doi: 10.1016/j.jadohealth.2012.12.018. Epub 2013 Apr 1. PMID: 23558038.
24. Mendle J, Turkheimer E, Emery RE. Detrimental psychological outcomes associated with early pubertal timing in adolescent girls. *Dev Rev*. 2007;27(2):151-71. doi: 10.1016/j.dr.2006.11.001. PMID: 20740062; PMCID: PMC2927128.
25. Williams VSL, Soliman AM, Barrett AM, et al. Review and evaluation of patient-centered psychosocial assessments for children with central precocious puberty or early puberty. *J Pediatr Endocrinol Metab*. 2018;31(5):485-95. doi: 10.1515/jpem-2017-0465. PMID: 29649000.
26. Berry JO, Jones WH. The parental stress scale: Initial psychometric evidence. *J Soc Pers Relat*. 1995;12(3):463-472. doi:10.1177/0265407595123009.
27. A L van Tilburg M, Edlynn E, Maddaloni M, et al. High levels of stress due to the SARS-CoV-2 pandemic among parents of children with and without chronic conditions across the USA. *Children (Basel)*. 2020;7(10):193. doi: 10.3390/children7100193. PMID: 33096787; PMCID: PMC7589303.
28. Kaltiala-Heino R, Marttunen M, Rantanen P, et al. Early puberty is associated with mental health problems in middle adolescence. *Soc Sci Med*. 2003;57(6):1055-64. doi: 10.1016/s0277-9536(02)00480-x. PMID: 12878105.



MAJALAH OBSTETRI & GINEKOLOGI

DEPARTEMEN OBSTETRI DAN GINEKOLOGI, FAKULTAS KEDOKTERAN UNIVERSITAS

AIRLANGGA

P-ISSN : 08540381 <> E-ISSN : 25981013 Subject Area : Health



0.25

Impact Factor



396

Google Citations



Sinta 2

Current
Accreditation

[Google Scholar](#)

[Garuda](#)

[Website](#)

[Editor URL](#)

History Accreditation

2018 2019 2020 2021 2022 2023 2024 2025 2026

[Garuda](#)

[Google Scholar](#)

[Profile of pregnant women with preeclampsia and its termination method](#)

Universitas Airlangga [Majalah Obstetri dan Ginekologi Vol. 30 No. 1 \(2022\): April 10-16](#)

2022 [DOI: 10.20473/mog.V30I12022.10-16](#) [Accred : Sinta 2](#)

[Hot herbal compresses as therapy for reducing labor pain levels in the first stage of active phase in primigravida](#)

Universitas Airlangga [Majalah Obstetri dan Ginekologi Vol. 30 No. 1 \(2022\): April 36-41](#)

2022 [DOI: 10.20473/mog.V30I12022.36-41](#) [Accred : Sinta 2](#)

[Different expression of NF-kB and endometrial implant width in the administration of red fruit \(Pandanus conoideus Lam\) and leuprolide](#)

Universitas Airlangga [Majalah Obstetri dan Ginekologi Vol. 30 No. 1 \(2022\): April 1-9](#)

2022 [DOI: 10.20473/mog.V30I12022.1-9](#) [Accred : Sinta 2](#)

[Maternal and perinatal outcomes of pre-referral magnesium sulfate treatment in severe preeclampsia patients](#)

Universitas Airlangga [Majalah Obstetri dan Ginekologi Vol. 30 No. 1 \(2022\): April 17-23](#)


2022 [DOI: 10.20473/mog.V30I12022.17-23](#) [Accred : Sinta 2](#)

[Preeclampsia correlates with maternal and perinatal outcomes in Regional Public Hospital, Madiun, Indonesia](#)

Universitas Airlangga [Majalah Obstetri dan Ginekologi Vol. 30 No. 1 \(2022\): April 24-31](#)

2022 [DOI: 10.20473/mog.V30I12022.24-31](#) [Accred : Sinta 2](#)

[Potential of trichloroacetic acid \(TCA\) for cervical precancerous lesions treatment in Indonesia](#)

[Universitas Airlangga](#)  [Majalah Obstetri dan Ginekologi Vol. 30 No. 1 \(2022\): April 48-51](#)

 2022  [DOI: 10.20473/mog.V30I12022.48-51](#)  [Accred : Sinta 2](#)

[Contraception method among pregnant women with HIV delivered in Cipto Mangunkusumo General Hospital, Jakarta, Indonesia](#)

[Universitas Airlangga](#)  [Majalah Obstetri & Ginekologi Vol. 30 No. 1 \(2022\): April 42-47](#)

 2022  [DOI: 10.20473/mog.V30I12022.42-47](#)  [Accred : Sinta 2](#)

[Eclampsia as the leading cause of maternal death at Prof. dr. R.D. Kandou Hospital, Manado, Indonesia](#)

[Universitas Airlangga](#)  [Majalah Obstetri dan Ginekologi Vol. 30 No. 1 \(2022\): April 32-35](#)

 2022  [DOI: 10.20473/mog.V30I12022.32-35](#)  [Accred : Sinta 2](#)

[Front Matter Vol. 30 No. 1 April 2022](#)

[Universitas Airlangga](#)  [Majalah Obstetri & Ginekologi Vol. 30 No. 1 \(2022\): April](#)

 2022  [DOI: 10.20473/mog.V30I12022.%p](#)  [Accred : Sinta 2](#)

[Back Matter Vol. 30 No. 1 April 2022](#)

[Universitas Airlangga](#)  [Majalah Obstetri & Ginekologi Vol. 30 No. 1 \(2022\): April](#)

 2022  [DOI: 10.20473/mog.V30I12022.%p](#)  [Accred : Sinta 2](#)

[View more ...](#)