



## Source details

### International Journal of Surgery Case Reports

Scopus coverage years: from 2010 to Present

Publisher: Elsevier

ISSN: 2210-2612

Subject area: [Medicine: Surgery](#)

Source type: Journal

[View all documents >](#)

[Set document alert](#)

[Save to source list](#) [Source Homepage](#)

CiteScore 2022

1.0



SJR 2022

0.193



SNIP 2022

0.580



[CiteScore](#) [CiteScore rank & trend](#) [Scopus content coverage](#)

#### i Improved CiteScore methodology



CiteScore 2022 counts the citations received in 2019-2022 to articles, reviews, conference papers, book chapters and data papers published in 2019-2022, and divides this by the number of publications published in 2019-2022. [Learn more >](#)

CiteScore 2022

$$1.0 = \frac{3,869 \text{ Citations 2019 - 2022}}{4,033 \text{ Documents 2019 - 2022}}$$

Calculated on 05 May, 2023

CiteScoreTracker 2023

$$0.8 = \frac{3,107 \text{ Citations to date}}{3,904 \text{ Documents to date}}$$

Last updated on 07 June, 2023 • Updated monthly

### CiteScore rank 2022

Category	Rank	Percentile
Medicine		
Surgery	#325/495	34th

[View CiteScore methodology >](#) [CiteScore FAQ >](#) [Add CiteScore to your site](#)

---

## About Scopus

[What is Scopus](#)

[Content coverage](#)

[Scopus blog](#)

[Scopus API](#)

[Privacy matters](#)

## Language

[日本語版を表示する](#)

[查看简体中文版本](#)

[查看繁體中文版本](#)

[Просмотр версии на русском языке](#)

## Customer Service

[Help](#)

[Tutorials](#)

[Contact us](#)

---

## ELSEVIER

[Terms and conditions ↗](#) [Privacy policy ↗](#)

Copyright © Elsevier B.V ↗. All rights reserved. Scopus® is a registered trademark of Elsevier B.V.


We use cookies to help provide and enhance our service and tailor content. By continuing, you agree to the use of cookies ↗.



# International Journal of Surgery Case Reports

Open access

Submit your article 


Guide for authors 


 Menu

 Search in this journal

## Volume 86

September 2021


 Download full issue

 Previous vol/issue

Next vol/issue 

Receive an update when the latest issues in this journal are published

 Sign in to set up alerts

 Open access

Editorial Board

Article 106394


 View PDF


Case Reports

FEEDBACK 

# International Journal of Surgery Case Reports

Open access

Submit your article 

Guide for authors 

 Menu



Case report ● Open access

## Transduodenal surgical ampullectomy for intra-ampullary papillary tubular neoplasm (IAPN): A case report

Susan Pradhan, Krishna Mohan Adhikari, Romi Dahal, Sumita Pradhan, Ramesh Singh Bhandari  
Article 106253



[View PDF](#)

Article preview 

Case report ● Open access

## Elongated styloid process syndrome with prolongation of the superior cornu of the thyroid cartilage: A case report

Katsuhisa Sekido, Yasushi Hariya, Kie Yamashiro, Michiko Okita, ... Eiji Nakayama  
Article 106283



[View PDF](#)

Article preview 

Case report ● Open access

## First case report of spontaneous perinatal gastric perforation in premature neonate with potter sequence and syndrome

Katherine Lizeth Muñoz-Murillo, Willfrant Jhonnathan Muñoz-Murillo, Urías De Jesús Hernández-López, Laura María Aponte-Ceballos, ... Sabrina Rahman  
Article 106297



[View PDF](#)

Article preview 

Case report ● Open access

## PEComa in the rectum: A case report and review of the literature on epithelioid angiomylipoma

Hee Jin Yeon, Nak Song Sung, Seung Jae Roh, Won Jun Choi, Yong Wook Park  
Article 106301

FEEDBACK 

# International Journal of Surgery Case Reports

Open access

Submit your article [↗](#)

Guide for authors [↗](#)

☰ Menu



Article 106300

 [View PDF](#) Article preview [▼](#)

Case report ● *Open access*

## Laparoscopic repositioning of an aberrant right hepatic artery and hepaticojejunostomy for pediatric choledochal cyst: A case report

Ryuta Masuya, Kina Miyoshi, Kazuhiko Nakame, Atsushi Nanashima, Satoshi Ieiri

Article 106300

 [View PDF](#) Article preview [▼](#)

Case report ● *Open access*

## Epidermolysis bullosa with clinical manifestations of sepsis and pneumonia: A case report

Samira Khanmohammadi, Raheleh Yousefzadeh, Maryam Rashidan, Azam Hajibeglo, Karvan Bekmaz

Article 106258

 [View PDF](#) Article preview [▼](#)

Case report ● *Open access*

## Acute mesenteric arterial thrombosis in severe SARS-Co-2 patient: A case report and literature review

Montserrat Del Carmen Valencia Romero, Adrián Morales Cárdenas, Alberto Briseño Fuentes, Adrian Alberto Salinas Barragán, ... Marisol Tello Jiménez

Article 106307

 [View PDF](#) Article preview [▼](#)

Case report ● *Open access*


## De Garengeot hernia doubly complicated: A case report


Atef Mejri, Ahmed Omry, Khaoula Arfaoui, Jasser Rchidi

FEEDBACK 

# International Journal of Surgery Case Reports

Open access

Submit your article 

Guide for authors 

 Menu



Wais Farda, Mohammad Omar Shaban, Mohammad Salem Sadeq, Hedayatullah Mangal, ... Shogoofa Barakzai

Article 106306



[View PDF](#)

Article preview 

Case report ● *Open access*

## Intermammary breast cancer; the first reported case

Abdulwahid M. Salih, Zhair D. Hammood, Lana R.A. Pshtiwan, Fahmi H. Kakamad, ... Bakhan S. Ali

Article 106223



[View PDF](#)

Article preview 

Case report ● *Open access*

## Primary adenocarcinoma of the appendix presenting with fresh bleeding per rectum: A case report

Baijaeek Sain, Arnab Gupta, Samir Bhattacharya, Radha Raman Mondal, ... Shravasti Roy

Article 106285



[View PDF](#)

Article preview 

Case report ● *Open access*

## Metastatic malignant melanoma of unknown primary site to the brain: A case report

Alex Mremi, Gregory Goodluck, Adnan Sadiq, Jay Lodhia

Article 106311



[View PDF](#)


Article preview 


Case report ● *Open access*

FEEDBACK 

# International Journal of Surgery Case Reports

Open access

Submit your article 

Guide for authors 

 Menu



Case report ● Open access

## Expanding pneumocephalus due to craniofacial fractures: A case report

Mendy Hatibie Oley, Maximillian Christian Oley, Eko Prasetyo, Andreas Suwito, Muhammad Faruk

Article 106314



[View PDF](#)

Article preview 

Case report ● Open access

## Postoperative subcutaneous emphysema following percutaneous nephrolithotomy: A rare complication

Hussam Uddin Soomro, Isaac Mawalla, Shabbir Adamjee, Nadeem Kassam, Athar Ali

Article 106310



[View PDF](#)

Article preview 

Case report ● Open access

## Trichoblastoma mimicking basal cell carcinoma and the approach to its management: Case report

Nadeen Al Mushcab, Raja Husain, Mohammad Al Subaiei, Ayedh Al Qarni, ... Mohammad Al Duhileb

Article 106318



[View PDF](#)

Article preview 

Case report ● Open access

## Large expanding splenic pseudocyst: A case report and review of literature

Bakhos Alhaddad, Abdul Azim Hussain, Haitham Al-Rawi, Rafif Mahmood Al Saady

Article 106317




[View PDF](#)


Article preview 

FEEDBACK 

# International Journal of Surgery Case Reports

Open access

Submit your article 

Guide for authors 

 Menu



Case report ● Open access

## Left atrial reverse remodeling improves sinus restoration following mitral valve replacement: A case report

Jayarasti Kusumanegara, Muhammad Nuralim Mallapasi, Peter Kabo, Umar Usman, ... Muhammad Faruk  
Article 106305



[View PDF](#)

Article preview 

Case report ● Open access

## Considerations in spontaneous quadriceps tendon rupture repair in end-stage renal disease patients: A case report

Franky Hartono, Karina E. Besinga, Hendra Tjie, Daniel Marpaung, ... Nicholas Gabriel H.R  
Article 106298



[View PDF](#)

Article preview 

Case report ● Open access

## A human tail arising from the anal mucocutaneous junction: A case report

Hussein Ibrahim, Ahmed Maher, Hesham Fayek Fouad, Tarek Abdelazeem Sabra  
Article 106228



[View PDF](#)

Article preview 

Case report ● Open access

## Intra-articular leiomyoma of the knee mimicking a ganglion cyst in a child: A case report and review of literature

Karim Khezami, Ahmed Gharbi, Emir Bassalah, Salim Jaafar, ... Mohamed Amine Bennour  
Article 106320



[View PDF](#)

Article preview 

FEEDBACK 



# International Journal of Surgery Case Reports

Open access

Submit your article ↗

Guide for authors ↗

Menu



View PDF Article preview ▾

Case report ● Open access

## 9-step magnetic assisted conversion from sleeve gastrectomy to roux-en-Y gastric bypass and hiatoplasty by single-port: Case report

Borjas Guillermo, Sánchez Nestor, Gonzalez Maria, Urdaneta Ali, ... Maldonado Andres

Article 106294

View PDF Article preview ▾

Case report ● Open access

## Rare glomus tumor formation following trauma to the first digit

Mohammad Saba, Austin Moser, Joshua Rosenberg, Jian-Hua Qiao, Gary Chen

Article 106324

View PDF Article preview ▾

Case report ● Open access

## Retroperitoneal unicentric Castleman's disease—A case report and review of literature

Rashpal Singh, Rizul Prasher, Shivek Mohan, Bharat Thakur

Article 106325

View PDF Article preview ▾

Case report ● Open access

## Gallstone ileus associated with cholecystogastric fistula: Case report, diagnosis and surgical treatment


Juan Eduardo Rios Rodriguez, Ana Elisa de Landa Moraes Teixeira Grossi, Victor Ripardo Siqueira, Josias Torres de Siqueira Filho, ... Decius Guimarães Carneiro da Cunha


Article 106328

FEEDBACK

# International Journal of Surgery Case Reports

Open access

Submit your article 

Guide for authors 

 Menu



Article 106304



[View PDF](#)

Article preview 

Case report ● *Open access*

Water clear cell ectopic non-iatrogenic giant parathyroid adenoma in sternohyoid muscle with thyroid nodule and asymptomatic hypercalcemia due to primary hyperparathyroidism: Case report and literature review

Walla Mohamed, Walid El Ansari, Mohamed S. Al Hassan, Rayan M. Sibira, Abdelrahman Abusabeib  
Article 106295



[View PDF](#)

Article preview 

Case report ● *Open access*

Cryptorchidism as an obscure cause of adhesive small bowel obstruction in an adult, a case report

Savni Satoskar, Sarang Kashyap, Joshua Ziehm, Francisco Benavides, ... Vinay Singhal  
Article 106319



[View PDF](#)

Article preview 

Case report ● *Open access*

Reversal of unstable atrial fibrillation after surgical correction of hiatus hernia: A case report

João Paulo Venancio de Carvalho, Luca Giovanni Antonio Pivetta, Eduardo Rullo Maranhão Dias, Pedro de Souza Lucarrelli Antunes, ... Sergio Roll  
Article 106316



[View PDF](#)


Article preview 


Case report ● *Open access*

FEEDBACK 

# International Journal of Surgery Case Reports

Open access

Submit your article 

Guide for authors 

 Menu



Case report ● Open access

## Tocilizumab in SARS-COVID19 following postoperative laparoscopic transhiatal esophagectomy for the adenocarcinoma of esophagogastric tumor: A case report

Flavio Roberto Takeda, Renan Rosetti Muniz, Silvia Moulin Ribeiro Fonseca, Alexandre de Matos Soeiro, ...  
Marcelo Nóbrega Litvoc

Article 106343



[View PDF](#)

Article preview 

Case report ● Open access

## Transnasal endoscopic neochoanal technique: An effective procedure for bilateral choanal atresia in adult female

Budi Sutikno, Muhammad Thaufiqurrakhman

Article 106338



[View PDF](#)

Article preview 

Case report ● Open access

## Unusual longstanding intrabronchial foreign body masquerading as intractable bronchial asthma in an adult: Case report and literature review

Zephania Saitabau Abraham, Faustine Bukanu, Olivia Michael Kimario, Aveline Aloyce Kahinga

Article 106340



[View PDF](#)

Article preview 

Case report ● Open access

## Pterygopalatine fossa schwannoma—case report and literature review

Wendell Dwarika, Shivanand A. Maharaj


Article 106312




[View PDF](#)

Article preview 

FEEDBACK 

Submit your article 

Guide for authors 

 Menu



Case report ● *Open access*

## Bilateral sciatic hernias in an elderly woman successfully managed with robotic surgery: A case report and literature review

Francine Zeng, Brian Shames, Elizabeth Appel, Niranjana Varalakshmi, ... Narinder Maheshwari  
Article 106333



[View PDF](#)

Article preview 

Case report ● *Open access*

## Saving diabetic foot ulcers from amputation by surgical debridement and maggot therapy: A case report

Kazem Hajimohammadi, Naser Parizad, Amireh Hassanpour, Rasoul Goli  
Article 106334



[View PDF](#)

Article preview 

Case report ● *Open access*

## Lotus petal flap for unusual indication: A recto-vaginal fistula with perineal defect after vaginal delivery

Ramzi Arfaoui, Mohamed Aymen Ferjaoui, Slim Khedhri, Kais Abdessamia, ... Khaled Neji  
Article 106337



[View PDF](#)

Article preview 

Case report ● *Open access*


## Retro-odontoid pseudotumor concomitant with proximal adjacent cervical spondylotic myelopathy after multilevel anterior cervical discectomy and fusion


Wongthawat Liawrungrueang, Waroon Tantivorawit, Nantawit Sugandhavesa, Torphong Bunmaprasert  
Article 106352

FEEDBACK 

# International Journal of Surgery Case Reports

Open access

Submit your article 

Guide for authors 

 Menu



Dhansha Ghartimajari, Manish Kiran Shrestha, Anub Ghosh, Kamrula Eshat Kuwanpatirana, Sudeep

Regmi

Article 106345



[View PDF](#)

Article preview 

Case report  Open access

## Early neonatal lobectomy for ILE; is it feasible?

Jayalaxmi Shripati Aihole

Article 106351



[View PDF](#)

Article preview 

Case report  Open access

## Long-term follow-up after arthroplasty for pediatric temporomandibular joint ankylosis performed before the critical period of mandibular growth: A case report

Yasuhiro Kurasawa, Hiroyuki Yoshitake, Nobuyoshi Tomomatsu, Tetsuya Yoda

Article 106330



[View PDF](#)

Article preview 

Case report  Open access

## Mucormycosis-unusual cause of lower GI bleeding: A rare case report

Gyaneswhor Shrestha, Narendra Maharajan, Sumita Pradhan, Ramesh Singh Bhandari

Article 106313



[View PDF](#)

Article preview 

Case report  Open access


## A case of cervico-mediastinal paraganglioma mimicking an ectopic goiter


Daniel Bianchi, Adriana Scamporlino, Matteo Costantini, Giorgio Cavallesco, ... Alessandro Stefani

FEEDBACK 

# International Journal of Surgery Case Reports

Open access

Submit your article 

Guide for authors 

 Menu



Tomoyuki Sugi, Yohei Owada, Tsuyoshi Enomoto, Yusuke Ohara, ... Tatsuya Oda

Article 106331



[View PDF](#)

Article preview 

Case report  *Open access*

A case report of non-functional ectopic left kidney obstructing the right kidney in crossed fused kidneys: A rare entity

Amine Hermi, Mokhtar Bibi, Kheireddine Mrad Dali, Housseem Hadj Alouane, ... Yassine Nouira

Article 106321



[View PDF](#)

Article preview 

Case report  *Open access*

Sigmoid colon strangulation caused by bilateral fallopian tubes: A case report

Yuto Igarashi, Katsunori Miyake, Naoko Isogai, Rai Shimoyama, ... Jun Kawachi

Article 106329



[View PDF](#)

Article preview 

Case report  *Open access*

Co-occurrence of bilateral intrathyroidal parathyroid gland and papillary thyroid carcinoma; a case report

Ari M. Abdullah, Hiwa O. Baba, Abdulwahid M. Salih, Aras J. Qaradakh, ... Shvan H. Mohammed

Article 106315



[View PDF](#)

Article preview 

Case report  *Open access*

Pneumocephalus secondary to a spinal surgery: A literature review and a case report

Osama J. Abu-Hamdiyah, Sarah Al Sharie, Sajeda Awadi, Almu'atasim Khamees, Moham

FEEDBACK 

# International Journal of Surgery Case Reports

Open access

Submit your article [↗](#)

Guide for authors [↗](#)

Menu



Nguyen Anh Tuan, Nguyen Van Du, Pham Van Hiep

Article 106326



[View PDF](#)

Article preview [▼](#)

Case report ● *Open access*

## Robot-assisted thoracoscopic esophagectomy for gastrointestinal stromal tumor of the esophagus: A case report

Hiroyuki Yamamoto, Yuma Ebihara, Kimitaka Tanaka, Aya Matsui, ... Satoshi Hirano

Article 106335



[View PDF](#)

Article preview [▼](#)

Case report ● *Open access*

## Invasive giant pancreatic desmoid-type fibromatosis with curative resection: A case report

Hanan M. Alghamdi

Article 106327



[View PDF](#)

Article preview [▼](#)

Case report ● *Open access*

## A Case Report: Hepatic artery pseudoaneurysm causing life-threatening haemobilia

J. Shelton, S. Raviraj

Article 106350



[View PDF](#)

Article preview [▼](#)

Case report ● *Open access*

## Candy cane syndrome at jejunojejunostomy causing small bowel obstruction following revisional laparoscopic gastric bypass: A case report and review of literature

Mohammad Almayouf, Srikar Billa, Awadh Alqahtani

FEEDBACK

# International Journal of Surgery Case Reports

Open access

Submit your article [↗](#)

Guide for authors [↗](#)

Menu



Reza Afghani, Hadi Gharib, Farhad Kor, Pezhman Kharazm

Article 106361



[View PDF](#)

Article preview [▼](#)

Case report ● *Open access*

## Pulmonary sequestration presenting as a massive haemoptysis in adult: A case report

Lokesh Shekher Jaiswal, Durga Neupane

Article 106341



[View PDF](#)

Article preview [▼](#)

Case report ● *Open access*

## One-stage sex reassignment surgery at the delayed presentation in a patient with partial androgen insensitivity syndrome: A case report

Pham Thi Viet Dung, Tran Thiet Son, Phan Van Tan

Article 106355



[View PDF](#)

Article preview [▼](#)

Case report ● *Open access*

## Case report of a primary subcutaneous melanoma; a surprising entity for a subcutaneous nodule

E. Jutten, M.F. Lutke Holzik, A. Baidoshvili, R.R. Dulfer

Article 106359



[View PDF](#)

Article preview [▼](#)

Case report ● *Open access*


## Tendon transfer for dysfunction of all tendons in leg excepting Achilles tendon and plantaris tendon following irreparable sciatic nerve palsy – A case report


FEEDBACK



# International Journal of Surgery Case Reports

Open access

Submit your article 

Guide for authors 

 Menu



Jason Liarto, Kuncoro Adi

Article 106358



[View PDF](#)

Article preview 

Case report ● *Open access*

## Case report: A rare cause of chest pain: Kommerell's diverticulum

Syed Muhammad Azeem, Umer Arif, Raziullah Baig, Mohammad Iqbal Khan

Article 106323



[View PDF](#)

Article preview 

Case report ● *Open access*

## Bartholin's gland abscess a rare cause of rectovaginal fistula: A case report and literature review

F.Z. Bensardi, S. KABURA, ElAttar Layla, A. El Bakouri, ... A. Fadil

Article 106344



[View PDF](#)

Article preview 

Case report ● *Open access*

## Hydromediastinum and hydrothorax as delayed complications of peripherally inserted central catheter used for total parenteral nutrition: A case report

Julian Chica, Natalia P. Ballén, Kelly J. Aguillon, Saul J. Rugeles

Article 106247



[View PDF](#)

Article preview 


Case report ● *Open access*


## Bifid rib with fused vertebrae - A rare abnormality of the skeletal system: A case report

FEEDBACK 

# International Journal of Surgery Case Reports

Open access

Submit your article 

Guide for authors 

 Menu



Freddy Houéhanou Rodrigue Gnangnon, Yacoubou Imorou Souaibou, Dansou Gaspard Gbessi, Tiani Marie Gaston Agbo, ... Delphin Kuassi Méhinto  
Article 106234



[View PDF](#)

Article preview 

Case report ● *Open access*

## Splenic flexure volvulus, a rare etiology of colonic obstruction: Case report

Amirsina Sharifi, Seyed Mohsen Ahmadi Tafti, Mohammadreza Keramati, Alireza Kazemeini, Behnam Behboudi  
Article 106128



[View PDF](#)

Article preview 

Case report ● *Open access*

## Urinoma following blunt renal trauma in a patient with anomalous solitary kidney: A case report

Mitesh Karn, Dipendra Kandel, Basant Kumar Mahato, Sudip Thapa, Hari bahadur KC  
Article 106386



[View PDF](#)

Article preview 

Case report ● *Open access*

## Non-oncologic indication for elbow megaprosthesis replacement: 2 cases report

Dung Tran Trung, Quyet Tran, Nam Vu Tu, Sang Nguyen Tran Quang, ... Hieu Pham Trung  
Article 106356



[View PDF](#)

Article preview 

Case report ● *Open access*

FEEDBACK 

# International Journal of Surgery Case Reports

Open access

Submit your article ↗

Guide for authors ↗

Menu



Case report ● Open access

## Peritonectomy of the colonic mesentery. Case report of a new surgical technology

Paul H. Sugarbaker

Article 106369



View PDF

Article preview ▾

Case report ● Open access

## A case report of post-surgical page kidney due to extensive renal hematoma following percutaneous nephrolithotomy

Meganathan Sivashankar, B. Balagobi, Neville D. Perera, Palehepitiya Gamage Nalin Ruvinda

Article 106382



View PDF

Article preview ▾

Case report ● Open access

## Treatment of duodenal lipoma with robotic-assisted transverse duodenotomy: A case report of novel approach

Logan D. Glosser, Conner V. Lombardi, Hanna M. Knauss, Wade Hopper, ... Stephen Stanek

Article 106366



View PDF

Article preview ▾

Case report ● Open access

## Redo aortic valve replacement due to early structural valve deterioration in a trileaflet valve: A case report

Tatsuya Watanabe, Noriyuki Tokunaga, Keita Maruno, Hideo Yoshida, Masahiko Kuinose

Article 106381



View PDF

Article preview ▾

FEEDBACK

# International Journal of Surgery Case Reports

Open access

Submit your article [↗](#)

Guide for authors [↗](#)

Menu



View PDF Article preview [▼](#)

Case report ● Open access

## The importance of early detection for postoperative maxillary cyst before dental implantation: A case report

Tatsuo Funakawa, Hitoshi Kawanabe, Akinobu Usami, Keiso Takahashi, ... Yuh Baba

Article 106370

View PDF Article preview [▼](#)

Case report ● Open access

## Thyroid hemigenesis associated with Hurthle cell carcinoma: A case report

Diani Kartini, Sonar Soni Panigoro, Maria Fransisca Ham, Agnes Stephanie Harahap, ... Kevin Varian Marceviando

Article 106372

View PDF Article preview [▼](#)

Case report ● Open access

## A pathological perspective to painful inguinal hernia: Report of two cases

Masato Narita, Koki Moriyoshi, Kentaro Goto, Ryoya Yamaoka, Takashi Yamaguchi

Article 106389

View PDF Article preview [▼](#)

Case report ● Open access

## Duodenal teratoma: Rare case of extragonadal germ cell tumors and review of literature

Bilal Chamaa, Jad Terro, Mostapha Mneimneh, Sirage Edris, Etienne El-Helou

Article 106377

View PDF Article preview [▼](#)

FEEDBACK

# International Journal of Surgery Case Reports

Open access

Submit your article [↗](#)

Guide for authors [↗](#)

Menu



[View PDF](#) [Article preview](#) [▼](#)

Case report ● Open access

## Amyand's hernia a case report

Hina Khalid, Naveed Ali Khan, Munira Abdul Aziz

Article 106332



[View PDF](#)

[Article preview](#) [▼](#)

Case report ● Open access

## Unusual combination of posterior cruciate ligament tibial avulsion fracture and Second fracture: A case report

Krisna Yuarno Phatama, Albert Lesmana, Felix Cendikiawan, Ananto Satya Pradana, ... Mohamad Hidayat

Article 106380



[View PDF](#)

[Article preview](#) [▼](#)

Case report ● Open access

## Dorsalis pedis artery pseudoaneurysm: A rare entity in the field of vascular surgery

Mohammed Dahman, Yara Alhomaidi, Meshare Albattah, Abdulaziz A. Howil, ... Nahar Alenazi

Article 106302



[View PDF](#)

[Article preview](#) [▼](#)

## Case Series

---

Mini review ● Open access


## The importance of medical treatment before surgery in pleomorphic carcinoma of the lung: A case series study


Francesco Tormen, Federico Banchelli, Valentina Masciale, Antonino Maiorana, ... Beatrice

FEEDBACK

# International Journal of Surgery Case Reports

Open access

Submit your article 

Guide for authors 

 Menu



A. El Karouachi, A. Hajri, S.R. El Jai, D. Erguibi, ... F. Chehab

Article 106322



[View PDF](#)

Article preview 

Mini review ● *Open access*

Synchronous presentation of acute cholecystitis and acute appendicitis successful treatment in one step laparoscopic procedure. A case series and literature review

Seyed Mohammad Nahidi, Khuram Khan, Christopher Engler, Sharang Tickoo, Carina Biggs

Article 106296



[View PDF](#)

Article preview 

Mini review ● *Open access*

Endovascular embolization for cases of 'hidden' pediatric cerebral arteriovenous malformations: A diagnostic & therapeutic challenge

Muhammad Arifin Parenrengi, Wihasto Suryaningtyas, Joandre Fauza

Article 106347



[View PDF](#)

Article preview 

Mini review ● *Open access*

Surgical procedures for correcting vertical maxillary excess: A review

Nisrina Ekayani Nasrun, Shigehiro Takeda, Yasuhito Minamida, Daichi Hiraki, ... Tsuyoshi Shimo

Article 106354



[View PDF](#)

Article preview 

Mini review ● *Open access*

Pelvic actinomycosis: A confusing diagnosis

Mohamed Aymen Ferjaoui, Ramzi Arfaoui, Slim Khedhri, Mohamed Amine Hannechi, ...

FEEDBACK 

# International Journal of Surgery Case Reports

Open access

[Submit your article ↗](#)

[Guide for authors ↗](#)

☰ Menu



Atsushi Nanashima, Yukinori Tanoue, Naoya Imamura, Masahide Hiyoshi, ... Takeshi Nagayasu

Article 106384



[View PDF](#)

[Article preview](#) ▾



ELSEVIER

Copyright © 2023 Elsevier B.V. or its licensors or contributors.  
ScienceDirect® is a registered trademark of Elsevier B.V.

RELX™

ISSN: 2210-2612

Copyright © 2023 IJS Publishing Group Ltd. Published by Elsevier Ltd. All rights reserved

FEEDBACK



ScienceDirect®

# International Journal of Surgery Case Reports

Open access

1

CiteScore

[Submit your article ↗](#)[Guide for authors ↗](#)[Menu](#)[Search in this journal](#)[> Aims and scope](#)[> Editorial board](#)[> News](#)

## Editorial board by country/region

79 editors and editorial board members in 29 countries/regions

1 United States of America (16)

2 United Kingdom (14)

3 India (12)

[> See more editors by country/region](#)

## Editorial board

[FEEDBACK](#)



## Editor-in-Chief

David Rosin, MBBS, FRCS(edin) & FRCS (eng), MS

Bridgetown, Barbados

## Managing and Executive Editor

Riaz Agha, BSc, MBBS, M.Sc., D.Phil, FHEA, FRSA, FRSPH, FRCS, FEBOPRAS

London, United Kingdom

## Senior Editors

R.Y. Afifi

Cairo, Egypt

H. B. Alam

Ann Arbor, United States of America

J. P. Barret

Barcelona, Spain

B. Challacombe

London, United Kingdom

X-P. Chen

Wuhan, China

R.L. De Wilde

Oldenburg, Germany

B. Ekser

Indianapolis, United States of America

H.B. Hechtman

Boston, United States of America

J. W. Y. Lau

Hong Kong, Hong Kong

O. Muensterer

Mainz, Germany

S. Rogers

Chicago, United States of America

J. Talati

Karachi, Pakistan

M. Thorat

London, United Kingdom

F.C. Wei

Taoyuan, Taiwan

## Associate Editors

R. Coppola

Roma, Italy

V. Kasivisvanathan

London, United Kingdom

R Keijzer

Winnipeg, Canada

B Kirshtein

Be'er Sheva, Israel

J.A. McCaul

Bradford, United Kingdom

E.R. McGlone

London, United Kingdom

D. Muzumdar

Mumbai, India

A Petroianu

BELO HORIZONTE, Brazil

S.G. Raja

London, United Kingdom

K Raveendran

Ipoh, Malaysia

D. Yeh

Boston, United States of America

## Assistant Editors

R. Al-mahfoudh

Oxford, United Kingdom

H. M. Atta

Boston, Massachusetts, United States of America

M. Bashashati

Calgary, Texas, Canada

S. Basu

Varanasi, India

A.J. Beamish

Göteborg, Sweden

A. G. Charles

Chapel Hill, North Carolina, United States of America

A. Das

Mohanpur, India

M.E. Erdil

İstanbul, Turkey

S. A. Esquivel Gaón

Ciudad de México, Mexico

S. Feng

Shanghai, China

J. Gómez Rivas

Madrid, Spain

H. Kaafarani

Boston, Massachusetts, United States of America

Y. D. Kamat

Mangaluru, India

O. Khan

London, United Kingdom

T. Manning

Heidelberg, Victoria, Australia

I. Mukherjee

Staten Island, Florida, United States of America

E Ofo

Adelaide, South Australia United Kingdom

S. Pai

Mumbai, India

L. Perger

Albuquerque, New Mexico, United States of America

A. Smailys

Kaunas, Lithuania

D.G. Weber

Perth, Australia

H. Zhu

Shanghai, China

## Statistical Editors

N. Donaldson, B.Sc., M.Sc., Ph.D.

Cali, Colombia

M.W. Gray, Ph.D., J.D.

Washington DC, District of Columbia, United States of America

## Society Representatives

J. Burke, BSc (Hons) MBChB MRCS PGCert

President of the Association of Surgeons in Training United Kingdom

X-P. Chen, M.D., Ph.D.

President of the Chinese Chapter of International Hepato-Pancreato-Biliary Association, Hubei, China

Coppa, M.D., Ph.D.

President of the New York Surgical Society, New York, United States of America

## Executive Committee

Dr. G. Catto

London, UK

Professor D.K.C Cooper

Pittsburgh, United States of America

general surgery, heart surgery

Professor A. Darzi

London, United Kingdom

colorectal surgery

Professor H. Ellis

London, United Kingdom

general surgery

Dr. B. Jackson

London, UK

Professor C.-H. Leong

Hong Kong, Hong Kong

urology, nephrology

Dr. A.K-C. Li

Hong Kong, China

general surgery

Dr. I. McColl

London, United Kingdom

general surgery

Professor J. Norcini

Philadelphia, United States of America

no specialty

Professor S. Standing

London, UK

Lord R. Winston

London, United Kingdom

Em. Professor M. Yacoub

London, United Kingdom

Cardiothoracic Surgery, Transplantation, Congenital Cardiac Surgery, Chain of Hope

## Editorial Board

R. A. Badwe

Mumbai, India

M. Boscoe

Uxbridge, United Kingdom

R. Bueno

Boston, Massachusetts, United States of America

K. Chatamra

Bangkok, Thailand

P. Coulthard

Manchester, United Kingdom

FEEDBACK 



A. d'Cruz

Mumbai, India

M. Desai

Mumbai, India

W. Green

London, United Kingdom

I. Harirchi

Tehran, Iran

D. Henne-Bruns

Ulm, Germany

D. Kahn

Cape Town, South Africa

X. Lin

Shanghai, China

A. Mahapatra

New Delhi, India

I. Mittra

Mumbai, India

V. Naraynsingh

West Indies, Trinidad and Tobago

F. Nicoli

London, United Kingdom

A. Núñez De Pierro

Buenos Aires, Argentina

R. Orda

Tel Aviv, Israel

V. Semiglazov

St Petersburg, Russian Federation

T. Singh

Ludhiana, India

B.L. Smith

Boston, Massachusetts, United States of America

T.E. Udwardia

Mumbai, India

M. C. Warlé

Nijmegen, Netherlands

J. Wee

Boston, Massachusetts, United States of America

M. Weiser

New York, New York, United States of America

Z.F. Xia

Shanghai, China

Y. Zhang

Shanghai, China

J Zhong

Shanghai, China

All members of the Editorial Board have identified their affiliated institutions or organizations, along with the corresponding country or geographic region. Elsevier remains neutral with regard to any jurisdictional claims.



Copyright © 2023 Elsevier B.V. or its licensors or contributors.  
ScienceDirect® is a registered trademark of Elsevier B.V.





## Case report

# Transnasal endoscopic neochoanal technique: An effective procedure for bilateral choanal atresia in adult female

Budi Sutikno<sup>\*</sup>, Muhammad Thaufiqurrakhman

Department of Otorhinolaryngology Head and Neck Surgery, Faculty of Medicine, Universitas Airlangga – Dr. Soetomo General Academic Hospital, Surabaya, Indonesia



## ARTICLE INFO

## Keywords:

Choanal atresia in adult  
Human and disease  
Stenosis  
Transnasal endoscopic neochoanal technique

## ABSTRACT

**Background:** Surgery on bilateral choanal atresia surgery is challenging and this case is rare in adults. In addition, stenosis issue postoperatively is commonly seen.

**Case presentation:** Transnasal endoscopic neochoanal technique was performed on a 27 years old female with the detailed surgical procedure was described. Neither stent nor nasal tamponade was applied. Ten months follow-up revealed a patent-wide neochoanae.

**Discussion:** Transnasal endoscopic neochoanal technique without stent and nasal tamponade can be considered the procedure of choice in the management of CA cases.

**Conclusions:** Transnasal endoscopic neochoanal technique is considered an effective surgical procedure on bilateral choanal atresia.

## 1. Introduction

Choanal atresia (CA) is a rare congenital anomaly that fails in communication between the nasal cavity and nasopharynx. It occurs in 1:8000 of live births, more prevalent in women than men, 2:1 respectively. Choanal atresia is classified based on unilateral (41%) and bilateral (59%), bony type (90%), and membranous type (10%) with various degrees of stenosis. Bony type of CA is due to thickened vomer and medialization of the pterygoid plate of the sphenoid bone. Around 41–72% of CA cases are a part of CHARGE syndrome consisting of coloboma, heart defects, choanal atresia, retarded growth and development, genital hypoplasia, ear anomalies, and deafness [1].

The majority of CA cases are found in infants [2], where as adults case is very rare [3,4]. New CA cases found in adults are related to socioeconomic factors in the family which are often found in low resource settings [3–5]. The transnasal endoscopic neochoanal technique is an effective technique for the management of CA cases [6,7]. Based on the Surgical CAse REport (SCARE) 2020 Guidelines [8], we are interested in reporting cases of CA in adults who underwent a modified transnasal endoscopic neochoanal technique.

## 2. Case presentation

A 27-year-old female complained of both nasal blockages since birth. Smell impairment, snoring, and mouth breathing accompanied the main symptom. There was no history of breathing support whilst delivered but encountered exhaustion especially on breastfeeding episodes relieved with crying. A saddle nose was noticed on examination. A preoperative nasoendoscopy revealed a different level of nasal floors (higher level of the right nasal floor), blocked choanae with spacious, normal inferior turbinates, and no deviated nasal septal (Fig. 1). Pre-operative paranasal sinus CT scan findings supported a bilateral bony type of CA with some degree of stenosis (Fig. 2).

Surgery was performed under general anesthesia. The patient was positioned supine and reverse Trendelenburg 20 degrees. Had the disinfection done, the nasal cavity was prepared with gauze soaked in oxymetazoline 0.05% and lidocaine 1%. The procedure began with an incision on the anterior mucosal surface of the left atretic area up to the vomer. A mucosal flap was created following the incision line to cover the incision wound and the exposed bone in the end of procedure. The atretic bone removal was performed up to vomer (posterior septectomy) by Kerrison rongeur and osteotome. The same procedure was performed on the contralateral side. A wide neochoanae was created (Fig. 3). Surgicel® was applied to ensure hemostasis. No nasal tamponade nor

<sup>\*</sup> Corresponding author at: Department of Otorhinolaryngology Head and Neck Surgery, Faculty of Medicine, Universitas Airlangga – Dr. Soetomo General Academic Hospital, Jl. Mayjend Prof. Dr. Moestopo No. 6-8, Airlangga, Gubeng, Surabaya, East Java 60286, Indonesia.

E-mail addresses: [budi-s@fk.unair.ac.id](mailto:budi-s@fk.unair.ac.id), [budisutikno104@gmail.com](mailto:budisutikno104@gmail.com) (B. Sutikno).

<https://doi.org/10.1016/j.ijscr.2021.106338>

Received 3 July 2021; Received in revised form 19 August 2021; Accepted 21 August 2021

Available online 24 August 2021

2210-2612/© 2021 The Authors. Published by Elsevier Ltd on behalf of IJS Publishing Group Ltd. This is an open access article under the CC BY-NC-ND license

(<http://creativecommons.org/licenses/by-nc-nd/4.0/>).

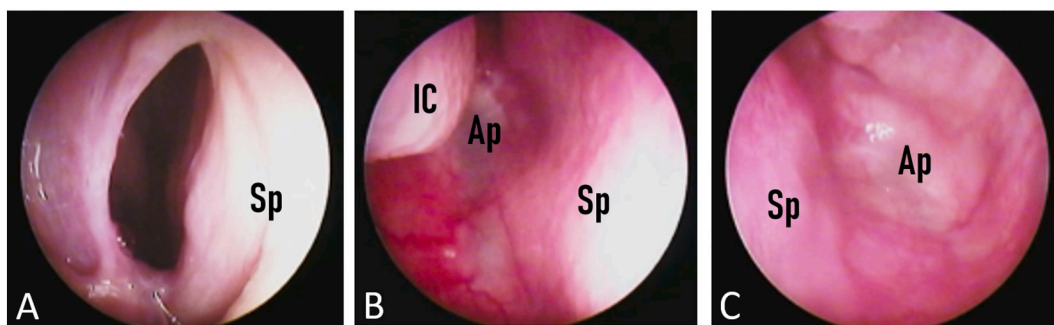


Fig. 1. Right (A, B) and left (C) nasal cavities showed bilateral choanal atresia. IC (inferior concha), Sp (septum), Ap (atretic plate).

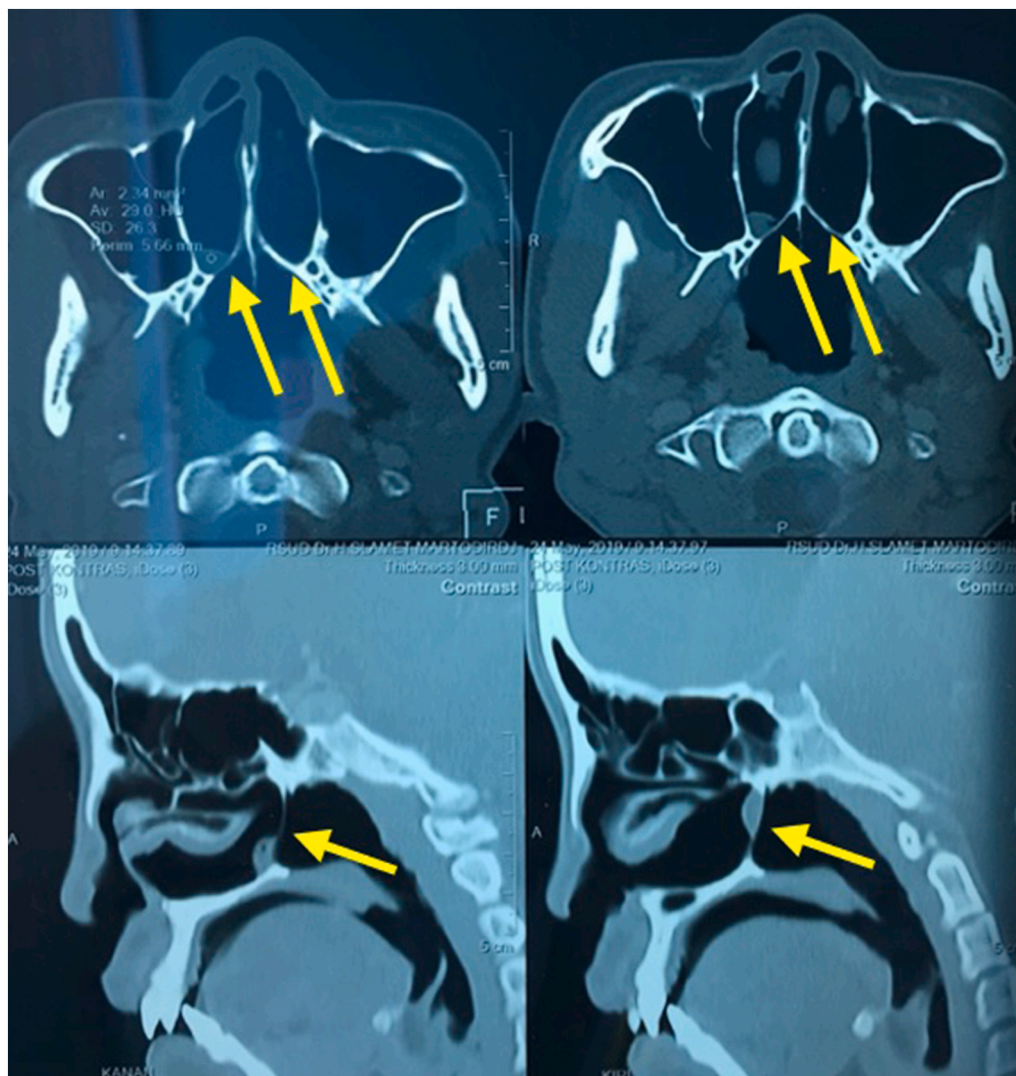


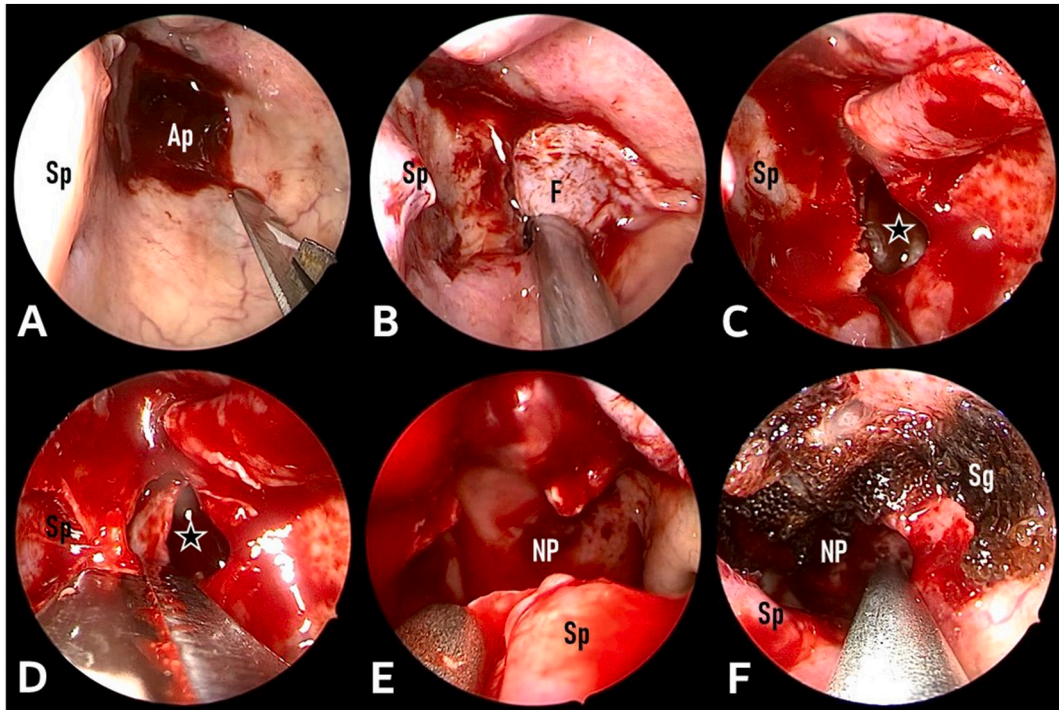
Fig. 2. A paranasal sinus CT scan revealed a bony type bilateral choanal atresia with some degree of stenosis (yellow arrow). (For interpretation of the references to colour in this figure legend, the reader is referred to the web version of this article.)

stent was applied. The patient was discharged on the following day. Post-operative nasal saline irrigation was delivered as frequently as twice daily for four weeks.

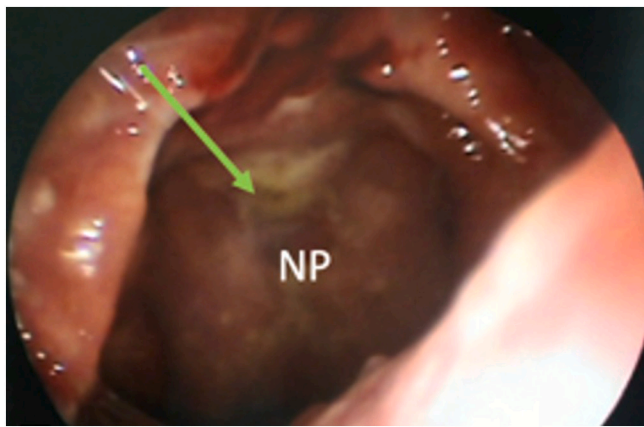
One month postoperative follow-up revealed a patent neochoanae with a good healing process (Fig. 4). The patient began to be able to identify some odorants. Ten months post-operative follow-up revealed no complaint of breathing problem, smell function was back to normal.

### 3. Discussion

Bilateral CA is rarely seen in adults, with only 10 cases reported in the literature [4,5,9,10]. Surgical management of CA consists of transseptal, transpalatal, and transnasal approaches [11]. The first successful surgery on a bony type bilateral CA was carried out by Carl Emmert in 1851 on 7 years old boy through a blind bilateral transnasal puncture with progressive dilatation. This blind technique potentially injured the



**Fig. 3.** Transnasal endoscopic neochoanal technique on bilateral CA began with a mucosal incision on atretic plate area and its surrounding (A), the mucosal flap was created (B), atretic plate opening (\*) (C), posterior septectomy using Kerrison rongeur and osteotome (D), wide neochoane was created (E), Surgicel® was applied to ensure hemostasis (F). Ap (atretic plate), F (mucosal flap), NP (nasopharynx), Sg (Surgicel®), Sp (septum).



**Fig. 4.** One month post-operative revealed patent neochoanae (green arrow). NP (nasopharynx). (For interpretation of the references to colour in this figure legend, the reader is referred to the web version of this article.)

skull base. In 1908, Uffenorder introduced a transseptal approach through a submucous resection to reach the vomer and removed it along with atretic plate removal to create a large uni-neochoanae. This was the first step toward modern CA surgery. Large resection of the growing septum may result in significant developmental anomalies of the face and nose. This old transseptal approach was lack of good visibility since it was not performed endoscopically. The transpalatal approach was proposed in 1937, entailed large exposure of the choanal region, enabling drilling away of the medial pterygoid plates, enlarging the uni-neochoanae. This technique might lead to serious complications such as abundant blood loss which was critical in newborns. Other disadvantages were its effect on maxillary growth causing cross-bite and high palatal arch deformity, palatal fissure, and velopharyngeal insufficiency [12]. The endoscopic technique is currently used widely. Transnasal

endoscopic procedure for CA provides excellent visualization and enables accurate surgery [6,7,11].

The role of the stent is controversial [4,7]. Stentless endoscopic repair reduces the need for frequent postoperative care and also avoids stent-related complications including patient discomfort, a potential nidus for a bacterial colonization that triggers persistent inflammation and fibrosis, and pressure. The recent literature has suggested the benefit of the stent are dubious and the endoscopic procedure for CA can be performed successfully without stenting. Nasal douching during the postoperative period is more helpful for preventing restenosis [13]. Novel application of steroid eluting sinus stent in minimizing scarring following endoscopic procedure for CA show a high level of success. Mitomycin C after choanoplasty is used to prevent stenosis. Of the ten documented cases of adult bilateral CA in literature, only one patient had restenosis and thus requiring a revision surgery [4].

The current surgical approaches for congenital CA should fulfill the requirement of minimally invasive surgery. Five main surgical objectives should be achieved to minimize the tendency for restenosis such as the construction of an as large as possible uni-neochoanae by safely removing the posterior part of the vomer (posterior septectomy) and by drilling away the medial pterygoid plate. In the case of rhinopharyngeal stenosis, part of the endochondral clival bone should be resected, all raw surfaces should be covered by multiple mucosal flaps secured with fibrin, no stent required, and appropriate postoperative care [10].

In communities with low socioeconomic status living in rural areas and far from sufficient health facilities, ante and postnatal history are unidentified. Meanwhile, choanal atresia is a congenital abnormality that should be identified during newborns [14,15]. In addition, in low socioeconomic communities, nutritional intake during pregnancy tends to be poor, which is a risk factor for choanal atresia [16]. Lack of awareness on the signs and symptoms of choanal atresia that appears such as respiratory distress relieved with crying and recurrent upper respiratory infection also plays a role in the delay of diagnosis [17,18].

#### 4. Conclusion

The transnasal endoscopic neochoanal technique is considered an effective procedure to manage bilateral choanal atresia. Low socioeconomic status causes delay in the management of choanal atresia.

#### Consent

We have requested the patient's consent to publish this case report for educational purposes.

#### Guarantor

Budi Sutikno.

#### Provenance and peer review

Not commissioned, externally peer-reviewed.

#### Funding

None.

#### Supplement

<https://www.youtube.com/watch?v=6nbb1zzclnQ&t=23s>

#### Ethical approval

We have conducted an ethical approval base on Declaration of Helsinki at Ethical Committee in Dr. Soetomo General Academic Hospital, Surabaya, Indonesia.

#### Credit authorship contribution statement

All authors contributed toward data analysis, drafting and revising the paper, gave final approval of the version to be published and agree to be accountable for all aspects of the work.

#### Declaration of competing interest

The authors declare that they have no conflict of interest.

#### Acknowledgement

We would like to thank Fis Citra Ariyanto for assisting in editing and proofing.

#### References

- [1] B. Liktör, L.V. Csokonai, I. Gerlinger, A new endoscopic surgical method for unilateral choanal atresia, *Laryngoscope* 111 (2) (2001) 364–366, <https://doi.org/10.1097/00005537-200102000-00033>.
- [2] S.H. Abdul Cader, F.A. Shah, N. Reghunandan, Clinical retrospective analysis of 15 cases of choanal atresia - our experience, *World J. Otorhinolaryngol. Head Neck Surg.* 5 (4) (2019) 188–192, <https://doi.org/10.1016/j.wjorl.2019.03.003>.
- [3] C.D. Durmaz, V. Tas, P. Kocaay, Ö.S. Fitöz, H. Onay, S. Beton, et al., Bilateral choanal atresia in an adult woman with pycnodysostosis, *Congenit. Anomalies* 57 (3) (2017) 91–92, <https://doi.org/10.1111/cga.12204>.
- [4] S. Anajar, J. Hassnaoui, S. Rouadi, R. Abada, M. Roubal, M. Mahtar, A rare case report of bilateral choanal atresia in an adult, *Int. J. Surg. Case Rep.* 37 (2017) 127–129, <https://doi.org/10.1016/j.ijscr.2017.05.002>.
- [5] R.K. Verma, P. Lokesh, N.K. Panda, Congenital bilateral adult choanal atresia undiagnosed until the second decade: how we did it, *Allergy Rhinol.* 7 (2) (2016) 82–84, <https://doi.org/10.2500/ar.2016.7.0155>.
- [6] R. Riepl, M. Scheithauer, T.K. Hoffmann, N. Rotter, Transnasal endoscopic treatment of bilateral choanal atresia in newborns using balloon dilatation: own results and review of literature, *Int. J. Pediatr. Otorhinolaryngol.* 78 (3) (2014) 459–464, <https://doi.org/10.1016/j.ijporl.2013.12.017>.
- [7] G.C. De Vincentiis, M.L. Panatta, E. De Corso, G. Marini, A. Bianchi, M. Giuliani, et al., Endoscopic treatment of choanal atresia and use of balloon dilation: our experience, *Acta Otorhinolaryngol. Ital.* 40 (1) (2020) 44–49, <https://doi.org/10.14639/0392-100x-1567>.
- [8] R.A. Agha, T. Franchi, C. Sohrabi, G. Mathew, A. Kerwan, The SCARE 2020 guideline: updating consensus Surgical CAse REport (SCARE) guidelines, *Int. J. Surg.* 84 (2020) 226–230, <https://doi.org/10.1016/j.ijso.2020.10.034>.
- [9] A. Kars, F. Bingöl, F. Atalay, A rare case report: bilateral choanal atresia in an adult patient, *Eur. J. Rhinol. Allergy* 3 (1) (2020) 26–28.
- [10] E. Tatar, A. Özdek, F. Akcan, H. Korkmaz, Bilateral congenital choanal atresia encountered in late adulthood, *J. Laryngol. Otol.* 126 (9) (2012) 949–951, <https://doi.org/10.1017/s0022215112001442>.
- [11] M.W. El-Anwar, A.A. Nofal, M.A. El-Ahl, Endoscopic repair of bilateral choanal atresia, starting with vomer resection: evaluation study, *Am. J. Rhinol. Allergy* 30 (3) (2016) 95–99, <https://doi.org/10.2500/ajra.2016.30.4321>.
- [12] P. Brihaye, I. Delpierre, A. De Villé, A.B. Johansson, D. Biarent, A.L. Mansbach, Comprehensive management of congenital choanal atresia, *Int. J. Pediatr. Otorhinolaryngol.* 98 (2017) 9–18, <https://doi.org/10.1016/j.ijporl.2017.04.022>.
- [13] E. Tatar, B. Öcal, E. Dogan, Ö. Bayir, C. Saka, A. Özdek, et al., Stentless endoscopic repair of congenital choanal atresia: is it enough for maintaining choanal patency? *Eur. Arch. Oto-rhino-laryngol.* 274 (10) (2017) 3673–3678, <https://doi.org/10.1007/s00405-017-4702-9>.
- [14] V.A. Patel, J. Ramadan, M.M. Carr, Congenital choanal atresia repair: an analysis of adverse perioperative events, *Otolaryngol. Head Neck Surg.* 159 (5) (2018) 920–926, <https://doi.org/10.1177/0194599818797282>.
- [15] J.B. Meleca, S. Anne, B. Hopkins, Reducing the need for general anesthesia in the repair of choanal atresia with steroid-eluting stents: a case series, *Int. J. Pediatr. Otorhinolaryngol.* 118 (2019) 185–187, <https://doi.org/10.1016/j.ijporl.2019.01.004>.
- [16] V. Kancherla, P.A. Romitti, L. Sun, J.C. Carey, T.L. Burns, A.M. Siega-Riz, et al., Descriptive and risk factor analysis for choanal atresia: the National Birth Defects Prevention Study, 1997–2007, *Eur. J. Med. Genet.* 57 (5) (2014) 220–229, <https://doi.org/10.1016/j.ejmg.2014.02.010>.
- [17] A. Merrow, S. Hariharan, *Imaging in pediatrics*, 1st ed., Elsevier, 2017.
- [18] E. Moreddu, M.E. Rossi, R. Nicollas, J.M. Triglia, Prognostic factors and management of patients with choanal atresia, *J. Pediatr.* 204 (2019) 234–239.e1, <https://doi.org/10.1016/j.jpeds.2018.08.074>.