



Source details

International Journal of Surgery Case Reports

Scopus coverage years: from 2010 to Present

Publisher: Elsevier

ISSN: 2210-2612

Subject area: [Medicine: Surgery](#)

Source type: Journal

[View all documents >](#)

[Set document alert](#)

[Save to source list](#) [Source Homepage](#)

CiteScore 2022

1.0



SJR 2022

0.193



SNIP 2022

0.580



[CiteScore](#) [CiteScore rank & trend](#) [Scopus content coverage](#)

i Improved CiteScore methodology



CiteScore 2022 counts the citations received in 2019-2022 to articles, reviews, conference papers, book chapters and data papers published in 2019-2022, and divides this by the number of publications published in 2019-2022. [Learn more >](#)

CiteScore 2022

$$1.0 = \frac{3,869 \text{ Citations 2019 - 2022}}{4,033 \text{ Documents 2019 - 2022}}$$

Calculated on 05 May, 2023

CiteScoreTracker 2023

$$0.8 = \frac{3,107 \text{ Citations to date}}{3,904 \text{ Documents to date}}$$

Last updated on 07 June, 2023 • Updated monthly

CiteScore rank 2022

Category	Rank	Percentile
Medicine		
Surgery	#325/495	34th

[View CiteScore methodology >](#) [CiteScore FAQ >](#) [Add CiteScore to your site](#)

About Scopus

[What is Scopus](#)

[Content coverage](#)

[Scopus blog](#)

[Scopus API](#)

[Privacy matters](#)

Language

[日本語版を表示する](#)

[查看简体中文版本](#)

[查看繁體中文版本](#)

[Просмотр версии на русском языке](#)

Customer Service

[Help](#)

[Tutorials](#)

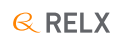[Contact us](#)

ELSEVIER

[Terms and conditions ↗](#) [Privacy policy ↗](#)

Copyright © Elsevier B.V ↗. All rights reserved. Scopus® is a registered trademark of Elsevier B.V.


We use cookies to help provide and enhance our service and tailor content. By continuing, you agree to the use of cookies ↗.



International Journal of Surgery Case Reports

Open access

Submit your article 


Guide for authors 

 Menu

 Search in this journal

Volume 97

August 2022


 Download full issue

[< Previous vol/issue](#)

[Next vol/issue >](#)

Receive an update when the latest issues in this journal are published

 [Sign in to set up alerts](#)

 Open access

Editorial Board

Article 107501


 [View PDF](#)


Correspondence

FEEDBACK 

International Journal of Surgery Case Reports

Open access

Submit your article 

Guide for authors 

 Menu



 View PDF

Case Reports

Case report ● Open access

Dilated sigmoid colon with Chilaiditi's sign mimicking diaphragmatic hernia: A case report

Suveksha Shaurya Shah, Dhiraj Chaurasia, Dinjul Katuwal

Article 107373



View PDF

Article preview 

Case report ● Open access

Infected urachal cyst in an adult, report of two observations

P.M. Faye, M.L. Gueye, O. Thiam, A. Niasse, ... M. Cisse

Article 107394



View PDF

Article preview 

Case report ● Open access

Synchronous breast cancer and non-Hodgkin lymphoma: A case report

Salman Ardi Syamsu, Rino Setiady, Nilam Smaradania, Prihantono, ... Muhammad Faruk

Article 107398



View PDF

Article preview 

Case report ● Open access

A rare case report of tricorpora penile fracture associated with urethral disruption

Gede Wirya Kusuma Duarsa, Muhlis Yusuf, Yudhistira Pradnyan Kloping, Ilham Akbar Rahman, Soetojo

Article 107351

FEEDBACK 

International Journal of Surgery Case Reports

Open access

Submit your article [↗](#)

Guide for authors [↗](#)

Menu



Article 107380



[View PDF](#)

[Article preview](#) [▼](#)

Case report ● *Open access*

Successful use of stereotactic navigation in posterior spinal fusion T10-S2 with bilateral iliac screw fixation in a patient with prior spinal surgeries and osteoporosis: A case report

Nolan J. Brown, Shane Shahrestani, Joshua S. Kurtz, Ryan S. Beyer, ... Joseph Osorio

Article 107380



[View PDF](#)

[Article preview](#) [▼](#)

Case report ● *Open access*

Massive retroperitoneal cyst impersonating ovarian tumor: A case report

Hidar Alibrahim, Amany Al Ali, Haidara Bohsas, Safaa Mohamed Alsharief Ahmed, ... Sarya Swed

Article 107393



[View PDF](#)

[Article preview](#) [▼](#)

Case report ● *Open access*

Chylous ascites and pancreatic pseudocyst on a child following blunt abdominal trauma; a case report

Kennedy Misso, Bahati Robert, Joachim Magoma, Tendai Joylene, David Msuya

Article 107406



[View PDF](#)

[Article preview](#) [▼](#)

Case report ● *Open access*

Mesenteric cyst manifested as obesity, gastroesophageal reflux, urinary incontinence, and abdominal mass during pregnancy—Case report and literature review


Francisco Aguilar-Espinosa, Rodolfo Salcedo-Vargas, Hiram Alfonso Galván-Bizarro, Carlos Rubén

FEEDBACK

International Journal of Surgery Case Reports

Open access

Submit your article 

Guide for authors 

 Menu



(PRF) to accelerate bone healing

Ahmad Taufik S, Adnanto Wiweko, Didit Yudhanto, Mohammad Rizki, ... Rohadi Muhammad Rosyidi
Article 107370

 [View PDF](#) Article preview 

Case report ● *Open access*

A rare case of appendiceal tip complete attachment to a sigmoid diverticulum: An appendiceal phlegmon case report

Farzad Vaghef Davari, Arezou Hashem Zadeh
Article 107379

 [View PDF](#) Article preview 

Case report ● *Open access*

Laparoscopic total gastrectomy performed for juvenile polyposis of the stomach: A case report

Misato Ito, Hisashi Onozawa, Masaru Saito, Hirofumi Ami, ... Kono Koji
Article 107368

 [View PDF](#) Article preview 

Case report ● *Open access*

Multispecialty surgical management of large clavicular tumor: A case report

Mohammad Aladaileh, Tom Moran, Austin Duffy, Karen Redmond, David O'Briain
Article 107375


 [View PDF](#) Article preview 


Case report ● *Open access*

FEEDBACK 

International Journal of Surgery Case Reports

Open access

Submit your article 

Guide for authors 

 Menu



Case report ● Open access

Multiple drill hole osteotomy and Herbert screw for correcting a-2 years ring finger phalanx media malunion: A case report

Huda Fajar Arianto, Muhammad Bayu Zohari Hutagalung, Yunus Abdul Bari

Article 107410



[View PDF](#)

Article preview 

Case report ● Open access

Deep anterior lamellar limbo-keratoplasty for bilateral limbal stem cell deficiency with corneal scarring in chemical injury sequelae: Two case reports

Neha Jain, Anahita Kate, Sayan Basu

Article 107409



[View PDF](#)

Article preview 

Case report ● Open access

Long-term results of sclerotherapy for cervical-thoracic-mediastinal lymphatic and venous malformations: A case report

Quan-Feng LUO

Article 107411



[View PDF](#)

Article preview 

Case report ● Open access

Bilateral ovarian mucinous carcinoma (stage III) with omental involvement and incidental hydronephrosis: A rare case report

Diptee Poudel, Kshitiz Acharya, Navin Poudel, Ashmita Adhikari, ... Suvana Maskey

Article 107415



[View PDF](#)

Article preview 

FEEDBACK 

International Journal of Surgery Case Reports

Open access

Submit your article [↗](#)

Guide for authors [↗](#)

Menu



[View PDF](#) [Article preview](#) [▼](#)

Case report ● *Open access*

Diagnostic approach and management of bilateral pneumothorax due to silicosis in Indonesian male: A rare case

Risa Natalia Siburian, Kristin Purnama Dewi, Winariani Koesoemoprodjo

Article 107407

[View PDF](#) [Article preview](#) [▼](#)

Case report ● *Open access*

Case report on peri-operative surgical and anaesthetic management of ruptured humongous lung abscess

Khalid Maudood Siddiqui, Akbar Azizullah, Muhammad Saad Yousuf

Article 107381

[View PDF](#) [Article preview](#) [▼](#)

Case report ● *Open access*

The evaluation of the effect of performing guided lid surgery with enucleation of a cystic lesion; a case report

Aly Khaled Hussein Abdelazez, Hossam El-Dien Hany, Mohamed Ehab Gamal El Din, Mahmoued Medhat Mostafa El Meregny, ... Mohammed Daa Zein El Abdien

Article 107385

[View PDF](#) [Article preview](#) [▼](#)

Case report ● *Open access*


Laparoscopic jejunostomy for enteral nutrition in gastric cancer patients: A report of two cases: A case report


Hiroshi Tsuchiya, Itaru Yasufuku, Naoki Okumura, Nobuhisa Matsuhashi, Takao Takahas

FEEDBACK

International Journal of Surgery Case Reports

Open access

Submit your article 

Guide for authors 

 Menu



Qin Ou, Ying-dong Li, Jun Chen, Lin-lin Yuan, Wenfang Li

Article 107408



[View PDF](#)

Article preview 

Case report  *Open access*

Thyroid angiosarcoma: A case report and review of literature

L. Benbella, I. Elouarith, H.E.L. Ouazzani, Z. Bernoussi, ... F. Zouaidia

Article 107358



[View PDF](#)

Article preview 

Case report  *Open access*

Intraparenchymal fiberoptic intracranial pressure monitoring and decompressive craniectomy in meningioma case with critical intracranial pressure: A case report during COVID-19 pandemic

Tedy Apriawan, Rizki Meizikri, Endra Wibisono Harmawan, Heru Kustono

Article 107364



[View PDF](#)

Article preview 

Case report  *Open access*

Duodenal perforation due to migrated biliary stent: Case report

Prarthana Pachhai, Rabi Khadka, Narendra Maharjan, Deepak Sharma, ... Ramesh Singh Bhandari

Article 107354



[View PDF](#)

Article preview 

Case report  *Open access*

Coronary artery to pulmonary artery fistula: Catheter or scalpel? A case report

FEEDBACK 

International Journal of Surgery Case Reports

Open access

Submit your article ↗

Guide for authors ↗

Menu



squamous cell carcinoma: A case report

Tiuri E. Kroese, Peter S.N. van Rossum, Sylvia van der Horst, Stella Mook, ... Richard van Hillegerberg
Article 107423



[View PDF](#)

Article preview

Case report ● *Open access*

Botryoid rhabdomyosarcoma of the uterine cervix: Report case

R.E.L. Qasseh, F. Bouyalik, S. Majidi, M. Moutahir, ... M. El Keroumi
Article 107389



[View PDF](#)

Article preview

Case report ● *Open access*

Perirenal cystic lymphangioma mimicking a renal cyst in an elderly patient: Case report

A. Lahfidi, W.M. Traore, K. Imrani, C. Ayadi, ... N. Moatassim Billah
Article 107403



[View PDF](#)

Article preview

Case report ● *Open access*

Idiopathic lymphatic mesenteric cyst of the proximal jejunum: A case report of an unusual clinical presentation

Michele Ghielmetti, Kerstin J. Neuschütz, Anna Hirschmann, Katharina Marston, ... Marco von Strauss und Torney
Article 107402



[View PDF](#)

Article preview


Case report ● *Open access*

FEEDBACK

International Journal of Surgery Case Reports

Open access

Submit your article 

Guide for authors 

 Menu



Case report ● Open access

Localized retroperitoneal Rosai-Dorfman-Destombes disease as a cause of fever of unknown origin in adults. Case report and review of the literature

Georgi Popivanov, Magdalena Baymakova, Pavel Bochev, Dimitar Penchev, ... Ventsislav Mutafchiyski
Article 107414



[View PDF](#)

Article preview 

Case report ● Open access

Zinner's syndrome: A rare diagnosis of congenital seminal vesicle cyst and renal agenesis on basis of radiological imaging and its management

Avishkar Raj Regmi, Sarmendra Mishra, Adarsh Gurung, Archana Acharya, ... Ajnish Ghimire
Article 107434



[View PDF](#)

Article preview 

Case report ● Open access

Conjunctival myxoma masquerading as conjunctival lymphoma: A case report

Majed Alkharashi, Hind M. Alkatan, Ahmed A. Alhumidi, Wael Otaif
Article 107441



[View PDF](#)

Article preview 

Case report ● Open access

One anastomosis gastric bypass with fundoplication of remnant stomach for weight regain prevention: Case report

O. Ospanov, K. Nadirov, V. Koikov, N. Zharov
Article 107431



[View PDF](#)

Article preview 

FEEDBACK 

International Journal of Surgery Case Reports

Open access

Submit your article ↗

Guide for authors ↗

Menu



 [View PDF](#) Article preview ▾

Case report ● Open access

Triple-valve replacement for *Rhizobium radiobacter* endocarditis with septic shock in an adult with ventricular septal defect. A case report

Andrei George Iosifescu, Ioana Marinică, Alexandru Popescu, Alina Teodora Timișescu, ... Vlad Anton Iliescu
Article 107401

 [View PDF](#) Article preview ▾

Case report ● Open access

Case report of an angiosarcoma of the abdominal wall during liraglutide injections: A coincidence?

Eric Bergeron, Meriamé Dami, Xuan Vien Do, Chantal Vallee, Jonathan Noujaim
Article 107444

 [View PDF](#) Article preview ▾

Case report ● Open access

Periosteal osteosarcoma of the clavicle: A case report and review of the literature

Son Do Le Hoang, Huy Hoang Quoc, Bach Nguyen, Binh Le Nguyen, ... Vinh Pham Quang
Article 107430

 [View PDF](#) Article preview ▾

Case report ● Open access

Giant omental lipoma, a rare etiology of right-iliac fossa pain in adult: A surgical case report


Athary Saleem, Jumana Alfadhli, Abrar Alawadhi, Maher Hassan, Khaled Alshammari
Article 107428

FEEDBACK 

International Journal of Surgery Case Reports

Open access

Submit your article 

Guide for authors 

 Menu



Abdulaziz Alkheraji, Sultana Dorai, Kheema Alaudini, Fawzi Aljassir

Article 107437



[View PDF](#)

Article preview 

Case report ● *Open access*

Dumbbell-shaped meningioma of Meckel's cave mimicking trigeminal schwannoma: A case report

Chun-Pi Chang, Cheng-Siu Chang, Meng-Yin Yang, Chiung-Chyi Shen

Article 107369



[View PDF](#)

Article preview 

Case report ● *Open access*


A rare case of obstructed labor due to sever uterine prolapse; a case report and literature review

Elham Askary, Shaghayegh Moradi Alamdarloo, Zinat Karimi, Anushe Karimzade

Article 107344



[View PDF](#)

Article preview 

Case report ● *Open access*

Von Hippel-Lindau disease: A case report

Durga Neupane, Alok Dahal, Nimesh Lageju, Lokesh Shekher Jaiswal, ... Srista Manandhar

Article 107417



[View PDF](#)

Article preview 

Case report ● *Open access*


Jejunal diverticulitis: A new case report and a review of the literature


Elmontassar Belleh Zafouri, Imen Ben Ismail, Marwen Sghaier, Saber Rebi, Ayoub Zoghlemi

FEEDBACK 

International Journal of Surgery Case Reports

Open access

Submit your article 

Guide for authors 

 Menu



A. Chirihan, S. Ezzaky, I. Eloual, A. Madani, ... F.Z. Laamrani

Article 107447



[View PDF](#)

Article preview 

Case report  *Open access*

Odontogenic brain abscess due to *Anaerococcus prevotii* infections: A case report and review article

Suharyadi Sasmanto, Eddy Bagus Wasito

Article 107450



[View PDF](#)

Article preview 

Case report  *Open access*

Ectopic ACTH syndrome complicated by hypercortisolism-associated urolithiasis. A case report

Emilio de León-Castorena, Dulce María López-Sotomayor, Luis Edwin Gaona-Garza, Mario Alberto Treviño-Aguillón, Alejandro Talamas-Mendoza

Article 107449



[View PDF](#)

Article preview 

Case report  *Open access*

Infectious hematogenous lumbar spondylodiscitis caused by *Actinotignum schaalii* in a 74-year-old man: A case report

Ekkehard F. Röpke, Martin Chwoika, Tim Treber, Jens Meyer, Christoph Paasch

Article 107453



[View PDF](#)


Article preview 


Case report  *Open access*

FEEDBACK 

International Journal of Surgery Case Reports

Open access

Submit your article 

Guide for authors 

 Menu



Case report ● Open access

Extraction of sphenchoanal polyp with functional endoscopic sinus surgery approach: A rare case and review article

Bunga Aline Ditha, Budi Sutikno

Article 107429



[View PDF](#)

Article preview 

Case report ● Open access

Acute appendicitis secondary to metastatic breast cancer. 12 Years after first primary tumor diagnosis. A case report

Victoria G. Hughes, Pedro Osácar, Darío Ramallo

Article 107452



[View PDF](#)

Article preview 

Case report ● Open access

Intercostal nerve block is effective in open biopsies of the anterior mediastinal region: Case report and review

Marina Brito Gondar, Mariana Fernandes, Pablo Mondragon, Andres Hagerman, Lennart Magnusson

Article 107461



[View PDF](#)

Article preview 

Case report ● Open access

Leiomyosarcoma of the small bowel: A case report and literature review

Mahdi Bouassida, Hazem Beji, Mohamed Fadhel Chtourou, Saloua Nechi, ... Hassen Touinsi

Article 107456



[View PDF](#)


Article preview 

FEEDBACK 

International Journal of Surgery Case Reports

Open access

Submit your article 

Guide for authors 

 Menu



Case report ● Open access

Minor lobulation of the testis, mimicking polyorchidism when inflammed, discussion of a rare case: A case report

Mohammad Hadi Gharib, Reza Zahedpasha

Article 107448



[View PDF](#)

Article preview 

Case report ● Open access

Perforated ileum as the initial presentation of Crohn's disease, a case report

Robel Tadesse, Biniam Ewnte, Kale'ab Tesfaye

Article 107305



[View PDF](#)

Article preview 

Case report ● Open access

Human papillomavirus-related carcinoma with adenoid cystic-like features of the sinonasal tract: Case report and literature review

Zephania Saitabau Abraham, Caroline Philip Ngimba, Atuganile Edward Malango, Alita Mrema, ... Edda Vuhahula

Article 107462



[View PDF](#)

Article preview 

Case report ● Open access

Case Report-Right atrial myxoma with total anomalous pulmonary venous connection in neonate

Shantanu Gomase, Sachin Kuthe, Manish Sonkusale

Article 107438

FEEDBACK 

International Journal of Surgery Case Reports

Open access

Submit your article [↗](#)

Guide for authors [↗](#)

Menu



Arisa Kunita, Masayuki Toshida, Takeshi Imurata, Akimiko Toshida, ... Shinn Takayama

Article 107435



[View PDF](#)

Article preview [v](#)

Case report ● *Open access*

Granulomatosis with polyangiitis presenting with intestinal obstruction: A case report

Reem Alawna, Tala Jalamneh, Maram Massad, Noor Alawna, ... Fadi Abu Alrub

Article 107446



[View PDF](#)

Article preview [v](#)

Case report ● *Open access*

Mesenteric textiloma early discovery in a 31-year-old female: A case report

Jeannot Baanitse Munihire, Moise Muhindo Valimugighe, Nyundo W. Martin

Article 107439



[View PDF](#)

Article preview [v](#)

Case report ● *Open access*

Unconstrained one-stage total knee arthroplasty PS design in patient with secondary osteoarthritis due to granulomatous infection with medial femoral condyle defect: A case report

Nur Rahmansyah, Dicky Mulyadi, Raden Moechammad Satrio Nugroho Magetsari, Aditya Fuad Robby Triangga

Article 107469



[View PDF](#)


Article preview [v](#)

Case report ● *Open access*

Gallbladder volvulus with gangrenous cholecystitis – A case report

FEEDBACK

Submit your article 

Guide for authors 

 Menu



Yusuf Rachman, Yosua Hardja

Article 107465



[View PDF](#)

Article preview 

Case report  *Open access*

First case report of gastric outlet obstruction due to aortofemoral bypass Dacron graft erosion of the duodenum treated with neo aortoiliac system procedure

Juan Fernando Muñoz, Fernando Mejía, Manuel Hosman, Luis Felipe Cabrera-Vargas, ... Alexis Rafael Narvaez-Rojas

Article 107400



[View PDF](#)

Article preview 

Case report  *Open access*

Giant fibrovascular polyps of the esophagus. Trans oral versus surgical approach. Case report and systematic literature review

Valentina Ferri, Emilio Vicente, Yolanda Quijano, Hipolito Duran, ... Riccardo Caruso

Article 107412



[View PDF](#)

Article preview 

Case report  *Open access*

Acute pancreatitis secondary to spontaneous intramural duodenal hematoma: A case report and a review of the literature

Wissal Skhiri, Marwa Moussaoui, Jamal Saad, Mohamed Maatouk, ... Ines Mazhoud

Article 107424



[View PDF](#)

Article preview 


Case report  *Open access*

FEEDBACK 

International Journal of Surgery Case Reports

Open access

Submit your article 

Guide for authors 

 Menu



Case report ● Open access

Esophageal extraskeletal neoplasm Ewing's sarcoma: Case report

Hina Khalid, Niaz Hussain, Rafay Shamshad

Article 107399



[View PDF](#)

Article preview 

Case report ● Open access

A rare incidence of primary Synovial Spindle Cell Sarcoma in a 46-year-old male, successfully managed by surgical intervention-A Case Report

Omar Hariri, Omar Al Laham, Zein Ibrahim Basha, Hisham Hamzeh

Article 107442



[View PDF](#)

Article preview 

Case report ● Open access

Bilateral tubal ectopic gestation: Complication in a patient with previous ectopic pregnancy, rare case report

Willbroad Kyejo, Davis Rubagumya, Zainab Fidaali, Ahmed Jusabani, ... Shweta Jaiswal

Article 107470



[View PDF](#)

Article preview 

Case report ● Open access

Collar-button abscess as a complication of infected hematoma in the setting of uncontrolled type 2 diabetes

Jennifer Adams, Daniel Habenicht, Savvas Poulos

Article 107427



[View PDF](#)

Article preview 

FEEDBACK 

International Journal of Surgery Case Reports

Open access

Submit your article ↗

Guide for authors ↗

Menu



View PDF Article preview ▾

Case report ● Open access

Generalized peritonitis secondary to spontaneous rupture of the urinary bladder in a diabetic patient: A case report

Foolad Eghbali, Hesam Mosavari, Ahmad Madankan, Vahid Hariri, ... Mansour Bhahdoust
Article 107458

View PDF Article preview ▾

Case report ● Open access

Ileocolic intussusception caused by giant submucosal colonic lipoma: A rare case report

Nahyeon Park, Jung Cheol Kuk, Eung Jin Shin, Su Sie Chin, Dae Ro Lim
Article 107451

View PDF Article preview ▾

Case report ● Open access

An extensive squamous cell carcinoma of the auricle: From curative to reconstructive treatment. A case report

Sara Halily, Karmouch Mohamed Amine, Youssef Oukessou, Sami Rouadi, ... Mohammed Mahtar
Article 107413

View PDF Article preview ▾

Case report ● Open access

Robot-assisted laparoscopic hysterectomy for early-stage endometrial cancer with massive uterine leiomyomas: A case report

Akiyo Kakibuchi, Fumitake Ito, Tetsuya Kokabu, Hiroyuki Okimura, ... Taisuke Mori
Article 107473

FEEDBACK

International Journal of Surgery Case Reports

Open access

Submit your article ↗

Guide for authors ↗

Menu



J.H. Gonzalez-Cortes, A.D. Trevino-Herrera, J.E. Gonzalez-Cantu, A. Sudhaikar, ... J. Mohamed-Hamsho

Article 107443



View PDF

Article preview ▾

Case report ● Open access

Acute kidney injury leading to the diagnosis of sporadic testicular Burkitt's lymphoma: A case report

Sanda Mrabet, Yosr Chaabouni, Mohamed Ben Hmida

Article 107471



View PDF

Article preview ▾

Case report ● Open access

Langerhans cell histiocytosis of the rib in an adult: A case report and review of the literature

Shengliang Zhao, Chao Luo, Bo Tang, Liang Chen, ... Hua Li

Article 107432



View PDF

Article preview ▾

Case report ● Open access

A case of primary mediastinal seminoma with superior vena cava syndrome and large intracardiac thrombus

Vicky Reinold Christofel Rampengan, Arief Bakhtiar

Article 107478



View PDF

Article preview ▾

Case report ● Open access

FEEDBACK

International Journal of Surgery Case Reports

Open access

Submit your article [↗](#)

Guide for authors [↗](#)

Menu



Case report ● Open access

Bowel obstruction secondary to gallstone ileus within a strangulated inguinal hernia: Report of a rare diagnosis

Mojtaba Ahmadinejad, Mohammad Hadi Bahri, Armin Tajik, Nooshin Taherzadeh-ghahfarokhi, Javad Zebarjadi Bagherpour

Article 107445



[View PDF](#)

Article preview [▼](#)

Case report ● Open access

Hidden appendix: A case report and literature review of perforated acute appendicitis masquerading as acute cholecystitis

E Ashwini, M Varun, PS Saravanan, Sunil Julian, P Sandeep

Article 107480



[View PDF](#)

Article preview [▼](#)

Case report ● Open access

Precise diagnosis of acute mesenteric ischemia using indocyanine green imaging prevents small bowel resection: A case report

Kohei Furusawa, Masanori Yoshimitsu, Hiroyoshi Matsukawa, Kuniomi Oi, ... Akihisa Tamura

Article 107463



[View PDF](#)

Article preview [▼](#)

Case report ● Open access

Wide-awake local anesthesia for open rotator cuff repair: A case report

Farsad Biglari, Amir Sabaghzadeh, Adel Ebrahimpour, Mehrdad Sadighi, ... Meisam Jafari Kafiabadi

Article 107494




[View PDF](#)


Article preview [▼](#)

FEEDBACK

International Journal of Surgery Case Reports

Open access

Submit your article 

Guide for authors 

 Menu



arthroscopic assisted intraarticular osteotomy

Oryza Satria, Irsan Abubakar, Syahdi Farqani, Irfan Kurnia Pratama

Article 107391



[View PDF](#)

Article preview 

Mini review  *Open access*

Osteoclast-like stromal giant cells in invasive ductal breast cancer: A case series

Giustina Angellotti, Giovanni Tomasicchio, Alda Elena Montanaro, Michele Telgrafo, ... Clelia Punzo

Article 107421



[View PDF](#)

Article preview 

Mini review  *Open access*

Case series of diagnosis and surgery challenges in parathyroid carcinoma

Diani Kartini, Ahmad Kurnia, Erwin Danil Yulian, Sonar Soni Panigoro, ... Jessica Wardana

Article 107390



[View PDF](#)

Article preview 

Mini review  *Open access*

Laparoscopic subtotal reconstituting cholecystectomy in type II & III Mirizzi syndrome:
Case series of 5 patients

Gerardo Chávez Saavedra, Dante Ríos Segovia, Raúl Hernandez Centeno, Nicolas Joaquín Fernández Pérez

Article 107425



[View PDF](#)

Article preview 

Mini review  *Open access*

Cerebellar primary central nervous system lymphoma: Case series report

Minglian He, Jun Zhong, Xuegang Li, Yujie Chen, Fei Li

FEEDBACK 

International Journal of Surgery Case Reports

Open access

[Submit your article](#) ↗

[Guide for authors](#) ↗

☰ Menu



Shehryar Ahmed Khan Niazi, Muhammad Umer Mukhtar, Rameez Hassan, Qasim Mehmood
Article 107459



[View PDF](#)

[Article preview](#) ▼

Mini review ● *Open access*

Diagnosis and Management of oro-antral fistula: Case series and review

Asma Azzouzi, Lamiae Hallab, Saliha Chbicheb
Article 107436



[View PDF](#)

[Article preview](#) ▼

Mini review ● *Open access*

Case series of high-grade soft tissue sarcoma of the lower limb with delayed diagnosis: Experience at a tertiary hospital in northern Tanzania

Jay Lodhia, Gregory Goodluck, Joylene Tendai, Ellyagape Urassa, ... Alex Mremi
Article 107475



[View PDF](#)

[Article preview](#) ▼

Mini review ● *Open access*

Radiofrequency ablation for benign thyroid nodule treatment: New solution in our center

Monica Bellynda, Muhammad Rizki Kamil, Kristanto Yuli Yarso
Article 107418



[View PDF](#)

[Article preview](#) ▼



ELSEVIER

Copyright © 2023 Elsevier B.V. or its licensors or contributors.
ScienceDirect® is a registered trademark of Elsevier B.V.

RELX™

FEEDBACK

International Journal of Surgery Case Reports

Open access

[Submit your article ↗](#)

[Guide for authors ↗](#)

☰ Menu





ELSEVIER



International Journal of Surgery Case Reports

Editor-in-Chief

Professor David Rosin, Barbados, West Indies

Managing and Executive Editor

Dr Riaz Agha, London, UK

Assistant Managing Editor

Maliha Agha, London, UK

Senior Editors

Professor Hasan Alam, Michigan, USA
Professor Raafat Afifi, Cairo, Egypt
Dr Juan Barret, Barcelona, Spain
Mr Ben Challacombe, London, UK
Dr Xiaoping Chen, Wuhan, China

Dr Burcin Ekser, Indianapolis, USA
Professor Joseph W Y Lau, Shatin, Hong Kong
Dr Oliver Muensterer, New York, USA
Dr Selwyn Rogers, Galveston, Texas
Professor Jamsheer Talati, Karachi, Pakistan

Dr Mangesh Thorat, London, UK
Professor Fu Chan Wei, Tapei, Taiwan
Professor Rudy Leon De Wilde, Oldenburg, Germany

Associate Editors

Professor Roberto Coppola, Rome, Italy
Dr Veerappan Kasivisvanathan, London, UK
Dr Richard Keijzer, Winnipeg, Canada, USA
Dr Boris Kirshtein, Beer Sheva, Israel

Professor James McCaul, London, UK
Miss Emma McGlone, London, UK
Dr Dattatraya Muzumdar, Mumbai, India
Professor Andy Petroianu, Minas Gerais, Brazil

Mr Shahzad Raja, London, UK
Dr Kandiah Raveedran, Ipoh, Malaysia
Dr Daniel Yeh, Boston, USA

Assistant Editors

Dr Rafid Al-Mahfoudh, Oxford, UK
Dr Hussein Atta, Boston, USA
Dr Mohammad Bashashati, Texas, USA
Professor Somprakus Basu, Varanasi, India
Mr Andrew Beamish, Cardiff, UK
Dr Anthony Charles, North Carolina, USA
Dr Amitava Das, Hyderabad, India
Dr Brian Davis, Texas, USA
Dr Susana Adriana Esquivel, Córdoba, Mexico
Professor Sheng Feng, Shanghai, China

Dr Juan Gomez Rivas, Madrid, Spain
Dr Satoshi Ieiri, Kagoshima City, Japan
Dr Haytham Kaafarani, Massachusetts, USA
Dr Yogeesh Kamat, Karnataka, India
Mr Omar Khan, London, UK
Prof. Tsuyoshi Konishi, Osaka, Japan
Dr Vito A Mannacio, Naples, Italy
Dr Todd Manning, Oxford, UK
Dr Zubing Mei, Shanghai, China
Dr Umesh Metkar, Beth, Israel

Dr Indraneil Mukherjee, Staten Island, USA
Dr Enyi Ofo, Adelaide, South Australia
Dr Lena Perger, Albuquerque, USA
Professor Prathamesh S Pai, Mumbai, India
Dr Alfredas Smailys, Kaunas, Lithuania
Prof. Peter Hyunsuk Suh, Seoul, South Korea
Dr Dieter Weber, Perth, Australia
Dr John Wee, Boston, USA
Dr Honggyi Zhu, Shanghai, China

Statistical Editors

Dr Derek Cooper, London, UK
Professor Nora Donaldson, London, UK
Professor Mary W Gray, Washington DC, USA

Society Representative

Deniz Balci, Representative of the International Society of Liver Surgeons
Rhiannon Harries, President, Association of Surgeons in Training
Gene F. Coppa, President of the New York Surgical Society
Xiao-ping Chen, President of the Chinese Chapter of International Hepato-Pancreato-Biliary Association

Social Media Editor

Dr Riaz Agha, London, UK

Assistant Commissioning Editors

Ahmed Al-Jabir, London, UK
Zaid Alsafi, London, UK
Thomas Franchi, Sheffield, UK
Christos Iosifides, London, UK

Ahmed Kerwan, London, UK
Mehdi Khan, London, UK
Ginimol Matthew, London, UK
Maria Nicola, London, UK

Niamh O'Neill, London, UK
Catrin Sohrabi, London, UK

Executive Committee

Professor David Albala, New York, USA
Sir Graeme Catto, London, UK
Professor David Cooper, Pittsburgh, USA
Lord Ara Darzi, London, UK
Professor Harold Ellis, London, UK
Ather Enam, Karachi, Pakistan

Sir Barry Jackson, London, UK
Professor Arthur Li Kwok-Cheung, Wanchai, Hong Kong
Professor C H Leong, Central, Hong Kong
Lord Ian McColl, London, UK

John Norcini, Philadelphia, USA
Professor Susan Standing, London, UK
Lord Robert Winston, London, UK
Sir Magdi Yacoub, London, UK

Editorial Board

Raj Badwe
Mumbai, India
Michael Boscoe
Middlesex, UK
Rapheal Bueno
Boston, USA
Kris Chatamra
Bangkok, Thailand
Paul Coulthard
Manchester, UK
Anil d'Cruz
Mumbai, India
Mahesh Desai
Mumbai, India
Juan Gomez Rivas
Spain, Madrid

David W. Green
London, UK
Iraj Harirchi
Tehran, Iran
Doris Henne-Bruns
Ulm, Germany
Delawir Kahn
Cape Town, South Africa
Xiaoxi Lin
Shanghai, China
Ashok Mahapatra
New Delhi, India
Todd Manning
Melbourne, Australia
Indraneel Mittra
Mumbai, India

Vijay Naraynsingh
West Indies
Fabio Nicoli
London, UK
Anibal R. Núñez De Pierro
Buenos Aires, Argentina
Reuben Orda
Tel Aviv, Israel
Vladimir Semiglazov
St. Petersburg, Russia
Tejinder Singh
Ludhiana, India
Barbara L. Smith
Boston, USA
James Tatum
California, USA

Thehnton Udwardia
Mumbai, India
Martin R. Weiser
New York, USA
Yixin Zhang
Shanghai, China
Jun Zhong
Shanghai, China
Zhao-Fan Xia
Shanghai, China

Elsevier

Executive Publisher

Ash Allan, Oxford, UK

Administrative Editor

Josie Hutchins, Oxford, UK

Marketing Manager

Jayne Dawkins, Philadelphia, USA

Journal Manager

Tamsyn Hopkins, Exeter, UK

Senior Business Development Executive (Reprints)

Emma Steel, London, UK

Advertising Sales Manager

Robert Bayliss, London, UK

Account Manager (Supplements)

Evelina Euren, Amsterdam, the Netherlands

Project Manager Supplements & E-business

Mónica Hernández-Sesma, Amsterdam, the Netherlands



Case report

Extraction of sphenochoanal polyp with functional endoscopic sinus surgery approach: A rare case and review article



Bunga Aline Ditha, Budi Sutikno *

Department of Otorhinolaryngology, Head, and Neck Surgery, Faculty of Medicine, Universitas Airlangga, Dr. Soetomo General Academic Hospital, Surabaya, Indonesia

ARTICLE INFO

Keywords:

Chronic respiratory disease
FESS
Medical care
Sphenochoanal polyp
Polyp mass

ABSTRACT

Background: Sphenochoanal polyp, a rare case of nasal polyp, is a benign mass that originates in the sphenoid sinus and develops into a choanal polyp.

Case presentation: A 36-year-old Indonesian male complained of irregular right nasal obstruction and runny nose for one year. Physical examination showed soft tissue mass in the right nasal cavity, cyst retention in the right maxillary sinus, right sphenoid sinus, and cervical spondylosis. Diagnosis of sphenochoanal polyp was supported by nasoendoscopy and CT-Scan of paranasal sinuses. The patient got medical care and underwent functional endoscopic sinus surgery (FESS) and rinsed the nose with normal saline and topical steroids. Evaluation at six months after the surgery, the patient came without complaint and showed no sign of polyp mass or cysts recurrence, so the patient was declared to have a full recovery.

Discussion: FESS is proven effective for managing sphenochoanal polyp and minimizes complications post-surgery and repetition of the polyp.

Conclusion: FESS is recommended for management of sphenochoanal polyp in term of minimizing recurrency.

1. Introduction

Sphenochoanal polyps are a solitary benign mass derived from the sphenoid sinus, especially the anterior wall progressing into the nasopharynx to become a choanal polyp. Sphenochoanal polyp is a rare polyp, with only 3–6 % of nasal polyps [1,2]. Polyp mass originates from the sphenoid sinus that expands through the sphenoid sinus ostium to the sphenoethmoid recess and choanal [3,4]. The recommended management of sphenochoanal polyps is functional endoscopic sinus surgery (FESS) which can see the location of the polyp so that the polyp can be extracted entirely with a low recurrence rate [1,5,6]. We are interested in reporting an Indonesian male with a sphenochoanal polyp. We wrote based on SCARE 2020 guidelines [7].

2. Case presentation

A 36-year-old male complained of irregular right nasal obstruction and runny nose for one year. The symptoms worsened in the last month with yellowish nasal discharge, thick consistency and foul odour. Other complaints included a bad smell in the right nose and pain behind the

right eye and top of the head. The patient denied the presence of pain in both cheeks, the base of the nose, the back of the head and the presence of mucus in the throat. The patient also denied a history of previous nasal pain, asthma, allergy, diabetes mellitus and hypertension.

The physical examination found a greyish mass with a slippery surface, a spongy impression of not easy bleeding and yellowish secretion on the middle meatus of the right nasal cavity. In the nasoendoscopy examination, a polyp-like mass in the right middle meatus spread to the choanal, while some parts of the polyp were inflamed (Fig. 1). The CT scan with contrast of the paranasal sinuses showed the impression of soft tissue mass in the right nasal cavity, cyst retention on the right maxillary sinus, right sphenoid sinus and cervical spondylosis (Fig. 2). The patient was diagnosed with a right unilateral sphenochoanal polyp.

The patient got medical care and underwent right functional endoscopic sinus surgery (FESS) [8]. Preparation for surgery included informed consent and antibiotic prophylaxis cefazolin 2 g intravenously. The patient was in supination position, reverse Trendelenberg 20°. The surgery location was disinfected with alcohol 70 %. The 0.05 % oxymetazoline was used to decongest the nasal cavity. At initial exploration, polyp mass was partially inflamed in the right nasal cavity extended to

* Corresponding author: Budi Sutikno, Department of Otorhinolaryngology, Head, and Neck Surgery, Faculty of Medicine, Universitas Airlangga, Dr. Soetomo General Academic Hospital, Jl. Mayjend Prof. Dr. Moestopo No. 6-8, Airlangga, Gubeng, Surabaya, East Java 60286, Indonesia.

E-mail addresses: budi-s@fk.unair.ac.id, budisutikno104@gmail.com (B. Sutikno).

<https://doi.org/10.1016/j.ijscr.2022.107429>

Received 24 May 2022; Received in revised form 12 July 2022; Accepted 17 July 2022

Available online 21 July 2022

2210-2612/© 2022 The Authors. Published by Elsevier Ltd on behalf of IJS Publishing Group Ltd. This is an open access article under the CC BY-NC-ND license (<http://creativecommons.org/licenses/by-nc-nd/4.0/>).

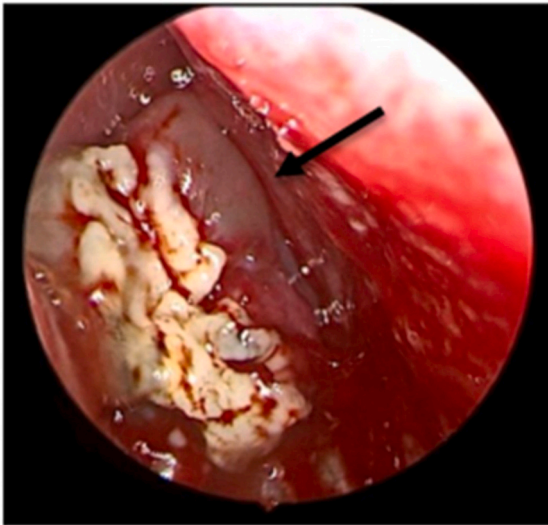


Fig. 1. Nasoendoscopy of the right nasal cavity showed polyp mass in the middle meatus area and mainly fulfilled the posterior part of the nasal cavity and reached choana (arrow).

choanal. The polyp was extracted as clean as possible until the base in the lateroinferior right of the sphenoid sinus using cutting forceps. Middle turbinate was pushed to the lateroposterior side (Fig. 3a–f). The bone was exposed from the sphenoid sinus, which was the polyp origin (Fig. 3f). Bleeding was treated with suction, cautery, and surgical installation in the surgical area. The surgery lasted 2 h without complication, and the amount of bleeding was about 100 ml. The patient received treatment of physiological normal saline for nasal irrigation and oral antibiotics cefadroxil of 500 mg twice daily for seven days post operatively.

Histopathology of the biopsy was not performed because it was microscopically similar to a polyp and the patient refused to biopsy because of his low income. Weekly post operative care, and in the sixth month, nasoendoscopy results showed complete wound healing. Nasoendoscopy examination showed a wide enlarged sphenoid ostium, the mucosal epithelialization was well established, and no polyp recurrence (Fig. 4).

3. Discussion

The sphenoidal polyps are often associated with precursors of the intramural cysts in the sphenoid sinus [1]. The sinus inflammation will obstruct the lymphatic vessels and the formation of intramural cysts. Then it develops into a polyp mass extending through the ostium to the choanal or nasopharynx. The presence of accessory ostium, the role of the urokinase enzyme, and arachidonic acid metabolism are also thought to cause sphenoidal polyps [9]. Fungal infections of the sinuses, inverted papilloma, internal carotid artery aneurysm, pituitary adenoma and neoplasm both primary and metastatic can also stimulate the formation of polyp masses in the sphenoid sinus [1,10].

Clinical manifestations in patients with sphenoidal polyps are unilateral nasal obstruction and chronic purulent discharge, with headache complaints, especially in the retro-orbital and vertex [1,11]. An intranasal polypoid mass may be obtained in anterior rhinoscopy examination, extending from the choanal to the nasopharynx [2,12]. Radiological examination is necessary to make the diagnosis. Computed tomography scans are superior to MRI because they are better in bone visualization and shorter examination times. On CT-scan, there is a description of soft tissue mass that fills the sphenoid sinus, extends through the ostium of the sphenoid sinus to the cavum nasi and may extend to the choanal and the nasopharynx in the posterior. The cyst mass in the right sphenoid sinus will push the ostium of the sphenoid sinus into the cavum nasi resulting in thrombosis from the lymphatic flow followed by sinus inflammation. Chronic inflammation will cause polyp mass [1,10].

The treatment used for sphenoidal polyps is simple polypectomy, but a newer and superior technique used nowadays using FESS. The FESS is conducted by performing intranasal polyp excision and extraction and enlarging the sphenoid sinus ostium endoscopically [8,13]. The surgery is first initiated by resectioning the inferior turbinate to expand the visual field [1,14]. Endoscopic sinus surgery may increase the accuracy in removing the origin of the polyp due to its ability to provide detail and magnified surgical view especially intra sphenoid sinus. Preservation of healthy mucosa is also enhanced by this endoscopic surgery. Blakesley forceps and Heuwieser antrum grasping forceps were used in this procedure. The duration of FESS is also faster than simple polypectomy [15,16].

The lack of FESS procedure is only applicable in certain advanced healthcare facilities. This is due to limited facilities and human resources. In addition, there is a risk of injury to the structures around the surgery area, cavernous sinus and cranial nerve II, III, IV, V1, V2, VI and carotid arteries. This risk will increase in simple polypectomy [17].

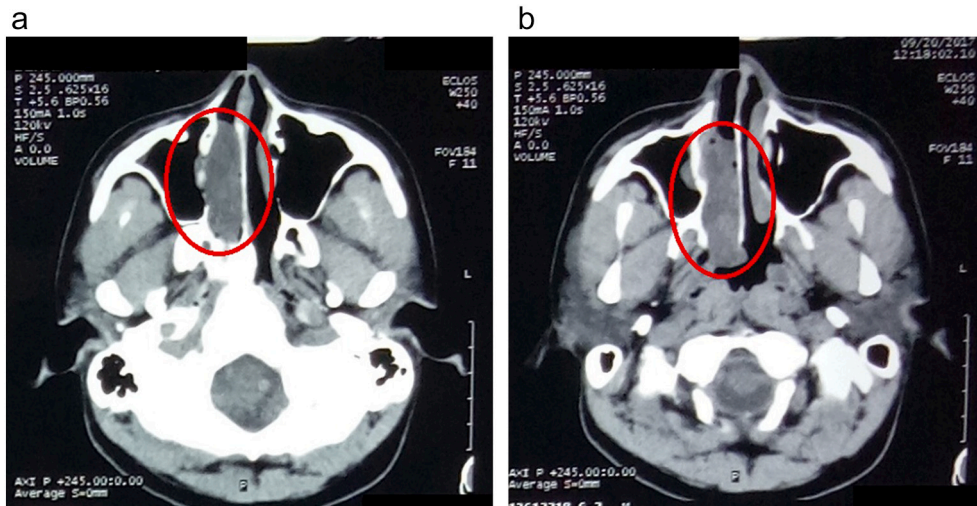


Fig. 2. (A–B) CT-scan of paranasal sinuses. A soft-tissue mass in the right nasal cavity expands to the choana (red circle).

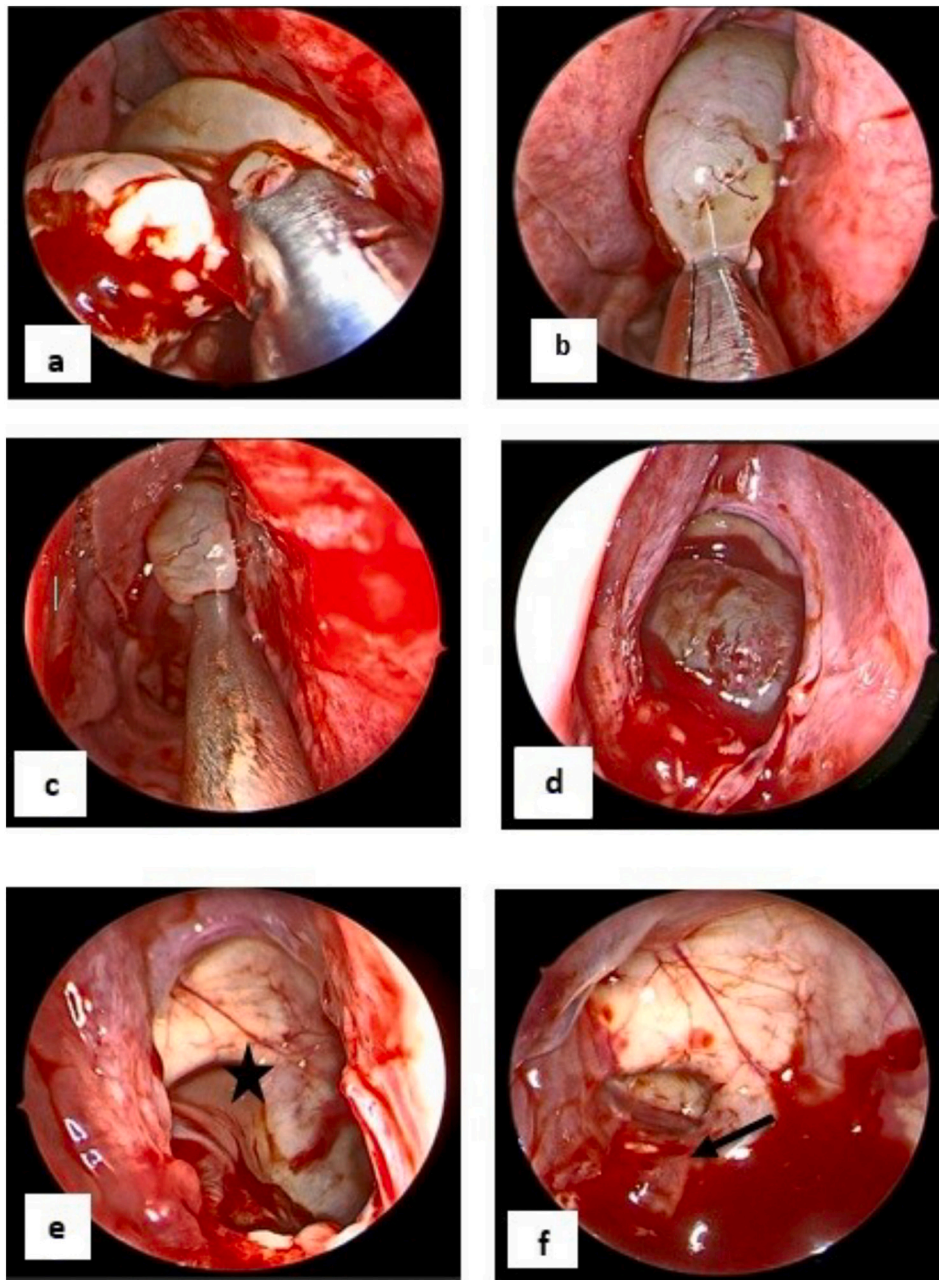


Fig. 3. (a–f) The polyp extraction process was located within the sphenoid sinus. The star marks (e) showed a wide ostium of the sphenoid sinus and a sphenoid sinus cavity. The arrow mark (f) showed bone exposure, which is the polyp origin in the lateroinferior side of the sphenoid sinus.

Evaluation of post-FESS aims to evaluate or monitor the wound healing process, complications and signs of recurrence. Post surgical nasal irrigation aims to facilitate a mucosal reepithelization and clean the nasal cavity from crust and secretion induced by the surgery [17,18].

Complications that can occur from FESS include infection, bleeding, sound changes, and injuries to the eyes and brain. Inflammation that can arise from the procedure is rhinitis or sinusitis, so appropriate antibiotic therapy is required to eliminate the causal microorganisms and prevent a recurrence. Analgesic therapy is given to reduce symptoms. Typically, minimal bleeding can occur post FESS. However, if bleeding occurs in large volumes and is accompanied by secretions, it must be evaluated and cauterized. The voice change is caused by the shift in sinus structure post FESS. Eye and brain injury complications are rare [13,15,16].

The functional endoscopic sinus surgery technique has a lower recurrence rate than simple polypectomy, 6 %. A simple polypectomy has a higher recurrence rate of 46 % [1,13,14]. The cause of recurrence

of sphenoidal polyps is an imperfect polyp extraction on intrasinus. This is due to the unidentified polyp origin on large polyp masses or intraoperative visualization limitations. The perfect identification of polyp origin and extraction is the basis of sphenoidal polyps management. In addition, other factors can cause inflammation in the mucosa, such as lifestyle, environment, and smoking habits [13,18].

4. Conclusion

Sphenoidal polyp, a rare case of nasal polyp, is a benign mass that originates in the sphenoid sinus and develops into a choanal polyp. The diagnosis of sphenoidal polyp needs to be confirmed by a better biopsy. FESS is the recommended management for sphenoidal polyps because it minimizes complications and recurrence of polyps.

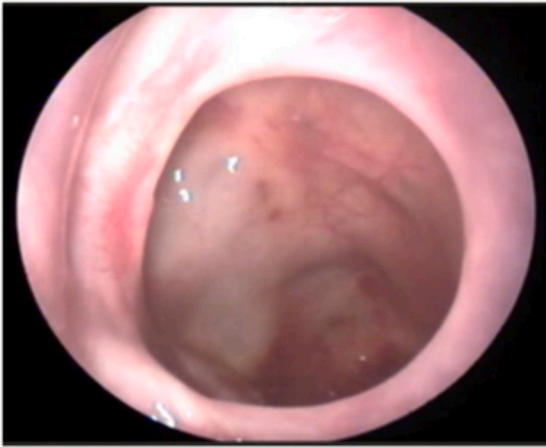


Fig. 4. The ostium of the sphenoid sinus was wide open, mucosal epithelialization is well established, and there is no polyp recurrence.

Provenance and peer review

Not commissioned, externally peer-reviewed.

Consent

Written informed consent was obtained from the patient for publication of this case report and accompanying images. A copy of the written consent is available for review by the Editor-in-Chief of this journal on request.

Ethical approval

Not applicable.

Funding

None.

Guarantor

Budi Sutikno is the person in charge of the publication of our manuscript.

Research registration number

Not applicable.

Credit authorship contribution statement

All authors contributed toward data analysis, drafting and revising the paper, gave final approval of the version to be published and agree to be accountable for all aspects of the work.

Declaration of competing interest

Bunga Aline Ditha and Budi Sutikno declare that they have no

conflict of interest.

Acknowledgement

We want to thank our editor “Fis Citra Ariyanto”.

References

- [1] H. Al Okbi, R. Jain, R. Al-Abri, Sphenoidal polyp—surgical review, *Int. J. Pediatric Otorhinolaryngol. Extra* 5 (3) (2010) 99–101, <https://doi.org/10.1016/j.pedex.2009.04.003>.
- [2] A. Çeçen, O. Kemal, S. Atmaca, E. Kavaz, Isolated sphenoidal polyp: report of three cases, *Hippokratia*. 21 (3) (2017) 150–153.
- [3] S.S. Bist, R. Kumar, S. Varshney, M. Bishr, Isolated sphenoidal polyp: a rare clinical entity, *Indian J. Otolaryngol. Head Neck Surg.* 59 (1) (2007) 56–57, <https://doi.org/10.1007/s12070-007-0016-3>.
- [4] M. Houda, E. Salk, B. Malika, E. Mehdi, R. Youssef, N. Hassan, et al., Sphenoidal polyp: case study of a rare entity and literature review, *Pan Afr. Med. J.* 37 (2020) 139, <https://doi.org/10.11604/pamj.2020.37.139.20832>.
- [5] S.A. Pol, S.K. Singhal, N. Gupta, A. Gulati, Sphenoidal polyp causing obstruction, *J. Pediatr. Surg. Case Rep.* 48 (2019), 101263, <https://doi.org/10.1016/j.epsc.2019.101263>.
- [6] K. Tywnoniuk, K. Haber, J. Mierzwiński, Sphenoidal polyps in children - a systematic review (1995–2021), *Braz. J. Otorhinolaryngol.* 1–9 (2022), <https://doi.org/10.1016/j.bjorl.2022.02.006>.
- [7] R.A. Agha, T. Franchi, C. Sohrabi, G. Mathew, A. Kerwan, The SCARE 2020 guideline: updating consensus surgical CAse REport (SCARE) guidelines, *Int. J. Surg.* 84 (2020) 226–230, <https://doi.org/10.1016/j.ijssu.2020.10.034>.
- [8] D.F. Widhiono, B. Sutikno, A rare case of allergic fungal rhinosinusitis in Indonesian elderly: a case report and diagnostic procedure, *Ann. Med. Surg.* 2021 (66) (2012), 102400, <https://doi.org/10.1016/j.amsu.2021.102400>.
- [9] H.S. Mostafa, T.O. Fawzy, W.R. Jabri, E. Ayad, Lymphatic obstruction: a novel etiologic factor in the formation of antrochoanal polyps, *Ann. Otol. Rhinol. Laryngol.* 123 (6) (2014) 381–386, <https://doi.org/10.1177/0003489414522973>.
- [10] H. Birkent, S. Karahatay, A. Durmaz, B. Kurt, F. Tosun, Choanal polyp originating from the nasal septum: septochoanal polyp. *Kulak burun bogaz ihtisas dergisi, Ear Nose Throat J.* 19 (3) (2009) 163–166.
- [11] Y. Kizil, U. Aydil, A. Ceylan, S. Uslu, V. Baştürk, F. İleri, Analysis of choanal polyps, *J. Craniofac. Surg.* 25 (3) (2014) 1082–1084, <https://doi.org/10.1097/scs.0000000000000543>.
- [12] Y. Hori, K. Taniguchi, T. Okabe, A. Sakamoto, A case of unexpectedly difficult intubation caused by a large asymptomatic choanal polyp, *JA Clin. Rep.* 2 (1) (2016) 2, <https://doi.org/10.1186/s40981-016-0028-7>.
- [13] J.R. Gardner, J.B. Campbell, O. Daigle, D. King, A. Kanaan, Operative and postoperative outcomes in elderly patients undergoing endoscopic sinus surgery, *European archives of oto-rhino-laryngology : official journal of the European Federation of Oto-Rhino-Laryngological Societies (EUFOS) : affiliated with the German Society for Oto-Rhino-Laryngology - Head and Neck Surgery.* 278 (5) (2021) 1471–1476, <https://doi.org/10.1007/s00405-020-06453-2>.
- [14] B.K. Tan, A.P. Lane, Endoscopic sinus surgery in the management of nasal obstruction, *Otolaryngologic clinics of North America.* 42 (2) (2009) 227–240, <https://doi.org/10.1016/j.otc.2009.01.012>, vii.
- [15] S. Suzuki, H. Yasunaga, H. Matsui, K. Fushimi, K. Kondo, T. Yamasoba, Complication rates after functional endoscopic sinus surgery: analysis of 50,734 Japanese patients, *Laryngoscope* 125 (8) (2015) 1785–1791, <https://doi.org/10.1002/lary.25334>.
- [16] M.R. Chaaban, N. Rana, J. Baillargeon, G. Baillargeon, V. Resto, Y.F. Kuo, Outcomes and complications of balloon and conventional functional endoscopic sinus surgery, *Am. J. Rhinol. Allergy* 32 (5) (2018) 388–396, <https://doi.org/10.1177/1945892418782248>.
- [17] A. Al-Mujaini, U. Wali, M. Alkhabori, Functional endoscopic sinus surgery: indications and complications in the ophthalmic field, *Oman Medical Journal* 24 (2) (2009) 70–80, <https://doi.org/10.5001/omj.2009.18>.
- [18] M. Chan, S. Carrie, Training and assessment in functional endoscopic sinus surgery, *J. Laryngol. Otol.* 132 (2) (2018) 133–137, <https://doi.org/10.1017/s0022215117002183>.