

Extraction of sphenochoanal polyp with functional endoscopic sinus surgery approach: A rare case a

by Budi Sutikno

Submission date: 21-Mar-2023 11:56AM (UTC+0800)

Submission ID: 2042369530

File name: 1-s2.0-S2210261222006757-main.pdf (1.64M)

Word count: 2585

Character count: 14184



Contents lists available at ScienceDirect

International Journal of Surgery Case Reports

journal homepage: www.elsevier.com/locate/ijscr



Case report

Extraction of sphenochoanal polyp with functional endoscopic sinus surgery approach: A rare case and review article

Bunga Aline Ditha, Budi Sutikno*

Department of Otorhinolaryngology, Head, and Neck Surgery, Faculty of Medicine, Universitas Airlangga, Dr. Soetomo General Academic Hospital, Surabaya, Indonesia



ARTICLE INFO

Keywords:
Chronic respiratory disease
FESS
Medical care
Sphenochoanal polyp
Polyp mass

ABSTRACT

Background: Sphenochoanal polyp, a rare case of nasal polyp, is a benign mass that originates in the sphenoid sinus and develops into a choanal polyp.
Case presentation: A 36-year-old Indonesian male complained of irregular right nasal obstruction and runny nose for one year. Physical examination showed soft tissue mass in the right nasal cavity, cyst retention in the right maxillary sinus, right sphenoid sinus, and cervical spondylosis. Diagnosis of sphenochoanal polyp was supported by nasoendoscopy and CT-Scan of paranasal sinuses. The patient got medical care and underwent functional endoscopic sinus surgery (FESS) and rinsed the nose with normal saline and topical steroids. Evaluation at six months after the surgery, the patient came without complaint and showed no sign of polyp mass or cysts recurrence, so the patient was declared to have a full recovery.
Discussion: FESS is proven effective for managing sphenochoanal polyp and minimizes complications post-surgery and repetition of the polyp.
Conclusion: FESS is recommended for management of sphenochoanal polyp in term of minimizing recurrency.

1. Introduction

Sphenochoanal polyps are a solitary benign mass derived from the sphenoid sinus, especially the anterior wall progressing into the nasopharynx to become a choanal polyp. Sphenochoanal polyp is a rare polyp, with only 3–6% of nasal polyps [1,2]. Polyp mass originates from the sphenoid sinus that expands through the sphenoid sinus ostium to the sphenoethmoid recess and choanal [3,4]. The recommended management of sphenochoanal polyps is functional endoscopic sinus surgery (FESS) which can see the location of the polyp so that the polyp can be extracted entirely with a low recurrence rate [1,5,6]. We are interested in reporting an Indonesian male with a sphenochoanal polyp. We wrote based on SCARE 2020 guidelines [7].

2. Case presentation

A 36-year-old male complained of irregular right nasal obstruction and runny nose for one year. The symptoms worsened in the last month with yellowish nasal discharge, thick consistency and foul odour. Other complaints included a bad smell in the right nose and pain behind the

right eye and top of the head. The patient denied the presence of pain in both cheeks, the base of the nose, the back of the head and the presence of mucus in the throat. The patient also denied a history of previous nasal pain, asthma, allergy, diabetes mellitus and hypertension.

The physical examination found a greyish mass with a slippery surface, a spongy impression of not easy bleeding and yellowish secretion on the middle meatus of the right nasal cavity. In the nasoendoscopy examination, a polyp-like mass in the right middle meatus spread to the choanal, while some parts of the polyp were inflamed (Fig. 1). The CT scan with contrast of the paranasal sinuses showed the impression of soft tissue mass in the right nasal cavity, cyst retention on the right maxillary sinus, right sphenoid sinus and cervical spondylosis (Fig. 2). The patient was diagnosed with a right unilateral sphenochoanal polyp.

The patient got medical care and underwent right functional endoscopic sinus surgery (FESS) [8]. Preparation for surgery included informed consent and antibiotic prophylaxis cefazolin 2 g intravenously. The patient was in supination position, reverse Trendelenberg 20°. The surgery location was disinfected with alcohol 70%. The 0.05% oxymetazoline was used to decongest the nasal cavity. At initial exploration, polyp mass was partially inflamed in the right nasal cavity extended to

* Corresponding author: Budi Sutikno, Department of Otorhinolaryngology, Head, and Neck Surgery, Faculty of Medicine, Universitas Airlangga, Dr. Soetomo General Academic Hospital, Jl. Mayjend Prof. Dr. Moestopo No. 6-8, Airlangga, Gubeng, Surabaya, East Java 60286, Indonesia.
E-mail addresses: budi-s@fk.unair.ac.id, budisutikno104@gmail.com (B. Sutikno).

<https://doi.org/10.1016/j.ijscr.2022.107429>

Received 24 May 2022; Received in revised form 12 July 2022; Accepted 17 July 2022

Available online 21 July 2022

2210-2612/© 2022 The Authors. Published by Elsevier Ltd on behalf of IJS Publishing Group Ltd. This is an open access article under the CC BY-NC-ND license (<http://creativecommons.org/licenses/by-nc-nd/4.0/>).

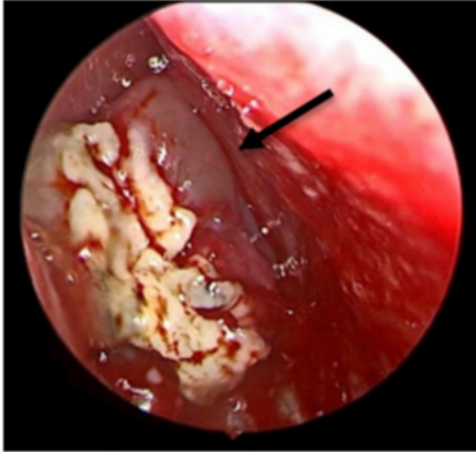


Fig. 1. Nasoendoscopy of the right nasal cavity showed polyp mass in the middle meatus area and mainly fulfilled the posterior part of the nasal cavity and reached choana (arrow).

choanal. The polyp was extracted as clean as possible until the base in the lateroinferior right of the sphenoid sinus using cutting forceps. Middle turbinate was pushed to the lateroposterior side (Fig. 3a–f). The bone was exposed from the sphenoid sinus, which was the polyp origin (Fig. 3f). Bleeding was treated with suction, cautery, and surgical installation in the surgical area. The surgery lasted 2 h without complication, and the amount of bleeding was about 100 ml. The patient received treatment of physiological normal saline for nasal irrigation and oral antibiotics cefadroxil of 500 mg twice daily for seven days post operatively.

Histopathology of the biopsy was not performed because it was microscopically similar to a polyp and the patient refused to biopsy because of his low income. Weekly post operative care, and in the sixth month, nasoendoscopy results showed complete wound healing. Nasoendoscopy examination showed a wide enlarged sphenoid ostium, the mucosal epithelialization was well established, and no polyp recurrence (Fig. 4).

3. Discussion

The sphenoidal polyps are often associated with precursors of the intramural cysts in the sphenoid sinus [1]. The sinus inflammation will obstruct the lymphatic vessels and the formation of intramural cysts. Then it develops into a polyp mass extending through the ostium to the choanal or nasopharynx. The presence of accessory ostium, the role of the urokinase enzyme, and arachidonic acid metabolism are also thought to cause sphenoidal polyps [9]. Fungal infections of the sinuses, inverted papilloma, internal carotid artery aneurysm, pituitary adenoma and neoplasm both primary and metastatic can also stimulate the formation of polyp masses in the sphenoid sinus [1,10].

Clinical manifestations in patients with sphenoidal polyps are unilateral nasal obstruction and chronic purulent discharge, with headache complaints, especially in the retro-orbital and vertex [1,11]. An intranasal polypoid mass may be obtained in anterior rhinoscopy examination, extending from the choanal to the nasopharynx [2,12]. Radiological examination is necessary to make the diagnosis. Computed tomography scans are superior to MRI because they are better in bone visualization and shorter examination times. On CT-scan, there is a description of soft tissue mass that fills the sphenoid sinus, extends through the ostium of the sphenoid sinus to the cavum nasi and may extend to the choanal and the nasopharynx in the posterior. The cyst mass in the right sphenoid sinus will push the ostium of the sphenoid sinus into the cavum nasi resulting in thrombosis from the lymphatic flow followed by sinus inflammation. Chronic inflammation will cause polyp mass [1,10].

The treatment used for sphenoidal polyps is simple polypectomy, but a newer and superior technique used nowadays using FESS. The FESS is conducted by performing intranasal polyp excision and extraction and enlarging the sphenoid sinus ostium endoscopically [8,13]. The surgery is first initiated by resectioning the inferior turbinate to expand the visual field [1,14]. Endoscopic sinus surgery may increase the accuracy in removing the origin of the polyp due to its ability to provide detail and magnified surgical view especially intra sphenoid sinus. Preservation of healthy mucosa is also enhanced by this endoscopic surgery. Blakesley forceps and Heuwieser antrum grasping forceps were used in this procedure. The duration of FESS is also faster than simple polypectomy [15,16].

The lack of FESS procedure is only applicable in certain advanced healthcare facilities. This is due to limited facilities and human resources. In addition, there is a risk of injury to the structures around the surgery area, cavernous sinus and cranial nerve II, III, IV, V1, V2, VI and carotid arteries. This risk will increase in simple polypectomy [17].

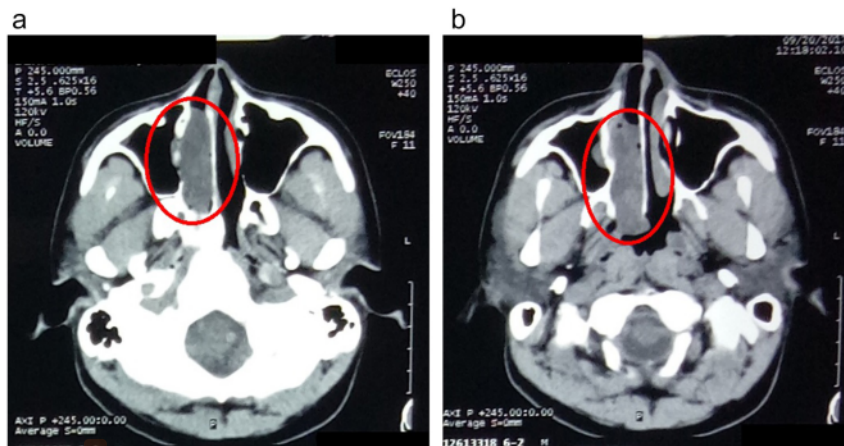


Fig. 2. (A–B) CT-scan of paranasal sinuses. A soft-tissue mass in the right nasal cavity expands to the choana (red circle).

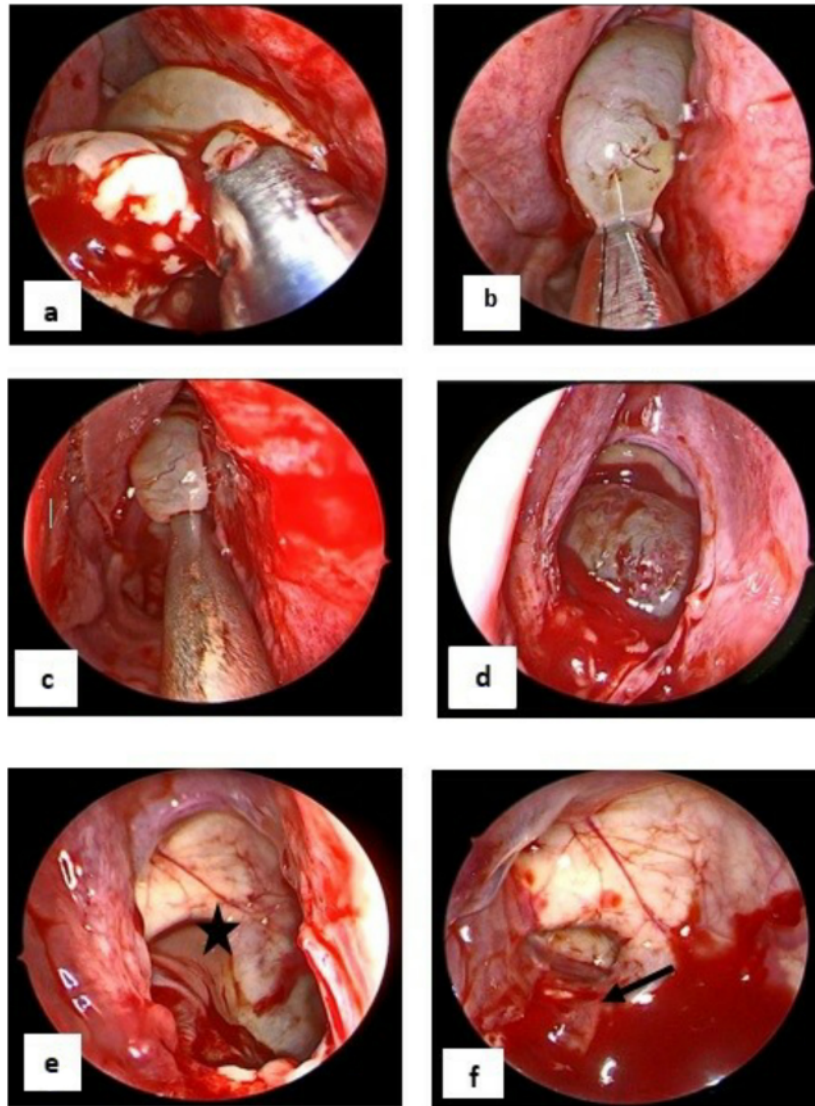


Fig. 3. (a–f) The polyp extraction process was located within the sphenoid sinus. The star marks (e) showed a wide ostium of the sphenoid sinus and a sphenoid sinus cavity. The arrow mark (f) showed bone exposure, which is the polyp origin in the lateroinferior side of the sphenoid sinus.

Evaluation of post-FESS aims to evaluate or monitor the wound healing process, complications and signs of recurrence. Post surgical nasal irrigation aims to facilitate a mucosal reepithelization and clean the nasal cavity from crust and secretion induced by the surgery [17,18].

Complications that can occur from FESS include infection, bleeding, sound changes, and injuries to the eyes and brain. Inflammation that can arise from the procedure is rhinitis or sinusitis, so appropriate antibiotic therapy is required to eliminate the causal microorganisms and prevent a recurrence. Analgesic therapy is given to reduce symptoms. Typically, minimal bleeding can occur post FESS. However, if bleeding occurs in large volumes and is accompanied by secretions, it must be evaluated and cauterized. The voice change is caused by the shift in sinus structure post FESS. Eye and brain injury complications are rare [13,15,16].

The functional endoscopic sinus surgery technique has a lower recurrence rate than simple polypectomy, 6 %. A simple polypectomy has a higher recurrence rate of 46 % [1,13,14]. The cause of recurrence

of sphenoidal polyps is an imperfect polyp extraction on intrasinus. This is due to the unidentified polyp origin on large polyp masses or intraoperative visualization limitations. The perfect identification of polyp origin and extraction is the basic of sphenoidal polyps management. In addition, other factors can cause inflammation in the mucosa, such as lifestyle, environment, and smoking habits [13,18].

4. Conclusion

Sphenoidal polyp, a rare case of nasal polyp, is a benign mass that originates in the sphenoid sinus and develops into a choanal polyp. The diagnosis of sphenoidal polyp needs to be confirmed by a better biopsy. FESS is the recommended management for sphenoidal polyps because it minimizes complications and recurrence of polyps.

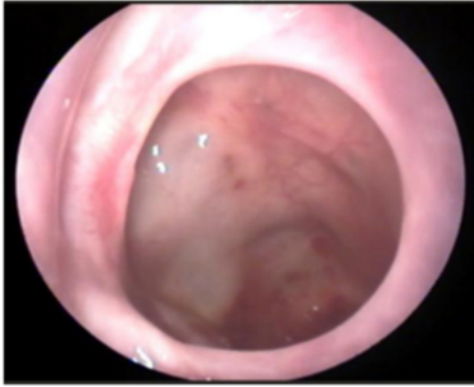


Fig. 4. The ostium of the sphenoid sinus was wide open, mucosal epithelialization is well established, and there is no polyp recurrence.

13 Provenance and peer review

Not commissioned, externally peer-reviewed.

1 Consent

Written informed consent was obtained from the patient for publication of this case report and accompanying images. A copy of the written consent is available for review by the Editor-in-Chief of this journal on request.

Ethical approval

Not applicable.

Funding

None.

Guarantor

Budi Sutikno is the person in charge of the publication of our manuscript.

Research registration number

Not applicable.

2 Credit authorship contribution statement

All authors contributed toward data analysis, drafting and revising the paper, gave final approval of the version to be published and agree to be accountable for all aspects of the work.

Declaration of competing interest

Bunga Aline Ditha and Budi Sutikno declare that they have no

conflict of interest.

Acknowledgement

We want to thank our editor "Fis Citra Ariyanto".

References

- [1] H. Al Okbi, R. Jain, R. Al-Abri, Sphenoidal polyp—surgical review, *Int. J. Pediatric Otorhinolaryngol. Extra* 5 (3) (2010) 99–101, <https://doi.org/10.1016/j.pedex.2009.04.003>.
- [2] A. Çeçen, O. Kemal, S. Atmaca, E. Kavaz, Isolated sphenoidal polyp: report of three cases, *Hippokratia* 21 (3) (2017) 150–153.
- [3] S.S. Bist, R. Kumar, S. Varshney, M. Bisht, Isolated sphenoidal polyp: a rare clinical entity, *Indian J. Otolaryngol. Head Neck Surg.* 59 (1) (2007) 56–57, <https://doi.org/10.1007/s12070-007-0016-3>.
- [4] M. Houda, E. Salk, B. Malika, E. Mehdi, R. Youssef, N. Hassan, et al., Sphenoidal polyp: case study of a rare entity and literature review, *Pan Afr. Med. J.* 37 (2020) 139, <https://doi.org/10.11604/pamj.2020.37.139.20832>.
- [5] S.A. Pol, S.K. Singhal, N. Gupta, A. Gulati, Sphenoidal polyp causing obstruction, *J. Pediatr. Surg. Case Rep.* 48 (2019), 101263, <https://doi.org/10.1016/j.jpesc.2019.10.1263>.
- [6] K. Tywoniuk, K. Haber, J. Mierzwiński, Sphenoidal polyps in children - a systematic review (1995–2021), *Braz. J. Otorhinolaryngol.* 1–9 (2022), <https://doi.org/10.1016/j.bjorl.2022.02.006>.
- [7] R.A. Agha, T. Franchi, C. Sohrabi, G. Mathew, A. Kerwan, The SCARE 2020 guideline: updating consensus surgical Case Report (SCARE) guidelines, *Int. J. Surg.* 84 (2020) 226–230, <https://doi.org/10.1016/j.ijsu.2020.10.034>.
- [8] D.F. Widhiono, B. Sutikno, A rare case of allergic fungal rhinosinusitis in Indonesian elderly: a case report and diagnostic procedure, *Ann. Med. Surg.* (2021) 66 (2021), 102400, <https://doi.org/10.1016/j.amsu.2021.102400>.
- [9] H.S. Mostafa, T.O. Fawzy, W.R. Jabri, E. Ayad, Lymphatic obstruction: a novel etiologic factor in the formation of antrochoanal polyps, *Ann. Otol. Rhinol. Laryngol.* 123 (6) (2014) 381–386, <https://doi.org/10.1177/0003489414522973>.
- [10] H. Birkent, S. Karahatay, A. Durmaz, B. Kurt, F. Tosun, Choanal polyp originating from the nasal septum: septochoanal polyp. *Kulak burun bogaz ihtisas dergisi, Ear Nose Throat J.* 19 (3) (2009) 163–166.
- [11] Y. Kizil, U. Aydil, A. Ceylan, S. Uslu, V. Baştürk, F. İleri, Analysis of choanal polyps, *J. Craniofac. Surg.* 25 (3) (2014) 1082–1084, <https://doi.org/10.1097/scs.0000000000000543>.
- [12] Y. Hori, K. Taniguchi, T. Okabe, A. Sakamoto, A case of unexpectedly difficult intubation caused by a large asymptomatic choanal polyp, *JA Clin. Rep.* 2 (1) (2016) 2, <https://doi.org/10.1186/s40981-016-0028-7>.
- [13] J.R. Gardner, J.B. Campbell, O. Daigle, D. King, A. Kanaan, Operative and postoperative outcomes in elderly patients undergoing endoscopic sinus surgery, *European archives of oto-rhino-laryngology : official journal of the European Federation of Oto-Rhino-Laryngological Societies (EUROS) : affiliated with the German Society for Oto-Rhino-Laryngology - Head and Neck Surgery.* 278 (5) (2021) 1471–1476, <https://doi.org/10.1007/s00405-020-06453-2>.
- [14] B.K. Tan, A.P. Lane, Endoscopic sinus surgery in the management of nasal obstruction, *Otolaryngologic clinics of North America.* 42 (2) (2009) 227–240, <https://doi.org/10.1016/j.otc.2009.01.012>, vii.
- [15] S. Suzuki, H. Yasunaga, H. Matsui, K. Fushimi, K. Kondo, T. Yamasoba, Complication rates after functional endoscopic sinus surgery: analysis of 50,734 Japanese patients, *Laryngoscope* 125 (8) (2015) 1785–1791, <https://doi.org/10.1002/lary.25334>.
- [16] M.R. Chaaban, N. Rana, J. Baillargeon, G. Baillargeon, V. Resto, Y.F. Kuo, Outcomes and complications of balloon and conventional functional endoscopic sinus surgery, *Am. J. Rhinol. Allergy* 32 (5) (2018) 388–396, <https://doi.org/10.1177/1945892418782248>.
- [17] A. Al-Mujaini, U. Wali, M. Alkhabori, Functional endoscopic sinus surgery: indications and complications in the ophthalmic field, *Oman Medical Journal* 24 (2) (2009) 70–80, <https://doi.org/10.5001/omj.2009.18>.
- [18] M. Chan, S. Carrie, Training and assessment in functional endoscopic sinus surgery, *J. Laryngol. Otol.* 132 (2) (2018) 133–137, <https://doi.org/10.1017/s0022215117002183>.

Extraction of sphenchoanal polyp with functional endoscopic sinus surgery approach: A rare case a

ORIGINALITY REPORT

14%

SIMILARITY INDEX

12%

INTERNET SOURCES

14%

PUBLICATIONS

0%

STUDENT PAPERS

PRIMARY SOURCES

1	Constantinos Mourouzis, Theodoros Panagiotopoulos, George Rallis. "Open parotid gland biopsy under combined superficial cervical plexus and auriculotemporal nerve block ", Research Square Platform LLC, 2023 Publication	2%
2	pdfs.semanticscholar.org Internet Source	2%
3	www.ijitee.org Internet Source	1%
4	balimedicaljournal.org Internet Source	1%
5	helda.helsinki.fi Internet Source	1%
6	"Liraglutide/paclitaxel", Reactions Weekly, 2022 Publication	1%
7	medwinpublishers.com Internet Source	1%

8	trepo.tuni.fi Internet Source	1 %
9	squ.pure.elsevier.com Internet Source	1 %
10	www.ijop.net Internet Source	1 %
11	Al Okbi, H.. "Sphenochoanal polypSurgical review", International Journal of Pediatric Otorhinolaryngology Extra, 201009 Publication	1 %
12	repository-tnmgrmu.ac.in Internet Source	1 %
13	spnefro.pt Internet Source	1 %

Exclude quotes Off

Exclude matches < 10 words

Exclude bibliography On

Extraction of sphenochoanal polyp with functional endoscopic sinus surgery approach: A rare case a

GRADEMARK REPORT

FINAL GRADE

/0

GENERAL COMMENTS

Instructor

PAGE 1

PAGE 2

PAGE 3

PAGE 4
