



Source details

International Journal of Surgery Case Reports

Scopus coverage years: from 2010 to Present

Publisher: Elsevier

ISSN: 2210-2612

Subject area: [Medicine: Surgery](#)

Source type: Journal

[View all documents >](#)

[Set document alert](#)

[Save to source list](#) [Source Homepage](#)

CiteScore 2022

1.0



SJR 2022

0.193



SNIP 2022

0.580



[CiteScore](#) [CiteScore rank & trend](#) [Scopus content coverage](#)

i Improved CiteScore methodology



CiteScore 2022 counts the citations received in 2019-2022 to articles, reviews, conference papers, book chapters and data papers published in 2019-2022, and divides this by the number of publications published in 2019-2022. [Learn more >](#)

CiteScore 2022

$$1.0 = \frac{3,869 \text{ Citations 2019 - 2022}}{4,033 \text{ Documents 2019 - 2022}}$$

Calculated on 05 May, 2023

CiteScoreTracker 2023

$$0.8 = \frac{3,107 \text{ Citations to date}}{3,904 \text{ Documents to date}}$$

Last updated on 07 June, 2023 • Updated monthly

CiteScore rank 2022

Category	Rank	Percentile
Medicine		
Surgery	#325/495	34th

[View CiteScore methodology >](#) [CiteScore FAQ >](#) [Add CiteScore to your site](#)

About Scopus

[What is Scopus](#)

[Content coverage](#)

[Scopus blog](#)

[Scopus API](#)

[Privacy matters](#)

Language

[日本語版を表示する](#)

[查看简体中文版本](#)

[查看繁體中文版本](#)

[Просмотр версии на русском языке](#)

Customer Service

[Help](#)

[Tutorials](#)

[Contact us](#)

ELSEVIER

[Terms and conditions ↗](#) [Privacy policy ↗](#)

Copyright © Elsevier B.V ↗. All rights reserved. Scopus® is a registered trademark of Elsevier B.V.


We use cookies to help provide and enhance our service and tailor content. By continuing, you agree to the use of cookies ↗.



International Journal of Surgery Case Reports

Open access

Submit your article 


Guide for authors 


 Menu

 Search in this journal

Volume 97

August 2022


 Download full issue

 Previous vol/issue

Next vol/issue 

Receive an update when the latest issues in this journal are published

 Sign in to set up alerts

 Open access

Editorial Board

Article 107501


 View PDF


Correspondence

FEEDBACK 

International Journal of Surgery Case Reports

Open access

Submit your article 

Guide for authors 

 Menu



Case Reports

Case report ● Open access

Dilated sigmoid colon with Chilaiditi's sign mimicking diaphragmatic hernia: A case report

Suveksha Shaurya Shah, Dhiraj Chaurasia, Dinjul Katuwal

Article 107373



[View PDF](#)

Article preview 

Case report ● Open access

Infected urachal cyst in an adult, report of two observations

P.M. Faye, M.L. Gueye, O. Thiam, A. Niasse, ... M. Cisse

Article 107394



[View PDF](#)

Article preview 

Case report ● Open access

Synchronous breast cancer and non-Hodgkin lymphoma: A case report

Salman Ardi Syamsu, Rino Setiady, Nilam Smaradania, Prihantono, ... Muhammad Faruk

Article 107398



[View PDF](#)

Article preview 

Case report ● Open access

A rare case report of tricorpora penile fracture associated with urethral disruption

Gede Wirya Kusuma Duarsa, Muhlis Yusuf, Yudhistira Pradnyan Kloping, Ilham Akbar Rahman, Soetojo


Article 107351

FEEDBACK 

International Journal of Surgery Case Reports

Open access

Submit your article 

Guide for authors 

 Menu



Article 107380

 [View PDF](#) Article preview 

Case report ● *Open access*

Successful use of stereotactic navigation in posterior spinal fusion T10-S2 with bilateral iliac screw fixation in a patient with prior spinal surgeries and osteoporosis: A case report

Nolan J. Brown, Shane Shahrestani, Joshua S. Kurtz, Ryan S. Beyer, ... Joseph Osorio

Article 107380

 [View PDF](#) Article preview 

Case report ● *Open access*

Massive retroperitoneal cyst impersonating ovarian tumor: A case report

Hidar Alibrahim, Amany Al Ali, Haidara Bohsas, Safaa Mohamed Alsharief Ahmed, ... Sarya Swed

Article 107393

 [View PDF](#) Article preview 

Case report ● *Open access*

Chylous ascites and pancreatic pseudocyst on a child following blunt abdominal trauma; a case report

Kennedy Misso, Bahati Robert, Joachim Magoma, Tendai Joylene, David Msuya

Article 107406

 [View PDF](#) Article preview 

Case report ● *Open access*

Mesenteric cyst manifested as obesity, gastroesophageal reflux, urinary incontinence, and abdominal mass during pregnancy—Case report and literature review

Francisco Aguilar-Espinosa, Rodolfo Salcedo-Vargas, Hiram Alfonso Galván-Bizarro, Carlos Rubén

FEEDBACK 

Submit your article ↗

Guide for authors ↗

Menu



(PRF) to accelerate bone healing

Ahmad Taufik S, Adnanto Wiweko, Didit Yudhanto, Mohammad Rizki, ... Rohadi Muhammad Rosyidi
Article 107370

 [View PDF](#) Article preview ▾

Case report ● Open access

A rare case of appendiceal tip complete attachment to a sigmoid diverticulum: An appendiceal phlegmon case report

Farzad Vaghef Davari, Arezou Hashem Zadeh
Article 107379

 [View PDF](#) Article preview ▾

Case report ● Open access

Laparoscopic total gastrectomy performed for juvenile polyposis of the stomach: A case report

Misato Ito, Hisashi Onozawa, Masaru Saito, Hirofumi Ami, ... Kono Koji
Article 107368

 [View PDF](#) Article preview ▾

Case report ● Open access

Multispecialty surgical management of large clavicular tumor: A case report

Mohammad Aladaileh, Tom Moran, Austin Duffy, Karen Redmond, David O'Briain
Article 107375


 [View PDF](#) Article preview ▾


Case report ● Open access

FEEDBACK 

International Journal of Surgery Case Reports

Open access

Submit your article 

Guide for authors 

 Menu



Case report ● Open access

Multiple drill hole osteotomy and Herbert screw for correcting a-2 years ring finger phalanx media malunion: A case report

Huda Fajar Arianto, Muhammad Bayu Zohari Hutagalung, Yunus Abdul Bari

Article 107410



[View PDF](#)

Article preview 

Case report ● Open access

Deep anterior lamellar limbo-keratoplasty for bilateral limbal stem cell deficiency with corneal scarring in chemical injury sequelae: Two case reports

Neha Jain, Anahita Kate, Sayan Basu

Article 107409



[View PDF](#)

Article preview 

Case report ● Open access

Long-term results of sclerotherapy for cervical-thoracic-mediastinal lymphatic and venous malformations: A case report

Quan-Feng LUO

Article 107411



[View PDF](#)

Article preview 

Case report ● Open access

Bilateral ovarian mucinous carcinoma (stage III) with omental involvement and incidental hydronephrosis: A rare case report

Diptee Poudel, Kshitiz Acharya, Navin Poudel, Ashmita Adhikari, ... Suvana Maskey

Article 107415



[View PDF](#)

Article preview 

FEEDBACK 

International Journal of Surgery Case Reports

Open access

Submit your article [↗](#)

Guide for authors [↗](#)

Menu



[View PDF](#) [Article preview](#) [▼](#)

Case report ● *Open access*

Diagnostic approach and management of bilateral pneumothorax due to silicosis in Indonesian male: A rare case

Risa Natalia Siburian, Kristin Purnama Dewi, Winariani Koesoemoprodjo

Article 107407

[View PDF](#) [Article preview](#) [▼](#)

Case report ● *Open access*

Case report on peri-operative surgical and anaesthetic management of ruptured humongous lung abscess

Khalid Maudood Siddiqui, Akbar Azizullah, Muhammad Saad Yousuf

Article 107381

[View PDF](#) [Article preview](#) [▼](#)

Case report ● *Open access*

The evaluation of the effect of performing guided lid surgery with enucleation of a cystic lesion; a case report

Aly Khaled Hussein Abdelazez, Hossam El-Dien Hany, Mohamed Ehab Gamal El Din, Mahmoued Medhat Mostafa El Meregny, ... Mohammed Daa Zein El Abdien

Article 107385

[View PDF](#) [Article preview](#) [▼](#)

Case report ● *Open access*


Laparoscopic jejunostomy for enteral nutrition in gastric cancer patients: A report of two cases: A case report


Hiroshi Tsuchiya, Itaru Yasufuku, Naoki Okumura, Nobuhisa Matsuhashi, Takao Takahas

FEEDBACK

International Journal of Surgery Case Reports

Open access

Submit your article 

Guide for authors 

 Menu



Qin Ou, Ying-dong Li, Jun Chen, Lin-lin Yuan, Wenfang Li

Article 107408



[View PDF](#)

Article preview 

Case report ● *Open access*

Thyroid angiosarcoma: A case report and review of literature

L. Benbella, I. Elouarith, H.E.L. Ouazzani, Z. Bernoussi, ... F. Zouaidia

Article 107358



[View PDF](#)

Article preview 

Case report ● *Open access*

Intraparenchymal fiberoptic intracranial pressure monitoring and decompressive craniectomy in meningioma case with critical intracranial pressure: A case report during COVID-19 pandemic

Tedy Apriawan, Rizki Meizikri, Endra Wibisono Harmawan, Heru Kustono

Article 107364



[View PDF](#)

Article preview 

Case report ● *Open access*

Duodenal perforation due to migrated biliary stent: Case report

Prarthana Pachhai, Rabi Khadka, Narendra Maharjan, Deepak Sharma, ... Ramesh Singh Bhandari

Article 107354



[View PDF](#)

Article preview 

Case report ● *Open access*

Coronary artery to pulmonary artery fistula: Catheter or scalpel? A case report

FEEDBACK 

International Journal of Surgery Case Reports

Open access

Submit your article ↗

Guide for authors ↗

Menu



squamous cell carcinoma: A case report

Tiuri E. Kroese, Peter S.N. van Rossum, Sylvia van der Horst, Stella Mook, ... Richard van Hilleberg
Article 107423



View PDF

Article preview ▾

Case report ● Open access

Botryoid rhabdomyosarcoma of the uterine cervix: Report case

R.E.L. Qasseh, F. Bouyalik, S. Majidi, M. Moutahir, ... M. El Keroumi
Article 107389



View PDF

Article preview ▾

Case report ● Open access

Perirenal cystic lymphangioma mimicking a renal cyst in an elderly patient: Case report

A. Lahfidi, W.M. Traore, K. Imrani, C. Ayadi, ... N. Moatassim Billah
Article 107403



View PDF

Article preview ▾

Case report ● Open access

Idiopathic lymphatic mesenteric cyst of the proximal jejunum: A case report of an unusual clinical presentation

Michele Ghielmetti, Kerstin J. Neuschütz, Anna Hirschmann, Katharina Marston, ... Marco von Strauss und Torney
Article 107402



View PDF

Article preview ▾


Case report ● Open access

FEEDBACK

International Journal of Surgery Case Reports

Open access

Submit your article 

Guide for authors 

 Menu



Case report ● Open access

Localized retroperitoneal Rosai-Dorfman-Destombes disease as a cause of fever of unknown origin in adults. Case report and review of the literature

Georgi Popivanov, Magdalena Baymakova, Pavel Bochev, Dimitar Penchev, ... Ventsislav Mutafchiyski
Article 107414



View PDF

Article preview 

Case report ● Open access

Zinner's syndrome: A rare diagnosis of congenital seminal vesicle cyst and renal agenesis on basis of radiological imaging and its management

Avishkar Raj Regmi, Sarmendra Mishra, Adarsh Gurung, Archana Acharya, ... Ajnish Ghimire
Article 107434



View PDF

Article preview 

Case report ● Open access

Conjunctival myxoma masquerading as conjunctival lymphoma: A case report

Majed Alkharashi, Hind M. Alkatan, Ahmed A. Alhumidi, Wael Otaif
Article 107441



View PDF

Article preview 

Case report ● Open access

One anastomosis gastric bypass with fundoplication of remnant stomach for weight regain prevention: Case report

O. Ospanov, K. Nadirov, V. Koikov, N. Zharov
Article 107431



View PDF

Article preview 

FEEDBACK 

Submit your article ↗

Guide for authors ↗

Menu



 [View PDF](#) Article preview ▾

Case report ● Open access

Triple-valve replacement for *Rhizobium radiobacter* endocarditis with septic shock in an adult with ventricular septal defect. A case report

Andrei George Iosifescu, Ioana Marinică, Alexandru Popescu, Alina Teodora Timișescu, ... Vlad Anton Iliescu
Article 107401

 [View PDF](#) Article preview ▾

Case report ● Open access

Case report of an angiosarcoma of the abdominal wall during liraglutide injections: A coincidence?

Eric Bergeron, Meriamé Dami, Xuan Vien Do, Chantal Vallee, Jonathan Noujaim
Article 107444

 [View PDF](#) Article preview ▾

Case report ● Open access

Periosteal osteosarcoma of the clavicle: A case report and review of the literature

Son Do Le Hoang, Huy Hoang Quoc, Bach Nguyen, Binh Le Nguyen, ... Vinh Pham Quang
Article 107430

 [View PDF](#) Article preview ▾

Case report ● Open access


Giant omental lipoma, a rare etiology of right-iliac fossa pain in adult: A surgical case report


Athary Saleem, Jumana Alfadhli, Abrar Alawadhi, Maher Hassan, Khaled Alshammari
Article 107428

FEEDBACK 

International Journal of Surgery Case Reports

Open access

Submit your article 

Guide for authors 

 Menu



Abdulaziz Alkheraji, Sultana Dorai, Kheema Alaudini, Fawzi Aljassir

Article 107437



[View PDF](#)

Article preview 

Case report ● *Open access*

Dumbbell-shaped meningioma of Meckel's cave mimicking trigeminal schwannoma: A case report

Chun-Pi Chang, Cheng-Siu Chang, Meng-Yin Yang, Chiung-Chyi Shen

Article 107369



[View PDF](#)

Article preview 

Case report ● *Open access*

A rare case of obstructed labor due to sever uterine prolapse; a case report and literature review

Elham Askary, Shaghayegh Moradi Alamdarloo, Zinat Karimi, Anushe Karimzade

Article 107344



[View PDF](#)

Article preview 

Case report ● *Open access*

Von Hippel-Lindau disease: A case report

Durga Neupane, Alok Dahal, Nimesh Lageju, Lokesh Shekher Jaiswal, ... Srista Manandhar

Article 107417



[View PDF](#)

Article preview 

Case report ● *Open access*


Jejunal diverticulitis: A new case report and a review of the literature


Elmontassar Belleh Zafouri, Imen Ben Ismail, Marwen Sghaier, Saber Rebi, Ayoub Zoghlemi

FEEDBACK 

International Journal of Surgery Case Reports

Open access

Submit your article 

Guide for authors 

 Menu



A. Chirihan, S. Ezzaky, I. Eloual, A. Madani, ... F.Z. Laamrani

Article 107447



[View PDF](#)

Article preview 

Case report  *Open access*

Odontogenic brain abscess due to *Anaerococcus prevotii* infections: A case report and review article

Suharyadi Sasmanto, Eddy Bagus Wasito

Article 107450



[View PDF](#)

Article preview 

Case report  *Open access*

Ectopic ACTH syndrome complicated by hypercortisolism-associated urolithiasis. A case report

Emilio de León-Castorena, Dulce María López-Sotomayor, Luis Edwin Gaona-Garza, Mario Alberto Treviño-Aguillón, Alejandro Talamas-Mendoza

Article 107449



[View PDF](#)

Article preview 

Case report  *Open access*

Infectious hematogenous lumbar spondylodiscitis caused by *Actinotignum schaalii* in a 74-year-old man: A case report

Ekkehard F. Röpke, Martin Chwoika, Tim Treber, Jens Meyer, Christoph Paasch

Article 107453



[View PDF](#)


Article preview 


Case report  *Open access*

FEEDBACK 

International Journal of Surgery Case Reports

Open access

Submit your article 

Guide for authors 

 Menu



Case report ● Open access

Extraction of sphenchoanal polyp with functional endoscopic sinus surgery approach: A rare case and review article

Bunga Aline Ditha, Budi Sutikno

Article 107429



[View PDF](#)

Article preview 

Case report ● Open access

Acute appendicitis secondary to metastatic breast cancer. 12 Years after first primary tumor diagnosis. A case report

Victoria G. Hughes, Pedro Osácar, Darío Ramallo

Article 107452



[View PDF](#)

Article preview 

Case report ● Open access

Intercostal nerve block is effective in open biopsies of the anterior mediastinal region: Case report and review

Marina Brito Gondar, Mariana Fernandes, Pablo Mondragon, Andres Hagerman, Lennart Magnusson

Article 107461



[View PDF](#)

Article preview 

Case report ● Open access

Leiomyosarcoma of the small bowel: A case report and literature review

Mahdi Bouassida, Hazem Beji, Mohamed Fadhel Chtourou, Saloua Nechi, ... Hassen Touinsi

Article 107456



[View PDF](#)


Article preview 

FEEDBACK 

International Journal of Surgery Case Reports

Open access

Submit your article 

Guide for authors 

 Menu



Case report ● Open access

Minor lobulation of the testis, mimicking polyorchidism when inflammed, discussion of a rare case: A case report

Mohammad Hadi Gharib, Reza Zahedpasha

Article 107448



[View PDF](#)

Article preview 

Case report ● Open access

Perforated ileum as the initial presentation of Crohn's disease, a case report

Robel Tadesse, Biniam Ewnte, Kale'ab Tesfaye

Article 107305



[View PDF](#)

Article preview 

Case report ● Open access

Human papillomavirus-related carcinoma with adenoid cystic-like features of the sinonasal tract: Case report and literature review

Zephania Saitabau Abraham, Caroline Philip Ngimba, Atuganile Edward Malango, Alita Mrema, ... Edda Vuhahula

Article 107462



[View PDF](#)

Article preview 

Case report ● Open access

Case Report-Right atrial myxoma with total anomalous pulmonary venous connection in neonate

Shantanu Gomase, Sachin Kuthe, Manish Sonkusale

Article 107438

FEEDBACK 

International Journal of Surgery Case Reports

Open access

Submit your article [↗](#)

Guide for authors [↗](#)

Menu



ARISA KUNITA, MASAYUKI TOSHIDA, TAKESHI MIYATA, AKIHIKO TOSHIDA, ... SHIMI TAKAYAMA

Article 107435



[View PDF](#)

Article preview [v](#)

Case report ● *Open access*

Granulomatosis with polyangiitis presenting with intestinal obstruction: A case report

Reem Alawna, Tala Jalamneh, Maram Massad, Noor Alawna, ... Fadi Abu Alrub

Article 107446



[View PDF](#)

Article preview [v](#)

Case report ● *Open access*

Mesenteric textiloma early discovery in a 31-year-old female: A case report

Jeannot Baanitse Munihire, Moise Muhindo Valimugighe, Nyundo W. Martin

Article 107439



[View PDF](#)

Article preview [v](#)

Case report ● *Open access*

Unconstrained one-stage total knee arthroplasty PS design in patient with secondary osteoarthritis due to granulomatous infection with medial femoral condyle defect: A case report

Nur Rahmansyah, Dicky Mulyadi, Raden Moechammad Satrio Nugroho Magetsari, Aditya Fuad Robby Triangga

Article 107469



[View PDF](#)


Article preview [v](#)

Case report ● *Open access*

Gallbladder volvulus with gangrenous cholecystitis – A case report

FEEDBACK

Submit your article 

Guide for authors 

 Menu



Yusuf Rachman, Yosua Hardja

Article 107465



[View PDF](#)

Article preview 

Case report  *Open access*

First case report of gastric outlet obstruction due to aortofemoral bypass Dacron graft erosion of the duodenum treated with neo aortoiliac system procedure

Juan Fernando Muñoz, Fernando Mejía, Manuel Hosman, Luis Felipe Cabrera-Vargas, ... Alexis Rafael Narvaez-Rojas

Article 107400



[View PDF](#)

Article preview 

Case report  *Open access*

Giant fibrovascular polyps of the esophagus. Trans oral versus surgical approach. Case report and systematic literature review

Valentina Ferri, Emilio Vicente, Yolanda Quijano, Hipolito Duran, ... Riccardo Caruso

Article 107412



[View PDF](#)

Article preview 

Case report  *Open access*

Acute pancreatitis secondary to spontaneous intramural duodenal hematoma: A case report and a review of the literature

Wissal Skhiri, Marwa Moussaoui, Jamal Saad, Mohamed Maatouk, ... Ines Mazhoud

Article 107424



[View PDF](#)

Article preview 


Case report  *Open access*

FEEDBACK 

International Journal of Surgery Case Reports

Open access

Submit your article 

Guide for authors 

 Menu



Case report ● Open access

Esophageal extraskeletal neoplasm Ewing's sarcoma: Case report

Hina Khalid, Niaz Hussain, Rafay Shamshad

Article 107399



[View PDF](#)

Article preview 

Case report ● Open access

A rare incidence of primary Synovial Spindle Cell Sarcoma in a 46-year-old male, successfully managed by surgical intervention-A Case Report

Omar Hariri, Omar Al Laham, Zein Ibrahim Basha, Hisham Hamzeh

Article 107442



[View PDF](#)

Article preview 

Case report ● Open access

Bilateral tubal ectopic gestation: Complication in a patient with previous ectopic pregnancy, rare case report

Willbroad Kyejo, Davis Rubagumya, Zainab Fidaali, Ahmed Jusabani, ... Shweta Jaiswal

Article 107470



[View PDF](#)

Article preview 

Case report ● Open access

Collar-button abscess as a complication of infected hematoma in the setting of uncontrolled type 2 diabetes

Jennifer Adams, Daniel Habenicht, Savvas Poulos

Article 107427



[View PDF](#)

Article preview 

FEEDBACK 

International Journal of Surgery Case Reports

Open access

Submit your article ↗

Guide for authors ↗

Menu



View PDF Article preview ▾

Case report ● Open access

Generalized peritonitis secondary to spontaneous rupture of the urinary bladder in a diabetic patient: A case report

Foolad Eghbali, Hesam Mosavari, Ahmad Madankan, Vahid Hariri, ... Mansour Bhahdoust

Article 107458

View PDF Article preview ▾

Case report ● Open access

Ileocolic intussusception caused by giant submucosal colonic lipoma: A rare case report

Nahyeon Park, Jung Cheol Kuk, Eung Jin Shin, Su Sie Chin, Dae Ro Lim

Article 107451

View PDF Article preview ▾

Case report ● Open access

An extensive squamous cell carcinoma of the auricle: From curative to reconstructive treatment. A case report

Sara Halily, Karmouch Mohamed Amine, Youssef Oukessou, Sami Rouadi, ... Mohammed Mahtar

Article 107413

View PDF Article preview ▾

Case report ● Open access

Robot-assisted laparoscopic hysterectomy for early-stage endometrial cancer with massive uterine leiomyomas: A case report

Akiyo Kakibuchi, Fumitake Ito, Tetsuya Kokabu, Hiroyuki Okimura, ... Taisuke Mori


Article 107473

FEEDBACK

International Journal of Surgery Case Reports

Open access

Submit your article 

Guide for authors 

 Menu



J.H. Gonzalez-Cortes, A.D. Trevino-Herrera, J.E. Gonzalez-Cantu, A. Sudhaikar, ... J. Mohamed-Hamsho

Article 107443



[View PDF](#)

Article preview 

Case report ● *Open access*

Acute kidney injury leading to the diagnosis of sporadic testicular Burkitt's lymphoma: A case report

Sanda Mrabet, Yosr Chaabouni, Mohamed Ben Hmida

Article 107471



[View PDF](#)

Article preview 

Case report ● *Open access*


Langerhans cell histiocytosis of the rib in an adult: A case report and review of the literature

Shengliang Zhao, Chao Luo, Bo Tang, Liang Chen, ... Hua Li

Article 107432



[View PDF](#)

Article preview 

Case report ● *Open access*


A case of primary mediastinal seminoma with superior vena cava syndrome and large intracardiac thrombus

Vicky Reinold Christofel Rampengan, Arief Bakhtiar

Article 107478



[View PDF](#)

Article preview 

Case report ● *Open access*

FEEDBACK 

International Journal of Surgery Case Reports

Open access

Submit your article [↗](#)

Guide for authors [↗](#)

☰ Menu



Case report ● Open access

Bowel obstruction secondary to gallstone ileus within a strangulated inguinal hernia: Report of a rare diagnosis

Mojtaba Ahmadinejad, Mohammad Hadi Bahri, Armin Tajik, Nooshin Taherzadeh-ghahfarokhi, Javad Zebarjadi Bagherpour

Article 107445



[View PDF](#)

Article preview [▼](#)

Case report ● Open access

Hidden appendix: A case report and literature review of perforated acute appendicitis masquerading as acute cholecystitis

E Ashwini, M Varun, PS Saravanan, Sunil Julian, P Sandeep

Article 107480



[View PDF](#)

Article preview [▼](#)

Case report ● Open access

Precise diagnosis of acute mesenteric ischemia using indocyanine green imaging prevents small bowel resection: A case report

Kohei Furusawa, Masanori Yoshimitsu, Hiroyoshi Matsukawa, Kuniomi Oi, ... Akihisa Tamura

Article 107463



[View PDF](#)

Article preview [▼](#)

Case report ● Open access

Wide-awake local anesthesia for open rotator cuff repair: A case report

Farsad Biglari, Amir Sabaghzadeh, Adel Ebrahimpour, Mehrdad Sadighi, ... Meisam Jafari Kafiabadi

Article 107494



[View PDF](#)

Article preview [▼](#)

FEEDBACK

International Journal of Surgery Case Reports

Open access

Submit your article ↗

Guide for authors ↗

Menu



arthroscopic assisted intraarticular osteotomy

Oryza Satria, Irsan Abubakar, Syahdi Farqani, Irfan Kurnia Pratama

Article 107391



View PDF

Article preview ▾

Mini review ● Open access

Osteoclast-like stromal giant cells in invasive ductal breast cancer: A case series

Giustina Angellotti, Giovanni Tomasicchio, Alda Elena Montanaro, Michele Telgrafo, ... Clelia Punzo

Article 107421



View PDF

Article preview ▾

Mini review ● Open access

Case series of diagnosis and surgery challenges in parathyroid carcinoma

Diani Kartini, Ahmad Kurnia, Erwin Danil Yulian, Sonar Soni Panigoro, ... Jessica Wardana

Article 107390



View PDF

Article preview ▾

Mini review ● Open access

Laparoscopic subtotal reconstituting cholecystectomy in type II & III Mirizzi syndrome:
Case series of 5 patients

Gerardo Chávez Saavedra, Dante Ríos Segovia, Raúl Hernandez Centeno, Nicolas Joaquín Fernández Pérez

Article 107425



View PDF

Article preview ▾

Mini review ● Open access

Cerebellar primary central nervous system lymphoma: Case series report

Minglian He, Jun Zhong, Xuegang Li, Yujie Chen, Fei Li

FEEDBACK

International Journal of Surgery Case Reports

Open access

[Submit your article](#) ↗

[Guide for authors](#) ↗

☰ Menu



Shehryar Ahmed Khan Niazi, Muhammad Umer Mukhtar, Rameez Hassan, Qasim Mehmood

Article 107459



[View PDF](#)

[Article preview](#) ▼

Mini review ● *Open access*

Diagnosis and Management of oro-antral fistula: Case series and review

Asma Azzouzi, Lamiae Hallab, Saliha Chbicheb

Article 107436



[View PDF](#)

[Article preview](#) ▼

Mini review ● *Open access*

Case series of high-grade soft tissue sarcoma of the lower limb with delayed diagnosis: Experience at a tertiary hospital in northern Tanzania

Jay Lodhia, Gregory Goodluck, Joylene Tendai, Ellyagape Urassa, ... Alex Mremi

Article 107475



[View PDF](#)

[Article preview](#) ▼

Mini review ● *Open access*

Radiofrequency ablation for benign thyroid nodule treatment: New solution in our center

Monica Bellynda, Muhammad Rizki Kamil, Kristanto Yuli Yarso

Article 107418



[View PDF](#)

[Article preview](#) ▼



ELSEVIER

Copyright © 2023 Elsevier B.V. or its licensors or contributors.
ScienceDirect® is a registered trademark of Elsevier B.V.

RELX™

FEEDBACK

International Journal of Surgery Case Reports

Open access

[Submit your article ↗](#)

[Guide for authors ↗](#)

☰ Menu





ELSEVIER



International Journal of Surgery Case Reports

Editor-in-Chief

Professor David Rosin, Barbados, West Indies

Managing and Executive Editor

Dr Riaz Agha, London, UK

Assistant Managing Editor

Maliha Agha, London, UK

Senior Editors

Professor Hasan Alam, Michigan, USA
Professor Raafat Afifi, Cairo, Egypt
Dr Juan Barret, Barcelona, Spain
Mr Ben Challacombe, London, UK
Dr Xiaoping Chen, Wuhan, China

Dr Burcin Ekser, Indianapolis, USA
Professor Joseph W Y Lau, Shatin, Hong Kong
Dr Oliver Muensterer, New York, USA
Dr Selwyn Rogers, Galveston, Texas
Professor Jamsheer Talati, Karachi, Pakistan

Dr Mangesh Thorat, London, UK
Professor Fu Chan Wei, Taipei, Taiwan
Professor Rudy Leon De Wilde, Oldenburg, Germany

Associate Editors

Professor Roberto Coppola, Rome, Italy
Dr Veerappan Kasivisvanathan, London, UK
Dr Richard Keijzer, Winnipeg, Canada, USA
Dr Boris Kirshtein, Beer Sheva, Israel

Professor James McCaul, London, UK
Miss Emma McGlone, London, UK
Dr Dattatraya Muzumdar, Mumbai, India
Professor Andy Petroianu, Minas Gerais, Brazil

Mr Shahzad Raja, London, UK
Dr Kandiah Raveedran, Ipoh, Malaysia
Dr Daniel Yeh, Boston, USA

Assistant Editors

Dr Rafid Al-Mahfoudh, Oxford, UK
Dr Hussein Atta, Boston, USA
Dr Mohammad Bashashati, Texas, USA
Professor Somprakus Basu, Varanasi, India
Mr Andrew Beamish, Cardiff, UK
Dr Anthony Charles, North Carolina, USA
Dr Amitava Das, Hyderabad, India
Dr Brian Davis, Texas, USA
Dr Susana Adriana Esquivel, Córdoba, Mexico
Professor Sheng Feng, Shanghai, China

Dr Juan Gomez Rivas, Madrid, Spain
Dr Satoshi Ieiri, Kagoshima City, Japan
Dr Haytham Kaafarani, Massachusetts, USA
Dr Yogeesh Kamat, Karnataka, India
Mr Omar Khan, London, UK
Prof. Tsuyoshi Konishi, Osaka, Japan
Dr Vito A Mannacio, Naples, Italy
Dr Todd Manning, Oxford, UK
Dr Zubing Mei, Shanghai, China
Dr Umesh Metkar, Beth, Israel

Dr Indraneil Mukherjee, Staten Island, USA
Dr Enyi Ofo, Adelaide, South Australia
Dr Lena Perger, Albuquerque, USA
Professor Prathamesh S Pai, Mumbai, India
Dr Alfredas Smailys, Kaunas, Lithuania
Prof. Peter Hyunsuk Suh, Seoul, South Korea
Dr Dieter Weber, Perth, Australia
Dr John Wee, Boston, USA
Dr Honggyi Zhu, Shanghai, China

Statistical Editors

Dr Derek Cooper, London, UK
Professor Nora Donaldson, London, UK
Professor Mary W Gray, Washington DC, USA

Society Representative

Deniz Balci, Representative of the International Society of Liver Surgeons
Rhiannon Harries, President, Association of Surgeons in Training
Gene F. Coppa, President of the New York Surgical Society
Xiao-ping Chen, President of the Chinese Chapter of International Hepato-Pancreato-Biliary Association

Social Media Editor

Dr Riaz Agha, London, UK

Assistant Commissioning Editors

Ahmed Al-Jabir, London, UK
Zaid Alsafi, London, UK
Thomas Franchi, Sheffield, UK
Christos Iosifides, London, UK

Ahmed Kerwan, London, UK
Mehdi Khan, London, UK
Ginimol Matthew, London, UK
Maria Nicola, London, UK

Niamh O'Neill, London, UK
Catrin Sohrabi, London, UK

Executive Committee

Professor David Albala, New York, USA
Sir Graeme Catto, London, UK
Professor David Cooper, Pittsburgh, USA
Lord Ara Darzi, London, UK
Professor Harold Ellis, London, UK
Ather Enam, Karachi, Pakistan

Sir Barry Jackson, London, UK
Professor Arthur Li Kwok-Cheung, Wanchai, Hong Kong
Professor C H Leong, Central, Hong Kong
Lord Ian McColl, London, UK

John Norcini, Philadelphia, USA
Professor Susan Standing, London, UK
Lord Robert Winston, London, UK
Sir Magdi Yacoub, London, UK

Editorial Board

Raj Badwe
Mumbai, India
Michael Boscoe
Middlesex, UK
Rapheal Bueno
Boston, USA
Kris Chatamra
Bangkok, Thailand
Paul Coulthard
Manchester, UK
Anil d'Cruz
Mumbai, India
Mahesh Desai
Mumbai, India
Juan Gomez Rivas
Spain, Madrid

David W. Green
London, UK
Iraj Harirchi
Tehran, Iran
Doris Henne-Bruns
Ulm, Germany
Delawir Kahn
Cape Town, South Africa
Xiaoxi Lin
Shanghai, China
Ashok Mahapatra
New Delhi, India
Todd Manning
Melbourne, Australia
Indraneel Mittra
Mumbai, India

Vijay Naraynsingh
West Indies
Fabio Nicoli
London, UK
Anibal R. Núñez De Pierro
Buenos Aires, Argentina
Reuben Orda
Tel Aviv, Israel
Vladimir Semiglazov
St. Petersburg, Russia
Tejinder Singh
Ludhiana, India
Barbara L. Smith
Boston, USA
James Tatum
California, USA

Thehnton Udwardia
Mumbai, India
Martin R. Weiser
New York, USA
Yixin Zhang
Shanghai, China
Jun Zhong
Shanghai, China
Zhao-Fan Xia
Shanghai, China

Elsevier

Executive Publisher

Ash Allan, Oxford, UK
Administrative Editor
Josie Hutchins, Oxford, UK
Marketing Manager
Jayne Dawkins, Philadelphia, USA

Journal Manager

Tamsyn Hopkins, Exeter, UK
Senior Business Development Executive (Reprints)
Emma Steel, London, UK
Advertising Sales Manager
Robert Bayliss, London, UK

Account Manager (Supplements)

Evelina Euren, Amsterdam, the Netherlands
Project Manager Supplements & E-business
Mónica Hernández-Sesma, Amsterdam, the Netherlands



Case report

Management of cerebrospinal fluid leak in the lateral recess of the sphenoid sinus with transpterygoid approach: A case report

Moudi Merlin Mona, Budi Sutikno*

Department of Otorhinolaryngology-Head and Neck Surgery, Faculty of Medicine, Universitas Airlangga – Dr. Soetomo General Academic Hospital, Surabaya, Indonesia



ARTICLE INFO

Keywords:

Cerebrospinal fluid leak
Lateral sinus sphenoid
Rhinology disease
Transethmoid-pterygoid endoscopy

ABSTRACT

Background: Cerebrospinal fluid (CSF) leak that occurred in the lateral sphenoid sinus is a rare and difficult case. This paper aims to report a case of defect closure in the lateral recess of the sphenoid sinus endoscopically with a transpterygoid approach.

Case presentation: A 38-year-old Indonesian woman reported a CSF leak, and identified a defect in the lateral recess of the left sphenoid sinus. CSF leak was repaired with endoscopic transtethmoid-pterygoid or transpterygoid endoscopic surgery and no CSF leak was found. The surgical procedure was successful even though it was only performed by an otorhinolaryngologist.

Discussion: Endoscopic transtethmoid-pterygoid or transpterygoid endoscopic surgery is effective in repairing defects in the lateral recess of the sphenoid sinus in which surgical procedure is performed by a single otorhinolaryngologist.

Conclusion: Endoscopic transpterygoid approach gained access to lateral site of sphenoid sinus was an effective approach in managing CSF leak of lateral sphenoid recess. Closure of the defect using a bone graft and mucosa of the middle turbinate was proven to be effective. It had been carried out successfully in Indonesia.

1. Introduction

Cerebrospinal fluid (CSF) leak is a rare condition, that can lead to meningitis if not diagnosed quickly and correctly [1,2]. A CSF leakage can be caused by 80%–90% trauma or 4%–10% non-trauma [2] in which there are 14–55% of idiopathic reported in non-traumatic cases [3]. A CSF leak in the lateral sphenoid sinus can be repaired with a transtethmoidal-pterygoid or endoscopic endonasal transpterygoid approach [4,5]. In Indonesia, cases of cerebrospinal fluid leakage are very rare, so we are interested in reporting them based on the 2020 surgical case report (SCARE) guidelines [6].

2. Case presentation

A 38-year-old Indonesian woman complained of clear discharge from her left nose for eight months every day in Dr. Soetomo General Academic Hospital, Surabaya, Indonesia. The watery discharge came out spontaneously, not continuously, increased when the patient is in a sitting position, head down, straining, and tasted salty. There were no

complaints of nasal obstruction, nasal pain, headache, olfactory disturbances, and eye disorders. No abnormality was found in the right nasal cavity. The patient had a history of meningioma nine months ago. Rhinorrhea was found in the left nasal cavity, no mucosal edema or hyperemia was found, the right nasal cavity was normal. The handkerchief test did not reveal any residual-colored liquid or changes in the stiffness of the fabric [7]. Nasoendoscopy revealed clear fluid came out from the left sphenoid ostium. CT scan of the paranasal sinuses showed an opacity of fluid density in the lateral recess of the left sphenoid sinus (Fig. 1).

The surgery was performed under general anesthesia by a single otorhinolaryngologist. The evaluation of the left nasal cavity showed clear watery fluid in the left sphenoid recess came out of the left sphenoid sinus ostium. The surgery began with partial resection of the left middle turbinate, uncinectomy, middle meatal antrostomy, widening to the posterior wall of the maxillary sinus, anterior ethmoidectomy, removing the basal lamella of middle and superior turbinates, and posterior ethmoidectomy. The process continued with partial resection of superior turbinate and sphenoidectomy, identification of

* Corresponding author: Budi Sutikno, Department of Otorhinolaryngology-Head and Neck Surgery, Faculty of Medicine, Universitas Airlangga – Dr. Soetomo General Academic Hospital, Jl. Mayjend Prof. Dr. Moestopo No. 6-8, Airlangga, Gubeng, Surabaya, East Java 60286, Indonesia.

E-mail addresses: budi-s@fk.unair.ac.id, budisutikno104@gmail.com (B. Sutikno).

<https://doi.org/10.1016/j.ijscr.2021.106594>

Received 21 September 2021; Received in revised form 7 November 2021; Accepted 9 November 2021

Available online 12 November 2021

2210-2612/© 2021 The Authors. Published by Elsevier Ltd on behalf of IJS Publishing Group Ltd. This is an open access article under the CC BY-NC-ND license

(<http://creativecommons.org/licenses/by-nc-nd/4.0/>).

the sphenopalatine foramen, ligation of the sphenopalatine artery and its branches. The medial aspect of the posterior wall of the maxillary sinus was partially removed. The upper portion of the medial pterygoid process of the sphenoid bone was also removed by Kerrison ronger. A sphenoidectomy was widened laterally, revealing a bony defect characterized by meningocele and CSF flow in the anterosuperolateral sphenoid recess (Fig. 2).

Meningocele was reduced by bipolar cauterization, the sphenoid sinus mucosa was removed, the defect was closed with an inlay insertion of a middle turbinate bone graft, a middle turbinate mucosal graft was evaluated, no more CSF flow was found, fibrin glue was applied, and absorbable hemostatic agent (Surgicel®) and gelfoam were placed (Fig. 3). Fifty milliliters of bleeding, no CSF flow was found on the final inspection intraoperatively. Postoperatively, the patient received 1 g of ceftriaxone twice daily intravenously, 15 mL of oral laxative three times daily. Bed rest with head elevation 15–30° for seven days postoperatively.

Seven days after surgery, the patient was discharged with the oral antibiotic ciprofloxacin 500 mg twice daily. Two weeks postoperatively, nasal washing with 0.9% NaCl was started twice daily. The patient was advised not to strain, lean forward, and weight lifting of more than seven kilograms for two weeks, and open mouth whilst sneezing or coughing. The postoperative visit on one, two, four, and six months showed no CSF leakage. The patient was followed up for up to two years and had serial visits every 6 months (Fig. 4).

3. Discussion

A CSF leak in the lateral recess of the sphenoid sinus is suspected to be due to a congenital abnormality of Sternberg's canal dehiscence, exacerbated by a history of meningiomas in which the tumor was increasing intracranial pressure resulting in CSF leakage [8]. The etiology of CSF leak is congenital, tumor-related, traumatic, and idiopathic [9]. Non-traumatic CSF rhinorrhea is more common in adult women >30 years old, with a ratio of 1:2 for men and women [9]. A CSF leak can occur at any location, including defects in the lamina cribrosa 35%, sphenoid sinus 26%, anterior ethmoid 18%, frontal sinus 10%, posterior ethmoid 9%, and inferior clivus 2% [8,9]. Symptoms of rhinorrhea due to CSF leak are clear watery discharge [10]. Rhinorrhea can be persistent or intermittent, usually unilateral and associated with changes in position or certain activities [10].

The teapot sign test was carried out on patients with positive results [11], followed by a handkerchief test that did not leave a mark and did not change the stiffness of the handkerchief so that a CSF leak was

suspected [7]. Identification of suspicious CSF leak includes the teapot sign test, handkerchief test, and β 2-transferrin [12]. The nasoendoscopy finding with clear watery discharge in the sphenoid recess is suspected a CSF [3]. Nasoendoscopy is performed to identify the site of the CSF leak but can be negative in some cases [13]. CT scan is the best diagnostic option for identifying skull base defects [3,13]. Skull base defects can be identified by CT scan in 80% of cases [3,13].

Factors contributing to CSF leak in the sphenoid sinus are congenital skull base defects, tumors, trauma, and increased intracranial pressure [14]. Lateral wall defects of the sphenoid sinus accounted for 9.8% of the normal population at autopsy [14,15]. Most CSF leaks close spontaneously within 7–10 days; non-closing CSF leaks increase the risk of meningitis [16]. The treatment of choice for CSF leak in the lateral sphenoid sinus recess defect is transnasal endoscopic surgery that has become the standard for repairing CSF leaks with low morbidity and a highly successful rate of 90% [15,16].

A transpterygoid approach is an option for defects closure in the lateral sphenoid recess due to its ability to expose the lateral sphenoid recess [17]. This approach involves performing a partial or total middle turbinate resection [17]. Maxillary sinuses are opened widely, anterior and posterior ethmoidectomy, and sphenoidectomy [18]. The optic nerve and internal carotid artery are identified. The sphenopalatine artery is identified and cauterized [18]. The medial pterygoid process is removed so that the lateral extension of the sphenoid sinus can be seen [17,18]. Bone and mucosal grafts of the middle turbinate are used to close the defect, in combination with fibrin glue and gelfoam [17]. The sphenoid sinus mucosa around the defect is removed as cleanly as possible with a curette so that the graft adheres to the surface of the defect well [18]. There is no CSF flow during the evaluation of surgical duration after insertion of bone grafts and mucosa of the middle turbinate [19]. The graft to cover the defect can be fat, fascia, mucosa, bone, cartilage, synthetic material, or a combination of these materials [17–19].

Antibiotics are given to prevent meningitis, although this is still a matter of debate [17]. Antibiotics can significantly reduce the incidence of meningitis [17]. Restrictions on patient activity are advised postoperatively [18]. Bed rest with head elevation 15–30° for seven days to prevent an increase in intracranial pressure which can lead to the release of the graft [17,18]. Bed rest with the head elevated or reverse Trendelenburg is to prevent increased intracranial pressure [17–20].

4. Conclusion

A case report of a 38-year-old Indonesian woman with CSF leak in

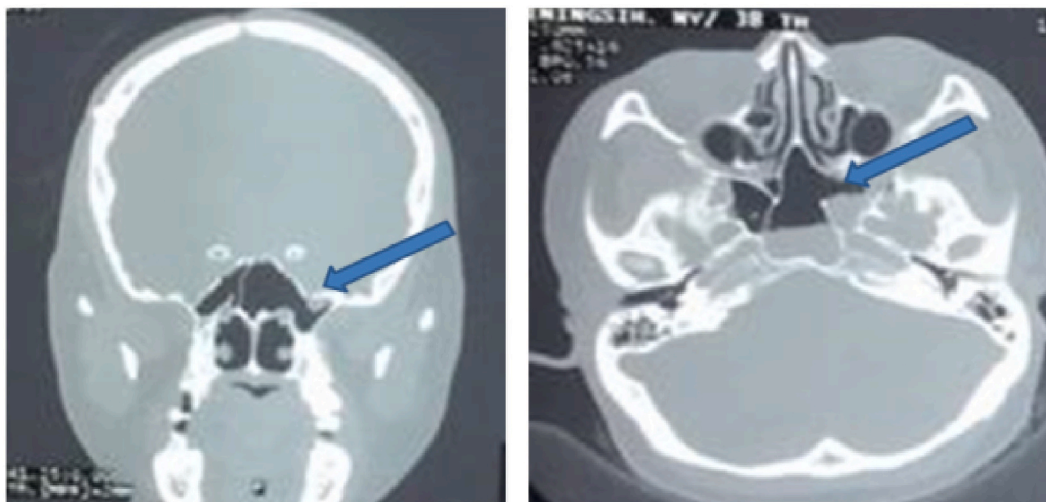


Fig. 1. Axial and coronal CT scan of the paranasal sinuses shows an opacity of fluid density in the lateral recess of the left sphenoid sinus (arrow).

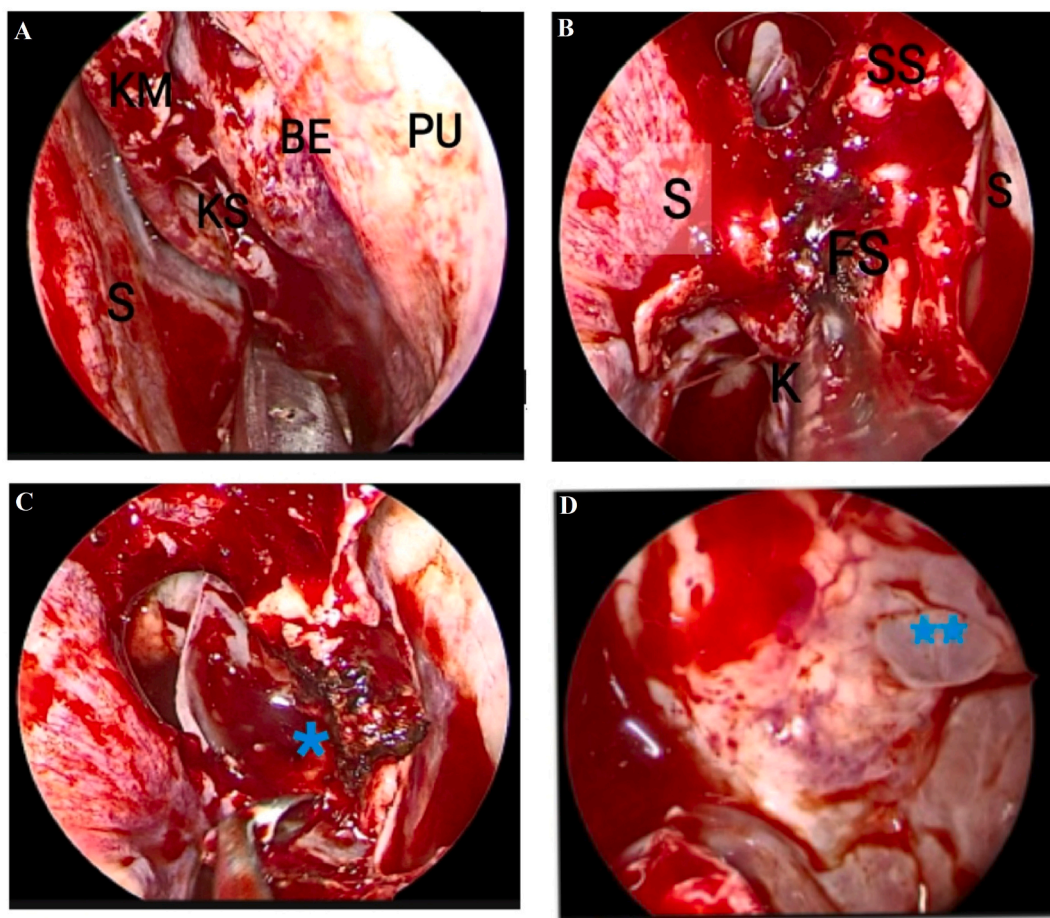


Fig. 2. Left nasal cavity. A. Resection of the middle turbinate, B. sphenoidectomy, C. lateral recess of the sphenoid sinus (*), D. bone defect is seen marked by anterosuperolateral meningocele (**). Seen on the image (S) of the septum, (KM) of the remnant of the middle turbinate, (BE) ethmoid bulla, (KS) superior turbinate, (PU) unciniate process, (FS) sphenopalatine foramen, (SM) maxillary sinus, (SS) sphenoid sinus, (K) choana.

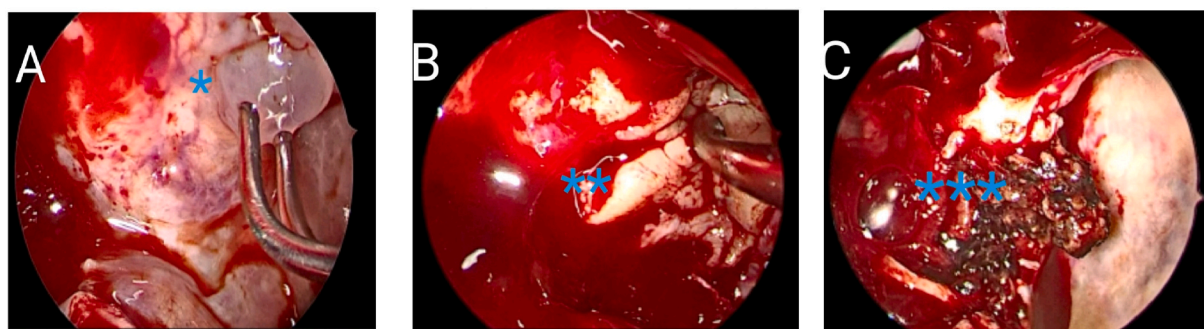


Fig. 3. Left nasal cavity. A. Meningocele bipolar cauterization (*), B. bone and mucosal graft of middle turbinate (**), C. fibrin glue and gelfoam layer (***)

the lateral recess of the sphenoid sinus who underwent endoscopic sinus surgery with transpterygoid approach by a single otorhinolaryngologist. Defect closure was successfully performed using bone and mucosal graft of the middle turbinate. Postoperative nasoendoscopy evaluation on one, two, four, and six months showed no leakage, the graft was viable and attached to its position.

Consent

Written informed consent was obtained from the patient for publication of this case report and accompanying images. A copy of the written consent is available for review by the editor-in-chief of this

journal on request.

Provenance and peer review

Not commissioned, externally peer-reviewed.

Ethical approval

We have conducted an ethical approval based on the Declaration of Helsinki at the Ethical Committee in Dr. Soetomo General Academic Hospital, Surabaya, Indonesia.

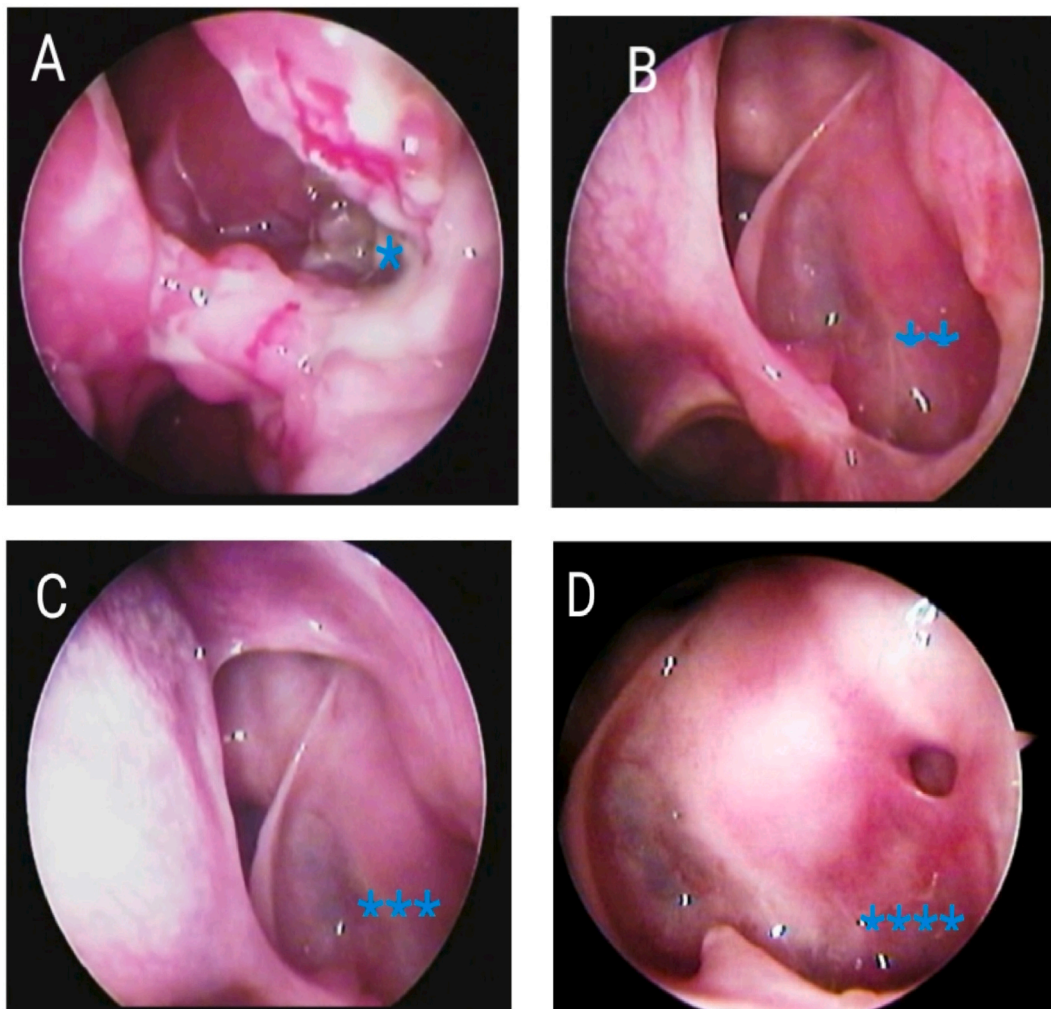


Fig. 4. Nasoendoscopy of the left nasal cavity showed no CSF leak, the mucosal graft was attached to its position. A. One month (*), B. two months (**), C. four months (***), D. six months postoperatively (****).

Funding

None.

Guarantor

Budi Sutikno.

Research registration number

Not applicable.

Credit authorship contribution statement

All authors contributed toward data analysis, drafting and revising the paper, gave final approval of the version to be published and agree to be accountable for all aspects of the work.

Declaration of competing interest

The authors declare that they have no conflict of interest.

Acknowledgment

The authors would like to thank Fis Citra Ariyanto for editing and

proofing assistance.

References

- [1] J.S. Virk, B. Elmiyeh, H.A. Saleh, Endoscopic management of cerebrospinal fluid rhinorrhea: the charing cross experience, *J.Neurol.Surg.B Skull Base* 74 (2) (2013) 61–67, <https://doi.org/10.1055/s-0033-1333620>.
- [2] A. Keshri, R. Jain, R.S. Manogaran, S. Behari, D. Khatri, A. Mathialagan, Management of spontaneous CSF rhinorrhea: an institutional experience, *J.Neurol. Surg.B Skull Base* 80 (5) (2019) 493–499, <https://doi.org/10.1055/s-0038-1676334>.
- [3] A.S. Enghard, V. Volgger, A. Leunig, C.S. Meßmer, G.J. Ledderose, Spontaneous nasal cerebrospinal fluid leaks: management of 24 patients over 11 years, *Eur. Arch. Oto-rhino-laryngol.* 275 (10) (2018) 2487–2494, <https://doi.org/10.1007/s00405-018-5089-y>.
- [4] N.S. Alexander, M.R. Chaaban, K.O. Riley, B.A. Woodworth, Treatment strategies for lateral sphenoid sinus recess cerebrospinal fluid leaks, *Arch.Otolaryngol.Head Neck Surg.* 138 (5) (2012) 471–478, <https://doi.org/10.1001/archoto.2012.614>.
- [5] A.Z. Maxfield, S.K. Mueller, A.R. Raquib, A.R. Sedaghat, R.W. Bergmark, R. B. Metson, et al. 5(3) (2020) 375–380, <https://doi.org/10.1002/lio2.412>.
- [6] R.A. Agha, T. Franchi, C. Sohrabi, G. Mathew, A. Kerwan, The SCARE 2020 guideline: updating consensus Surgical CAse REport (SCARE) guidelines, *Int.J. Surg.(Lond.Engl.)* 84 (2020) 226–230, <https://doi.org/10.1016/j.ijsu.2020.10.034>.
- [7] J.W. Oh, S.H. Kim, K. Whang, Traumatic cerebrospinal fluid leak: diagnosis and management, *Korean J. Neurotrauma* 13 (2) (2017) 63–67, <https://doi.org/10.13004/kjnt.2017.13.2.63>.
- [8] B.C. Lobo, M.M. Baumanis, R.F. Nelson, Surgical repair of spontaneous cerebrospinal fluid (CSF) leaks: a systematic review, *Laryngoscope Investig. Otolaryngol.* 2 (5) (2017) 215–224, <https://doi.org/10.1002/lio2.75>.
- [9] N. Kim-Orden, J. Shen, M. Or, K. Hur, G. Zada, B. Wrobel, Endoscopic endonasal repair of spontaneous cerebrospinal fluid leaks using multilayer composite graft

- and vascularized pedicled nasoseptal flap technique, *Allergy Rhinol.* 10 (2019), 2152656719888622, <https://doi.org/10.1177/2152656719888622>.
- [10] C. Martín-Martín, G. Martínez-Capoccioni, R. Serramito-García, F. Espinosa-Restrepo, Surgical challenge: endoscopic repair of cerebrospinal fluid leak, *BMC Res. Notes* 5 (2012) 459, <https://doi.org/10.1186/1756-0500-5-459>.
- [11] T.N. Janakiram, V. Subramaniam, P. Parekh, Endoscopic endonasal repair of sphenoid sinus cerebrospinal fluid leaks: our experience, *Indian J. Otolaryngol. Head Neck Surg.* 67 (4) (2015) 412–416, <https://doi.org/10.1007/s12070-015-0924-6>.
- [12] A.E. Kita, D.W. Bradbury, Z.D. Taylor, D.T. Kamei, M.A. St John, Point-of-care cerebrospinal fluid detection, *Otolaryngology–head and neck surgery : official journal of American Academy of otolaryngology-head and neckSurgery* 159 (5) (2018) 824–829, <https://doi.org/10.1177/0194599818789075>.
- [13] M.A. Eryilmaz, M. Arıçgil, M.A. Alan, Multilayered closure of cerebrospinal fluid rhinorrhea with inlay fascia lata, autologous fat, and outlay fascia lata: our experience, *ORL J. Otorhinolaryngol. Relat. Spec.* 78 (5) (2016) 289–295, <https://doi.org/10.1159/000451002>.
- [14] M. Tomaszewska, E. Brożek-Mądry, A. Krzeski, Spontaneous sphenoid sinus cerebrospinal fluid leak and meningoencephalocele - are they due to patent Sternberg's canal? *Wideochirurgia i inne techniki maloinwazyjne = Videosurgery and other miniinvasive techniques.* 10 (2) (2015) 347–358, <https://doi.org/10.5114/wiitm.2014.47097>.
- [15] G. Bozkurt, M. Turri-Zanoni, E. Coden, F. Russo, H.A. Elhassan, S. Gallo, et al., Endoscopic endonasal transpterygoid approach to sphenoid sinus lateral recess defects, *J. NeuroI.Surg.B Skull Base* 81 (5) (2020) 553–561, <https://doi.org/10.1055/s-0039-1692639>.
- [16] M.N. El-Tarabishi, S.A. Fawaz, S.M. Sabri, M.M. El-Sharnobi, A. Sweed, A modification of endoscopic endonasal approach for management of encephaloceles in sphenoid sinus lateral recess, *European archives of Oto-rhinolaryngology : official journal of the european Federation of Oto-Rhino-Laryngological Societies (EUFOS): affiliated with the german Society for Oto-Rhino-Laryngology - Head and Neck Surgery.* 273 (12) (2016) 4305–4314, <https://doi.org/10.1007/s00405-016-4125-z>.
- [17] R.F. Schmidt, O.J. Choudhry, J. Raviv, S. Baredes, R.R. Casiano, J.A. Eloy, et al., Surgical nuances for the endoscopic endonasal transpterygoid approach to lateral sphenoid sinus encephaloceles, *Neurosurg. Focus* 32 (6) (2012) E5, <https://doi.org/10.3171/2012.3.Focus1267>.
- [18] A. Spina, N. Boari, F. Calvanese, P. De Domenico, M. Cannizzaro, M. Trimarchi, et al., Transcranial extradural subtemporal repair for sphenoid sinus lateral recess meningoencephalocele: technical note, *Neurosurg. Rev.* (2021), <https://doi.org/10.1007/s10143-021-01581-7>.
- [19] G.M. Oakley, R.R. Orlandi, B.A. Woodworth, P.S. Batra, J.A. Alt, Management of cerebrospinal fluid rhinorrhea: an evidence-based review with recommendations, *Int. Forum Allergy Rhinol.* 6 (1) (2016) 17–24, <https://doi.org/10.1002/alr.21627>.
- [20] G. Fyrmpas, I. Konstantinidis, P. Selviaridis, J. Constantinidis, Management of spontaneous cerebrospinal fluid leaks of the sphenoid sinus: our experience, *J. Laryngol. Otol.* 128 (9) (2014) 797–802, <https://doi.org/10.1017/s0022215114001698>.