

EXPRESSION OF CYTOKERATIN – 7 AND CYTOKERATIN – 19 ON NEWBORN MICE AS BILIARY ATRESIA MODEL

Corresponding author submit naskah lewat web PAMJ Manuscript Hut:

Tanggal 26 Juli 2022 *corresponding author* mendapat email dari editor bahwa naskah diterima:

PAMJ - Manuscript acceptance notice [Manuscript ID 28408]

Eksternal
Kotak Masuk



Editor - Manuscript Hut Pan African Medical Journal
<editor@panafrican-med-journal.com>

Sel, 26 Jul 2022,
10.57

kepada saya, Delsa, Jaja, Grace, editor

Dear Bagus Setyoboedi,

Manuscript: EXPRESSION OF CYTOKERATIN – 7 AND CYTOKERATIN – 19 ON NEWBORN MICE AS BILIARY ATRESIA MODEL

We are pleased to inform you that your manuscript is now formally accepted for publication in Pan African Medical Journal and will soon be published, pending payment the of Manuscript Processing Charges (if applicable; see the Manuscript Processing Charges Summary below).

Article Processing Charges (APC): If article processing charges apply to this journal and you opted to pay, APC should be paid in full within 10 days of acceptance of the manuscript. Failure to pay the Article Processing Charges within 10 days of acceptance may result in the automatic rejection of your submission.

BEWARE OF SCAMMERS: The Pan African Medical Journal only accepts payments through PayPal (to the address sales-service@panafrican-med-journal.com) and Bank transfert (to our Standard Chartered Bank Account in Kenya). Before making any payment, contact sales-service@panafrican-med-journal.com or the editor in charge of your submission.

Your manuscript is currently undergoing a quality control audit and the editorial team will eventually get back to you if need be.

Thank you for trusting the Pan African Medical Journal with your submission.

Manuscript Processing Charges Summary

- **Your decision on Article Processing Charges:** *Will pay full*
- **Your comments on Article Processing Charges:** *Non applicable*
- **Journal decision on your waiver request:** Non applicable
- **Amount to be paid by the authors:** 180 USD

Thank you for accepting to pay the Article Processing Charges (APC) of **180 USD**. You are contributing to the development of medical publishing and Open Access in Africa.

We expect authors to complete payment of APC within 10 days of acceptance of the manuscript to avoid delays in its publication. Failure to pay Article Processing Charges within 10 dys will result in the rejection of the manuscript.

The journal currently accepts 3 forms of payment; please chose below which one is suitable for you. Transfer fees must be covered by the person making the payment:

BEWARE OF SCAMMERS..! The PAMJ will never ask you to send payment by means other than bank transfer, PayPal (to the email address sales-service@panafrican-med-journal.com, or Mobile Money (for Cameroon only). We do not request payments by bitcoins or other crypto currencies/wallets. Contact the PAMJ if you have questions.

PAYMENT THROUGH BANK TRANSFER

Make a payment of **180 USD** to:

Name of account: PAN AFRICAN MEDICAL CTR

USD Account number: 87028-173160-00

Account address: P.O Box: 63565-00619, Gigiri, Nairobi, Kenya.

Standard Chartered Bank

Priority Banking, Muthaiga

P.O Box 64355 - 00620

Nairobi, Kenya

Swift Address: SCBLKENXXXX

Branch Code: 02 07600

To avoid any delays in the processing of your manuscript, send an email to sales-service@panafrican-med-journal.com to confirm the completion of the transfer. Attached the proof of payment to the email.

SECURED PAYMENT BY CREDIT CARD THROUGH PAYPAL:

If you wish to pay by PayPal using your credit card, send an email to sales-service@panafrican-med-journal.com and we will send you a PayPal email payment request. Add the title and the manuscript number for which the payment will be made.

IF YOU RESIDE IN KENYA You can pay directly to PAMJ Bank account at any Standard Chartered Bank.

Name of account: PAN AFRICAN MEDICAL CTR

USD Account number: 87028-173160-00

Kenyan shillings Account number: 01028-173160-00

Standard Chartered Bank
Priority Banking, Muthaiga
P.O Box 64355 - 00620
Nairobi, Kenya

Send payment confirmation by email to sales-service@panafrican-med-journal.com

IF YOU RESIDE IN CAMEROON You can pay directly to PAMJ Bank account at any Afriland First Bank.

Name of account: PANAFRICAN CENTER FOR PUBLIC HEALTH AND INFORMATION

Accountnumber Franc CFA (XAF) US: 05490881001

Afriland First Bank

Account address: Yaounde - Cameroon

Bank code: 10005

RIB: 10005 00001 05490881001 11

IBAN: CM21 10005 00001 05490881001 11

Code SWIFT: CCEICMCX

To avoid any delays in the processing of your manuscript, send an email to sales-service@panafrican-med-journal.com to confirm the completion of the payment.

Pan African Medical Journal Editorial Office

editor@panafrican-med-journal.com

<https://www.panafrican-med-journal.com/>

Check our special issues on COVID-19 in Africa in the PAMJ | [Volume 1](#) | [Volume 2](#)

Check our [PAMJ 2021 in review dashboard](#)

The PAMJ is also [PAMJ Conference Management System](#) | [The PAMJ Conference Proceedings](#) | [The PAMJ Blog](#)

Tanggal 26 Juli 2022 *corresponding author* membalas email dari editor bahwa nakah diterima:

BAGUS SETYOBOEDI <bagus.setyoboedi@fk.unair.ac.id> Sel, 26 Jul 2022, 11.20

kepada Editor

Oke, thank you for accepting my manuscript and I will fulfill the charge payment

Tanggal 27 Juli 2022 *corresponding author* mendapat email perihal cara pembayaran:

PAMJ - Article Processing Charges payment instructions (Manuscript id:28408)

Eksternal

Kotak Masuk



Admin - Manuscript Hut Pan African Medical Journal
<admin@panafrican-med-journal.com>

Rab, 27 Jul
2022, 18.01

kepada saya, Mariette, editor

Dear Setyoboedi

The instructions for payment of article processing charges are appended below.

Manuscript: [EXPRESSION OF CYTOKERATIN – 7 AND CYTOKERATIN – 19 ON NEWBORN MICE AS BILIARY ATRESIA MODEL \(28408\)](#)

Journal: PAMJ. Submitted 16 Feb 2021

The Pan African Medical Journal currently accepts various forms of payment; please chose below which one is suitable for you. Transfer fees must be covered by the person making the payment:

BEWARE OF SCAMMERS..! The PAMJ will never ask you to send payment by means other than bank transfer, PayPal (to the email address sales-service@panafrican-med-journal.com, or Mobile Money (for Cameroon only). We do not request payments by bitcoins or other crypto currencies/wallets. Contact the PAMJ if you have questions.

Payment through bank transfer: Make a payment of **180 USD** to:

Name of account: PAN AFRICAN CTR

US Account number:87028-173160-00

Standard Chartered Bank

Priority Banking, Muthaiga

P.O Box 64355 - 00620

Nairobi, Kenya

Swift Address: SCBLKENXXXX

Branch Code: 02 07600

IF YOU RESIDE IN KENYA You can pay directly to PAMJ Bank account at any Standard Chartered Bank.

Name of account: PAN AFRICAN CTR

US Account number: 87028-173160-00

Kenyan shillings Account number: 01028-173160-00

Standard Chartered Bank
Priority Banking, Muthaiga
P.O Box 64355 - 00620
Nairobi, Kenya

To avoid any delays in the processing of your manuscript, send an email to sales-service@panafrican-med-journal.com to confirm the completion of the transfer.

IF YOU RESIDE IN CAMEROON You can pay directly to PAMJ Bank account at any Afriland First Bank.

Name of account: PANAFRICAN CENTER FOR PUBLIC HEALTH AND INFORMATION

Accountnumber Franc CFA (XAF) US: 05490881001

Afriland First Bank

Account address: Yaounde - Cameroon

Bank code: 10005

RIB: 10005 00001 05490881001 11

IBAN: CM21 10005 00001 05490881001 11

Code SWIFT: CCEICMCX

To avoid any delays in the processing of your manuscript, send an email to sales-service@panafrican-med-journal.com to confirm the completion of the payment.

Mariette Gaelle Manifo, Admin and finance

sales-service@panafrican-med-journal.com

[Pan African Medical Journal \(PAMJ\)](#)

Kenya: 3rd Floor, Park Suite Building, Parkland Road, Nairobi. PoBox 38583-00100, tel: +254 (0)20-520-4356 | Cameroon: Immeuble TechnoPark Essos, Yaounde, PoBox: 10020 Yaounde, tel: +237 (0)24-309-5880

Check our special issues on COVID-19 in Africa in the PAMJ | [Volume 1](#) | [Volume 2](#)

Check our [PAMJ 2021 in review dashboard](#)

The PAMJ is also [PAMJ Conference Management System](#) | [The PAMJ Conference Proceedings](#) | [The PAMJ Blog](#)

Tanggal 29 Juli 2022 *corresponding author* membalas email editor tentang pembayaran naskah:

Publication payment

Eksternal
Kotak Masuk

BAGUS SETYOBOEDI <bagus.setyoboedi@fk.unair.ac.id> Jum, 29 Jul 2022, 12.34

kepada sales-service, Editor, Admin

I have already paid my publication charge payment.
Manuscript: EXPRESSION OF CYTOKERATIN – 7 AND CYTOKERATIN – 19 ON
NEWBORN MICE AS BILIARY ATRESIA MODEL (28408)
Journal: PAMJ. Submitted 16 Feb 2021

Best regards
Bagus Setyoboedi

Tanggal 29 Juli 2022 *corresponding author* mendapat balasan email editor tentang pembayaran naskah:

Mariette Gaelle Manifo <sales-service@panafrican-med-journal.com>

Jum, 29 Jul 2022,
22.33

kepada saya

Thank you,

I will send you an email to confirm your payment.

Regards

--

Mariette Gaelle Manifo
Sales and finance representative
Pan African Medical Journal
sales-service@panafrican-med-journal.com
Yaounde - Cameroon
www.panafrican-med-journal.com

Tanggal 1 Agustus 2022 *corresponding author* membalas email editor tentang pembayaran naskah:

BAGUS SETYOBOEDI <bagus.setyoboedi@fk.unair.ac.id> Sen, 1 Agu 2022, 16.02

kepada Mariette

Here is my payment bill

Satu lampiran • Dipindai dengan Gmail

Mariette Gaelle Manifo <sales-service@panafrican-med-journal.com>

Sel, 2 Agu 2022,
16.43

kepada saya

Received, thank you.

Tanggal 2 Agustus 2022 *corresponding author* mendapat email editor tentang revisi naskah:

Pan African Medical Journal - Manuscript in quality control [Manuscript ID 28408]

Eksternal
Kotak Masuk



Editor - Manuscript Hut Pan African Medical Journal
<editor@panafrican-med-journal.com>

Sel, 2 Agu 2022,
18.47

kepada saya, Delsa, Jaja, Winnie, Grace, editor

EXPRESSION OF CYTOKERATIN – 7 AND CYTOKERATIN – 19 ON NEWBORN MICE AS BILIARY ATRESIA MODEL (28408)

Dear Bagus

Your manuscript is in quality control. We have identified few issues that should be corrected before we proceed with the processing of your manuscript:

1. All PAMJ Journals adopted the [STROBE guidance](https://www.equator-network.org/reporting-guidelines/strobe/) (<https://www.equator-network.org/reporting-guidelines/strobe/>) to help improve the structure and presentation of your paper. We suggest you use the relevant [STROBE Checklist](https://www.equator-network.org/reporting-guidelines/strobe/) (<https://www.equator-network.org/reporting-guidelines/strobe/>) to help format your manuscript.

Here is an example of a publication adhering to the STROBE checklist:
<https://www.panafrican-med-journal.com/content/article/41/3/full/>

2. Kindly add all the necessary subsections under the method sections as per the strobe guidelines.
3. Your revised manuscript should include, as an annex, the completed relevant STROBE checklist, indicating the pages in which the checklist items are included.

Submit the revised version of your manuscript through the online system. Do not submit the revised version of your manuscript as a new manuscript, it will delay the processing. To submit the revised version of your manuscript, follow the steps below:

- Log into the Manuscript Hut using the email and password you used to submit this manuscript
- Locate the manuscript tagged for resubmission and follow the link to upload the revised version

Thank you for trusting us with your submission

Winnie Mwema, Assistant editor

winnie.mwema@panafrican-med-journal.com

[Pan African Medical Journal \(PAMJ\)](#)

Kenya: 3rd Floor, Park Suite Building, Parkland Road, Nairobi. PoBox 38583-00100, tel: +254 (0)20-520-4356 | Cameroon: Immeuble TechnoPark Essos, Yaounde, PoBox: 10020 Yaounde, tel: +237 (0)24-309-5880

Check our special issues on COVID-19 in Africa in the PAMJ | [Volume 1](#) | [Volume 2](#)

Check our [PAMJ 2021 in review dashboard](#)

The PAMJ is also [PAMJ Conference Management System](#) | [The PAMJ Conference Proceedings](#) | [The PAMJ Blog](#)

Tanggal 2 Agustus 2022 corresponding author mendapat email editor tentang bukti payment:

Admin - Manuscript Hut Pan African Medical Journal
<admin@panafrican-med-journal.com>

Sel, 2 Agu 2022,
16.43

kepada saya, Mariette, editor

Dear Setyoboedi

The Pan African Medical Journal confirms that your payment of the Manuscript Processing Charges for the article below was received. Included in the email is a receipt of payment.

MANUSCRIPT PROCESSING CHARGES PAYMENT RECEIPT

Receipt for: Manuscript processing charges

Paid to: Pan African Medical Journal

Payment received from: Setyoboedi Setyoboedi

For manuscript title: EXPRESSION OF CYTOKERATIN – 7 AND CYTOKERATIN – 19 ON NEWBORN MICE AS BILIARY ATRESIA MODEL (28408)

Amount paid: 180 USD

Mode of payment: Bank transfer

Date payment received: 2022-07-30

Date of receipt: 02 Aug 2022

We would like to take this opportunity to once again thank you for supporting the development of Open access publishing in Africa.

Submit all inquiries regarding manuscript processing charges to: sales-services@panafrican-med-journal.com

Tanggal 3 Agustus 2022 *corresponding author* mendapat email editor tentang revisi naskah:

Pan African Medical Journal - Correction of manuscript [Manuscript ID 28408]

Eksternal
Kotak Masuk



Editor - Manuscript Hut Pan African Medical Journal
<editor@panafrican-med-journal.com>

Rab, 3 Agu 2022,
17.26

kepada saya, Delsa, Jaja, Ornella, Grace, editor

EXPRESSION OF CYTOKERATIN – 7 AND CYTOKERATIN – 19 ON NEWBORN MICE AS BILIARY ATRESIA MODEL (28408)

Dear BAGUS SETYOBOEDI ,

For a better visibility of your manuscript, we decided to improve the language.

In attachment the document read and improved. The changes are in red.

If you agreed with the changes, please submit the document through the system.

Submit the revised version of your manuscript through the online system. Do not submit the revised version of your manuscript as a new manuscript, it will delay the processing. To submit the revised version of your manuscript, follow the steps below:

- Log into the Manuscript Hut using the email and password you used to submit this manuscript
- Locate the manuscript tagged for resubmission, locate your manuscript and follow the link to upload the revised version

Please we wish you to submit your manuscript within five days.

Thank you for trusting us with your submission

Ornella Ngankong, Language editor

ornella.ngankong@panafrican-med-journal.com

[Pan African Medical Journal \(PAMJ\)](#)

Kenya: 3rd Floor, Park Suite Building, Parkland Road, Nairobi. PoBox 38583-00100, tel:

+254 (0)20-520-4356 | Cameroon: Immeuble TechnoPark Essos, Yaounde, PoBox: 10020

Yaounde, tel: +237 (0)24-309-5880

Check our special issues on COVID-19 in Africa in the PAMJ | [Volume 1](#) | [Volume 2](#)

Check our [PAMJ 2021 in review dashboard](#)

The PAMJ is also [PAMJ Conference Management System](#) | [The PAMJ Conference](#)

[Proceedings](#) | [The PAMJ Blog](#)

Satu lampiran • Dipindai dengan Gmail

Tanggal 4 Agustus 2022 *corresponding author* menjawab email editor tentang revisi naskah:

BAGUS SETYOBOEDI <bagus.setyoboedi@fk.unair.ac.id> Kam, 4 Agu 2022, 12.19

kepada **Editor**

Dear

Editor of PAMJ

Here i attached the revision of manuscript and table with the title " expression of cytokeratin-7 and cytokeratin-19 on newborn mice induced rhesus rotavirus as biliary model atresia

Thank you

Best regards

Bagus Setyoboedi

Satu lampiran • Dipindai dengan Gmail

Tanggal 4 Agustus 2022 *corresponding author* mendapat email editor tentang revisi naskah:



Managing Editor <editor@panafrican-med-journal.com> Kam, 4 Agu 2022, 18.56

kepada saya

Good afternoon Dear Bagus,

Please send your revisions online through the system.

Regards

--

Raoul Kamadjeu, MD, MPH

Managing Editor

Pan African Medical Journal

editor@panafrican-med-journal.com

www.panafrican-med-journal.com

Nairobi, Kenya

Tel: +254 714 606 223

Follow us on Facebook: <http://www.facebook.com/pages/Panafrican-Medical-Journal/189123838167>

Tanggal 4 Agustus 2022 *corresponding author* menjawab email editor tentang revisi naskah:

BAGUS SETYOBOEDI <bagus.setyoboedi@fk.unair.ac.id> Kam, 4 Agu 2022, 19.46

kepada **Managing**

Dear Editor

I also have already sent it by system.

Regard

Bagus Setyoboedi

Tanggal 15 Agustus 2022 *corresponding author* mendapat email editor tentang revisi naskah:

Manuscript 28408

Eksternal
Kotak Masuk



Kelvin Nderitu <kelvin.nderitu@panafrican-med-journal.com>

Sen, 15 Agu 2022,
13.33

kepada saya, rofibudiyanto, aendaryanto.ae

Dear Dr. Bagus,

I hope this email finds you well. We requested revision on your manuscript "**EXPRESSION OF CYTOKERATIN - 7 AND CYTOKERATIN - 19 ON NEWBORN MICE AS BILIARY ATRESIA MODEL (28408)**" which we have not yet received. Please work on the requested revision so we can finish the publication of your article by the end of the day.

Kind regards.

Kelvin Nderitu
Pan African Medical Journal
kelvin.Nderitu@panafrican-med-journal.com
www.panafrican-med-journal.com

Tanggal 15 Agustus 2022 corresponding author menjawab email editor tentang revisi naskah:

BAGUS SETYOBOEDI <bagus.setyoboedi@fk.unair.ac.id> Sen, 15 Agu 2022, 13.55

kepada Kelvin, rofibudiyanto, aendaryanto.ae

Dear Kelvin,

Thank you, I will do that. Soon I will send it.

Regard
Bagus S

Tanggal 31 Agustus 2022 corresponding author mendapat email editor tentang revisi naskah:

Minor revision

Eksternal
Kotak Masuk



Kelvin Nderitu <kelvin.nderitu@panafrican-med-journal.com>

Rab, 31 Agu 2022,
12.12

kepada saya, rofibudiyanto

Dear Bagus,

I hope this email finds you well. Your manuscript "**EXPRESSION OF CYTOKERATIN - 7 AND CYTOKERATIN - 19 ON NEWBORN MICE AS BILIARY ATRESIA MODEL (28408)**" is in the final stages of publication and we request revision on one of your references.

We could not locate reference 6 anywhere on the internet. Please provide the exact link for the reference. Use this format: Author(s), title of the reference, internet link of the reference, date of publication of the reference and the date of access of the reference. Work on this so we can finish the publication of your manuscript by the end of the day. Do not change anything inside the main text as the manuscript has already undergone peer-review.

Kind regards.

Kelvin Nderitu
Pan African Medical Journal
kelvin.Nderitu@panafrican-med-journal.com
www.panafrican-med-journal.com

Tanggal 31 Agustus 2022 *corresponding author* mendapat email editor tentang naskah yang dipublikasikan dan menanyakan apakah ada revisi kembali:

Pan African Medical Journal - Article Publication Notice [Manuscript 28408]

Eksternal
Kotak Masuk



Production - Manuscript Hut Pan African Medical Journal
<production@panafrican-med-journal.com>

Rab, 31 Agu
2022, 17.29

kepada saya, rofibudiyanto, aendaryanto.ae, sjamsularief, kelvin.Nderitu, editor

Dear authors,

We are glad to inform you that your manuscript is now published in its final version in the Pan African Medical Journal; note however that it may take few days for the manuscript to appear on the journal main page. Your article is accessible online at:

Research

[Expression of cytokeratin-7 and cytokeratin-19 on newborn mice induced rhesus rotavirus as biliary atresia model](#)

Bagus Setyoboedi, Ahmad Rofii, Anang Endaryanto, Sjamsul Arief

Pan African Medical Journal. 2022;42:322. Published on 31 Aug 2022

[PDF in process]

Correction of errors

Take time to carefully review your article. If you notice errors (typographical, grammatical, omissions, wrong character, author names etc..) in your publication, ensure that they are corrected within the next 5 days, before your manuscript is sent for long term preservation to several long term preservation bodies.

It is very important that errors identified be corrected promptly. Share this message with your co-authors to ensure that author names are free of errors and written in the order First Name - Middle Names(if any) - Last Name.

All corrections should be made before the final PDF is formatted. Some changes are not possible at this stage including changes in authors order, addition or subtraction of authors. Use the attached Correction Request Sheet to compile, organize and submit your request for corrections to the production team. The sheet is also available online at

https://www.panafrican-med-journal.com/resources/Proof_Correction_Template_English.docx

If there are errors to correct, submit your completed **Corrections Request Sheet** through the online Proof Checking System by clicking on the link below.

If your manuscript does not require corrections, you still need to access the link below to approve this online version of your manuscript.

<https://www.manuscript-hut.panafrican-med-journal.com/proofcheck/ManageProof.php?GetId=28408&PubType=Art&Src=pr&Proof=htm&JournalAbr=PAMJ&ConfirmKey=1662805767>.

If the link does not show in your email, simply copy the text and paste it in the address bar of your browser and click Enter

In case we do not hear from you within the next 10 (ten) working days, we will assume that your article does not need corrections and can be finalized and archived as such.

Once again, thank you for considering the Pan African Medical Journal with your submission.

Sincerely

Pan African Medical Journal Production Team

editor@panafrican-med-journal.com

<https://www.panafrican-med-journal.com/>

Check our special issues on COVID-19 in Africa in the PAMJ | [Volume 1](#) | [Volume 2](#)
Check our [PAMJ 2021 in review dashboard](#)
The PAMJ is also [PAMJ Conference Management System](#) | [The PAMJ Conference Proceedings](#) | [The PAMJ Blog](#)

Tanggal 25 Oktober 2022 *corresponding author* mendapat email editor tentang naskah yang dipublikasikan:

An action was taken on your published manuscript

Eksternal
Kotak Masuk



Production - Manuscript Hut Pan African Medical Journal
<production@panafrican-med-journal.com>

Sel, 25 Okt
2022, 21.30

kepada saya, Marie, kelvin.Nderitu

Dear author Bagus Setyo boedi, Department of Child Health, Faculty of Medicine, Universitas Airlangga/Dr. Soetomo General Hospital, Surabaya, Indonesia

You received this email as the corresponding author for the manuscript below:

Expression of cytokeratin-7 and cytokeratin-19 on newborn mice induced rhesus rotavirus as biliary atresia model - 2022-08-31

Bagus Setyo boedi, Ahmad Rofii, Anang Endaryanto, Sjamsul Arief

We write to let you know that the final PDF version of your manuscript is now available for review. Please check this final PDF for accuracy (mostly authors names) and let us know as soon as possible if there is any error.

To review and report any issue with the PDF version of your article, follow the link below.

<https://www.manuscript-hut.panafrican-med-journal.com/proofcheck/ManageProof.php?GetId=28408&PubType=Art&Src=pr&Proof=pdf&JournalAbr=PAMJ&ConfirmKey=1667572231>

If you have additional questions, contact the editor in charge of your article

Post production editor in charge of this PDF: Marie Paule Adamou
(paule.adamou@panafrican-med-journal.com)

Editor in charge of the manuscript: Kelvin Nderitu (kelvin.Nderitu@panafrican-med-journal.com)

Thank you for trusting us with your submission.

*This email was submitted by an automated system and is not configured to receive messages.
If necessary, please contact the editors.*

*The Production Team, **Pan African Medical Journal** Copyright 2022*

Tanggal 27 Oktober 2022 *corresponding author* menjawab email editor tentang naskah yang dipublikasikan:

BAGUS SETYOBOEDI <bagus.setyoboedi@fk.unair.ac.id> Kam, 27 Okt 2022, 13.06

kepada **Production**

Ok, I approve the pdf of manuscript

Tanggal 27 Oktober 2022 *corresponding author* mendapat email editor tentang naskah yang sudah dipublikasikan:

PAMJ - The PDF version of your article was approved

Eksternal
Kotak Masuk



Editor - Manuscript Hut Pan African Medical Journal
<editor@panafrican-med-journal.com>

Kam, 27 Okt
2022, 13.38

kepada saya, Marie, Kelvin, Pan

To
Bagus Setyoboedi, Department of Child Health, Faculty of Medicine, Universitas
Airlangga/Dr. Soetomo General Hospital, Surabaya, Indonesia

Thank you for approving the PDF version of your manuscript. The final PDF is now available
online in the *Pan African Medical Journal* through the link below

<https://www.panafrican-med-journal.com//content/article/42/322/pdf/322.pdf>

This concludes the publication of your article in the PAMJ

We look forward to publishing more of your work in the future.

PAMJ - Manuscript acceptance notice [Manuscript ID 28408]

2 pesan

Editor - Manuscript Hut Pan African Medical Journal <editor@panafrican-med-journal.com>

26 Juli 2022 pukul 10.57

Balas Ke: Editor - Manuscript Hut Pan African Medical Journal <editor@panafrican-med-journal.com>

Kepada: BAGUS SETYOBOEDI <bagus.setyoboedi@fk.unair.ac.id>

Cc: Delsa Hanane <dr.delsa.hanane@gmail.com>, Jaja Chinwe <chinwe.jaja@panafrican-med-journal.com>, Grace Mungai <grace.mungai@panafrican-med-journal.com>, editor@panafrican-med-journal.com



Dear Bagus Setyoboedi,

Manuscript: EXPRESSION OF CYTOKERATIN – 7 AND CYTOKERATIN – 19 ON NEWBORN MICE AS BILIARY ATRESIA MODEL

We are pleased to inform you that your manuscript is now formally accepted for publication in Pan African Medical Journal and will soon be published, pending payment the of Manuscript Processing Charges (if applicable; see the Manuscript Processing Charges Summary below).

Article Processing Charges (APC): If article processing charges apply to this journal and you opted to pay, APC should be paid in full within 10 days of acceptance of the manuscript. Failure to pay the Article Processing Charges within 10 days of acceptance may result in the automatic rejection of your submission.

BEWARE OF SCAMMERS: The Pan African Medical Journal only accepts payments through PayPal (to the address sales-service@panafrican-med-journal.com) and Bank transfert (to our Standard Chartered Bank Account in Kenya). Before making any payment, contact sales-service@panafrican-med-journal.com or the editor in charge of your submission.

Your manuscript is currently undergoing a quality control audit and the editorial team will eventually get back to you if need be.

Thank you for trusting the Pan African Medical Journal with your submission.

Manuscript Processing Charges Summary

- **Your decision on Article Processing Charges:** *Will pay full*
- **Your comments on Article Processing Charges:** *Non applicable*
- **Journal decision on your waiver request:** Non applicable
- **Amount to be paid by the authors:** 180 USD

Thank you for accepting to pay the Article Processing Charges (APC) of **180 USD**. You are contributing to the development of medical publishing and Open Access in Africa.

We expect authors to complete payment of APC within 10 days of acceptance of the manuscript to avoid delays in its publication. Failure to pay Article Processing Charges within 10 dys will result in the rejection of the manuscript.

The journal currently accepts 3 forms of payment; please chose below which one is suitable for you. Transfer fees must be covered by the person making the payment:

BEWARE OF SCAMMERS..! The PAMJ will never ask you to send payment by means other than bank transfer, PayPal (to the email address sales-service@panafrican-med-journal.com, or Mobile Money (for Cameroon only). We do not request payments by bitcoins or other crypto currencies/wallets. Contact the PAMJ if you have questions.

PAYMENT THROUGH BANK TRANSFER

Make a payment of **180 USD** to:

Name of account: PAN AFRICAN MEDICAL CTR

USD Account number: 87028-173160-00

Account address: P.O Box: 63565-00619, Gigiri, Nairobi, Kenya.

Standard Chartered Bank

Priority Banking, Muthaiga

P.O Box 64355 - 00620

Nairobi, Kenya

Swift Address: SCBLKENXXXX

Branch Code: 02 07600

To avoid any delays in the processing of your manuscript, send an email to sales-service@panafrican-med-journal.com to confirm the completion of the transfer. Attached the proof of payment to the email.

SECURED PAYMENT BY CREDIT CARD THROUGH PAYPAL:

If you wish to pay by PayPal using your credit card, send an email to sales-service@panafrican-med-journal.com and we will send you a PayPal email payment request. Add the title and the manuscript number for which the payment will be made.

IF YOU RESIDE IN KENYA You can pay directly to PAMJ Bank account at any Standard Chartered Bank.

Name of account: PAN AFRICAN MEDICAL CTR

USD Account number: 87028-173160-00

Kenyan shillings Account number: 01028-173160-00

Standard Chartered Bank
Priority Banking, Muthaiga
BAGUS SETYOBOEDI <bagus.setyoboedi@fk.unair.ac.id>
P.O. Box 64355-100620
Nairobi, Kenya
Kepada: Editor, Manuscript Hut Pan African Medical Journal <editor@panafrican-med-journal.com>

26 Juli 2022 pukul 11.20

Ok, thank you for accepting my manuscript and I will fulfill the charge payment.
Send payment confirmation by email to sales-service@panafrican-med-journal.com
[Kutipan teks disembunyikan]

IF YOU RESIDE IN CAMEROON You can pay directly to PAMJ Bank account at any Afriland First Bank.

Name of account: PANAFRICAN CENTER FOR PUBLIC HEALTH AND INFORMATION

Accountnumber Franc CFA (XAF) US: 05490881001

Afriland First Bank

Account address: Yaounde - Cameroon

Bank code: 10005

RIB: 10005 00001 05490881001 11

IBAN: CM21 10005 00001 05490881001 11

Code SWIFT: CCEICMCX

To avoid any delays in the processing of your manuscript, send an email to sales-service@panafrican-med-journal.com to confirm the completion of the payment.

Pan African Medical Journal Editorial Office

editor@panafrican-med-journal.com

<https://www.panafrican-med-journal.com/>

Check our *special issues on COVID-19 in Africa in the PAMJ* | [Volume 1](#) | [Volume 2](#)

Check our [PAMJ 2021 in review dashboard](#)

The PAMJ is also [PAMJ Conference Management System](#) | [The PAMJ Conference Proceedings](#) | [The PAMJ Blog](#)



PAMJ - Article Processing Charges payment instructions (Manuscript id:28408)

1 pesan

Admin - Manuscript Hut Pan African Medical Journal <admin@panafrican-med-journal.com> 27 Juli 2022 pukul 18.01
 Balas Ke: Admin - Manuscript Hut Pan African Medical Journal <admin@panafrican-med-journal.com>
 Kepada: Bagus Setyoboedi <bagus.setyoboedi@fk.unair.ac.id>, Mariette Gaelle Manifo <sales-service@panafrican-med-journal.com>, editor@panafrican-med-journal.com

Dear Setyoboedi

The instructions for payment of article processing charges are appended below.

Manuscript: EXPRESSION OF CYTOKERATIN – 7 AND CYTOKERATIN – 19 ON NEWBORN MICE AS BILIARY ATRESIA MODEL (28408)

Journal: PAMJ. Submitted 16 Feb 2021

The Pan African Medical Journal currently accepts various forms of payment; please chose below which one is suitable for you. Transfer fees must be covered by the person making the payment:

BEWARE OF SCAMMERS..! The PAMJ will never ask you to send payment by means other than bank transfer, PayPal (to the email address sales-service@panafrican-med-journal.com, or Mobile Money (for Cameroon only). We do not request payments by bitcoins or other crypto currencies/wallets. Contact the PAMJ if you have questions.

Payment through bank transfer: Make a payment of **180 USD** to:

Name of account: PAN AFRICAN CTR
US Account number:87028-173160-00
 Standard Chartered Bank
 Priority Banking, Muthaiga
 P.O Box 64355 - 00620
 Nairobi, Kenya
 Swift Address: SCBLKENXXXX
 Branch Code: 02 07600

IF YOU RESIDE IN KENYA You can pay directly to PAMJ Bank account at any Standard Chartered Bank.

Name of account: PAN AFRICAN CTR
US Account number: 87028-173160-00
Kenyan shillings Account number: 01028-173160-00
 Standard Chartered Bank
 Priority Banking, Muthaiga
 P.O Box 64355 - 00620
 Nairobi, Kenya

To avoid any delays in the processing of your manuscript, send an email to sales-service@panafrican-med-journal.com to confirm the completion of the transfer.

IF YOU RESIDE IN CAMEROON You can pay directly to PAMJ Bank account at any Afriland First Bank.

Name of account: PANAFRICAN CENTER FOR PUBLIC HEALTH AND INFORMATION
Accountnumber Franc CFA (XAF) US: 05490881001
 Afriland First Bank
Account address: Yaounde - Cameroon
Bank code: 10005
RIB: 10005 00001 05490881001 11
IBAN: CM21 10005 00001 05490881001 11
Code SWIFT: CCEICMCX

To avoid any delays in the processing of your manuscript, send an email to sales-service@panafrican-med-journal.com to confirm the completion of the payment.

Mariette Gaelle Manifo, Admin and finance

sales-service@panafrican-med-journal.com

Pan African Medical Journal (PAMJ)

Kenya: 3rd Floor, Park Suite Building, Parkland Road, Nairobi. PoBox 38583-00100, tel: +254 (0)20-520-4356 | Cameroon: Immeuble TechnoPark Essos, Yaounde, PoBox: 10020 Yaounde, tel: +237 (0)24-309-5880

Check our special issues on COVID-19 in Africa in the PAMJ | [Volume 1](#) | [Volume 2](#)

Check our [PAMJ 2021 in review dashboard](#)

The PAMJ is also [PAMJ Conference Management System](#) | [The PAMJ Conference Proceedings](#) | [The PAMJ Blog](#)



Publication payment

4 pesan

BAGUS SETYOBOEDI <bagus.setyoboedi@fk.unair.ac.id>

29 Juli 2022 pukul 12.34

Kepada: sales-service@panafrican-med-journal.com

Cc: Editor - Manuscript Hut Pan African Medical Journal <editor@panafrican-med-journal.com>, Admin - Manuscript Hut Pan African Medical Journal

<admin@panafrican-med-journal.com>

I have already paid my publication charge payment.

Manuscript: EXPRESSION OF CYTOKERATIN – 7 AND CYTOKERATIN – 19 ON NEWBORN MICE AS BILIARY ATRESIA MODEL (28408)

Journal: PAMJ. Submitted 16 Feb 2021

Best regards

Bagus Setyoboedi



IMG-20220729-WA0016.jpg

219K

Mariette Gaelle Manifo <sales-service@panafrican-med-journal.com>

29 Juli 2022 pukul 22.32

Kepada: BAGUS SETYOBOEDI <bagus.setyoboedi@fk.unair.ac.id>

Thank you,

I will send you an email to confirm your payment.

Regards

[Kutipan teks disembunyikan]

--

Mariette Gaelle Manifo

Sales and finance representative

Pan African Medical Journal

sales-service@panafrican-med-journal.com

Yaounde - Cameroon

www.panafrican-med-journal.com

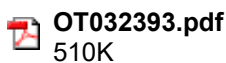
BAGUS SETYOBOEDI <bagus.setyoboedi@fk.unair.ac.id>

1 Agustus 2022 pukul 16.02

Kepada: Mariette Gaelle Manifo <sales-service@panafrican-med-journal.com>

Here is my payment bill

[Kutipan teks disembunyikan]



510K

Mariette Gaelle Manifo <sales-service@panafrican-med-journal.com>

2 Agustus 2022 pukul 16.43

Kepada: BAGUS SETYOBOEDI <bagus.setyoboedi@fk.unair.ac.id>

Received, thank you.

[Kutipan teks disembunyikan]



BAGUS SETYOBOEDI <bagus.setyoboedi@fk.unair.ac.id>

PAMJ - Article Processing Charges confirmation of payment

2 pesan

Admin - Manuscript Hut Pan African Medical Journal <admin@panafrican-med-journal.com>

2 Agustus 2022 pukul 16.43

Balas Ke: Admin - Manuscript Hut Pan African Medical Journal <admin@panafrican-med-journal.com>

Kepada: Bagus Setyoboedi <bagus.setyoboedi@fk.unair.ac.id>, Mariette Gaelle Manifo <sales-service@panafrican-med-journal.com>, editor@panafrican-med-journal.com

Dear Setyoboedi

The Pan African Medical Journal confirms that your payment of the Manuscript Processing Charges for the article below was received. Included in the email is a receipt of payment.

MANUSCRIPT PROCESSING CHARGES PAYMENT RECEIPT

Receipt for: Manuscript processing charges**Paid to:** Pan African Medical Journal**Payment received from:** Setyoboedi Setyoboedi**For manuscript title:** EXPRESSION OF CYTOKERATIN – 7 AND CYTOKERATIN – 19 ON NEWBORN MICE AS BILIARY ATRESIA MODEL (28408)**Amount paid:** 180 USD**Mode of payment:** Bank transfer**Date payment received:** 2022-07-30**Date of receipt:** 02 Aug 2022

We would like to take this opportunity to once again thank you for supporting the development of Open access publishing in Africa.

Submit all inquiries regarding manuscript processing charges to: sales-services@panafrican-med-journal.com

Mariette Gaelle Manifo, Admin and financesales-service@panafrican-med-journal.com*Pan African Medical Journal (PAMJ)**Kenya: 3rd Floor, Park Suite Building, Parkland Road, Nairobi. PoBox 38583-00100, tel: +254 (0)20-520-4356 | Cameroon: Immeuble TechnoPark Essos, Yaounde, PoBox: 10020 Yaounde, tel: +237 (0)24-309-5880**Check our special issues on COVID-19 in Africa in the PAMJ | [Volume 1](#) | [Volume 2](#)**Check our [PAMJ 2021 in review dashboard](#)**The PAMJ is also [PAMJ Conference Management System](#) | [The PAMJ Conference Proceedings](#) | [The PAMJ Blog](#)*

BAGUS SETYOBOEDI <bagus.setyoboedi@fk.unair.ac.id>

2 Agustus 2022 pukul 20.40

Kepada: rendiskaji@yahoo.com

[Kutipan teks disembunyikan]

Pan African Medical Journal - Correction of manuscript [Manuscript ID 28408]

6 pesan

Editor - Manuscript Hut Pan African Medical Journal <editor@panafrican-med-journal.com> 3 Agustus 2022 pukul 17.25
 Balas Ke: Editor - Manuscript Hut Pan African Medical Journal <editor@panafrican-med-journal.com>
 Kepada: BAGUS SETYOBOEDI <bagus.setyoboedi@fk.unair.ac.id>
 Cc: Delsa Hanane <dr.delsa.hanane@gmail.com>, Jaja Chinwe <chinwe.jaja@panafrican-med-journal.com>, Ornella Ngankong <ornella.ngankong@panafrican-med-journal.com>, Grace Mungai <grace.mungai@panafrican-med-journal.com>, editor@panafrican-med-journal.com

EXPRESSION OF CYTOKERATIN – 7 AND CYTOKERATIN – 19 ON NEWBORN MICE AS BILIARY ATRESIA MODEL (28408)

Dear BAGUS SETYOBOEDI ,

For a better visibility of your manuscript, we decided to improve the language.

In attachment the document read and improved. The changes are in red.

If you agreed with the changes, please submit the document through the system.

Submit the revised version of your manuscript through the online system. Do not submit the revised version of your manuscript as a new manuscript, it will delay the processing. To submit the revised version of your manuscript, follow the steps below:

- Log into the Manuscript Hut using the email and password you used to submit this manuscript
- Locate the manuscript tagged for resubmission, locate your manuscript and follow the link to upload the revised version

Please we wish you to submit your manuscript within five days.

Thank you for trusting us with your submission

Ornella Ngankong, Language editor

ornella.ngankong@panafrican-med-journal.com

Pan African Medical Journal (PAMJ)

Kenya: 3rd Floor, Park Suite Building, Parkland Road, Nairobi. PoBox 38583-00100, tel: +254 (0)20-520-4356 | Cameroon: Immeuble TechnoPark Essos, Yaounde, PoBox: 10020 Yaounde, tel: +237 (0)24-309-5880

Check our special issues on COVID-19 in Africa in the PAMJ | [Volume 1](#) | [Volume 2](#)

Check our [PAMJ 2021 in review dashboard](#)

The PAMJ is also [PAMJ Conference Management System](#) | [The PAMJ Conference Proceedings](#) | [The PAMJ Blog](#)



 **EditorAttach_28408.docx**
3014K


BAGUS SETYOBOEDI <bagus.setyoboedi@fk.unair.ac.id> 4 Agustus 2022 pukul 12.19
 Kepada: Editor - Manuscript Hut Pan African Medical Journal <editor@panafrican-med-journal.com>

Dear
 Editor of PAMJ

Here i attached the revision of manuscript and table with the title " expression of cytokeratin-7 and cytokeratin-19 on newborn mice induced rhesus rotavirus as biliary model atresia

Thank you

Best regards
 Bagus Setyoboedi
 [Kutipan teks disembunyikan]

 **EditorAttach_28408 revision PAMJ.docx**
3004K

Managing Editor <editor@panafrican-med-journal.com> 4 Agustus 2022 pukul 18.56
 Kepada: BAGUS SETYOBOEDI <bagus.setyoboedi@fk.unair.ac.id>

Good afternoon Dear Bagus,

Please send your revisions online through the system.

Regards
 [Kutipan teks disembunyikan]

--
Raoul Kamadjeu, MD, MPH
 Managing Editor
[Pan African Medical Journal](http://www.panafrican-med-journal.com)
editor@panafrican-med-journal.com
www.panafrican-med-journal.com
 Nairobi, Kenya
 Tel: +254 714 606 223

Follow us on Facebook:<http://www.facebook.com/pages/Panafrican-Medical-Journal/189123838167>



BAGUS SETYOBOEDI <bagus.setyoboedi@fk.unair.ac.id>
Kepada: rendiskaji@yahoo.com

4 Agustus 2022 pukul 19.14

[Kutipan teks disembunyikan]

BAGUS SETYOBOEDI <bagus.setyoboedi@fk.unair.ac.id>
Kepada: Managing Editor <editor@panafrican-med-journal.com>

4 Agustus 2022 pukul 19.46

Dear Editor

I also have already sent it by system.

Regard

Bagus Setyoboedi
[Kutipan teks disembunyikan]

Managing Editor <editor@panafrican-med-journal.com>
Kepada: BAGUS SETYOBOEDI <bagus.setyoboedi@fk.unair.ac.id>

5 Agustus 2022 pukul 17.01

Thank you
[Kutipan teks disembunyikan]



BAGUS SETYOBOEDI <bagus.setyoboedi@fk.unair.ac.id>

Manuscript 28408

2 pesan

Kelvin Nderitu <kelvin.nderitu@panafrican-med-journal.com>

15 Agustus 2022 pukul 13.34

Kepada: bagus.setyoboedi@fk.unair.ac.id

Cc: rofibudiyanto@gmail.com, aendaryanto.ae@gmail.com

Dear Dr. Bagus,

I hope this email finds you well. We requested revision on your manuscript "**EXPRESSION OF CYTOKERATIN - 7 AND CYTOKERATIN - 19 ON NEWBORN MICE AS BILIARY ATRESIA MODEL (28408)**" which we have not yet received. Please work on the requested revision so we can finish the publication of your article by the end of the day.

Kind regards.

Kelvin Nderitu

Pan African Medical Journal

kelvin.Nderitu@panafrican-med-journal.comwww.panafrican-med-journal.com

BAGUS SETYOBOEDI <bagus.setyoboedi@fk.unair.ac.id>

15 Agustus 2022 pukul 13.55

Kepada: Kelvin Nderitu <kelvin.nderitu@panafrican-med-journal.com>

Cc: rofibudiyanto@gmail.com, aendaryanto.ae@gmail.com

Dear Kelvin,

Thank you, I will do that. Soon I will send it.

Regard

Bagus S

[Kutipan teks disembunyikan]

**BAGUS SETYOBOEDI** <bagus.setyoboedi@fk.unair.ac.id>

Minor revision

2 pesan

Kelvin Nderitu <kelvin.nderitu@panafrican-med-journal.com>
Kepada: bagus.setyoboedi@fk.unair.ac.id
Cc: rofibudiyanto@gmail.com

31 Agustus 2022 pukul 12.13

Dear Bagus,

I hope this email finds you well. Your manuscript "**EXPRESSION OF CYTOKERATIN - 7 AND CYTOKERATIN - 19 ON NEWBORN MICE AS BILIARY ATRESIA MODEL (28408)**" is in the final stages of publication and we request revision on one of your references.

We could not locate reference 6 anywhere on the internet. Please provide the exact link for the reference. Use this format: Author(s), title of the reference, internet link of the reference, date of publication of the reference and the date of access of the reference. Work on this so we can finish the publication of your manuscript by the end of the day. Do not change anything inside the main text as the manuscript has already undergone peer-review.

Kind regards.

Kelvin Nderitu
Pan African Medical Journal
kelvin.Nderitu@panafrican-med-journal.com
www.panafrican-med-journal.com

BAGUS SETYOBOEDI <bagus.setyoboedi@fk.unair.ac.id>
Kepada: rendiskaji@yahoo.com

31 Agustus 2022 pukul 12.23

[Kutipan teks disembunyikan]

Pan African Medical Journal - Article Publication Notice [Manuscript 28408]

1 pesan

Production - Manuscript Hut Pan African Medical Journal <production@panafrican-med-journal.com>

31 Agustus 2022 pukul 17.29

Balas Ke: Production - Manuscript Hut Pan African Medical Journal <production@panafrican-med-journal.com>

Kepada: bagus.setyoboedi@fk.unair.ac.id, rofibudiyanto@gmail.com, aendaryanto.ae@gmail.com, sjamsularief@gmail.com

Cc: kelvin.Nderitu@panafrican-med-journal.com, editor@panafrican-med-journal.com



Dear authors,

We are glad to inform you that your manuscript is now published in its final version in the Pan African Medical Journal; note however that it may take few days for the manuscript to appear on the journal main page. Your article is accessible online at:

Research[Expression of cytokeratin-7 and cytokeratin-19 on newborn mice induced rhesus rotavirus as biliary atresia model](#)**Bagus Setyoboedi, Ahmad Rofii, Anang Endaryanto, Sjamsul Arief***Pan African Medical Journal. 2022;42:322. Published on 31 Aug 2022*

[PDF in process]

Correction of errors

Take time to carefully review your article. If you notice errors (typographical, grammatical, omissions, wrong character, author names etc..) in your publication, ensure that they are corrected within the next 5 days, before your manuscript is sent for long term preservation to several long term preservation bodies.

It is very important that errors identified be corrected promptly. Share this message with your co-authors to ensure that author names are free of errors and written in the order First Name - Middle Names(if any) - Last Name.

All corrections should be made before the final PDF is formatted. Some changes are not possible at this stage including changes in authors order, addition or subtraction of authors.

Use the attached Correction Request Sheet to compile, organize and submit your request for corrections to the production team. The sheet is also available online at

https://www.panafrican-med-journal.com/resources/Proof_Correction_Template_English.docx

If there are errors to correct, submit your completed **Corrections Request Sheet** through the online Proof Checking System by clicking on the link below.

If your manuscript does not require corrections, you still need to access the link below to approve this online version of your manuscript.


<https://www.manuscript-hut.panafrican-med-journal.com/proofcheck/ManageProof.php?GetId=28408&PubType=Art&Src=pr&Proof=htm&JournalAbr=PAMJ&ConfirmKey=1662805767>

If the link does not show in your email, simply copy the text and paste it in the address bar of your browser and click Enter

In case we do not hear from you within the next 10 (ten) working days, we will assume that your article does not need corrections and can be finalized and archived as such.

Once again, thank you for considering the Pan African Medical Journal with your submission.

Sincerely

Pan African Medical Journal Production Teameditor@panafrican-med-journal.com<https://www.panafrican-med-journal.com/>Check our special issues on COVID-19 in Africa in the PAMJ | [Volume 1](#) | [Volume 2](#)Check our [PAMJ 2021 in review dashboard](#)The PAMJ is also [PAMJ Conference Management System](#) | [The PAMJ Conference Proceedings](#) | [The PAMJ Blog](#) **PAMJ_Proof_Correction_Template_English.docx**

47K



BAGUS SETYOBOEDI <bagus.setyoboedi@fk.unair.ac.id>

An action was taken on your published manuscript

2 pesan

Production - Manuscript Hut Pan African Medical Journal <production@panafrican-med-journal.com>

25 Oktober 2022 pukul 21.30

Balas Ke: Production - Manuscript Hut Pan African Medical Journal <production@panafrican-med-journal.com>

Kepada: bagus.setyoboedi@fk.unair.ac.id, Marie Paule Adamou <paule.adamou@panafrican-med-journal.com>, kelvin.Nderitu@panafrican-med-journal.com

Dear author Bagus Setyoboedi, Department of Child Health, Faculty of Medicine, Universitas Airlangga/Dr. Soetomo General Hospital, Surabaya, Indonesia

You received this email as the corresponding author for the manuscript below:

Expression of cytokeratin-7 and cytokeratin-19 on newborn mice induced rhesus rotavirus as biliary atresia model - 2022-08-31*Bagus Setyoboedi, Ahmad Rofii, Anang Endaryanto, Sjamsul Arief*

We write to let you know that the final PDF version of your manuscript is now available for review. Please check this final PDF for accuracy (mostly authors names) and let us know as soon as possible if there is any error.

To review and report any issue with the PDF version of your article, follow the link below.

<https://www.manuscript-hut.panafrican-med-journal.com/proofcheck/ManageProof.php?GetId=28408&PubType=Art&Src=pr&Proof=pdf&JournalAbr=PAMJ&ConfirmKey=1667572231>

If you have additional questions, contact the editor in charge of your article

Post production editor in charge of this PDF: Marie Paule Adamou (paule.adamou@panafrican-med-journal.com)Editor in charge of the manuscript: Kelvin Nderitu (kelvin.Nderitu@panafrican-med-journal.com)

Thank you for trusting us with your submission.

*This email was submitted by an automated system and is no configured to receive messages. If necessary, please contact the editors.
The Production Team, Pan African Medical Journal Copyright 2022*

BAGUS SETYOBOEDI <bagus.setyoboedi@fk.unair.ac.id>

27 Oktober 2022 pukul 13.06

Kepada: Production - Manuscript Hut Pan African Medical Journal <production@panafrican-med-journal.com>

Ok, I approve the pdf of manuscript

[Kutipan teks disembunyikan]



BAGUS SETYOBOEDI <bagus.setyoboedi@fk.unair.ac.id>

PAMJ - The PDF version of your article was approved

1 pesan

Editor - Manuscript Hut Pan African Medical Journal <editor@panafrican-med-journal.com>

27 Oktober 2022 pukul 13.38

Balas Ke: Editor - Manuscript Hut Pan African Medical Journal <editor@panafrican-med-journal.com>

Kepada: Corresponding author <bagus.setyoboedi@fk.unair.ac.id>, Marie Paule <paule.adamou@panafrican-med-journal.com>, Kelvin <kelvin.Nderitu@panafrican-med-journal.com>, Pan African Medical Journal <editor@panafrican-med-journal.com>


To
Bagus Setyoboedi, Department of Child Health, Faculty of Medicine, Universitas Airlangga/Dr. Soetomo General Hospital, Surabaya, Indonesia

Thank you for approving the PDF version of your manuscript. The final PDF is now available online in the *Pan African Medical Journal* through the link below
<https://www.panafrican-med-journal.com/content/article/42/322/pdf/322.pdf>

This concludes the publication of your article in the PAMJ

We look forward to publishing more of your work in the future.

The editorial team of the PAMJ. - 2022

 **PAMJ-42-322.pdf**
983K

Research



Expression of cytokeratin-7 and cytokeratin-19 on newborn mice induced rhesus rotavirus as biliary atresia model

Bagus Setyoboedi, Ahmad Rofii,  Anang Endaryanto, Sjamsul Arief

Corresponding author: Bagus Setyoboedi, Department of Child Health, Faculty of Medicine, Universitas Airlangga/Dr. Soetomo General Hospital, Surabaya, Indonesia. bagus.setyoboedi@fk.unair.ac.id

Received: 16 Feb 2021 - **Accepted:** 25 Jul 2022 - **Published:** 31 Aug 2022

Keywords: Biliary atresia, cytokeratin-7, cytokeratin-19, mice model

Copyright: Bagus Setyoboedi et al. Pan African Medical Journal (ISSN: 1937-8688). This is an Open Access article distributed under the terms of the Creative Commons Attribution International 4.0 License (<https://creativecommons.org/licenses/by/4.0/>), which permits unrestricted use, distribution, and reproduction in any medium, provided the original work is properly cited.

Cite this article: Bagus Setyoboedi et al. Expression of cytokeratin-7 and cytokeratin-19 on newborn mice induced rhesus rotavirus as biliary atresia model. Pan African Medical Journal. 2022;42(322). 10.11604/pamj.2022.42.322.28408

Available online at: <https://www.panafrican-med-journal.com//content/article/42/322/full>

Expression of cytokeratin-7 and cytokeratin-19 on newborn mice induced rhesus rotavirus as biliary atresia model

Bagus Setyoboedi^{1,&}, Ahmad Rofii¹, Anang Endaryanto¹, Sjamsul Arief¹

¹Department of Child Health, Faculty of Medicine, Universitas Airlangga/Dr. Soetomo General Hospital, Surabaya, Indonesia

&Corresponding author

Bagus Setyoboedi, Department of Child Health, Faculty of Medicine, Universitas Airlangga/Dr. Soetomo General Hospital, Surabaya, Indonesia

Abstract

Introduction: biliary atresia (BA) is a progressive inflammation that causes obstruction and fibro-obliteration of the bile ducts during the perinatal period. Biliary atresia occurs in about 1 in 5000 to 8000 live births, and 50% require liver transplantation. This study aims to investigate the influence of induction and duration of illness after rhesus rotavirus (RRV) exposure to changes in the expression of cytokeratin-7 (CK-7) and cytokeratin-19 (CK-19) in mice models of AB. **Methods:** a total of 48 Balb/c less than a day after birth was included as model of BA. The overall sample was split randomly by using the randomization table into 4

control groups and 4 treatment groups. Groups 1,2,3, and 4 composed of 24 infant mice Balb/c (each group of 6 tails) with blue color code get a placebo (buffered saline) intraperitoneally less than a day after birth. Groups 5, 6, 7, and 8 were composed of 24 mice Balb/c (each group of 6 tails) with red color code get induction RRV 1.5×10^6 Plaque forming units (PFU) as treatment groups. **Results:** there are influence of the RRV induced changes in the expression of CK-7 murine model of BA day 3, 7, 14 and 21 after induction compared to the control ($p < 0.05$). There was interaction between induction effects and duration of illness after RRV exposure to CK-7 expression in murine models of BA on days 3, 7, 14 and 21 ($p < 0.001$). There was difference in the value of CK-19 expressions progressively between trial group and control group seen from day-3 and day 21. **Conclusion:** induction and duration of illness after rhesus rotavirus exposure effect on the expression of cytokeratin-7 and cytokeratin-19 mice models of biliary atresia.

Introduction

Biliary atresia (BA) results from progressive inflammation. In BA, obstruction and fibro-obliteration of the intra and extrahepatic bile ducts occur during the perinatal period [1-3]. Biliary atresia occurs in about 1 in 5000 to 8000 live births, and 50% require liver transplantation [4,5]. The incidence of cholestatic jaundice is 1 in every 2,500 infants [6].

Biliary atresia's etiology remains uncertain. There are several factors thought to play a role in the pathogenesis of biliary atresia BA include infection, fetal circulatory disorders, abnormal morphogenesis, exposure to toxins, and immunological disorders [4,7,8]. Perinatal hepatobiliary viral infection will cause premature apoptosis or necrosis cholangiocyte if it lasts a chronic inflammatory process will lead to the total destruction of the bile ducts [7,9]. In BA, there is cell damage caused by an immunological response. In addition, there is a change in the characteristics of bile duct cells to those of mesenchymal cells.

Bile duct epithelial cells lose cell polarity, cell communication, loss of normal structure of epithelial cells accompanied by the accumulation of extracellular matrix (MES) [10-12]. This process is known as epithelial mesenchymal transition (EMT) [13-16]. In the process of EMT is characterized by decreased expression of calcium-dependent adhesion epithelial (E-cadherin), cytokeratin-7 (CK-7), cytokeratin-19 (CK - 19), integrins and increased expression of calcium-dependent adhesion neural (N-cadherin), vimetin, fibronectin, α - smooth muscle actin (α -SMA), fibroblast specific protein-1 (FSP-1) [17-19]. Studies in cell culture defined decreasing of epithelial cells markers such as cytokeratins and increasing of mesenchymal cells markers [20-22]. Liu (2013) found decreased expression of E cadherin and increased expression of N-cadherin (cadherin switch) day 6 after induction of TGF- β in cell culture bile duct and De Vries (2011) found an increase in CK-7 and CK-19 day 7 and 14, but Taura (2010) in vitro did not get an increase in markers of mesenchymal cells [17,23,24]. The purpose of this study is to investigate the influence of induction and duration of illness after rhesus rotavirus (RRV) exposure to changes in the expression of CK-7 and CK-19 in mice models of AB.

Methods

This research is purely experimental research using factorial design to investigate the influence of induction and duration of illness after rhesus rotavirus (RRV) exposure to changes in the expression of CK-7 and CK-19 in mice models of AB.

Subject: a total of 48 Balb/c less than a day after birth was included as model of BA. The overall sample was split randomly by using the randomization table into 4 control groups and 4 treatment groups. Groups 1,2,3, and 4 composed of 24 infant mice Balb/c (each group of 6 tails) with blue color code get a placebo (buffered saline) intraperitoneally less than a day after birth. Groups 5, 6, 7, and 8 were composed of 24 mice Balb/c (each group of 6 tails) with red color code get induction RRV 1.5×10^6 PFU as treatment groups.

Inclusion criteria of Balb/c mice newborn from healthy carries, aged less than a day after birth startup research, and no any physical deformities. We excluded the baby mice born premature, and we drop out the mice with damage organs or tissues at the time of sampling for examination or the baby mice dead before age termination as specified. The control groups (O1) given 50 μ L buffered phosphate saline intraperitoneally less than a day after birth, then termination performed on the days 3, 7, 14 and 21, then checked the variables (P1-P4). Less than a day after birth, treatment groups (O2) were induced 50 μ L of phosphate buffered saline containing 1.5×10^6 PFU RRV intraperitoneally. Furthermore randomly selected for termination performed on days 3, 7, 14, and 21, then examined the variables (P1-P4).

Setting: this research was conducted at the Laboratory of Biomolecular and Biomedical Laboratories, Faculty of Medicine, University of Brawijaya, Malang. The data collection of this research was conducted in January-February 2014.

Data analysis: analysis of the average for numerical data using mean and standard deviations (SD) of each variable with the independent sample t-test to the data with univariate normal distribution. For the results of the study were not normally distributed, the analysis performed by Mann Whitney test (for data with 2 groups) or Kruskal-Wallis (for data with >2 groups) for each group by using the median, respectively.

Ethical clearance: this study is part of a larger research entitled "benefits and the effect of corticosteroids on the difference between the expression of CD56, CD68, TLR, NFkB, CD4, CD8, ANCA, fibrosis and bile duct obstruction in animal model of biliary atresia (study changes in innate immune response, innate to adaptive non-self, adaptive non-self and adaptive self)" who has received information ethics from the Health Research Ethics Committee of the Faculty of Medicine, University of Brawijaya.

Results

Basic characteristic of neonatal mice in each trial groups can be seen in Table 1. The baseline characteristics of weight initially homogeneous sample because the sample preparation in accordance with the inclusion criteria. However, in general there are differences in the mean body weight of mice when performed late termination (not included in the table). The increase in body weight of mice in the trial groups comparatively lower than the control groups for each day of termination. In this study, histopathological examination was also carried out to prove the occurrence of biliary atresia in mice induced RRV. Here is a comparison picture of the biliary tract histopathology qualitatively compared between the treatment groups to control groups (Figure 1, Figure 2, Figure 3 and Figure 4).

Induction RRV influence on expression of cytokeratin-7 and cytokeratin-19: from the expression of CK-7 and CK-19 biliary tract in the control groups of healthy mice that expresses all the variables studied, both CK-7 and CK-19. This suggests that the constitutive variables studied have been produced prior to the induction of RRV. To get an overview of the effect of RRV induced changes in the expression of CK-7 and CK-19, displayed the flow cytometry results in tabular form, all the results are arranged in the form of graphs that reflect the relative position of the two groups in each variable.

Induction RRV influence on expression of cytokeratin-7: in this study, a trial groups with a median value of expression of CK-7 quantitatively lower in the trial groups than the control groups with general results $p < 0.05$, which shows the influence of the RRV induced changes in the expression of CK-7 murine model of BA day 3, 7, 14 and 21 after induction compared to the control (Table 2). Also obtained results that are interaction between induction effects and duration of illness after RRV exposure to CK-7 expression in murine models of BA on days 3, 7, 14 and 21 with $p < 0.001$ (Table 2).

The following chart changes in expression of CK-7 (median) from time to time in the control groups compare with trial groups (Figure 5). From the above chart, expression of CK-7 decreased in trial group since day 3 compared to control group. There was difference in the value of CK-7 expressions progressively between trial group and control group obtained from day-7 and the large difference in expression values obtained on day 21. The CK-7 expressions are lower in the trial group than control group.

Induction RRV influence on expression of cytokeratin-19: in this study, a trial groups with a median value of expression of CK-19 quantitatively lower in the trial groups than the control groups with general results $p < 0.05$, which shows the influence of the RRV induced changes in the expression of CK-19 murine model of BA day 3, 7, 14 and 21 after induction compared to the control (Table 3). Also obtained results that are interaction between induction effects and duration of illness after RRV exposure to CK-19 expressions in murine models of BA on days 3, 7, 14 and 21 with $p < 0.001$ (Table 3).

The following chart changes in expression of CK-19 (median) from time to time in the control groups compare with trial groups (Figure 6). From the above chart, expression of CK-19 decreased in trial group since day 3 compared to control group. There is a progressive difference in the expression of CK-19 between the trial group and the control group obtained from day 3 and day 21. The CK-19 expressions are higher in trial group than control group. RRV induction dose of 1.5×10^6 PFU intraperitoneally in infants Balb/c mice less than 1 day after birth would affect changes in cellular adaptive immune response in biliary tract tissue. In this study, the cellular adaptive immune response that occurs is reflected in the presence of expression of CK-7 and CK-19.

The hypothesis that pro-inflammatory cytokines important for the pathogenesis of BA has been tested on mice models induced RRV. Bile duct damage initiated by viral infection which is

followed by the release of antigens "self" that has changed and activate autoreactive T-cells and specific bile ducts, which causes chronic fibrosclerosing injury to the bile duct [4].

Discussion

In this study, there were differences in mean final body weight (at termination) of mice in the control groups and trial groups. Newborn mice RRV-induced increased weight gain was relatively lower than control mice because of illness. Similarly, the mortality rate of mice in the trial groups occurs more frequently, especially before day 7 and between day 14 and 21. Mortality is caused by the baby mice looking sick and eaten by its parent in accordance with their nature. Baby mice that sick is most likely due to the induction of RRV as evidenced by the death of the trial groups more than the controls. These results are similar with Allen and Bessho, who obtained more than 80% of mice that have undergone RRV-induced biliary atresia on the 14th day of termination [25,26]. Petersen in his research got the lethality number reaches 100% in neonatal mice intervention after day 21 post-induction [27].

In this study, histopathological examination was done to prove the occurrence of inflammation and biliary tract obstruction as a result of an immunological response after induction of RRV. From the histopathology, inflammatory processes occurred from day 3 after induction of RRV were intensified on day 7. Obstruction process of biliary tract visible on day 14, and total obstruction seen at day 21. These results do not vary with Carvalho in which the inflammatory process in the biliary tract occurs on days 3 and 7 after induction of RRV, but he gets the total obstruction on day 14 [28]. Rhesus rotavirus infection in the biliary tract causing immunological dysregulation that results in inflammation of the duct epithelium and lumen of the duct becomes swollen. This inflammatory process is chronic and progressive because the autoimmune process that ended in the total obstruction of biliary tract and biliary tract cannot function properly. Rhesus rotavirus induction dose

of 1.5×10^6 PFU intraperitoneally less than 1 day after birth in infants Balb/c mice would affect changes in cellular adaptive immune response in biliary tract tissue. In this study, the cellular adaptive immune response that occurs is reflected in the presence of expression of CK-7 and CK-19. The hypothesis that pro-inflammatory cytokines important for the pathogenesis of BA has been tested on mice models induced RRV. Bile duct damage initiated by viral infection which is characterized decrease CK-7 and CK-19.

Cytokeratin-7 expressions: this study is an experimental study with Balb/c mice which proves that RRV induction dose of 1.5×10^6 PFU intraperitoneally at the age of less than 1 day after birth provides significant effect on the decrease in the expression of CK-7 when compared with controls and the decrease is going according to the time sequence begins after day 3 post-induction RRV.

In this study, decreased expression of CK-7 in experimental group compared to control group ($p < 0.001$). The results of the study Harada (2009) with the dsRNA analog administration on bile duct epithelial cell cultures also have reduced expression of CK-7 as well Valdes (2002), Wistar rats were induced by TGF- β that. There are differences in the expression of CK-7 were significantly ($\Delta = 0.30$, $p = 0.00$) between groups of families and groups try although the difference is not too big on day 3 [21,29]. On day 7 after induction of RRV also found decreased expression of CK-7 and expression differences greater than the control group ($\Delta = 3.06$, $p = 0.00$). These results are in accordance with the histopathology that showed an increase in inflammatory cells and bile duct lumen is narrower. Erickson (2008) also got mild to moderate obstruction and inflammation around the bile ducts in the preparation of histopathological on day 7 [30].

Choi (2009) found the lowest value CK-7 expressions at day 7 after administration of CCl₄ in intraperitoneal in mice. Increased expression of this cytokeratins according to De Vries (2011) caused

the entire cell stress induced RRV and some cells undergo phenotypic changes, especially for the formation of connective tissue, whereas the expression of CK-7 and CK-19 were decreased [24,31]. On day 14 the expression values obtained difference between experimental and control group greater ($\Delta = 10.6$, $p = 0.00$) and on day 21 the greatest decrease obtained in this study ($\Delta = 17.5$, $p = 0.00$). This phenomenon indicates that the longer the exposure after induction of RRV, epithelial cell damage or apoptosis, fibrosis and EMT that occurs more widely. In the histopathological results obtained biliary tract total obstruction on 21st day. These results corresponded to Feng's (2005) gain on day 21 of total obstruction extrahepatic bile duct after induction RRV [32].

Cytokeratin-7 expressions from day 3 until day 21 had an upward trend despite the lower expression values when compared with control group. This could be because the baby bulb/c is still in a growth phase so that the process of epithelialization occurs for the growth of tissues and organs as well as for cell regeneration. In bulb/c infants, the given induction RRV also in the maturity phase of growth for organ function and regeneration of cells, although the value is lower than the control group therefore occur RRV-induced inflammatory process so that the process of epithelialization of epithelial cells disrupted by inflammation, apoptosis and changes into mesenchymal cells. The difference in the value of CK-7 expressions on experimental group apoptosis and cell survival changes the phenotype of epithelial cells into mesenchymal cells accompanied by activation of fibroblasts as a result of inflammatory responses by induction of RRV.

Cytokeratin-19 expression: in this study, gain reduction the expression of CK-19 in experimental group ($p < 0.001$) and the longer the exposure time, the virus was also found reduced expression of CK-19 greater than the experimental group than the control group. Harada (2009) found that after administration of the dsRNA analog bile duct epithelial cell culture, a decline in CK-19 and other markers of epithelial cells and an increase in

markers - markers of mesenchymal cells, such as FSP-1 and vimentin [21]. On the third day there is a decrease in the expression of CK-19 significant ($\Delta = 1.1$; $p = 0.007$) between the groups. On day 7 obtained the lowest decline and greatest expression differences CK-19 among experimental group compared to control group ($\Delta = 13.9$; $p = 0.000$). Yabushita (2001) found a decrease in the expression of CK-19 since day 3 in rats induced RRV. De Vries (2011) found that difference expression of CK-19 were increased compared to control on day 7, results this is supported by the increased expression of mesenchymal cell markers such as α -SMA [24,33].

Increased expression of CK-19 at experimental group happened from day 14 ($\Delta = 10.8$; $p = 0.000$) and continued on day 21 although it remained below the pattern control group ($\Delta = 7.6$; $p = 0.000$). Histopathological results at day 14 showed that the distribution of inflammatory cells reached a maximum and on day 21 had occurred total obstruction biliary tract. This research is in accordance with Paku (2005) which says that although there has been a total blockage on histopathologic examination, however CK-19 can still be detected on flow cytometry examination [14,17,21].

In the EMT process biliary atresia besides a decline in the expression of CK-7 and CK-19, obtained also a decrease other markers of epithelial cells (E-cadherin) and an increase in markers of mesenchymal cells such as N-cadherin vimentin, FSP-1, α -SMA, fibronectin [10,13,20,21,29]. In biliary atresia EMT process, in addition to decrease expression of CK-19 and other epithelial cell markers, also found an increasing in the expression of mesenchymal cells (vimentin, FSP-1, α -SMA, collagen type 1, fibronectin). And in normal mammalian life, mesenchymal cells will always be formed to establish and maintain the integrity of connective tissue organs and tissues [34].

Conclusion

The results of this study provide additional evidence of the truth of the hypothesis that the induction of RRV resulted in changes the expression of cytokeratin-7 and cytokeratin-19 in the pathogenesis of BA, thus opening discourse to do further studies for new strategies in the management of medically BA. Progressive decrease expression of cytokeratin-7 and cytokeratin-19 beginning on day 7 with a peak at day 21 shows that the possibility of a good time for medical intervention performed around day 7 and before day 14, because after day 14, the occurrence of BA already irreversible.

What is known about this topic

- *Biliary atresia (BA) is a progressive inflammatory obstruction in bile ducts during the perinatal period;*
- *Etiology of biliary atresia is still unclear;*
- *In biliary atresia, there are decreased expression of calcium-dependent adhesion epithelial (E-cadherin), cytokeratin-7 (CK-7), and cytokeratin-19 (CK-19).*

What this study adds

- *There is influence of the RRV induced changes in the expression of CK-7 murine model of BA day 3, 7, 14 and 21 after induction compared to the control;*
- *There are interaction between induction effects and duration of illness after RRV exposure to CK-7 expressions in murine models of BA on days 3, 7, 14 and 21;*
- *Induction and duration of illness after rhesus rotavirus exposure effect on the expression of cytokeratin-7 and cytokeratin-19 mice models of biliary atresia.*

Competing interests

The authors declare no competing interests.

Authors' contributions

Bagus Setyoboedi conceived and designed analysis, collect the data, contributed data and analysis tool, performed the analysis, drafted and wrote the article, and final approval of the version to be published; Ahmad Rofii collected the data, contributed data and analysis tool, performed the analysis, drafted and wrote the article, and final approval of the version to be published; Anang Endaryanto and Sjamsul Arief contributed data and analysis tool, final approval of the version to be published. All the authors have read and agreed to the final manuscript.

Tables and figures

Table 1: sample characteristics

Table 2: changes in the expression of cytokeratin-7 in the RRV induction groups and control groups

Table 3: changes in the expression of cytokeratin-19 in the RRV induction groups and control groups

Figure 1: histological slices of liver and biliary tract tissues of infant mice after termination day 3; A) control groups: no visible presence of inflammatory cells in the lumen of the bile duct with no narrowing (black arrow); B) treatment groups: visible infiltration of inflammatory cells accompanied by swelling of the lumen of the bile duct that causes ranging narrowed lumen (black arrow) (bPV: branch of portal vein, bHA: branch of hepatic artery)

Figure 2: histological slices of liver and biliary tract tissues of infant mice after termination day 7; A) control groups: no visible presence of inflammatory cells in the lumen of the bile duct with no narrowing (black arrow); B) treatment groups: visible infiltration of inflammatory cells that multiply the lumen of the bile duct causing swelling that result in increased narrow lumen (black arrow) compared to day 3 (bPV: branch of portal vein, bHA: branch of hepatic artery)

Figure 3: histological slices of liver and biliary tract tissues of mice after termination day 14; A) control groups: no visible presence of inflammatory cells in the lumen of the bile duct with no narrowing (black

arrow); B) treatment groups: visible infiltration a lot of inflammatory cells that cause swelling and the lumen of the bile ducts become clogged lumen (black arrow) (bPV: branch of portal vein, bHA: branch of hepatic artery)

Figure 4: histological slices of liver and biliary tract tissues of mice after termination day 21; A) control groups: no visible presence of inflammatory cells in the lumen of the bile duct with no narrowing (black arrow); B) treatment groups: visible lumen of the bile duct has undergone atresia (black arrows) (bPV: branch of portal vein, bHA: branch of hepatic artery)

Figure 5: effect of induction of RRV and duration of illness after RRV exposure to changes in the expression of cytokeratin - 7 (median) compared to the control groups

Figure 6: effect of induction of RRV and duration of illness after RRV exposure to changes in the expression of cytokeratin - 19 (median) compared to the control groups

References

- Balistreri WF, Grand R, Hoofnagle JH, Suchy FJ, Ryckman FC, Perlmutter DH *et al.* Biliary atresia: current concepts and research directions. *Hepatology.* 1996;23(6): 1682-1692. [PubMed](#) | [Google Scholar](#)
- Bezerra JA. Potential etiologies of biliary atresia. *Pediatr Transplant.* 2005 Oct;9(5): 646-51. [PubMed](#) | [Google Scholar](#)
- Hadzic N. Biliary atresia. *Acta Medica Academica.* 2009;38: 92-103. [Google Scholar](#)
- Kahn E. Biliary atresia revisited. *Pediatr Dev Pathol.* 2004 Mar-Apr;7(2): 109-24. [PubMed](#) | [Google Scholar](#)
- Hartley JL, Davenport M, Kelly DA. Biliary atresia. *Lancet.* 2009;374(9702): 1704-13. [PubMed](#) | [Google Scholar](#)
- Feldman AG, Sokol RJ. Neonatal cholestasis. *Neoreviews.* 2013 Feb 1;14(2): 10. [PubMed](#) | [Google Scholar](#)

7. Mack CL. The pathogenesis of biliary atresia: evidence for a virus induced autoimmune disease. *Semin Liver Dis.* 2007;27(3): 233-242. **PubMed** | **Google Scholar**
8. Basset MD, Murray KF. Biliary atresia recent progress. *J Clin Gastroenterol.* 2008 Jul;42(6): 720-9. **PubMed** | **Google Scholar**
9. Shivakumar P, Campbell KM, Sabla GE, Miethke A, Tiao G, McNeal MM *et al.* Obstruction of extrahepatic bile ducts by lymphocytes is regulated by IFN- γ in experimental biliary atresia. *J Clin Invest.* 2004;114(3): 322-329. **PubMed** | **Google Scholar**
10. Díaz R, Kimf JW, Hui J, Li Z, Swain GP, Fong K *et al.* Evidence for the epithelial to mesenchymal transition in biliary atresia fibrosis. *Hum Pathol.* 2008 Jan;39(1): 102-15. **PubMed** | **Google Scholar**
11. Greenbaum LE. Hedgehog signaling in biliary fibrosis. *J Clin Invest.* 2008;118(10): 3263-3265. **PubMed** | **Google Scholar**
12. Rygiel KA, Robertson H, Marshall HL, Pekalski M, Zhao L, Booth TA *et al.* Epithelial mesenchymal transition contributes to portal tract fibrogenesis during human chronic liver disease. *Lab Invest.* 2008;88(2): 112-123. **PubMed** | **Google Scholar**
13. Omenetti A, Porrello A, Jung Y, Yang L, Popov Y, Choi SS *et al.* Hedgehog signaling regulates epithelialmesenchymal transition during biliary fibrosis in rodents and humans. *J Clin Invest.* 2008;118(10): 3331-3342. **PubMed** | **Google Scholar**
14. Park SM. The crucial role of cholangiocytes in cholangiopathies. *Gut Liver.* 2012;6(3): 295-304. **PubMed** | **Google Scholar**
15. Xu J, Lamouille S, Derynck R. TGF- β -induced epithelial to mesenchymal transition. *Cell Res.* 2009 Feb;19(2): 156-72. **PubMed** | **Google Scholar**
16. Zeisberg M, Yang C, Martino M, Duncan MB, Rieder F, Tanjore H *et al.* Fibroblasts derive from hepatocytes in liver fibrosis via epithelial to mesenchymal transition. *J Biol Chem.* 2007 Aug 10;282(32): 23337-47. **PubMed** | **Google Scholar**
17. Lee K, Nelson CM. New insight into the regulation of epithelial mesenchymal transition and tissue fibrosis. *Int Rev Cell Mol Biol.* 2012;294: 171-221. **PubMed** | **Google Scholar**
18. Kalluri R. EMT: when epithelial cells decide to become mesenchymal like cells. *J Clin Invest.* 2009 Jun;119(6): 1417-9. **PubMed** | **Google Scholar**
19. Wells RG. Epithelial to mesenchymal transition in liver fibrosis: here today, gone tomorrow? *Hepatology.* 2010;51(3): 737-740. **PubMed** | **Google Scholar**
20. Sato Y, Harada K, Ozaki S, Furubo S, Kizawa K, Sanzen T *et al.* Cholangiocytes with mesenchymal features contribute to progressive hepatic fibrosis of the polycystic kidney rat. *Am J Pathol.* 2007;171(6): 1859-1871. **PubMed** | **Google Scholar**
21. Harada K, Sato Y, Ikeda H, Isse K, Ozaki S, Enomae M *et al.* Epithelial mesenchymal transition induced by biliary innate immunity contributes to the sclerosing cholangiopathy of biliary atresia. *J Pathol.* 2009 Apr;217(5): 654-64. **PubMed** | **Google Scholar**
22. Deng YH, Pu CL, Li YC, Zhu J, Xiang C, Zhang MM *et al.* Analysis of biliary epithelial-mesenchymal transition in portal tract fibrogenesis in biliary atresia. *Dig Dis Sci.* 2011 Mar;56(3): 731-40. **PubMed** | **Google Scholar**
23. Taura K, Miura K, Iwaisako K, Osterreicher CH, Kodama Y, Penz-Osterreicher M *et al.* Hepatocytes do not undergo epithelial mesenchymal transition in liver fibrosis in mice. *Hepatology.* 2010 Mar;51(3): 1027-36. **PubMed** | **Google Scholar**
24. De Vries W. Bile duct proliferation and hedgehog signaling in murine biliary atresia: a pilot study. Degree of Master in University Medical Center Groningen. Groningen. 2011.
25. Allen SR, Jafri M, Donnelly B, McNeal M, Witte D, Bezerra J *et al.* Effect of rotavirus strain on the murine model of biliary atresia. *J Virol.* 2007;81(4): 1671-1679. **PubMed** | **Google Scholar**

26. Bessho K, Bezerra JA. Biliary atresia: Will blocking inflammation tame the disease? *Annu Rev Med.* 2011;62: 171-185. **PubMed** | **Google Scholar**
27. Petersen C, Grassholl S, Luciano L. Diverse morphology of biliary atresia in an animal model. *J Hepatol.* 1998 Apr;28(4): 603-7. **PubMed** | **Google Scholar**
28. Carvalho E, Liu C, Shivakumar P, Sabla G, Aronow B, Bezerra JA. Analysis of the biliary transcriptome in experimental biliary atresia. *Gastroenterology.* 2005;129(2): 713-717. **PubMed** | **Google Scholar**
29. Valdes F, Alvarez AM, Locascio A, Vega S, Herrera B, Fernandez M *et al.* The epithelial mesenchymal transition confers resistance to the apoptotic effects of transforming growth factor β in fetal rat hepatocytes. *Mol Cancer Res.* 2002 Nov;1(1): 68-78. **PubMed** | **Google Scholar**
30. Erickson N, Mohanty SK, Shivakumar P, Sabla G, Chakraborty R, Bezerra JA. Temporal spatial activation of apoptosis and epithelial Injury in murine experimental biliary atresia. *Hepatology.* 2008;47(5): 1567-77. **PubMed** | **Google Scholar**
31. Choi SS, Diehl AM. Epithelial to mesenchymal transitions in the liver. *Hepatology.* 2009;50(6): 2007-2013. **PubMed** | **Google Scholar**
32. Feng J, Lia M, Caib T, Tang H, Gu W. Rotavirus induced murine biliary atresia is mediated by nuclear factor- κ B. *J Pediatr Surg.* 2005 Apr;40(4): 630-6. **PubMed** | **Google Scholar**
33. Yabushita K, Yamamoto K, Ibuki N, Okano N, Matsumura S, Okamoto R *et al.* Aberrant expression of cytokeratin - 7 as a histological marker of progression in primary biliary cirrhosis. *Liver.* 2001;21(1): 50-55. **PubMed** | **Google Scholar**
34. Nakaya Y, Sheng G. Epithelial to mesenchymal transition during gastrulation: an embryological view. *Dev Growth Differ.* 2008 Dec;50(9): 755-66. **PubMed** | **Google Scholar**

Table 1: sample characteristics

Day	Control groups				Trial groups			
	3	7	14	21	3	7	14	21
Number of groups	6	6	6	6	6	6	6	6
Mean early BW (g)	1.84	1.82	1.80	1.81	1.85	1.83	1.80	1.82
Drop out	2	0	0	0	2	2	1	2
Total samples	4	6	6	6	4	4	5	4

BW: body weight

Table 2: changes in the expression of cytokeratin-7 in the RRV induction groups and control groups

Variable	Day	Control groups	Trial groups	p* between groups per variables
		Median (interquartil)	Median (interquartil)	
CK - 7	3	4.5 (0.06) %	4.2 (0.05) %	0.00*
	7	6.9 (0.15) %	3.9 (0.10) %	0.00*
	14	20.8% (0.08) %	10.2 (3.22) %	0.00*
	21	25.2 (0.63)%	7.7 (0.71) %	0.00*
	p*	0.000**	0.02**	

*significant differences by Mann Whitney test at $\alpha=0.05$; ** significant differences by Kruskal Wallis test at $\alpha=0.05$

Table 3: changes in the expression of cytokeratin-19 in the RRV induction groups and control groups

Variable	Day	Control groups Median (interquartil)	Trial groups Median (interquartil)	p* between groups per variables
CK - 19	3	6.4 (0.64) %	5.3 (0.06) %	0.007***
	7	18.2 (0.14) %	4.3 (0.09) %	0.000*
	14	19.4 (1.02) %	8.6 (1.59) %	0.000*
	21	23.3 (0.06) %	15.7 (0.71)%	0.000*
	p	<0.000**	0.002**	

*significant differences by Mann Whitney test at $\alpha < 0.05$; ** significant differences by Kruskal Wallis test at $\alpha < 0.05$; *** significant differences by T-Test at $p < 0.05$

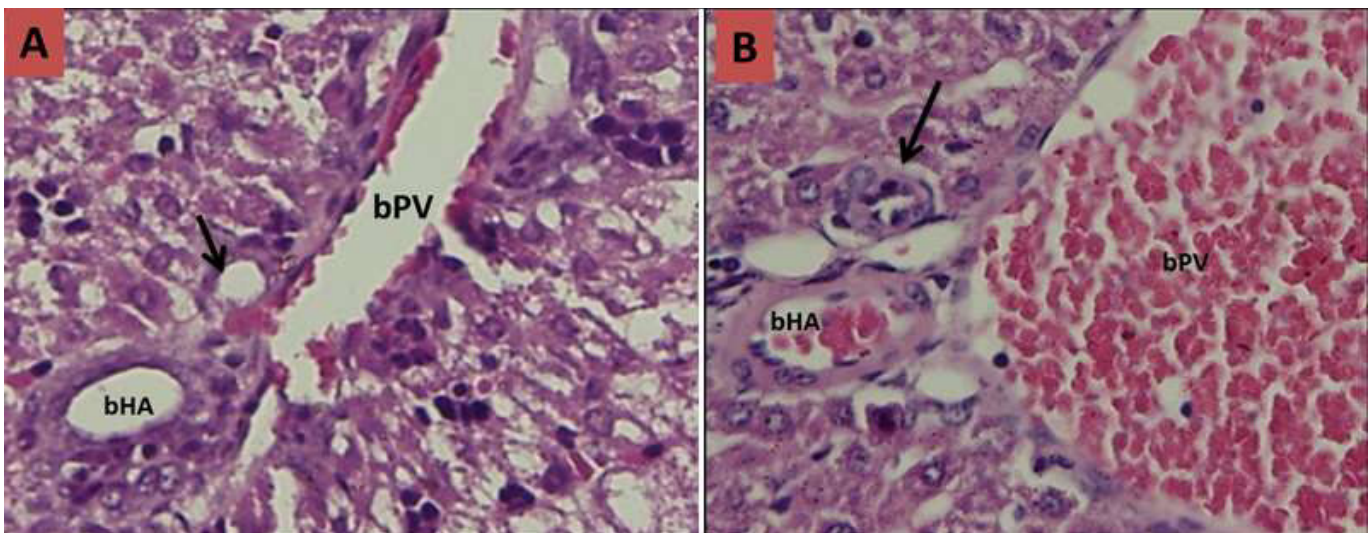


Figure 1: histological slices of liver and biliary tract tissues of infant mice after termination day 3; A) control groups: no visible presence of inflammatory cells in the lumen of the bile duct with no narrowing (black arrow); B) treatment groups: visible infiltration of inflammatory cells accompanied by swelling of the lumen of the bile duct that causes ranging narrowed lumen (black arrow) (bPV: branch of portal vein, bHA: branch of hepatic artery)

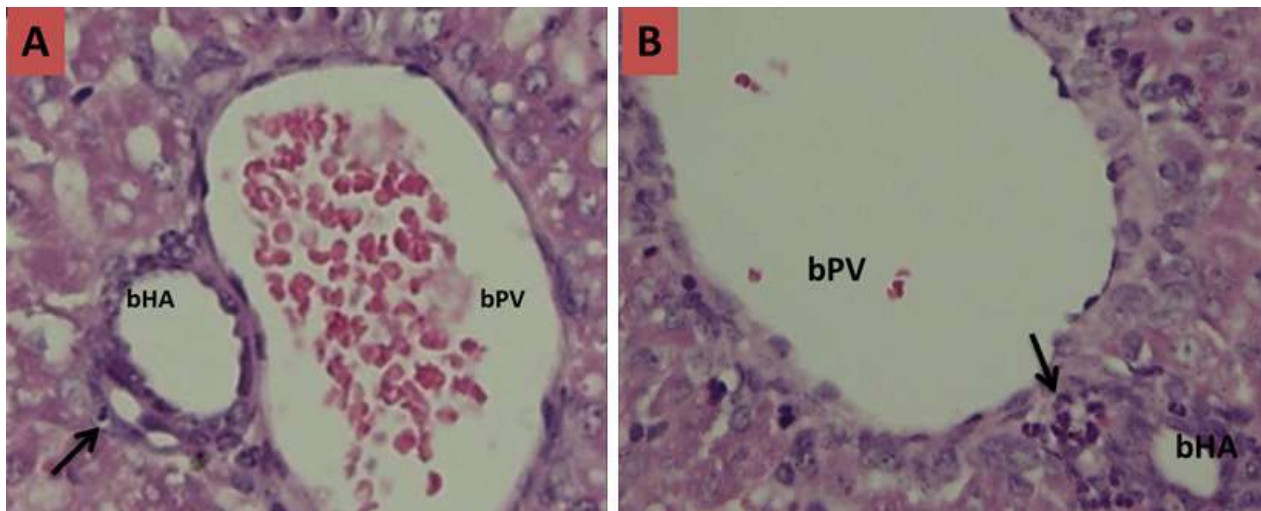


Figure 2: histological slices of liver and biliary tract tissues of infant mice after termination day 7; A) control groups: no visible presence of inflammatory cells in the lumen of the bile duct with no narrowing (black arrow); B) treatment groups: visible infiltration of inflammatory cells that multiply the lumen of the bile duct causing swelling that result in increased narrow lumen (black arrow) compared to day 3 (bPV: branch of portal vein, bHA: branch of hepatic artery)

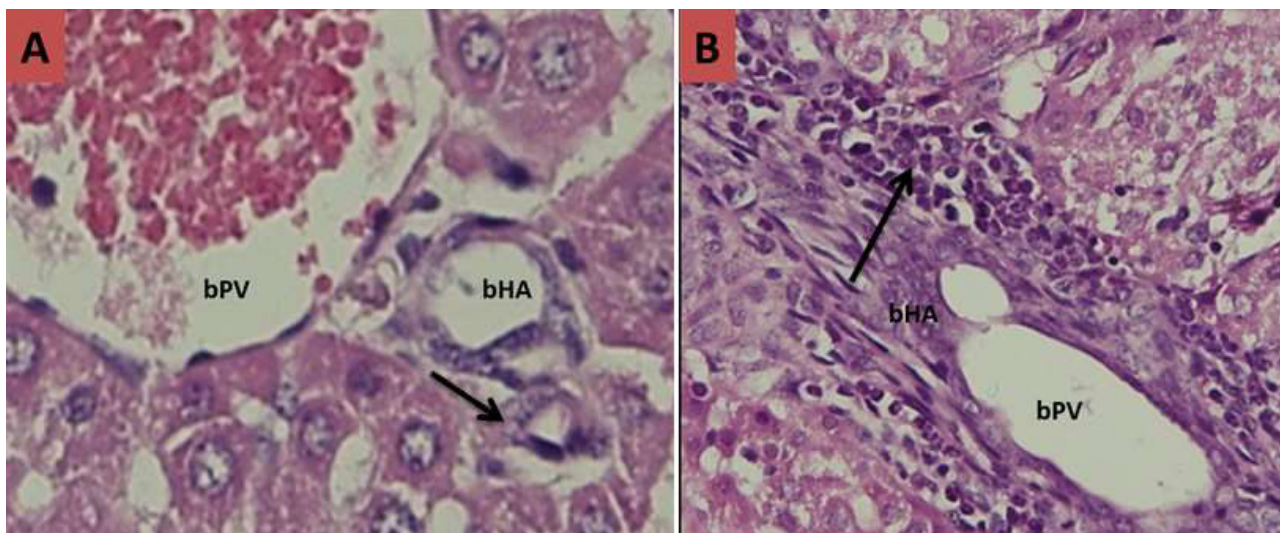


Figure 3: histological slices of liver and biliary tract tissues of mice after termination day 14; A) ontrol groups: no visible presence of inflammatory cells in the lumen of the bile duct with no narrowing (black arrow); B) treatment groups: visible infiltration a lot of inflammatory cells that cause swelling and the lumen of the bile ducts become clogged lumen (black arrow) (bPV: branch of portal vein, bHA: branch of hepatic artery)

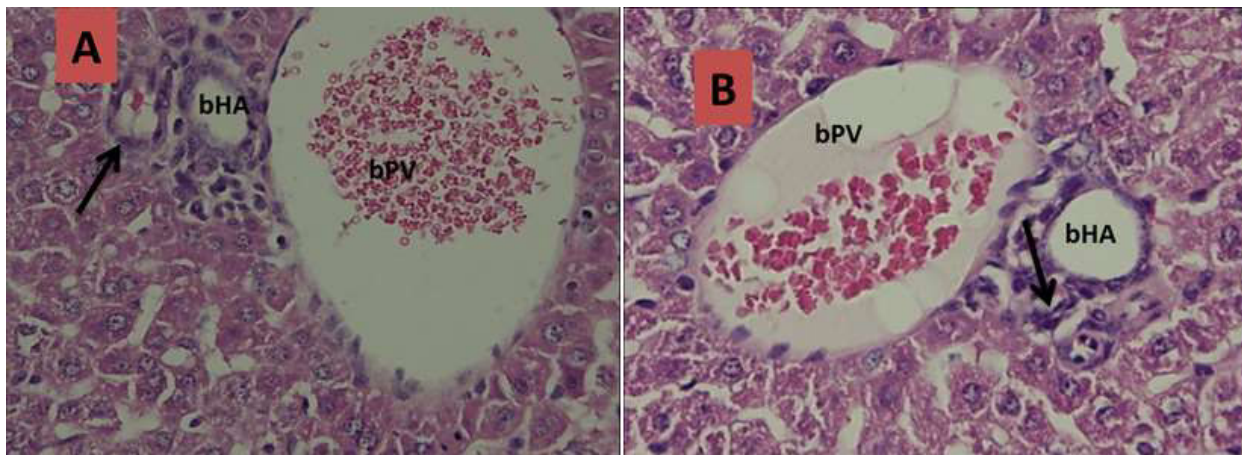


Figure 4: histological slices of liver and biliary tract tissues of mice after termination day 21; A) control groups: no visible presence of inflammatory cells in the lumen of the bile duct with no narrowing (black arrow); B) treatment groups: visible lumen of the bile duct has undergone atresia (black arrows) (bPV: branch of portal vein, bHA: branch of hepatic artery)

CK-7

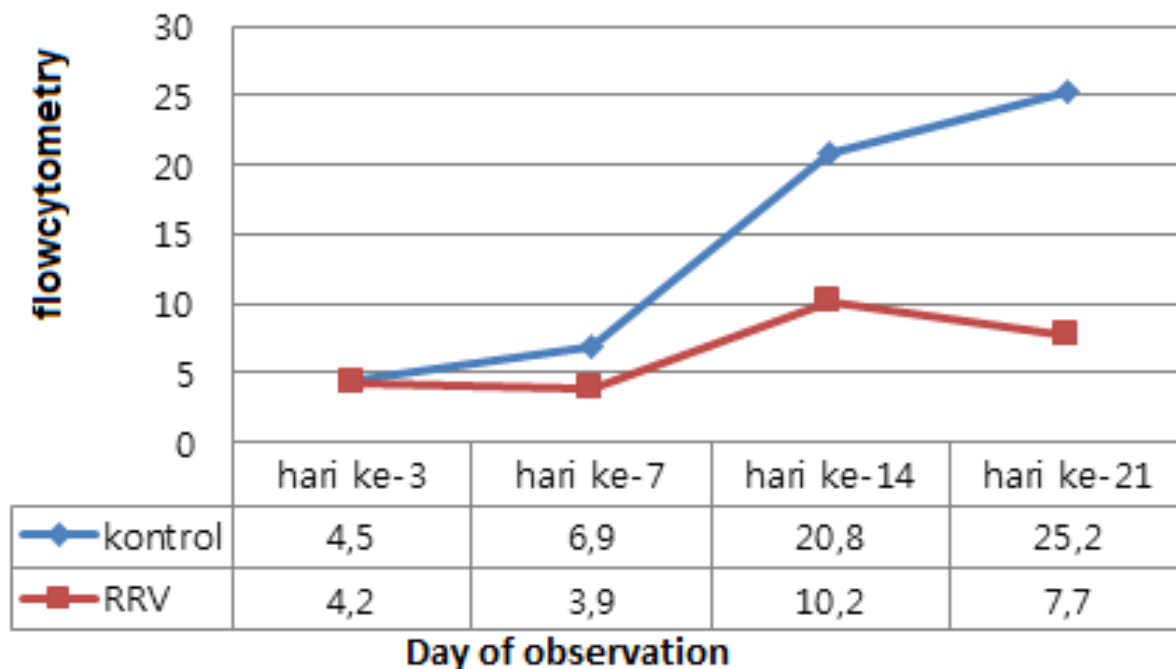


Figure 5: effect of induction of RRV and duration of illness after RRV exposure to changes in the expression of cytokeratin - 7 (median) compared to the control groups

CK-19

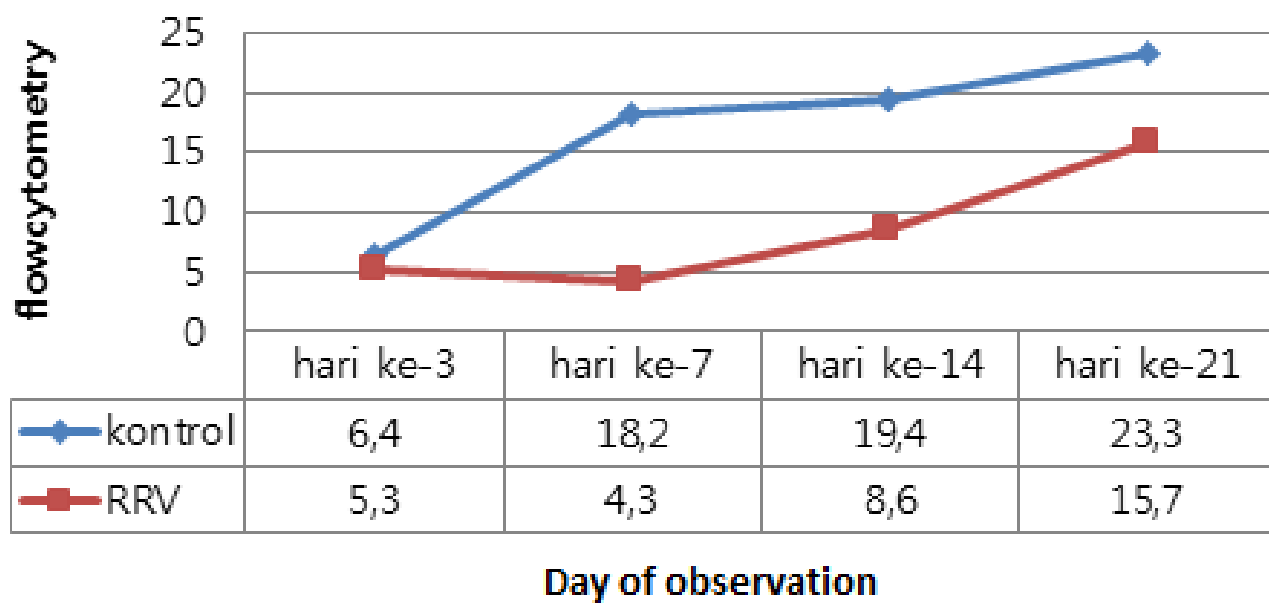


Figure 6: effect of induction of RRV and duration of illness after RRV exposure to changes in the expression of cytokeratin - 19 (median) compared to the control groups