

Cranial vault reduction cranioplasty for severe macrocephaly due to holoprosencephaly and subdural hygroma: a case report

by Muhammad Arifin Parenrengi

Submission date: 28-Jul-2023 03:51PM (UTC+0800)

Submission ID: 2137960002

File name: 2023_-_bf3cc174-6040-4237-b1f3-8d3d332bf4e6.pdf (833.51K)

Word count: 2551

Character count: 14069



Cranial vault reduction cranioplasty for severe macrocephaly due to holoprosencephaly and subdural hygroma: a case report

Ahmad Data Dariansyah¹ · Wihasto Suryaningtyas¹ · Muhammad Arifin Parenrengi¹

Received: 17 April 2023 / Accepted: 19 May 2023

© The Author(s), under exclusive licence to Springer-Verlag GmbH Germany, part of Springer Nature 2023

Abstract

Background Severe macrocephaly can still be found in developing countries. This condition is usually caused by neglected hydrocephalus and can cause a lot of morbidities. Cranial vault reconstruction cranioplasty is the main treatment option for severe macrocephaly.

Holoprosencephaly is often seen with features of microcephaly. Hydrocephalus should be considered as the main cause in HPE patients with features of macrocephaly. In this report, we present a rare case of cranial vault reduction cranioplasty procedure in patient with severe macrocephaly due to holoprosencephaly and subdural hygroma.

Case description A 4-year-10-month-old Indonesian boy was admitted with head enlargement since birth. He had a history of VP shunt placement when he was 3 months old. But the condition was neglected. Preoperative head CT showed massive bilateral subdural hygroma that compressed brain parenchyma caudally. From the craniometric calculation, the occipital frontal circumference was 70.5 cm with prominent vertex expansion, the distance between nasion toinion was 11.91 cm and the vertical height was 25.59 cm. The preoperative cranial volume was 24.611 cc. The patient underwent subdural hygroma evacuation and cranial vault reduction cranioplasty. The postoperative cranial volume was 10.468 cc.

Conclusion Subdural hygroma can be a rare cause of severe macrocephaly in holoprosencephaly patients. Cranial vault reduction cranioplasty and subdural hygroma evacuation is still the main treatment option. Our procedure successfully reduces significant cranial volume (57.46% volume reduction).

Keywords Macrocephaly · Holoprosencephaly · Subdural hygroma · Hydrocephalus · Cranial vault reduction cranioplasty · Neglected disease

Introduction

Macrocephaly is defined as an abnormal large head with an occipital frontal circumference (OFC) more than 2 standard deviations above the mean or above the 97th percentile for age and sex. Macrocephaly is a fairly common condition in the pediatric population with an incidence rate of 2–5%. Many types of diseases can cause macrocephaly, varying from benign to more severe conditions [1, 2].

Holoprosencephaly (HPE) is the most common congenital anomaly of the forebrain development, resulting from

incomplete separation of the prosencephalon, and associated with neurologic impairment and malformation of the brain and craniofacial structure. Microcephaly is often present as craniofacial malformations in HPE [3–5]. In HPE patients with normal head size or macrocephaly, hydrocephalus should be considered as the main cause [3, 4]. Subdural hygroma or subarachnoid enlargement can also be found in HPE; however, it rarely causes macrocephaly [6].

Severe macrocephaly (OFC > 60 cm) is rarely found in developed countries. But it is still often found in developing countries like Indonesia. Several factors can be the cause, such as socioeconomic, education, or difficulty in accessing health care services [7]. Severe macrocephaly often causes many morbidities in the patient. Due to mobilization difficulties, patients are often only able to lie in bed. Difficulties in nursing care, motor development, and cosmetics are also becoming problems for these patients. Cranial vault reduction cranioplasty surgery is often needed to reduce the

✉ Muhammad Arifin Parenrengi
muhammad.arifin@fk.unair.ac.id

¹ Department of Neurosurgery, Faculty of Medicine, Universitas Airlangga, Dr. Soetomo General Academic Hospital, Jalan Mayjend Prof. Dr. Moestopo No. 6-8, Mojo, Gubeng, Surabaya, East Java 60285, Indonesia

cranial volume [3], an effort to decrease the associated morbidities [7, 8]. In this case report, we present a rare case of cranial vault reduction cranioplasty procedure in a patient with severe macrocephaly due to holoprosencephaly and subdural hygroma.

Case presentation

A 4-year-10-month-old Indonesian boy was admitted with head enlargement since birth. The patient also complained of vomiting and had a history of persistent seizures. The patient was referred from another hospital, where he had a history of VP shunt placement due to HPE-related hydrocephalus when he was 3 months old. After the operation, the

patient was neglected; he was never brought to the hospital and never re-examined by a neurosurgeon. The family said that after VP shunt placement, the patient's head still tended to be enlarged.

On examination, he was fully conscious with GCS 15, but accompanied by developmental delay. The patient could only lie on bed and was unable to raise his head on his own. The OFC was 70.5 cm with prominent vertex expansion, and the fontanelle was still widely opened (Fig. 1). The VP shunt chamber was migrated and palpated in the right clavicle region.

Preoperative head CT scan showed massive bilateral subdural hygroma that compressed and pushed brain parenchyma caudally. The midline structures appear fused and a single ventricle system was seen. The ventricular catheter

Fig. 1 Preoperative 3D reconstruction head CT shows severe macrocephaly with prominent vertex expansion. **A** Anterior view. **B** Posterior view. **C** Right side view. **D** Left side view

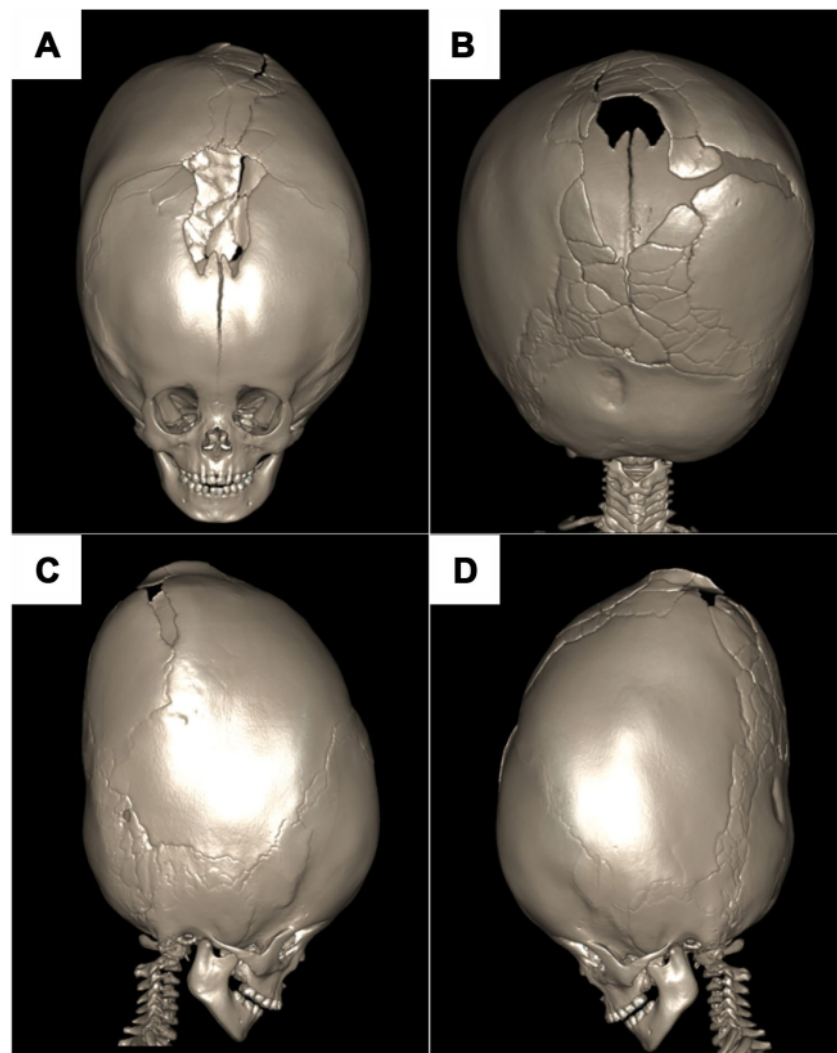
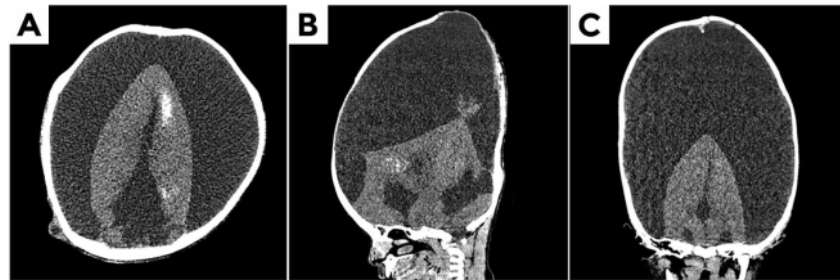


Fig. 2 Preoperative head CT shows massive bilateral subdural hygroma that compress brain parenchyma caudally. Midline structures appear to be fused and a single ventricle system was seen. **A** Axial. **B** Sagittal. **C** Coronal

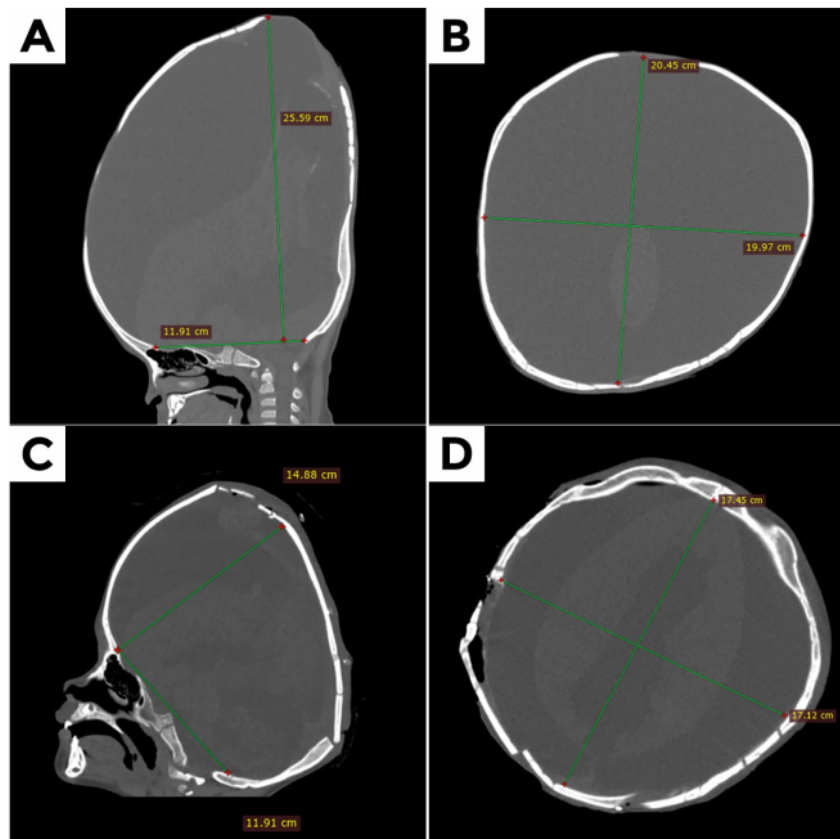


was not seen intracranially (Fig. 2). From the craniometric calculation, the distance between nasion to inion was 11.91 cm and the vertical height was 25.59 cm. The patient presents with a hyper-brachycephalic head shape with a cephalic index of 97. The biparietal diameter (BPD) was 19.97 cm and the occipitofrontal diameter (OFD) was 20.45 cm (Fig. 3). The preoperative cranial volume was 24.611 cc. The volume of the cranial was calculated with the ellipsoid volume formula: $V = \frac{3}{4} \pi abc$, where V is the volume of the ellipsoid and a , b , and c dimensions of the ellipsoid [8].

Surgical procedure

Cranial vault reduction cranioplasty surgery was performed to reduce cranial volume. The initial goal of surgery was to evacuate all of the subdural hygroma, and total reconstruction of the calvaria. The main purpose of this surgery is to make it easier for the parents to care for patients, such as carrying and could avoid complications from prolonged immobilization. The patient also has a developmental delay and was in a neglected condition for

Fig. 3 Comparison of head CT before and after surgery. **A** Sagittal before surgery. **B** Axial before surgery. **C** Sagittal after surgery. **D** Axial after surgery



more than 4 years. This condition can make it difficult for the patient to lift his head on his own after surgery.

The patient was put in a prone position with head extended. The optimal sphinx position cannot be attained because the head was too heavy and large. A coronal incision was performed, and the scalp was flapped anteriorly and posteriorly. The dura mater is carefully separated from the bone. Then we cut off the excess parietal, temporal, and occipital bones. The frontal bone was not accessible caused of difficulty in proper sphinx positioning. Dural incision was made to remove as much of the subdural hygroma as possible. Then we did wedge-shaped cut in the temporal bone and did the bone reconstruction. Bone fixation was done using wires.

Post-operative course

After surgery, the patient was treated in ICU for 6 days because of seizures. From the postoperative head CT, there was a significant reduction in craniometric calculations. Postoperative vertical height was 14.88 cm, BPD was 17.12 cm, and OFD was 17.45 cm (Fig. 3). The postoperative cranial volume was 10.468 cc (57.46% volume reduction). The patient was discharged on the 11th postoperative day.

Because this case was recently done, follow-up time for this patient was limited. One month postoperatively, the patient came to the outpatient clinic. The patient is still unable to lift his head on his own. But we can see improvement in the patient. Objectively, the size of the patient's head is reduced. The parents also find it easier and lighter to carry the patient.

Discussion

Severe macrocephaly can cause many morbidities to patients, due to difficulties in mobilization, skin breakdown, and poor cosmetics. These problems can impair patients' quality of life and can be a significant burden for the patients, families, or caregivers. Neglected or partially treated hydrocephalus or enlargement of subarachnoid spaces are common causes of macrocephaly in pediatric patients [1, 7, 9]. HPE patients often have features of microcephaly. Macrocephaly can be found in HPE-associated hydrocephalus [3, 4, 6].

Over the past decades, several authors have studied various surgical techniques for treating macrocephaly. In patients with hydrocephalic macrocephaly, CSF shunting with VP shunt only may be adequate. But in severe macrocephaly, cranial vault reduction cranioplasty is necessary to reduce cranial volume [9–11].

The first reduction cranioplasty surgery was performed by Ehni in 1951 in the case of hydrocephalic children. He performed the surgery in 13 stages. In 1964, Sayers and Duran reported 3 stages of reduction cranioplasty surgery [7, 8]. With the development of neurosurgery and advances in medical technology, reduction cranioplasty surgery is currently growing rapidly. In 2010, Kohan and colleagues reported the application of molding helmet therapy after total cranial vault remodeling [12]. In 2014, Shen and colleagues reported a technique of reduction cranioplasty in 5 cases of hydrocephalic macrocephaly with the help of 3D computer remodeling [13]. In 2020, Saleh and colleagues reported the advantages of using virtual surgical planning for the reduction of cranioplasty [14]. These advancements are expected to reduce complications during surgery, such as reducing blood loss, operating time, and infection rate.

In our case, the macrocephaly was caused by HPE and massive subdural hygroma without a sign of hydrocephalus. Because there were no signs of hydrocephalus, and subdural hygroma was a pathological condition, we planned a one-stage operation to evacuate the entire subdural hygroma and perform a total reconstruction of the calvaria without VP shunt placement. Initially, we planned to put the patient in a sphinx position, but the optimal sphinx position cannot be attained because the head was too heavy and large. We put the patient in a prone condition with the head extended as much as possible, with the consequence that the frontal bone cannot be reached.

We plan to do periodic follow-ups of this patient. We must assess the patient's condition and whether there is an improvement in his quality of life. We also have to evaluate whether there are complications that occur, such as infection, hydrocephalus, or CSF leakage. Second-stage surgery is planned in the future to perform frontal bone reconstruction.

Conclusion

Severe macrocephaly can still be found in developing countries, especially due to neglected hydrocephalus cases. Subdural hygroma can also be a rare cause of severe macrocephaly in holoprosencephaly patients. Cranial vault reduction cranioplasty is the main treatment option, with the aim of reducing cranial volume and reducing the associated morbidities. In our case, the macrocephaly was caused by HPE and massive bilateral subdural hygroma. The operation we did was to evacuate subdural hygroma and to do total cranial vault reconstruction. Our procedure successfully reduces significant cranial volume (57.46% volume reduction).

Acknowledgements The authors would like to thank all the staff of the Department of Neurosurgery, Faculty of Medicine, Universitas Airlangga.

Author contribution Ahmad Data Dariansyah contributed to the conceptualization, data collection, writing, and editing of the study. Wihasto Suryaningtyas and Muhammad Arifin Parenrengi contributed to reviewing, editing, and finalizing the manuscript of the study.

Data availability All data generated or analyzed for this report are included in this published article.

Declarations

Consent to participate The authors certify that they have obtained all appropriate patient consent.

Conflict of interest There are no conflicts of interest.

References

- Accogli A, Geraldo AF, Piccolo G et al (2022) Diagnostic approach to macrocephaly in children. *Front Pediatr* 9:794069. Published 2022 Jan 14. <https://doi.org/10.3389/fped.2021.794069>
- Jones SG, Samanta D (2022) Macrocephaly. In: StatPearls [Internet]. Treasure Island (FL): StatPearls Publishing; 2023 Jan-. Available from: <https://www.ncbi.nlm.nih.gov/books/NBK560786/>
- Weiss K, Kruszka PS, Levey E, Muenke M (2018) Holoprosencephaly from conception to adulthood. *American journal of medical genetics. Part C. Seminars Med Genet* 178(2):122–127. <https://doi.org/10.1002/ajmg.c.31624>
- Raam MS, Solomon BD, Muenke M (2011) Holoprosencephaly: a guide to diagnosis and clinical management. *Indian Pediatr* 48(6):457–466. <https://doi.org/10.1007/s13312-011-0078-x>
- Dubourg C, Bendavid C, Pasquier L, Henry C, Odent S, David V (2007) Holoprosencephaly. *Orphanet J Rare Dis* 2:8. <https://doi.org/10.1186/1750-1172-2-8>
- Varma A, Mishra GV, Dhande R, Lakhkar BB (2022) Varied presentation of lobar holoprosencephaly as a cause of macrocephaly in a neonate. *BMJ Case Rep* 15(1):e248024. <https://doi.org/10.1136/bcr-2021-248024>
- Suryaningtyas W, Muhammad A (2020) Case report: cranial vault reduction cranioplasty for severe hydrocephalus. *Folia Medica Indonesiana* 56:154. <https://doi.org/10.20473/fmi.v56i2.21237>
- Abuzayed B, Alawneh K, Qawasmeh MAL, Raffee L (2019) Modified bilateral Pi craniectomy technique for reduction cranioplasty: novel technique. *J Craniofac Surg* 30(8):2593–2596. <https://doi.org/10.1097/SCS.0000000000005688>
- Iyer RR, Carey CM, Rottgers SA, Tetreault L, Shimony N, Katzenstein J, Ruas E, Tuite GF (2018) Early postnatal cranial vault reduction and fixation surgery for severe hydrocephalic macrocephaly. *J Neurosurg Pediatr* 21(5):486–495. <https://doi.org/10.3171/2017.11.PEDS17173>
- Gage EA, Price AV, Swift DM, Sacco DJ, Fearon JA (2011) Limited reduction cranioplasty for the treatment of hydrocephalic macrocephaly. *Plast Reconstr Surg* 128(6):1272–1280. <https://doi.org/10.1097/PRS.0b013e3182221404>
- Manwaring JC, Truong D, Deukmedjian AR, Carey CM, Storrs BB, Rodriguez LF, Tetreault L, Tuite GF (2013) Cranial reduction and fixation with a resorbable plate combined with cerebrospinal fluid shunting for difficult-to-manage macrocephaly related to hydrocephalus. *J Neurosurg Pediatr* 11(2):210–213. <https://doi.org/10.3171/2012.10.PEDS12340>
- Kohan E, Jackson E, Heller J, Lazareff J, Bradley JP (2010) Correction of hydrocephalic macrocephaly with total cranial vault remodeling and molding helmet therapy. *Plast Reconstr Surg* 125(6):1763–1770. <https://doi.org/10.1097/PRS.0b013e3181cc5a1b>
- Shen SH, Kwan AL, Wang BL, Guo JF, Tan GW, Chen SF, Liu XY, Liu F, Cai M, Wang ZX (2014) Reduction cranioplasty with the aid of simulated computer imaging for the treatment of hydrocephalic macrocephaly. *J Neurosurg Pediatr* 13(2):133–139. <https://doi.org/10.3171/2013.10.PEDS12573>
- Saleh E, Govshievich A, Justino J, Weil AG, Borsuk DE (2020) The Use of Virtual Surgical Planning for Reduction Cranioplasty. *Plast Reconstr Surg Glob Open* 8(1):e2565. <https://doi.org/10.1097/GOX.0000000000002565>. PMID: 32095391; PMCID: PMC7015603

13

Publisher's Note Springer Nature remains neutral with regard to jurisdictional claims in published maps and institutional affiliations.

Springer Nature or its licensor (e.g. a society or other partner) holds exclusive rights to this article under a publishing agreement with the author(s) or other rightsholder(s); author self-archiving of the accepted manuscript version of this article is solely governed by the terms of such publishing agreement and applicable law.

Cranial vault reduction cranioplasty for severe macrocephaly due to holoprosencephaly and subdural hygroma: a case report

ORIGINALITY REPORT

13%

SIMILARITY INDEX

11%

INTERNET SOURCES

13%

PUBLICATIONS

0%

STUDENT PAPERS

PRIMARY SOURCES

- 1 Gigih Aditya Wardana, Wihasto Suryaningtyas, Muhammad Arifin Parenrengi. "Surgical drain induced subgaleal hematomas and skin necrosis in pediatrics: a case report", *Child's Nervous System*, 2022
Publication 1%
- 2 www.thieme-connect.com
Internet Source 1%
- 3 Akmal Niam Firdausi Masyhudi, Muhammad Arifin Parenrengi, Wihasto Suryaningtyas. "Fatal complication caused by laxative suppository agent on pediatric patient with hydrocephalus on ventriculo-peritoneal shunt: a case report", *Child's Nervous System*, 2023
Publication 1%
- 4 Bashar Abuzayed, Khaled Alawneh, Majdi A.L. Qawasmeh, Liqaa Raffee. "Modified Bilateral Pi Craniectomy Technique for Reduction 1%

Cranioplasty", Journal of Craniofacial Surgery, 2019

Publication

5

Mirna Sobana, Danny Halim, Ahmad Faried, Betha Egih Riestiano et al. "Amniotic band syndrome with CNS involvement: a pediatric neurosurgeon's dilemma—a case series and literature review", Child's Nervous System, 2023

Publication

1 %

6

www.frontiersin.org

Internet Source

1 %

7

Ruihu Zhou, Haisheng Liu, Huifu Wang. "Modeling and simulation of metal selective laser melting process: a critical review", The International Journal of Advanced Manufacturing Technology, 2022

Publication

1 %

8

www.researchsquare.com

Internet Source

1 %

9

threedmedprint.biomedcentral.com

Internet Source

1 %

10

Surajit Gorai. " Few passes of CO laser to aid to remove foreign body under skin ", Cosmoderma, 2023

Publication

1 %

www.thepermanentejournal.org

11	Internet Source	1 %
12	www.ajol.info Internet Source	1 %
13	www.nature.com Internet Source	1 %
14	Ibukun John Ariyo, Deborah N. Mchaile, Marco Magwizi, Michael Kayuza, Phillip Mrindoko, Desderius Celestine Chussi. "Alobar holoprosencephaly with cebocephaly in a neonate: A rare case report from Northern Tanzania", International Journal of Surgery Case Reports, 2022 Publication	<1 %
15	Muhammad Arifin Parenrengi, IG. M. Aswin R. Ranuh, Wihasto Suryaningtyas. "Is ventricular lavage a novel treatment of neonatal posthemorrhagic hydrocephalus? a meta analysis", Child's Nervous System, 2023 Publication	<1 %

Exclude quotes Off
Exclude bibliography On

Exclude matches < 10 words