



Amniotic band syndrome with CNS involvement: a pediatric neurosurgeon's dilemma—a case series and literature review

Mirna Sobana¹ · Danny Halim^{1,2} · Ahmad Faried¹ · Betha Egih Riestiano³ · Hendra Fajar Pajan⁴ · Andi Asadul Islam⁴ · Ahmad Data Dariansyah⁵ · Muhammad Arifin Parenrengi⁵

Received: 15 April 2023 / Accepted: 22 May 2023

© The Author(s), under exclusive licence to Springer-Verlag GmbH Germany, part of Springer Nature 2023

Abstract

Background Amniotic band syndrome (ABS) is a rare congenital disease characterized by a broad spectrum of congenital anomalies resulting from the strangulated developing organ(s) by the detached fibrous amniotic band. The prevalence of CNS involvement in ABS is rare, but the mortality rate in these cases is high, while morbidity among the surviving patients is inevitable.

Case report Three-month-old male, 9-month-old female, and newborn female babies were presented with head lump(s), severe facial cleft, syndactyly, and finger amputation. The patient's head imaging confirmed meningoencephalocele as the cause of the head lump in 2 patients; meanwhile, a porencephalic cyst was identified as the origin of head lumps in the other patient. VP shunt placement surgery was performed as the initial management in 2 patients, while one patient directly underwent meningoencephalocele resection surgery. Craniofacial and limb reconstructions were planned as the follow-up management in all cases. Unfortunately, one patient died of complications from suspected aspiration, while another never returned for follow-up treatment.

Conclusion Here, we report 3 ABS cases with CNS involvement. Despite the severe disfigurement and disability, the inexistence of fatal malformation might lead to long-term survival. The treatment of malformation(s) that might predispose to another fatal condition and surgery(-ies) to improve functional outcomes and patient's social acceptability should be prioritized in managing the surviving ABS patients.

Keywords Amniotic band syndrome · Strangulated developing organ · Detached fibrous amniotic band · Head lump · Facial cleft · Syndactyly · Finger amputation

✉ Muhammad Arifin Parenrengi
muhammad.arifin@fk.unair.ac.id

Mirna Sobana
mirna.sobana@unpad.ac.id

Danny Halim
dannyhalim@gmail.com

Ahmad Faried
ahmad.faried@unpad.ac.id

Betha Egih Riestiano
bethariestiano@gmail.com

Hendra Fajar Pajan
hendra.pajan@hotmail.com

Andi Asadul Islam
undee@med.unhas.ac.id

Ahmad Data Dariansyah
ahmad.data.dariansyah@gmail.com

¹ Department of Neurosurgery, Faculty of Medicine, Universitas Padjadjaran - Dr. Hasan Sadikin General Hospital, Bandung, West Java, Indonesia

² Research Center for Medical Genetics, Faculty of Medicine, Universitas Padjadjaran, Bandung, West Java, Indonesia

³ Department of Plastic Surgery, Faculty of Medicine, Universitas Padjadjaran - Dr. Hasan Sadikin General Hospital, Bandung, West Java, Indonesia

⁴ Department of Neurosurgery, Faculty of Medicine, Universitas Hasanuddin - Dr. Wahidin Sudirohusodo General Hospital, Makassar, South Sulawesi, Indonesia

⁵ Department of Neurosurgery, Faculty of Medicine, Universitas Airlangga - Dr. Soetomo General Hospital, Surabaya, East Java, Indonesia

Introduction

Amniotic band syndrome (ABS) is a rare congenital disease where an abnormal detachment of fibrous amniotic band occurs and strangulates fetal's organ(s), causing cleft and amputation of the strangulated organ(s). The prevalence of this complex disease ranges from 1:1200 to 1:15,000 live births and 1:70 stillbirths [1]. Due to the randomness of the affected organ(s), ABS is characterized by a wide spectrum of congenital defects, most typically limb and finger amputation [2, 3]. The attachment of fibrous amniotic bands to CNS organ(s) would cause CNS involvement in ABS, often leading to fatal consequences. Depending on the severity of CNS involvement and other affected organ(s), morbidity in the surviving patients is inevitable [4, 5]. Due to the variety of combinations of congenital defects in ABS, standardized treatment for ABS has yet to be established. Thus, the description of the new ABS spectrum and its medical management are valuable in extending our understanding of this devastating condition and improving ABS patients' outcomes.

Exemplary case description

Case 1

A 3-month-old male baby presented with multiple congenital anomalies, including a large lump on the top of his forehead, facial malformations, finger amputation, and fusion. He was the third child of healthy non-consanguineous parents with no family history of congenital malformation. History of trauma, amniocentesis, misoprostol consumption, and any other incident that may cause vascular insults was denied; hence, the pregnancy was uneventful until he was suspected of encephalocele by ultrasound that was performed when his delivery was stalled. He was delivered by cesarean section at 38 weeks gestation. The parents noticed the presence of all anomalies since his birth. They acknowledged that the lump

grew larger over time, measuring 20×20×8 cm when presented. The transillumination result was positive, indicating that the lump was predominantly filled with cerebrospinal fluid. Facial malformation, including the absence of bilateral bulbi (anophthalmia) and nasal (arrhinia), cleft lip, and cleft palate (labiopalatoschizis) were detected (Fig. 1A, B). Moreover, the absence of a distal phalanx of the middle toe of his left foot and fusion of the toes of his right foot and fingers of both hands (Fig. 1C–F) were also acknowledged. Characteristic digital amputation due to constriction band was identified on all extremities.

Head computed tomography (CT) scan revealed extensive craniofacial malformation, partial agenesis of the frontal bone, and extracalvarial herniation of cerebral tissue into the proximal part of the encephalocele. Since the risk of rupture in a patient with giant encephalocele is high, he underwent ventriculoperitoneal (VP) shunt placement (Fig. 2A–C) prior to encephalocele resection surgery; thus, the size of the encephalocele was reduced to 12×10×5 cm. Then, he underwent a successful encephalocele resection surgery (Fig. 2D–F). Afterwards, he was planned to undergo a series of facial reconstruction surgeries to treat his cleft lip and palate, anophthalmia, and arrhinia, and syndactyly release surgery. Unfortunately, prior to these planned surgeries, the patient showed signs of aspiration pneumonia at home, including fever and respiratory distress. After 3 days, he succumbed to his illness when his parents were just about to take him to the nearest hospital.

Case 2

A 9-month-old female baby consulted with multiple congenital anomalies, including a lump on her left head, facial deformities, amputated left foot, amputated fingers and fusion, and a history of recurrent seizures. She was the first child of healthy non-consanguineous parents with no family history of congenital diseases. History of trauma, amniocentesis, consumption of drugs, and other events that might cause vascular insults during gestation was denied. During

Fig. 1 Physical examination revealed ABS characteristics in patient 1. **A** and **B** In addition to microcephaly, a giant frontal encephalocele is predominantly filled with CSF. Moreover, craniofacial cleft, anophthalmia, and arrhinia were also present. **C–F** Syndactyly and digital amputation due to constriction band was identified on patient's extremities

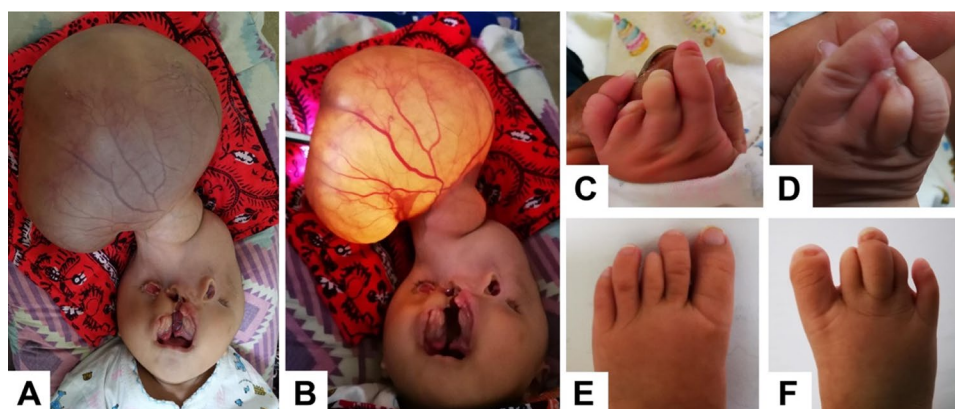
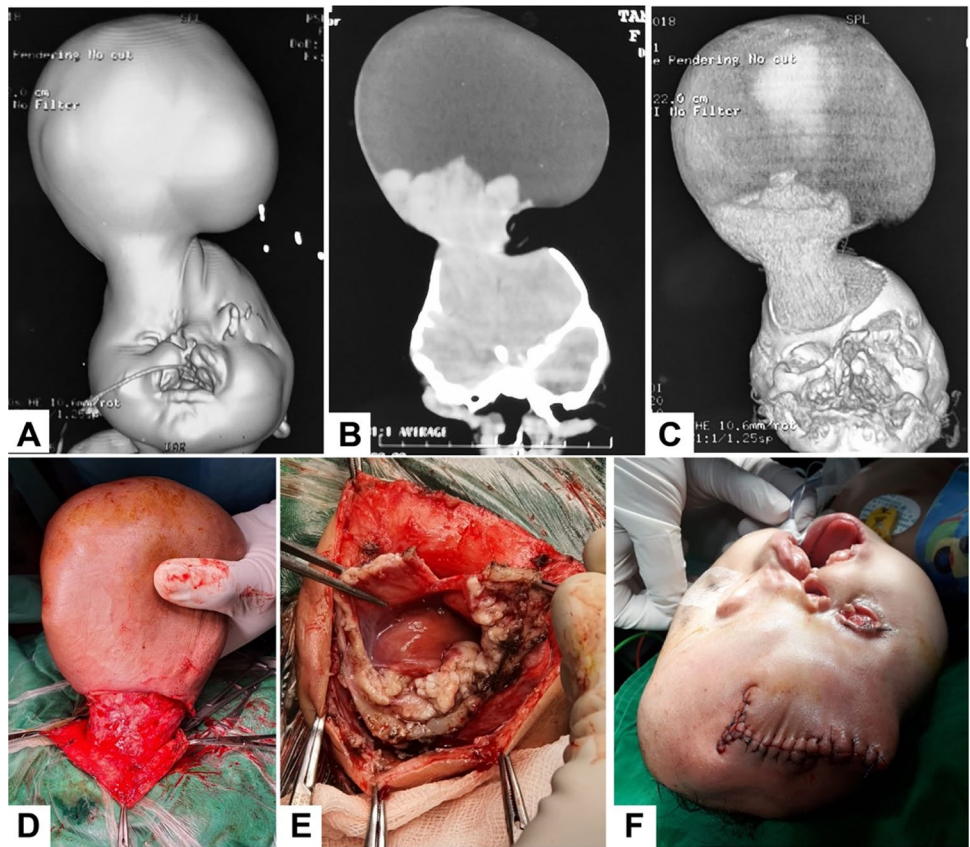


Fig. 2 Head imaging and treatment of patient 1. **A–C** Head 3D reconstruction confirmed that CSF predominated the content of encephalocele. However, infiltration of cerebral tissue also existed. **D–F** Thus, VP shunt placement followed by frontal encephalocele resection was performed on this patient



gestation, her mother had a routine antenatal check; hence, a lump on the patient's head was detected at 20 weeks gestation, then she was delivered by cesarean section at 39 weeks gestation. Her parents acknowledged the presence of all congenital anomalies since birth. The lump on her head grew to the size of 20 × 19 × 8 cm when she was presented. Other prominent defects were also detected, including bilateral anophthalmia, bilateral labiopalatoschizis (Fig. 3A),

syndactyly of both hands, digital amputations of fingers and toes from her right hand and right foot, and complete amputation of her left foot (Fig. 3B–E). Constriction bands were identified on the hands' syndactyly and proximal of the amputated left foot.

A head CT scan confirmed the diagnosis of meningoencephalocele, along with the partial absence of the bilateral frontal, temporal, and parietal bones. She underwent

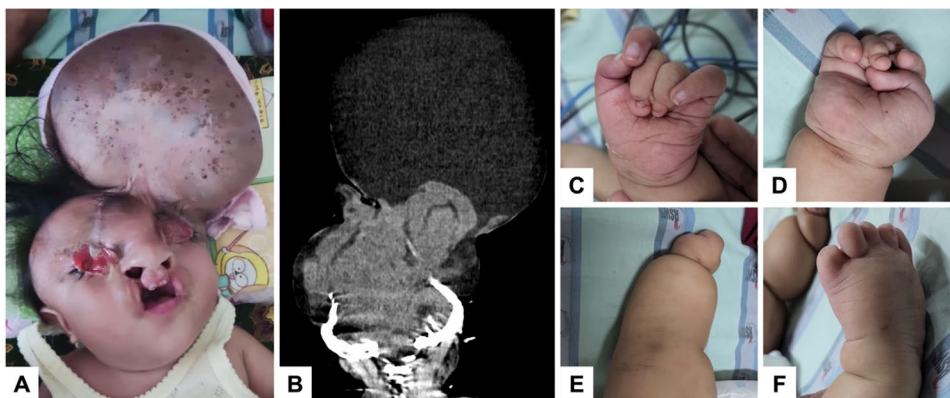


Fig. 3 Clinical and head CT scan images of patient 2. **A** Meningoencephalocele and severe craniofacial anomalies were presented, including bilateral anophthalmia and labiopalatoschizis. **B** Head CT scan identified meningoencephalocele and partial agenesis of frontal, temporal, and parietal bones leading to exencephaly. **C–F** Multiple defects in all extremities were identified, including syndactyly of both hands, amputation of multiple fingers of right hand and foot, and complete amputation of the left foot

tal, temporal, and parietal bones leading to exencephaly. **C–F** Multiple defects in all extremities were identified, including syndactyly of both hands, amputation of multiple fingers of right hand and foot, and complete amputation of the left foot

a successful meningoencephalocele resection surgery to eliminate the risk of rupture. The patient's post-surgical assessment was uneventful, and at the time of publication, she is scheduled to undergo labiopalatoschizis reconstruction surgery.

Case 3

A newborn female baby presented with multiple congenital anomalies, including multiple lumps on her head, facial defects, finger amputation, and fusion. She was the first child of non-consanguineous parents with no family history of congenital diseases. The gestation period went uneventful, with a history of trauma, amniocentesis, infection, drug consumption, and other events that might affect fetal vascularization all absent. Nevertheless, USG at 24 weeks' gestation detected the patient's head lump and other congenital anomalies; hence, she was delivered by cesarean section at 39 weeks gestation.

Physical examination identified three lumps on her head, including one lump on the frontal region with a size of $5 \times 4 \times 3$ cm, one lump on the parietooccipital region of $6 \times 5 \times 2.5$ cm in size, and another lump on the temporooccipital region sized $2 \times 2 \times 2$ cm. Transillumination results indicated the cystic nature of the lumps. Careful observation of the patient's facial defects acknowledged nasal cleft and labiopalatoschizis (Fig. 4A, B). The patient also had anomalies in all extremities, including syndactyly of both hands, constriction bands on multiple toes of both feet, and varus rotation of the left small toe (Fig. 4C–F). The patient's head MRI revealed porencephalic cysts as the cause of head lumps. Furthermore, it identified dysgenesis of bilateral

parietal bones, lobar holoprosencephaly, agenesis of the corpus callosum and septum pellucidum, and aqueduct stenosis. Malformation of the brain midline was also acknowledged (Fig. 5).

To treat the porencephalic cysts, she underwent VP shunt placement surgery. The post-surgical observation was uneventful; thus, she was discharged and planned to undergo a series of reconstruction surgeries to treat the defects of her craniofacial and extremities. Nonetheless, two months after the VP shunt placement surgery, the patient was readmitted and diagnosed with shunt malfunction. She underwent shunt repair surgery, and no surgical complication was identified afterward. Unfortunately, she never returned to the hospital for routine follow-up; thus, her current condition is unknown.

Discussion

Although the clinical description of this particular entity in a scientific publication could be found as early as 1946, it was not until 1971 that the term "amniotic-band syndrome" (ABS) was coined in a case series about a spectrum of deformities that were identified in infants who were born from a mother with a history of lysergic acid diethylamide (LSD) intake [6]. In brief, partial detachment of the amniotic layer from the chorion causes the free amniotic band to entangle and strangulate the developing organ(s) of the growing fetus, leading to the decrease of the vascular supply, thus causing atrophy, cleft, or amputation of the strangulated organ(s), such as nose, finger(s), and toe(s) [1, 2, 6]. As the loose amniotic band can randomly attach to any organ(s),

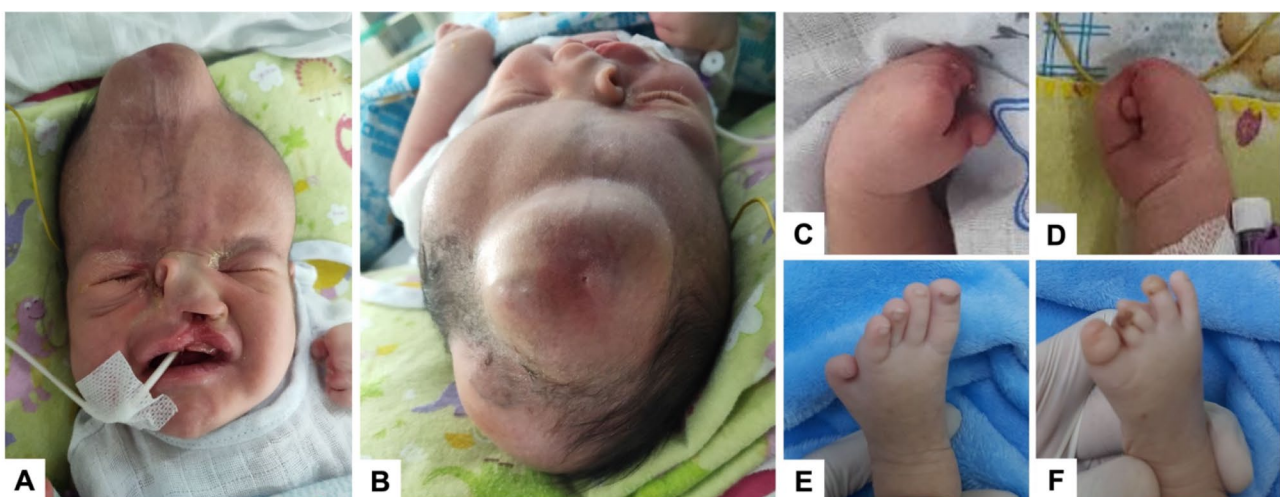

Fig. 4 Clinical presentation and head CT scan of patient 3 at 2 months old. **A, B** In addition to multiple lumps on her head, nasal cleft and labiopalatoschizis were recognized. **C–F** Observation of the

patient's extremities acknowledged syndactyly of both hands, constriction bands on multiple toes of her feet, and left small toe deformity

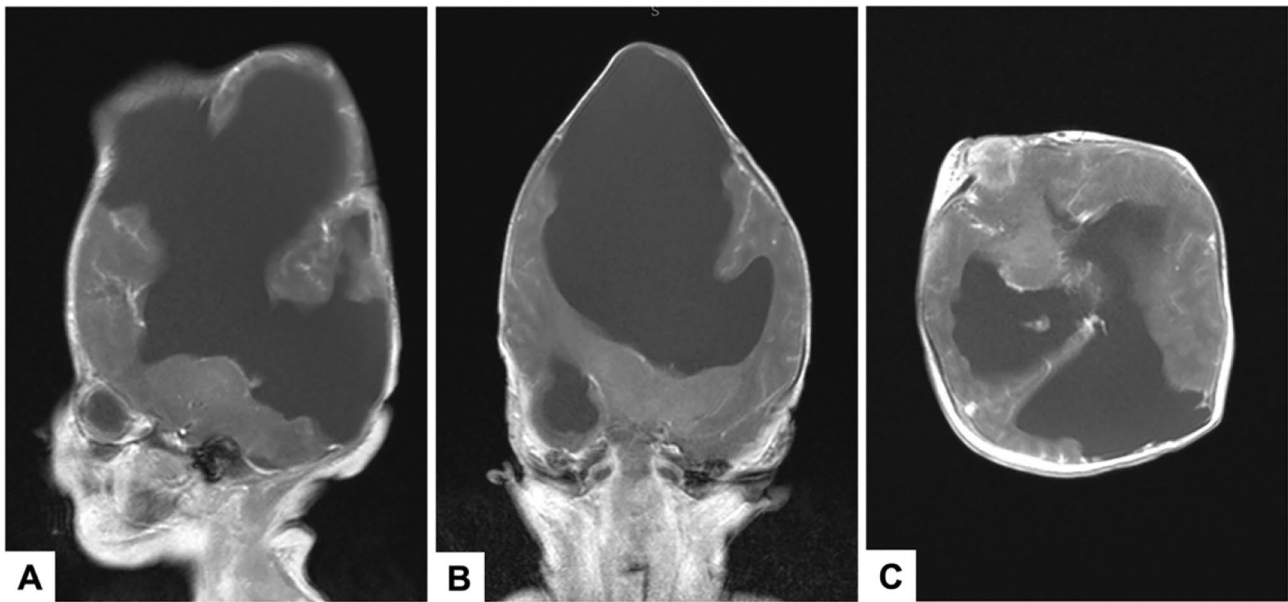


Fig. 5 Head MRI images from patient 3. **A–C** Multiple cranial and brain anomalies were identified, including dysgenesis of bilateral parietal bones, lobar holoprosencephaly, agenesis of the corpus callosum and septum pellucidum, aqueduct stenosis, and malformation of brain midline

ABS is arguably a generic name for a wide spectrum of congenital defects. In cases where ABS patients are presented with CNS anomalies, a neurosurgeon's familiarity with recognizing the clinical presentation of this syndrome would be pivotal to diagnosing and treating the patients accordingly.

Clinical presentation and diagnosis

ABS has a vast spectrum, depending on the part(s) of the fetal body where the band attaches to and strangulates [1]. Based on the published case reports, some findings are pathognomonic of ABS. These include finger(s) or toe(s) amputation, finger(s) or toe(s) fusion, and identification of constriction bands on the affected organ(s) [2]. In many cases, including ours, congenital defects can be detected by prenatal ultrasound [7–13]. Nevertheless, any findings from ultrasound examination will generate multiple differential diagnoses. Hence, ABS can only be diagnosed during the neonatal period or later.

In addition to the pathognomonic findings, many other clinical phenotypes of ABS have been reported, such as facial cleft, severe nasal deformity, cleft lip and/or palate, gastroschisis, omphalocele, clubbed feet, and abnormal dermal ridge pattern [14]. Several CNS anomalies had been identified in ABS patients, including encephalocele [15–17], meningoencephalocele [1, 18], absence of tentorium [7], acrania [8, 9, 11, 12, 15], meroacrania [1], acalvaria [19], anencephaly [9, 10], exencephaly [12, 20], holoprosencephaly [21], abnormal skull base [21],

constricted head and brain [13], periventricular nodular heterotopia [22], periventricular leukomalacia [21], dilatation of lateral ventricles [13], fused thalami [21], hypothalamic hamartoblastoma [21], agenesis of the corpus callosum [21], absent falx cerebri [21], aqueduct atresia [21], leptomenigeal heterotopia [21], cerebellar cortical dysplasia [21], shallow sella turcica [21], ectopic pituitary [21], pituitary hypoplasia [4], optic nerve hypoplasia [4], limited dorsal myeloschisis [5], and dysplasia of cervical laminae [5] (see Table 1).

In this study, all patients were presented with pathognomonic signs of ABS, including fusion and amputation of fingers and toes, and constriction bands on some affected limbs. Additionally, all patients in this study presented with severe nasal deformity and labiopalatoschizis. Interestingly, the underlying etiology of the head lump in patients 1 and 2 was meningoencephalocele, while the cause of head lumps in patient 3 was porencephalic cyst. Bilateral anophthalmia was detected in patients 1 and 2, but not in patient 3. A few different brain anomalies were specifically identified in patient 3, including dysgenesis of bilateral parietal bones, lobar holoprosencephaly, agenesis of the corpus callosum and septum pellucidum, and aqueduct stenosis. Interestingly, a head MRI from patient 3 suspected severe congenital cerebral midline malformation. To our knowledge, this abnormal feature has never been reported elsewhere. As this is the first report of this abnormality in an ABS patient, no theory could explain its pathogenesis. However, it is tempting to speculate that dysgenesis of bilateral parietal bones and porencephaly might have disrupted the cranial bones

Table 1 Summary of previously reported cases of amniotic band syndrome (ABS) patients with CNS involvement

Author, year of publication	Number of cases	Gender	Family history of ABS	Age and obstetrics status of the mother	History of trauma during pregnancy	Other significant histories	CNS involvement	Non-CNS defects	Treatment	Outcome
Aitken et al. (1984) [7]	1	Female	Not present	26-year-old, G1P0	Not present	Not present	Fusion of meninges and amnion, absence of tentorium	Labiopalatosischizis, right pulmonary aplasia, left pulmonary hypoplasia, absence of ductus arteriosus and pulmonary artery branches, digital amputation, and constrictions	Termination of pregnancy (22-week-old of gestation)	Neonatal death
Hughes and Benzie (1984) [8]	1	Female	Not present	30-year-old, G1P0	Not present	Not present	Acrania	Labiopalatosischizis, facial defect	Termination of pregnancy (20-week-old)	Neonatal death
Ito et al. (1986) [9]	1	Female	Not present	23-year-old, G1P0	Not present	Not present	Acrania, anencephaly	Adrenal hypoplasia, microphthalmia, arrhinia, labioschizis	Termination of pregnancy (32-week-old)	Neonatal death
Chen and Gonzalez (1987) [18]	4	Female	Not present	16-year-old, G1P0	Not mentioned	History of marijuana smoking, cocaine inhalation, amphetamine administration, and heroin injections during pregnancy	Meningoencephalocele, absent posterior fossa	Eye lid and nasal deformity, left microphthalmia, labioschizis, right lung hypoplasia, agenesis of the right upper limb, gastroschisis, irregular shape and size of the liver, and agenesis of the gallbladder	Not mentioned	Stillbirth

Table 1 (continued)

Author, year of publication	Number of cases	Gender	Family history of ABS	Age and obstetrics status of the mother	History of trauma during pregnancy	Other significant histories	CNS involvement	Non-CNS defects	Treatment	Outcome
		Female	Not mentioned	26-year-old, G3P2	Not mentioned	Vaginal bleeding for 3 weeks before delivery	Abnormal fetal head with a complex structure arising from the front of the head, irregular cranioschisis with a large and irregular meningoencephalocele containing remnants of central nervous tissue and meninges	Nasal cleft, labio-palatoschizis, abnormal shape and low set of ears, severe talipes equinovarus, amputation of the distal left great toe, and pseudosyndactyly of all left toes	Not mentioned	Stillbirth
		Male	Not present	31-year-old, G2P1	Not mentioned	Viral infections during the 2nd and 7th week of gestation	Irregular cranioschisis; meningoencephalocele	Bilateral anophthalmia, a large midline facial cleft extending from the mouth to the nasal bridge, absence of nose, palatoschizis, constriction rings on the left 3rd and 4th fingers with distal lymphedema, and amputation of the left 5th finger	Not mentioned	Low body temperature, increased intra-encephalocele pressure, minor motor seizures, and apnea episodes, then died at 1-year-old

Table 1 (continued)

Author, year of publication	Number of cases	Gender	Family history of ABS	Age and obstetrics status of the mother	History of trauma during pregnancy	Other significant histories	CNS involvement	Non-CNS defects	Treatment	Outcome
Chandran et al. (2000) [19]	1	Male	Not present	25-year-old, not mentioned	Not mentioned	The mother took contraceptives for 5 years, and just stopped taking them a month before prior to the conception. Fibroid tumor was identified in the uterine in the 3rd month of gestation; then, it was successfully resected	Irregular craniioschisis, meningoencephalocele	Facial cleft, absent of orbital bones and eyelids, rudimentary eyes, absent right maxilla	Not mentioned	Severely delayed neuromotor development, deficient head and trunk control, low body temperature, minor and major motor seizures, and apnea episodes, then died at 22-month-old
Chen et al. (2001) [10]	1	Male	Not present	Age not mentioned, G6P4	Not present	Not present	Acalvaria	Not present	Palliative care	Died at 6-h-old
Cincore et al. (2003) [11]	1	Male	Not present	21-year-old, G1P0	Not mentioned	Not present	Anencephaly	Microphthalmia of the left eye, facial cleft, nasal dysplasia	Termination of pregnancy (12-week-old)	Neonatal death
			Not mentioned	Age not mentioned, G1P0	Not present	History of anemia, illicit drug consumption, including marijuana, lysergic acid diethylamide, methamphetamine, as well as, tobacco use, and alcohol consumption	Acrania	Partial digit amputation	Termination of pregnancy (35-week-old)	Neonatal death

Table 1 (continued)

Author, year of publication	Number of cases	Gender	Family history of ABS	Age and obstetrics status of the mother	History of trauma during pregnancy	Other significant histories	CNS involvement	Non-CNS defects	Treatment	Outcome
Chen et al. (2004) [12]	2	Male	Not present	27-year-old, G1P0	Not present	Not present	Acrania, exencephaly	Deformity of the nose, an aberrant skin band over the face, constrictive amniotic bands over the fingers, and pseudosyndactyly of both hands and feet	Termination of pregnancy (21-week-old of gestation)	Neonatal death
		Female	Not present	32-year-old, G2P1	Not present	Not present	Acrania, exencephaly	Hypertelorism, midfacial cleft, pseudosyndactyly on the right hand and both feet, constrictive amniotic bands over the fingers and toes, and partial absence of the digits of the right hand	Termination of pregnancy (16-week-old of gestation)	Neonatal death
Ruggieri et al. (2007) [22]	1	Female	Not present	Not mentioned	Not present	Abruptio placenta and fetal distress detected at 38-week-old of gestation	Bilateral periventricular nodular heterotopia	Near-total missing of proximal and distal phalanxes of all digits in the feet, with hypoplastic metatarsal and no other bone anomaly	Termination of pregnancy by Caesarean Sect. (38-week-old of gestation)	Alive (9-year-old at time of publication) with profound mental retardation, episodic seizure, absent gag reflex, mildly decreased muscle tone

Table 1 (continued)

Author, year of publication	Number of cases	Gender	Family history of ABS	Age and obstetrics status of the mother	History of trauma during pregnancy	Other significant histories	CNS involvement	Non-CNS defects	Treatment	Outcome
Purandare et al. (2008) [21]	3	Female	Not present	30-year-old, G7P5	Not present	Not present	Encephalocele, agenesis of the corpus callosum, and fused thalami	Hypertelorism, Tessier 4–5 facial cleft, bilateral microphthalmia, and microcornea, rudimentary nose, talipes equinovarus, and skin appendages/hamartomas near the right eye and over the right forearm	Emergency Caesarean Sect. (39-week-old of gestation)	Died at 4-day-old
		Male	Not mentioned	22-year-old, G7P3	Present (Developmental delay in 2 siblings, and 1 sibling has brain hamartoma)	Chlamydia infection, smoking, alcohol and marijuana use	Encephalocele, periventricular leukomalacia, agenesis of the corpus callosum, aqueductal atresia, cerebral and cerebellar leptomeningeal heterotopia, and focal cerebellar cortical dysplasia	Facial cleft, arrhinia, labiopalatoschizis, amputation of the left upper extremity at the level of the distal humerus, circumferential constriction of the ankle with two cutaneous polyyps/hamartomas over dorsal aspect of the right foot, hypoplasia of the metatarsal and absence of one distal phalanx of the right second toe and absent distal phalanges of the left fifth toe, bilateral talipes equinovarus	Termination of pregnancy (35-week-old of gestation)	Died in several hours after delivery

Table 1 (continued)

Author, year of publication	Number of cases	Gender	Family history of ABS	Age and obstetrics status of the mother	History of trauma during pregnancy	Other significant histories	CNS involvement	Non-CNS defects	Treatment	Outcome
		Female	Not mentioned	20-year-old, G1P0	Not present	Not present	Holoprosencephaly, hypothalamic hamartoblastoma, absent falx cerebri, abnormal skull base, shallow sella turcica, and ectopic pituitary present in the nasopharyngeal submucosa	Omphalocele, facial cleft, arhinia, anophthalmia, microphthalmia, syndactyly, immature ovaries with the persistence of the primordial sex cords, focal oncotic changes in the follicular epithelium of the thyroid, cutaneous pit between the right ear and eye, bilateral hydronephrosis and scoliosis with convexity to the right	Termination of pregnancy (36-week-old of gestation)	Died in 1 h after delivery
Lee et al. (2011) [13]	1	Not mentioned	Not present	26-year-old, G1P0	Not present	Not present	Constricted head and brain, dilatation of bilateral lateral ventricles	Not present	Emergency caesarean Sect. (28-week-old of gestation)	Alive at the time of publication, sent to neonatal intensive care unit due to prematurity

Table 1 (continued)

Author, year of publication	Number of cases	Gender	Family history of ABS	Age and obstetrics status of the mother	History of trauma during pregnancy	Other significant histories	CNS involvement	Non-CNS defects	Treatment	Outcome
Barros et al. (2014) [1]	2	Not mentioned	Not mentioned	32-year-old, not mentioned	Not mentioned	This pregnancy was a result of Assisted Reproductive Technology (ART)	Meroacrania	Severe facial dysmorphism and fingers amputations	Termination of pregnancy (13-week-old of gestation)	Neonatal death
Li et al. (2017) [15]	2	Male	Not present	23-year-old, not mentioned	Not mentioned	Not present	Encephalocele, cranial cleft	Facial cleft, amputations of hand, wrist, and small segment of distal forearm	Termination of pregnancy (15-week-old of gestation)	Neonatal death
		Male	Not present	22-year-old, GIP0	Present	Not present	Acrania	Digital amputation on left hand, absent of right forefoot	Termination of pregnancy (16-week-old of gestation)	Intrauterine fetal death
		Not mentioned	Not mentioned	Not mentioned	Not mentioned	Not present	Encephalocele	Craniofacial cleft, amputation of the hand, wrist, and small segment of the distal forearm	Termination of pregnancy (15-week-old of gestation)	Neonatal death
Amiji et al. (2019) [4]	1	Male	Not mentioned	Age not mentioned, GIP0	Not present	Not present	Optic nerve hypoplasia, midline brain abnormalities (agenesis of corpus callosum or absence of septum pellucidum), and pituitary hypoplasia with consequent hypopituitarism	Absence of all five digits in the right hand with a constricting band in the right wrist joint, constricting band on the left arm, presence of low-set ears, and bilateral talipes equinovarus	Constricting amniotic band release repair of both upper limbs, corrective repair of the right hand, repeat hormone profile at the age of 6 months	Alive at time of publication (age not mentioned)

Table 1 (continued)

Author, year of publication	Number of cases	Gender	Family history of ABS	Age and obstetrics status of the mother	History of trauma during pregnancy	Other significant histories	CNS involvement	Non-CNS defects	Treatment	Outcome
da Silva (2019) [20]	1	Female	Not mentioned	35-year-old, G1P0	Not mentioned	Consanguineous marriage	Exencephaly with partial absence of the cranial bones, including frontal, left temporal, and left parietal bones	Bilateral proptosis, facial cleft, bilateral labio-palatoshizis, nasal deformity, syndactyly, digital amputation, congenital clubfoot	Palliative care	Died at 5-month-old
Yengo-Kahn et al. (2020) [16]	1	Female	Not mentioned	Not mentioned	Not mentioned	Not present	Encephalocele	Bilateral palatoschizis	Cells resection, VP Shunt	Alive at time of publication (2-month-old)
Chatterjee et al. (2021) [5]	1	Male	Not mentioned	Age not mentioned, G1P0	Not mentioned	Severe respiratory infection at the second trimester related to severe bouts and coughing	Limited dorsal myeloschisis, and dysplasia of cervical laminae at vertebrae C3-C7	Partial agenesis of manubrium sternum, large constriction band-like structure that encircled the neck, deformity of shoulder girdle, malformation of acromioclavicular joint, presence of free-floating clavicle	Exploration of the LDM and untethering of the cervical cord	Alive at time of publication (2.5-year-old)
Yazawa et al. (2021) [17]	1	Male	None	24-year-old, G1P0	None	None	Occipital encephalocele	None	Cells resection	Alive at time of publication (2-month-old)

and cerebral ventricles' integrities, thus affecting cerebral midline formation.

Management

As the affected organs may vary, the management of ABS patients should be tailored as patient specific. When ABS is suspected during prenatal ultrasound examination, termination of pregnancy has been reported as the treatment of choice in many cases [1, 7–12, 15, 19]. Meanwhile, when ABS is diagnosed during the neonatal period or later, it might be considerate to perform an initial evaluation of the survival prognosis of the ABS patients. For example, palliative management might be considered if a uniformly fatal condition, such as acrania, is identified [8, 9, 11, 12, 15]. However, if the ABS patient is presented without fatal anomalies, the caring physician must set the order of treatment priorities. As ABS patients are always presented with limb anomalies, limb reconstruction surgery, such as syndactyly release surgery, might always be included as one of the therapeutic components. Nevertheless, in ABS patients presenting with brain anomalies, limb reconstruction surgery might be less prioritized than surgical treatment for brain abnormalities. Like the principles of treatment for any other diseases, treatment of any abnormalities that have the potential to become fatal must be prioritized. In our cases, management of head lump(s), including VP shunt and meningoencephalocele resection surgery, is the initial treatment of choice. Craniofacial and limb reconstruction surgeries can be suggested as the next treatment phase. Nonsurgical treatment, such as antiseizure medication, might be given when necessary.

Prognosis and outcomes

In many cases, ABS patients who also acquired CNS abnormalities died in their early period of life. On the other hand, lifelong morbidity is inevitable in those who survived longer, depending on the severity of the identified phenotypes. Based on the reviewed ABS cases with CNS involvement in Table 1, the mortality rate of this clinical entity is as high as 76% (19/25). Of these 19 patients, 12 died of intrauterine fetal death, stillbirth, or neonatal death, while three died less than 24 h after their deliveries. Based on the reported anomalies, the CNS involvement in ABS patients who survived longer was arguably less severe.

Nevertheless, the association of the severity of CNS involvement with functional outcomes in ABS patients remains speculative, as no studies ever reported ABS patient evaluation in their adulthood. This could mean that there are no ABS patients with CNS anomalies that reach adulthood,

or there are no studies that have ever evaluated it. Future studies that evaluate the surviving ABS patients with CNS anomalies in their later period of life are critical to unravel the long-term prognosis of these patients.

In this study, although all patients presented with debilitating and disfiguring anomalies, none were fatal; hence, they were expected to survive longer. Unfortunately, as patients with cleft palate are subjected to a high risk of aspiration, patient 1 was suspected of developing respiratory distress and pneumonia due to aspiration; then, he succumbed to his illness. This suggests that prognoses of ABS patients with CNS anomalies are not always the direct consequences of the malformation.

Conclusion

In cases where constricting amniotic bands cause severe malformation/disfigurement but are nonfatal, several conditions should be prioritized when planning the comprehensive management of ABS patients. First, treatment should be directed to treat malformation(s) that can become risk factor(s) for other debilitating conditions. Secondly, treatment should be directed to improve long-term functional outcomes. Lastly, since severe disfigurement is an essential issue in a patient's long-term survival, facial reconstruction surgery might be considered an effort to make the patient as "acceptable" as possible in society.

Author contribution MS, DH, AF, BER, HFP, AAI, ADD, and MAP treated the patient; MS, DH, AF, HFP, ADD, and MAP wrote the main manuscript and prepared the figures and table; MS, DH, AF, BER, HFP, AAI, ADD, and MAP reviewed the manuscript.

Data availability The data presented in this study are not openly available due to the potential to compromise patient's privacy, but they are available from the corresponding author upon reasonable request.

Declarations

Consent to participate Appropriate consent forms for the publication of this case study were obtained from the patient's family. The patient and his family understood that the patient's name and initial would not be published and that due efforts would be made to conceal their identity, but anonymity cannot be guaranteed.

Conflict of interest The authors declare no competing interests.

References

- Barros M, Gorgal G, Machado AP, Ramalho C, Matias A, Montenegro N (2014) Revisiting amniotic band sequence: a wide spectrum of manifestations. *Fetal Diagn Ther* 35(1):51–56. <https://doi.org/10.1159/000354616>. (Epub 2013 Nov 14 PMID: 24247024)

2. Singh AP, Gorla SR (2022) Amniotic Band Syndrome. In: StatPearls [Internet]. Treasure Island (FL): StatPearls Publishing; 2023 Jan. (PMID: 31424867)
3. Iqbal CW, Derderian SC, Cheng Y, Lee H, Hirose S (2015) Amniotic band syndrome: a single-institutional experience. *Fetal Diagn Ther* 37(1):1–5. <https://doi.org/10.1159/000358301>. (Epub 2014 Dec 16 PMID: 25531236)
4. Amiji IA, Mohamed UH, Rutashobya AG, Mngoya M, Schoenmann N, Naburi HE, Manji KP (2019) Septo-optic dysplasia with amniotic band syndrome sequence: a case report. *J Med Case Rep* 13(1):370. <https://doi.org/10.1186/s13256-019-2306-2>. PMID:31839004; PMCID:PMC6913001
5. Chatterjee S, Rao KSM, Nadkarni A (2021) Amniotic band syndrome associated with limited dorsal myeloschisis: a case report of an unusual case and review of the literature. *Childs Nerv Syst* 37(2):707–713. <https://doi.org/10.1007/s00381-020-04713-4>. (Epub 2020 Jun 9 PMID: 32519131)
6. Blanc WA, Mattison DR, Kane R, Chauthan P (1971) L.S.D., intrauterine amputations, and amniotic-band syndrome. *Lancet* 2(7716):158–9. [https://doi.org/10.1016/s0140-6736\(71\)92326-9](https://doi.org/10.1016/s0140-6736(71)92326-9). (PMID: 4104480)
7. Aitken DA, May HM, Ferguson-Smith MA, Howat R, Kohler HG (1984) Amniotic band disruption syndrome associated with elevated amniotic AFP and normal acetylcholinesterase gel test. *Prenat Diagn* 4(6):443–6. <https://doi.org/10.1002/pd.1970040608>. (PMID: 6084243)
8. Hughes RM, Benzie RJ, Thompson CL (1984) Amniotic band syndrome causing fetal head deformity. *Prenat Diagn* 4(6):447–50. <https://doi.org/10.1002/pd.1970040609>. (PMID: 6395127)
9. Ito M, Onitsuka Y, Matsui K, Fujisaki S, Maeyama M (1986) Craniofacial defects associated with amniotic band syndrome: a case report. *Int J Gynaecol Obstet* 24(1):43–45. [https://doi.org/10.1016/0020-7292\(86\)90022-6](https://doi.org/10.1016/0020-7292(86)90022-6). (PMID: 2874069)
10. Chen CP (2001) First-trimester sonographic demonstration of a mobile cranial cyst associated with anencephaly and amniotic band sequence. *Ultrasound Obstet Gynecol* 17(4):360–361. <https://doi.org/10.1046/j.1469-0705.2001.00389.x>. (PMID: 11339199)
11. Cincore V, Ninios AP, Pavlik J, Hsu CD (2003) Prenatal diagnosis of acrania associated with amniotic band syndrome. *Obstet Gynecol* 102(5 Pt 2):1176–1178. [https://doi.org/10.1016/s0029-7844\(03\)00118-2](https://doi.org/10.1016/s0029-7844(03)00118-2). (PMID: 14607048)
12. Chen CP, Chang TY, Lin YH, Wang W (2004) Prenatal sonographic diagnosis of acrania associated with amniotic bands. *J Clin Ultrasound* 32(5):256–260. <https://doi.org/10.1002/jcu.20021>. (PMID: 15124194)
13. Lee SH, Lee MJ, Kim MJ, Son GH, Namgung R (2011) Fetal MR imaging of constriction band syndrome involving the skull and brain. *J Comput Assist Tomogr* 35(6):685–7. <https://doi.org/10.1097/RCT.0b013e31823489ae>. (PMID: 22082536)
14. Seeds JW, Cefalo RC, Herbert WN (1982) Amniotic band syndrome. *Am J Obstet Gynecol* 144(3):243–248. [https://doi.org/10.1016/0002-9378\(82\)90574-9](https://doi.org/10.1016/0002-9378(82)90574-9). (PMID: 7124837)
15. Li L, Cerda S, Kindelberger D, Yang J, Sarita-Reyes C (2017) Isolated acrania in the presence of amniotic band syndrome. *N Am J Med Sci* 10(3):100–103
16. Yengo-Kahn AM, Plackis AC, Bonfield CM, Reddy SK (2020) Correction of a vertex encephalocele related to amniotic band syndrome. *BMJ Case Rep* 13(3)
17. Yazawa O, Hirokawa D, Okamoto K, Tanaka M, Shibasaki J, Sato H (2022) A new phenotype of amniotic band syndrome with occipital encephalocele-like morphology: a case report. *Childs Nerv Syst* 38(7):1405–1408. <https://doi.org/10.1007/s00381-021-05406-2>. (Epub 2021 Nov 5 PMID: 34739550)
18. Chen H, Gonzalez E (1987) Amniotic band sequence and its neurocutaneous manifestations. *Am J Med Genet* 28(3):661–673. <https://doi.org/10.1002/ajmg.1320280314>. (PMID: 3425634)
19. Chandran S, Lim MK, Yu VY (2000) Fetal acalvaria with amniotic band syndrome. *Arch Dis Child Fetal Neonatal Ed* 82(1):F11–F13. <https://doi.org/10.1136/fn.82.1.f11>. PMID:10634833; PMCID:PMC1721025
20. da Silva AJF (2019) Amniotic band syndrome associated with exencephaly: a case report and literature review. *J Pediatr Neurosci* 14(2):94–96. https://doi.org/10.4103/jpn.JPN_130_18. (PMID: 31516628; PMCID: PMC6712913)
21. Purandare SM, Ernst L, Medne L, Huff D, Zackai EH (2009) Developmental anomalies with features of disorganization (Ds) and amniotic band sequence (ABS): a report of four cases. *Am J Med Genet A* 149A(8):1740–1748. <https://doi.org/10.1002/ajmg.a.32716>. (PMID: 19606475)
22. Ruggieri M, Spalice A, Polizzi A, Ruggini M, Iannetti P (2007) Bilateral periventricular nodular heterotopia with amniotic band syndrome. *Pediatr Neurol* 36(6):407–410. <https://doi.org/10.1016/j.pediatrneurol.2007.02.006>. (PMID: 17560504)

Publisher's Note Springer Nature remains neutral with regard to jurisdictional claims in published maps and institutional affiliations.

Springer Nature or its licensor (e.g. a society or other partner) holds exclusive rights to this article under a publishing agreement with the author(s) or other rightsholder(s); author self-archiving of the accepted manuscript version of this article is solely governed by the terms of such publishing agreement and applicable law.