

Comparison Of Fusion Outcomes Of Bone Morphogenetics Proteins-7 And Bone Autograft In Posterolateral Lumbar Fusion: A Systematic Review

by Budi Utomo

Submission date: 07-Aug-2023 02:48PM (UTC+0800)

Submission ID: 2142531266

File name: Artikel_Tambahan_8.pdf (662.26K)

Word count: 7838

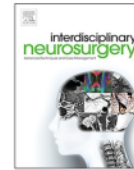
Character count: 42397



ELSEVIER

Contents lists available at ScienceDirect

Interdisciplinary Neurosurgery: Advanced Techniques and Case Management

journal homepage: www.elsevier.com/locate/inat

Review Article

Comparison of fusion outcomes of bone morphogenetics proteins-7 and bone autograft in posterolateral lumbar fusion: A systematic review

Eko Agus Subagio^{a,*}, Mustaqim Apriyansa Rahmadhan^{b,5}, Muhammad Faris^{b,1},
Rahardian Indarto Susilo^{b,2}, Nur Setiawan Suroto^{b,3}, Budi Utomo^{c,4}, Pandu Wicaksono^b,
Abdul Hafid Bajamal^b

^a Neurospine Division Neurosurgery Department, Faculty of Medicine Airlangga University/Dr. Seotomo General Teaching Hospital, Indonesia

^b Neurosurgery Department, Faculty of Medicine Airlangga University/Dr. Seotomo General Teaching Hospital, Indonesia

^c Public Health Department, Faculty of Medicine Airlangga University, Indonesia

ARTICLE INFO

Keywords:

Posterolateral fusion

BMP-7

Autograft

ABSTRACT

The aim of the study is to evaluate the parameter of fusion success of Bone Morphogenetic Protein-7 (BMP-7 or osteogenic protein-1) versus autograft (autogenous iliac crest bone graft (ICBG) or cancellous bone) in posterolateral fusion (PLF) of the spine. A systematic search of all articles published through January 1, 2000 to January 2022 was conducted in databases such as PubMed, Cochrane Collaboration Library, and Cross Reference. Randomized controlled trials (RCTs) that compared BMP-7 with autograft for the treatment of degenerative spondylolisthesis, provided the clinical success rate and fusion rate were assessed using Medical Subject Headings terms "bone morphogenetic protein," and "spinal fusion." Two independent investigators screened eligible studies, assessed the bias of original articles, extracted data including radiological fusion success, Oswestry disability index improvement. Inclusion criteria were randomized controlled trial studies published in Indonesian or English. Initial selection yielded 246 studies, and 8 studies were selected for the systematic review. Posterolateral fusion had been used as therapy for spondylolisthesis and symptomatic canal stenosis. Based on the systematic review to date, there are several studies that provide complete information of fusion success. There is no significant difference between BMP-7 and autograft. There are several factors that affects successful radiological fusion success and Oswestry Disability Index such as composite carrier, instruments use, decompression factor, and the definition for radiological fusion success. Further research is needed to compare the benefit of BMP-7 as effective substitute for autograft.

1. Introduction

Low back pain continues to be one of the most common symptoms in spine. Procedure to treat the underlying disease is discussed continuously regarding its efficiency and efficacy. In patients with refractory pain, surgery is a good alternative for patient with no improvement after 6 months of conservative therapy [1].

One surgical approach to address this problem is spinal fusion. There are several techniques to achieve fusion, in degenerative cases and cases of decreased spinal quality due to osteoporosis posterolateral fusion (PLF) is preferred. PLF technique has shorter operating time and an easier technique. The main target of the PLF is the occurrence of post-decompression fusion in the affected structure. On the other hand, this technique also has a risk of fusion failure of around 5 % to 40 %. Many

* Corresponding author at: Jl. Karimata No 14, Surabaya, East Java, Indonesia.

E-mail addresses: eko.agus@fk.unair.ac.id (E. Agus Subagio), mustaqim90@gmail.com (M. Apriyansa Rahmadhan), mfarisns@fk.unair.ac.id (M. Faris), rahadian-i-s@fk.unair.ac.id (R. Indarto Susilo), setiawan.dr@gmail.com, nur.setiawan.suroto-2016@fk.unair.ac.id (N. Setiawan Suroto), budiutom@gmail.com (B. Utomo), drduwns@gmail.com (P. Wicaksono), hfbajamal@gmail.com (A. Hafid Bajamal).

¹ Teluk Weda 5-A RT I RW 4 Perak Utara Surabaya, East Java, Indonesia.

² Jl. Bendul Merisi Selatan 47 Surabaya, East Java, Indonesia.

³ Griya Babatan Mukti XIII/ 19 blok L- 15 RT 3/ RW 7 Babatan - Wiyung, Surabaya, East Java, Indonesia.

⁴ Jl. Manyar Sabrangan 47 Surabaya, East Java, Indonesia.

⁵ Jl. Ploso Timur I No 60, Surabaya, East Java, Indonesia.

<https://doi.org/10.1016/j.inat.2023.101765>

Received 1 February 2023; Accepted 26 March 2023

Available online 31 March 2023

2214-7519/© 2023 The Authors. Published by Elsevier B.V. This is an open access article under the CC BY-NC-ND license (<http://creativecommons.org/licenses/by-nc-nd/4.0/>).

factors influence the success of fusion, one of which is the choice of bone graft [2] (see Table 1).

Autograft in the form of autologous iliac bone graft (ICBG) is the main choice for spinal fusion. However, there are some risks in using this graft, such as increased occurrence of nonunion, complications on the donor side, and the use of grafts in multi-segment fusion is difficult to do. In a systematic review by Liu et al., it was shown that 1- or 2-level fusion using local bone alone could still produce an acceptable fusion rate. Whereas 3 levels of fusion using local bone show a very low fusion rate of 62.5 % [3].

Urist in 1965 introduced a protein from the bone matrix that could induce formation of ectopic bone, known as bone morphogenetic protein (BMP). There are two BMPs that are currently used commercially: BMP-2 and BMP-7/ Osteogenic Protein-1 (OP-1 Putty). BMPs are purified from demineralized bone matrix due to their ability to induce new bone in vivo and they represent members of the TGF-β protein superfamily as well as having effects at the cellular level [4].

Until now, in spinal surgery, BMP-2 has been used commercially with FDA (Food Drug Administration) approval since 2001, in procedures such as ALIF (anterior lumbar interbody fusion) surgery and BMP-7 is used in nonunion long bone fractures. Other than that, it's usage is still off-label because it is believed that BMP-2 still has the potential for soft tissue swelling which could be a fatal complication[5].

In this review, the authors aim to provide different perspectives on the function and effectiveness of the BMP-7. The existing systematic review in 2020 by Liu et al described many BMPs in terms of effectiveness and safety. This study by Liu et al., has not specifically discussed the advantages of BMP-7 as a potential osteoinductive in PLF. Liu et al., stated in conclusion that there is no significant benefit in BMP-7. This systematic review also adds more details to Liu et al. findings[3].

There is another systematic review study by Ye et. al 2016 and has described well the use of BMP-7, but an update of perspective is needed in some literature that has not been included in research [6]. This systematic review adds more perspective in Ye et al. findings, including several factors that affect the outcome of the procedure such as composite carrier, instruments use, decompression factor, and the definition for radiological fusion success. With the development of technology towards minimal invasiveness, but with the same target of fusion quality, more in-depth studies with the latest perspectives are needed regarding the most effective and efficient materials.

2. Materials and methods

This is a systematic review and was conducted based on results of a literature search from the publication database based on the Preferred Reporting Items for Systematic Reviews and Meta-Analysis (PRISMA) flow.

Table 1
Characteristic of the study included in systematic review.

Study	Total sample		Gender		Mean age (years)		Follow up time
	OP-1	Autograft	OP-1	Autograft	Op-1	Autograft	
Johnson et al., 2002	10	10	P: 7 L: 3	P: 5 L: 5	42	41	12 months
Vaccaro et al., 2004	24	12	P: 13 L: 11	P: 7 L: 5	63	66	12 months
Vaccaro et al., 2005	24	12	P: 13 L: 11	P: 7 L: 5	63	66	24–36 months
Kanayama et al., 2006	9	10	P: 4 L: 5	P: 4 L: 6	70,3	58,7	3 – 12 months
Vacarro et al., 2008	24	12	P: 13 L: 11	P: 7 L: 5	63	66	48 months
Delawi et al., 2010	60	59	P: 33 L: 27	P: 34 L: 25	54	55	12 months
Agabegi et al., 2011	208	87	Not mentioned		69	69	24 months
Delawi et al., 2016	18	16	P: 8 L: 10	P: 10 L: 6	53	55	12 months

2.1. Search strategy

The search was conducted from October 2022 in the following databases: (1) Pubmed, (2) Cochrane Library, (3) Cross Reference. This was no limit in publication date. The keywords used for individual search strategy were: *spinal fusion surgery, bone morphogenetic protein-7, osteogenic protein-1, recombinant bone morphogenetic protein-7, BMP-7, OP-1, rhBMP-7, autograft, bone chip, bone graft, iliac crest graft, ICBG, fusion success*. These words were also searched in combined form, as described: *Spinal fusion surgery AND Recombinant bone morphogenetic protein-7 OR bone morphogenetic protein-7 OR BMP-7 OR rhBMP-7 OR osteogenic protein-1 OR OP-1 AND Autograft OR Bone chip OR Bone graft OR Iliac crest graft OR ICBG AND Fusion Success*.

2.2. Eligibility criteria

The inclusion criteria for this study were: (1) a clinical trial studies with randomized controlled trial design, and prospective cohort or retrospective cohort; (2) study using spinal fusion patient who underwent posterolateral fusion; (3) study that used BMP-7 as intervention group and autograft as control group, there should be no different in surgical approach; (4) study that used Oswestry disability index (ODI) as fusion outcome; (5) study assessed the outcome of fusion or fusion success using radiological studies, either using conventional static and dynamic plain photos or using a CT scan.

2.3. Data extraction

For the data extraction, one researcher (MAR) extract all identified references. There references were added to Mendeley Software. The extracted data were title of the study, author, total sample, gender of the subjects, mean of age of the subject, follow up times, type of study, pre operative condition of the subject, surgical approach, dosage and carrier of OP-1, fusion criteria, and outcomes.

2.4. Evaluation of the methodological quality of the articles

Assessment of quality of study and risk of bias was conducted using ROBINS.

3. Results

A literature search was performed on the PubMed (342), Cochrane (105), and Cross Reference (20) journal databases. After duplication screening, a total of 246 literatures were obtained. Titles and abstracts were filtered, 10 literatures were obtained. Overall text screening resulted in 8 literatures that met the criteria. All of this literature was

then used to conduct a systematic review using qualitative data. The research literature search flowchart can be seen in Fig. 1.

This systematic review took data from various literature with various study designs. The study design with the highest level of evidence was the RCT, followed by cohort, case control, and case series studies. In this systematic review, 8 studies were found, and there were no studies with a high risk of bias, all studies had a low risk of bias (see Fig. 2).

We obtained eight studies that described the effect of Op-1 when compared to autograft. Outcomes were evaluated based on clinical and radiological influences, and if the studies used ODI as assessment of outcomes, it was included in the review. While the radiological standards used were plain photos (static and dynamic) and CT scans, assessments were carried out by at least 2 experts in a blind manner.

Johnson et al., result showed no significant difference between OP-1 and autograft comparisons. This study included 20 patients and compared the use of OP-1 with ICBG. Posterolateral fusion performed on all samples of this study had clinical outcomes that were not measured specifically using ODI, but it was explained that the results of the surgery had satisfactory clinical outcomes. The radiological outcomes in this study were measured in variables such as formation of bilateral fusion, partial fusion, and no fusion. Observations made up to 1 year

postoperatively showed that in the OP-1 group, there were 6 patients who had bilateral bridging bones, 3 patients who experienced partial fusion, and 1 patient who did not achieve fusion. In the autograft group, 8 patients had bilateral bridging bone, and 1 patient had partial fusion. The interesting thing is that OP-1 is close to or almost the same as the gold standard, namely autograft in both clinical outcomes and radiographic and radiosterometric outputs. The drawback of this study is that the number of samples is still too small [7].

Vacarro et al., study published in 2004, concluded that BMP-7 was similar with autograft in terms of effectiveness. This study was conducted on a larger sample of 36 patients who experienced spondylolisthesis (grade I and II) with clinical symptoms in the form of neurogenic claudication. In addition, preoperative studies of all patients confirmed MRI or CT spinal stenosis. Assessment of clinical aspects in this study was ODI, all preoperative patients had an ODI > 30 which would later be compared postoperatively. Vacarro et al also provided preoperative screening criteria that the patient had undergone non-operative treatment for 6 months but had refractory complaints. In this study 36 patients were divided into two groups, the OP-1 group and the ICBG group, all patients underwent the same approach, single level uninstrumented posterolateral fusion with decompression laminectomy. At one year

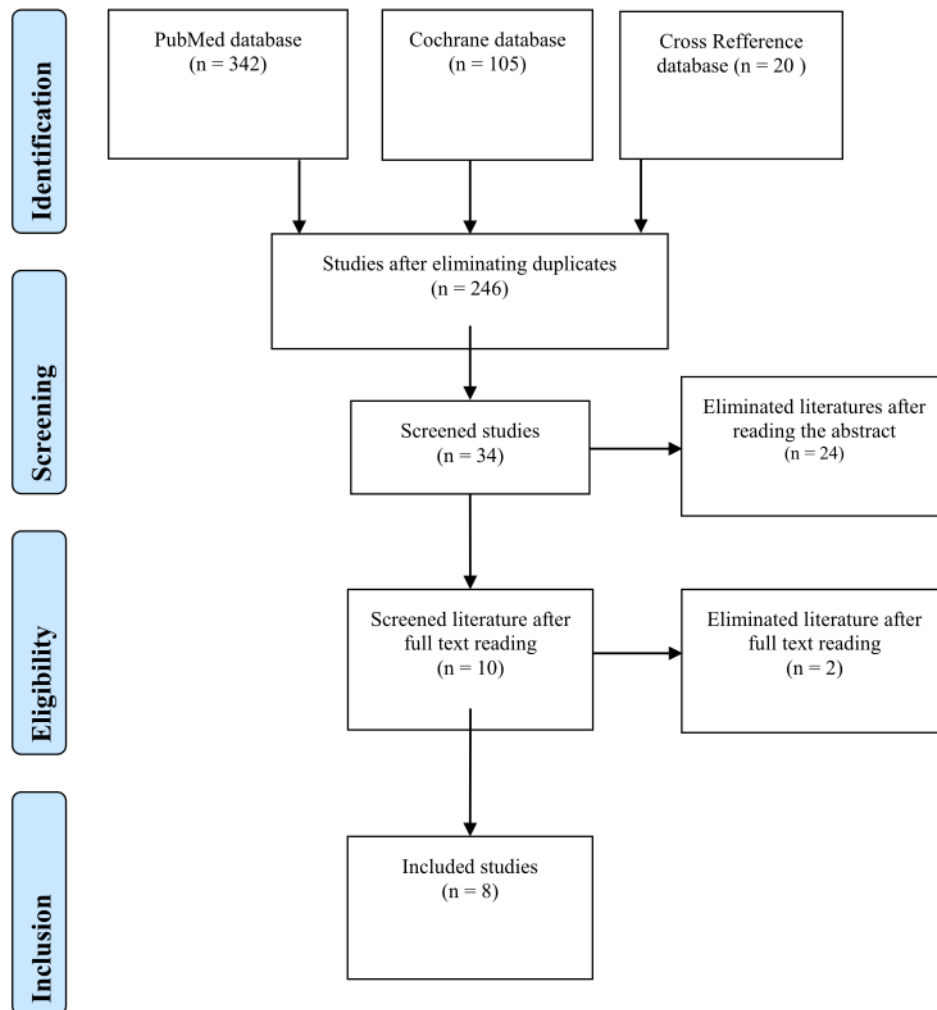
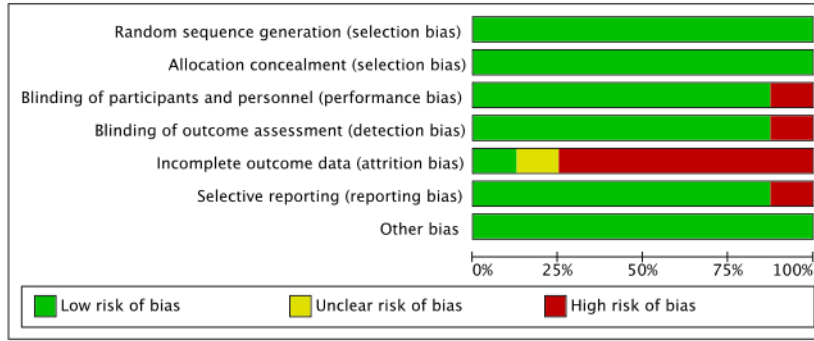


Fig. 1. Systematic Review Flowchart based on PRISMA model.



	Random sequence generation (selection bias)	Allocation concealment (selection bias)	Blinding of participants and personnel (performance bias)	Blinding of outcome assessment (detection bias)	Incomplete outcome data (attrition bias)	Selective reporting (reporting bias)	Other bias
Agabegi et al., 2011	+	+	-	+	?	+	+
Delawi et al., 2010	+	+	+	+	-	-	+
Delawi et al., 2016	+	+	+	+	-	+	+
Johnson et al., 2002	+	+	+	+	+	+	+
Kanayama et al., 2006	+	+	+	+	-	+	+
Vacarro et al., 2004	+	+	+	+	-	+	+
Vacarro et al., 2005	+	+	+	-	-	+	+
Vacarro et al., 2008	+	+	+	+	-	+	+

Fig. 2. Risk of bias analysis using ROBINS-2.

follow-up, a preoperative ODI comparison was performed in both groups, the OP-1 preoperative group had an average of 46 out of 24 patients, while the autograft group had an average of 47 out of 12 patients. Postoperatively, 18 out of 21 patients in the OP-1 group (86 %) achieved improvement with increase of ODI > 20 %, in line with that result the autograft group showed 8 out of 11 patients (73 %) achieved improvement. Meanwhile, radiological assessment used were plain photos (static and dynamic) assessed by 2 neuroradiologists blindly. Radiological studies showed that in the OP-1 group 17 out of 21 patients (81 %) formed bilateral bridging bone. Meanwhile, in the autograft group 9 out of 10 patients (90 %) showed successful fusion with the formation of bilateral bridging bone. This study did not find any significant side effects from the use of OP-1 compared to controls. The conclusion of this study was that posterolateral fusion with OP-1 has a safety and success rate similar to ICBG [8].

Vaccaro et al., continued the research the following year which was published in 2005 with a similar study design. The observations were continued for 24–36 months. The output of this ODI study showed that 17 out of 20 patients (85 %) achieved improvement in ODI in the OP-1 group, whereas in the autograft group it showed 7 out of 11 patients (64 %) had improvement. In the radiological review of this study there was successful posterolateral fusion in 75 % of patients in the OP-1 group and 80 % of patients in the autograft group [9].

The last study by Vaccaro et al., was published in 2008. This study has a similar study design but with an additional observation time of up to 48 months. All of Vaccaro's studies used single level uninstrumented posterolateral fusion. Besides that, this study did not use local bone. All autografts were taken from ICBG. OP-1 used 3.5 mg of lyophilized which was added with 1 g of collagen which is a bovine derivative mixed with 200 mg of carboxymethylcellulose to form the final OP-1 implant of 0.875 mg/ml. The observational assessment was continued for up to 48 months with the aim of obtaining intermediate-term optimal efficacy and safety in the use of OP-1. The outputs of this study were ODI and radiological studies. In this study, clinical success of ODI was found in 73.7 % of OP-1 patients and 57.1 % of the autograft group which managed to improve > 20 % of ODI. Meanwhile, radiological monitoring in the OP-1 group showed 68.8 % solid fusion and 50 % in the autograft group [10].

Kanayama et al., who compared the use of 3.5 mg of BMP-7 mixed with collagen bone matrix and carboxymethylcellulose with autograft in the form of corticocancellous combined with hydroxyapatite. In this study, all 19 patients underwent posterolateral lumbar fusion using instrumentation in the form of a pedicle screw. ODI was used in this study, the mean preoperative ODI in the OP-1 group was 36.1 and preoperative ODI the control group was 39.1. Postoperatively there was a decrease in ODI on the initial 3 months both groups and continued to improve up to 12 months of observation. Radiological review in this study used CT scans and a combination of static and dynamic plain photos, found that 7 out of 9 patients had successful fusion in the OP-1 group and 9 out of 10 patients had successful fusion with bridging bone criteria between transverse processes, lateral flexion–extension showed ≤ 5 degrees angulation and ≤ 2 mm translation. The conclusion of this study is that OP-1 may be considered as an alternative for fusion in patients undergoing posterolateral lumbar fusion but its viability compared to autograft is still in question [11].

Delawi et al., published in 2010, an RCT study of 36 patients. Patients were divided into two groups, the first group was the group that was given OP-1 and the second group was the group that was given ICBG. In using OP-1 in this study, 3.5 mg of OP-1 was mixed with 1 g of collagen and 2.5 ml of blood that was not contaminated with heparin and prepared 15 min before use. Besides that, the autograft in this study used local bone. The entire surgery involved decompression and posterolateral fusion at one spinal level. The clinical output of this study was ODI, observed 12 months after surgery. There was a significant increase of ODI in both groups. Evaluation of the radiological assessment of the OP-1 group found 63 % fusion, 25 % doubtful, 13 % non-

union. Evaluation in the autograft group showed 67 % fusion, 20 % doubtful, and 13 % non-union. There was no significant difference between OP-1 and ICBG groups with $P = 0.95$ [12].

Agabegi et al., aimed compare the outcomes of using BMP-7 and ICBG. Both of these procedures are used for non-instrumentation single-level posterolateral fusion for patients with symptomatic degenerative spondylolisthesis with spinal stenosis accompanied by neurogenic claudication. In total there were 67 patients who underwent randomization. Spinal fusion achieved if there was a bony bridge between the transverse processes, an angulation of less than equal to five degrees, or translational movement of less than or equal to 2 mm on conventional static and dynamic radiographs. This study does not explain in detail the number of doses used for OP-1. The results of this study were 63 % of patients achieved radiographic fusion. The mean preoperative translation was 1.87 mm, and the angular motion was 4.44 degrees, and the lateral disc height was 8.74 mm. There are 37 % of patients who had radiographic pseudoarthrosis. A test was performed which did not classify in detail between OP-1 and autograft but was randomized and obtained good fusion outcomes and some pseudoarthrosis. BMP-7 in this study was similar autografts to induce fusion [13].

The largest study conducted by Delawi et al., published in 2016, was an RCT aimed at comparing BMP-7 and ICBG for single level posterolateral fusion operative procedures, complete or partial posterior decompression laminectomy with or without medial facetectomy, and pedicle instrumentation. The output of this study was overall success which is defined as a combination of clinical success (ODI) and evidence of fusion through a CT scan examination with 2 independent spinal surgeons and senior radiological residents 12 months postoperatively. In this research, it was specifically used in combination with local bone, the OP-1 group was mixed with local bone and in the autograft group it was also mixed with local bone. In this study, 119 patients were the subjects, but only 113 patients whose outcome could be assessed. Non-inferiority was not found in BMP-7 compared to ICBG 1 year postoperatively. Clinical success assessed using ODI showed significant changes at 1 year postoperatively. There were 84 % and 86 % in the OP-1 and Autograft groups. Radiological observation of success with the Cristensen score method, was found in the OP-1 group 54 % fusion, 10 % doubtful, 16 % nonunion. In the autograft group, the result was 74 % fusion, 10 % doubtful, 16 % nonunion were obtained. There was no significant difference between the two groups with $P = 0.90$. So it can be concluded that BMP-7 is an alternative to ICBG in spinal fusion surgery [14].

4. Discussion

BMP use for lumbar fusion started because of complications from using a large number of grafts, causing pain and the uncomfortable sensation for patients. BMP testing especially OP-1 is to prove its function in inducing fusion in spinal surgery. The mechanism of bone formation in the use of bone morphogenetic protein has been widely reviewed [15].

In this systematic review the authors look at several viewpoints that also contribute to clinical and radiological outcomes. So that it influences every research method in the literature review contained in this paper. Several things are suspected to play a role in the success of posterolateral lumbar fusion, such as: BMP-7 carrier, decompression technique, and use of instrumentation [15].

4.1. BMP-7 carrier

The main objective of using a carrier composite for BMP-7 is to maintain the concentration of BMP molecules at the fusion site and provide a degradable scaffold to facilitate new bone formation. The mechanism of new bone formation requires an inflammatory response so that the properties of BMP-7 as an osteoinductive can work. Indirectly, the inflammatory reaction contributes to the success of fusion.

The mechanism of the activated immune response in BMP

implantation is not fully understood or well-defined because the existing literature is still controversial. It is hypothesized that single application of allogeneic and non-collagenous BMP proteins elicited a moderate immune response through production of immunoglobulin G, but did not decrease the osteoinductive capacity of BMPs. A single dose of BMP protein without a composite substance can stimulate high concentrations of anti-BMP antibodies, which can inhibit the osteoinductive potential of BMP [15].

The most used carrier for humans is Type I collagen. However, the powdered nature of the OP-1 implant device creates problem during surgery. The ideal composite carrier is considered to be an absorbable construct that can be shaped into desired shapes while maintaining compression resistance, and capable of bridging the posterolateral space without allowing BMP to diffuse away from the site of action [16].

Collagen has been the most widely used carrier for rhBMP delivery, and is the carrier used in commercial rhBMP products (INFUSE® and OP-1®). The fact that collagen is the most abundant non-mineral component of bone and can be easily isolated and enzymatically purified from various animal species makes it a very favorable candidate for rhBMP carriers. Despite optimal biocompatibility, collagen has several drawbacks. Collagen matrix biodegradation is unpredictable and difficult to control, resulting in undefined protein release kinetics. In addition, collagen has immunogenic properties due to common extraction from bovine and porcine skins, found to have developed antibodies against type I collagen. Another problem encountered with collagen is the difficulty of sterilization, whereby hot sterilization causes complete or partial denaturation whereby the collagen helices become permanently damaged [16,17].

In a systematic review of all studies using collagen type 1 as the main carrier. The system described in studies conducted by Vaccaro et al. 2004, 2005, and 2008; Kanayama et al. 2006 used carboxymethyl-cellulose as an additional material until an immobilization occurred and a scaffold was formed. This is believed to make it easier during spinal surgery, because the formation of the BMP material to be implanted is easy to place and mold [16,17].

Fibrin, derived from blood clots, has also been used as a carrier for rhBMP-2 and its construct significantly enhances bone formation. Fibrin along with type 1 collagen in combination shows complete bone healing in cranial implant models [16,18].

The general advantages of this group of materials are their biocompatibility, hydrolytic biodegradability, low risk of immunogenicity and eliminated possibility of disease transmission in addition to ease of use, formability and general design flexibility. An additional advantage of these materials over natural polymers is their ability to adjust their mechanical strength, tackiness, and degradability according to the requirements of their clinical use through manipulation of the polymer structure. Research conducted by Delawi et al. 2010 and 2016 both used blood as a mixture of collagen. From this study we also found that the fusion rate in the group with BMP-7 was quite high [12,14].

Inorganic materials (mainly ceramics) are another class of carrier materials investigated for the delivery of rhBMPs. Calcium phosphate material is the most used inorganic material in bone tissue regeneration because of its ability to osteoconduct. According to the chemical composition, the most widely used calcium phosphates are divided into three main categories: hydroxyapatite, β -tricalcium phosphate, and the combination of the two is called biphasic calcium phosphate.

The use of various materials as carriers in the studies contained in this systematic review aims to form a combined material that triggers fusion. There are interesting things about using this material, in a study conducted by Delawi et al. 2016 they used local bone as a scaffold in both the BMP-7 group and the autograft group. It can be observed that in the control group with a combination of ICBG and local bone, the fusion success rate achieved was quite high, 74 %, in the BMP-7 group, it reached 54 % success rate.

4.2. Decompression in posterior lumbar approach

In this study, all of the procedures performed mentioned decompression measures. The act of decompression itself affects the outcome in patients with clinical pressure on the canal thereby improving post-operative ODI. However, what needs to be highlighted is the laminectomy approach with or without a medial facetectomy. It is feared that this technique will affect instability. In the study with spinal stenosis cases, open surgery was performed, although there are other techniques such as microsurgery but open surgery is still the main choice. The degree of stenosis severity will determine the approach, the usual choices are mono or bilateral laminectomy. In posterior decompression, resection of the facet capsule and part of the bone can be carried out, but it could result in instability, knowing the severity of the condition will help determine the choice of action [19].

Facetectomy has affected lumbosacral mechanical ability during rotational axial loading. The preload force causes the weight of the upper body and muscles to have the same effect as the accompanying force, which has a minor effect on intersegmental rotation. The increased intersegmental rotation caused by facetectomy is accompanied by increased stress on the annulus and intradiscal pressure. When calculating intersegment rotation, differences in the degree of posterior resection have a large effect on standing and forward bending [19].

Laminectomy when performed at 2 levels has only a very minimal effect on intersegmental rotation, stress, strain, intradiscal pressure and forces on the facet joint segments above. Biomechanically it does not cause any effect on the region above it. Resection of the posterior area will have the greatest effect when the ligament is involved and causes stress on the disc. Bilateral or one-sided hemi facetectomy increases intersegment rotation during axial loading. There are only minor differences between bilateral hemi facetectomy and hemilaminectomy. The patient should avoid excessive axial rotation after the procedure. The difference between a hemilaminectomy and a bilateral laminectomy is only when flexing and bending forward. The role of postoperative physical therapy is important to strengthen skeletal muscle stability and avoid excessive axial loading [19].

4.3. Instrumentation VS without instrumentation in single level posterolateral fusion approach

In this systematic review, it was found that 2 studies by Kanayama et al. and Delawi et al. used instrumentation, while the rest did without instrumentation. The use of instrumentation or not, also played a role in the outcomes of the studies included in this systematic review. All of the research in this systematic review only used single level instrumentation [11,12,14].

In the study by Pourtaheri et al. Overall, there was a similar increase in mean ODI scores at final follow-up in the instrumented and non-instrumented groups. In the instrumented group, the average ODI score increased from 83 points (range, 72–94 points) before surgery to 43 points (range, 21–58 points) after surgery. In the non-instrumented group, the mean ODI score increased from 85 points (range, 70–92 points) preoperatively to 46 points (range, 61–84 points) post-operatively (Table 2). Therefore, there was no difference in the mean increase in ODI scores between the 2 groups (40 vs 39 points each; $P = 0.81$) [20].

The incidence of severe adjacent segmental degeneration (ASD) was similar for both first and second adjacent cranial segments. Eleven (32 %) patients showed evidence of severe ASD at the first adjacent cranial level and 11 showed evidence of severe ASD at the next level. The average grade is 1.9 at the first level and 2 at the second level. Not only were the radiographic results similar between the instrumented and non-instrumented cohorts, but the increase in ODI scores was similar. Another study by Katz et al, with 272 patients as subject, were treated for degenerative lumbar stenosis. This study showed that the non-instrumented fusion group had better relief of back pain at 6 months

Table 2
Investigation data for study included in systematic review.

Study	Type of study	Preoperative condition	Surgical approach	Comparison		Preoperative ODI		Fusion criteria	Outcomes		Result	
				Control group		OP-1	Autograft		Radiologic Fusion Success			
				OP-1 group	Carrier				OP-1	Autograft		
Johanson et al., 2002	RCT	Age > 20, L5 spondylolysis, vertebral slip < 50%, refractory ain 6 months	PLF + uninstrumented	3.5 mg	1 g bone collagen type 1 + 2.5 ml saline = 3.5 ml paste	ICBG	Not mentioned	Plain radiograph radio graph Cristensen kriterias	OP-1: 3 Non-union:1	Fusion:8 Doubtful:1 Non-union:0	No significant comparison between groups (P = 0.648)	
Vaccaro et al., 2004	RCT	Grade I & II Degenerative spondylolisthesis, claudication neurogenic, pre operative MRI or CT canal stenosis, refractory pain 6 months	Single level + PLF + decompression laminectomy + medical facetectomy + uninstrumented	3.5 mg	1 g bone collagen type 1 + 200 mg carboxymethyl-cellulose + saline = 0.875 mg/ml	ICBG	46 47	Larsen criteria plain radiograph	(18/21) (81%) 73 % 86 %	9/10 (90 %)	No significant differences between groups (P = 0.648)	
Vaccaro et al., 2005	RCT	Grade I & II Degenerative spondylolisthesis, claudication neurogenic, pre operative MRI or CT canal stenosis, refractory pain 6 months	Single level + PLF + decompression laminectomy + medical facetectomy + uninstrumented	3.5 mg	1 g bone collagen type 1 + 200 mg carboxymethyl-cellulose + saline = 0.875 mg/ml	ICBG	46 47	Larsen criteria plain radiograph	(17/20) (85 %)	15/20 (75 %)	No significant difference between groups (P = 0.21)	
Kanayama et al., 2006	RCT	Degenerative L3-L4 or L4-5 spondylolisthesis	PLF + instrumentation	3.5 mg	1 g bone collagen matrix + carboxymethyl-cellulose + 2.2 ml saline	Corticocancellous bone + HA-TCP granules	36,1 39,1	CT scan + plain radiography Kanyama criteria	ODI significantly decrease in both groups after 3 months (P < 0.05 with one-way ANOVA test)	7/9 (78 %)	9/10 (90 %)	There is no difference between both groups (P > 0.05 with unpaired t-test) ODI on both groups showed improvement No difference between both groups, there was no reported local or systemic toxicity
Vaccaro et al., 2008	RCT	Grade I & II Degenerative spondylolisthesis, claudication neurogenic, pre operative MRI or CT canal stenosis, refractory pain 6 months	Single level + PLF + decompression laminectomy + medical facetectomy + uninstrumented	3.5 mg	1 g bone collagen type 1 + 200 mg carboxymethyl-cellulose + saline = 0.875 mg/ml	ICBG	46 47	Plain radiography Larsen Criteria	14/19 (73.7 %)	11/16 (68.8 %)	3/6 (50 %)	No difference between both groups, there was no reported local or systemic toxicity
Delawi et al., 2010	RCT	Degenerative spondylolisthesis + Neurologic compression	Single level + PLF + decompression, uninstrumented	3.5 mg	1 g collagen + 2.5 ml fresh blood prepared 15 min before use	Local bone	>30 >30	Plain radiography + CT scan Cristensen criteria	ODI significantly decreased in both group	Fusion:10 (63 %) Doubtful: 4 (25 %) Non-union:2 (13 %)	Fusion: 10 (67 %) Doubtful: 3 (20 %) Non-union: 2 (13 %)	No significant difference between both groups (P = 0.95 %)

(continued on next page)

Table 2 (continued)

Study	Type of study	Preoperative condition	Surgical approach	Comparison		Preoperative ODI	Fusion criteria	Outcomes		Radiologic Fusion Success		Result
				OP-1 group	Carrier			Control group	OP-1	Autograft	OP-1	
Agabegi et al., 2011	RCT	Grade I or grade II degenerative spondylolisthesis + spinal stenosis + refractory pain for 6 months	Single level + PLF + decompression + uninstrumented	No specific explanation	ICBG	No specific explanation	Plain radiography Larsen Criteria	No specific explanation	42/67 (63%) complete fusion	42/67 (63%) complete fusion	No significant difference between both groups	
Delawi et al., 2016	RCT	Grade I or grade II degenerative spondylolisthesis + spinal stenosis + refractory pain for 6 months	Single level + PLF + decompression + total laminectomy or partial + medial facetectomy + instrumentation	3.5 mg 1 g collagen + 2.5 ml fresh blood + local bone prepared 15 min before use	ICBG + local bone	>30	Plain radiography + CT Cristensen criteria	84% 86%	Fusion: 54% Fusion: 74%	Fusion: 54% Fusion: 74%	No significant difference between both groups (P = 0.90)	

and 2 years compared to the instrumented fusion group. Although the non-instrumented cases in this study had a longer follow-up period, they maintained good clinical and radiographic results [21].

Fusion without instrument may be a good option for degenerative lumbar stenosis even with extensive laminectomy and bilateral partial facetectomy. Longer follow-up appears to be a risk factor for the development of ASD and may be a consequence of disease progression or biomechanical changes. Adjacent segmental degeneration is unlikely to occur at a level requiring further surgery, either with instruments or in situ [22].

4.4. Radiological imaging in defining fusion success

Noninvasive assessment of bone fusion after spinal surgery is essential for diagnosing patients with symptoms of pseudarthrosis and evaluating the performance of the surgery, although there is already consensus on the definition of successful lumbar posterolateral fusion [23].

Although there are many studies highlighting the modalities used to assess successful posterolateral fusion, recommending thin-slice CT scanning with multiplanar reconstruction, the criteria for successful fusion are still controversial. In the literature review conducted, there are several criteria used to determine radiological fusion success. Combinations of modalities, criteria and cut-off values are used in clinical practice. A systematic review was carried out by Lehr et al 2022 on 88 articles that used a classification system, with the most being Lenke's classification followed by Christensen's classification. The overall classification essentially evaluates the continuity of the bony link between the two segments. Various terms are used to describe the bony link such as trabecular, cortical edges, dense, and solid [23].

The concept by Cristansen et al. shows the classification rating at each level and each side is determined separately and respectively. The presence of a continuous intertransverse link having at least one or two sides indicates fusion at that level. "Fusion" indicates fusion quality at all levels involved, "doubtful" indicates suboptimal quality at one or more levels including fusion occurring behind instrumentation, "nonunion" indicates clearly poor fusion quality at levels involved [24].

In this review, there are several classification systems used, namely: Larsen, Cristensen and the Kanayama combination. From this review, the authors also wanted to assess the accuracy of each classification used on the basis of other literature such as the systematic review by Lehr et al. The use of the Lanke and Cristensen classification system is supported by certified radiologists, although the evidence for diagnostic accuracy is still limited. The systematic review also shows that the use of CT continues is accurate to determine the success rate of fusion, although static radiography is still the main choice. A sizable study showed sensitivity and specificity in determining the success of fusion between assessment based on radiological and surgical exploration images which were still.

Although Lehr et al. could not show the superiority of plain radiographs compared to CT, it is recommended to use CT to determine the success of fusion and the risk of pseudarthrosis. While the use of dynamic plain radiography does not provide added value for determining fusion since a rigid instrumentation is used. The classification used in that study shows good reliability for systematically determining posterolateral fusion [23].

4.5. Use of BMP in the future

Along with the development of minimally invasive surgical techniques, the use of BMP as an alternative to biological autograft can reduce the morbidity associated with spinal fusion. This is a proof-of-concept for gene therapy-mediated anterior spinal fusion that can be adapted by percutaneous techniques to clinical use [25].

Spinal fusion using ICBG may become a historical practice due to modern advances in bone morphogenetic proteins. Currently two

specific BMP homodimers (BMP-2 and BMP-7) with different carriers are being used to achieve successful spinal fusion in pre-clinical and clinical studies. This BMP 2/7 heterodimer combination is efficient for increasing callus volume compared to homodimer and reducing osteoclastic stimulation in spinal fusion although the exact dose and increase in fusion rate are still unclear [26].

To date, the use of BMPs has been demonstrated clinically in only one fusion level. Spinal fusion often requires many levels especially in cases where deformity correction surgery is required. The efficacy and use of BMPs at various levels with appropriate carriers and doses has not been established. Comprehensive understanding in this required domain is yet to develop. The main challenge in the future is to further optimize the dosage and carrier materials for specific fusion applications, i.e. anterior, posterior, for repair of pseudarthrosis, multi-level operations and instrumented cases [26].

4.6. Research limitations

This study is a systematic review describing the clinical and radiological success of patients undergoing posterolateral lumbar fusion surgery. This systematic review attempts to analyze RCT studies to obtain strong scientific evidence. The limitation of this study is that the researchers did not group the sample population based on the specific time of evaluating the homogeneous outcomes. This study also did not perform analysis based on each vertebral segment and was only limited to studies with posterolateral lumbar fusion.

5. Conclusion

The use of OP-1/BMP-7 as alternative of autograft for posterolateral lumbar fusion gives similar clinical success with minimal donor site complication. OP-1/BMP-7 have similar osteoinductive properties showing similar radiological success with autograft. There is no significant difference between BMP-7 and autograft. There are several factors that affects successful radiological fusion success and Oswestry Disability Index such as composite carrier, instruments use, decompression factor, and the definition for radiological fusion success. To evaluate the efficacy of BMP-7/OP-1 need further research with bigger sample size.

6. Author Agreement

All listed authors have reviewed and approved the final version of the manuscript. This manuscript has not been published elsewhere and this is author's original work.

Financing Basis

This research did not receive any funding from any public and commercial agencies.

CRedit authorship contribution statement

Eko Agus Subagio: Conceptualization, Data curation, Writing – original draft. **Mustaqim Apriyansa Rahmadhan:** Conceptualization, Data curation, Writing – original draft. **Muhammad Faris:** Conceptualization, Data curation. **Rahardian Indarto Susilo:** . **Nur Setiawan Suroto:** . **Budi Utomo:** . **Pandu Wicaksono:** . **Abdul Hafid Bajamal:** .

Declaration of Competing Interest

The authors declare that they have no known competing financial interests or personal relationships that could have appeared to influence the work reported in this paper.

References

- [1] S. Baliga, K. Treon, N.J.A. Craig, Low Back Pain: Current Surgical Approaches, *Asian Spine J.* 9 (2015) 645, <https://doi.org/10.4184/asj.2015.9.4.645>.
- [2] D.K. Park, R. Roberts, P. Arnold, D.H. Kim, R. Sasso, K.C. Baker, J.S. Fischgrund, Lumbar Spine Fusion Rates With Local Bone in Posterolateral and Combined Posterolateral and Interbody Approaches, *JAAOS: Global Res. Rev.* 3 (2019) e018.
- [3] S. Liu, Y. Wang, Z. Liang, M. Zhou, C. Chen, Comparative Clinical Effectiveness and Safety of Bone Morphogenetic Protein Versus Autologous Iliac Crest Bone Graft in Lumbar Fusion, *Spine (Phila Pa 1976)* 45 (2020), <https://doi.org/10.1097/BRS.0000000000003372>.
- [4] M.R. Urist, Bone: Formation by Autoinduction, *Science* 150 (1965) (1979) 893–899, <https://doi.org/10.1126/science.150.3698.893>.
- [5] D. Drazin, E. Choi, A. Garcia, T. Rustagi, Bone morphogenic proteins are a good choice for select spinal surgeries and merit further research, *Journal of Spine Surgery.* 3 (2017) 119–121. [10.21037/jss.2017.02.03](https://doi.org/10.21037/jss.2017.02.03).
- [6] F. Ye, Z. Zeng, J. Wang, H. Liu, H. Wang, Z. Zheng, Comparison of the use of rhBMP-7 versus iliac crest autograft in single-level lumbar fusion: a meta-analysis of randomized controlled trials, *J. Bone Miner. Metab.* 36 (2018) 119–127, <https://doi.org/10.1007/s00774-017-0821-z>.
- [7] R. Johnsson, B. Strömqvist, P. Aspenberg, Randomized Radiostereometric Study Comparing Osteogenic Protein-1 (BMP-7) and Autograft Bone in Human Noninstrumented Posterolateral Lumbar Fusion 2002 Volvo Award in Clinical Studies, *Spine (Phila Pa 1976)* 27 (2002) 2654–2661.
- [8] A.R. Vaccaro, T. Patel, J. Fischgrund, D.G. Anderson, E. Truumees, H.N. Herkowitz, F. Phillips, A. Hilibrand, T.J. Albert, T. Wetzel, J.A. Mcculloch, A Pilot Study Evaluating the Safety and Efficacy of OP-1 Putty (rhBMP-7) as a Replacement for Iliac Crest Autograft in Posterolateral Lumbar Arthrodesis for Degenerative Spondylolisthesis, *Spine (Phila Pa 1976)* 29 (2004) 1885–1892.
- [9] A.R. Vaccaro, D.G. Anderson, T. Patel, J. Fischgrund, E. Truumees, H.N. Herkowitz, F. Phillips, A. Hilibrand, T.J. Albert, T. Wetzel, J.A. Mcculloch, Comparison of OP-1 Putty (rhBMP-7) to Iliac Crest Autograft for Posterolateral Lumbar Arthrodesis A Minimum 2-Year Follow-up Pilot Study, *Spine (Phila Pa 1976)* 30 (2005) 2709–2716.
- [10] A.R. Vaccaro, P.G. Whang, T. Patel, F.M. Phillips, D.G. Anderson, T.J. Albert, A. S. Hilibrand, R.S. Brower, M.F. Kurd, A. Appannagari, M. Patel, J.S. Fischgrund, The safety and efficacy of OP-1 (rhBMP-7) as a replacement for iliac crest autograft for posterolateral lumbar arthrodesis: minimum 4-year follow-up of a pilot study, *Spine J.* 8 (2008) 457–465, <https://doi.org/10.1016/j.spinee.2007.03.012>.
- [11] M. Kanayama, T. Hashimoto, K. Shigenobu, S. Yamane, T.W. Bauer, D. Togawa, A Prospective Randomized Study of Posterolateral Lumbar Fusion Using Osteogenic Protein-1 (OP-1) Versus Local Autograft With Ceramic Bone Substitute Emphasis of Surgical Exploration and Histologic Assessment, *Spine (Phila Pa 1976)* 31 (2006) 1067–1074.
- [12] D. Delawi, W.J.A. Dhert, L. Rillardon, E. Gay, D. Prestamburgo, C. Garcia-Fernandez, E. Guerado, N. Specchia, J.L.C. van Susante, J. N. Verschoor, H.M.E. Quarles Van Ufford, F.C. Oner, A Prospective, Randomized, Controlled, Multicenter Study of Osteogenic Protein-1 in Instrumented Posterolateral Fusions Report on Safety and Feasibility, *Spine (Phila Pa 1976)* 35 (2010) 1185–1191.
- [13] S.S. Agabegi, K. Majid, J.S. Fischgrund, A.R. Vaccaro, T. Patel, Can Preoperative Radiographic Parameters Be Used to Predict Fusion in Non-instrumented Posterolateral Fusion for Degenerative Spondylolisthesis? *Spine (Phila Pa 1976)* 36 (2011) <https://doi.org/10.1097/BRS.0b013e31821d289f>.
- [14] D. Delawi, W. Jacobs, J.L.C. van Susante, L. Rillardon, D. Prestamburgo, N. Specchia, E. Gay, N. Verschoor, C. Garcia-Fernandez, E. Guerado, H. Quarles van Ufford, M.C. Kruyt, W.J.A. Dhert, F.C. Oner, OP-1 Compared with Iliac Crest Autograft in Instrumented Posterolateral Fusion, *Journal of Bone and Joint, Surgery* 98 (2016) 441–448, <https://doi.org/10.2106/JBJS.O.00209>.
- [15] J.M. Granjeiro, R.C. Oliveira, J.C. Bustos-Valenzuela, M.C. Sogayar, R. Taga, Bone morphogenetic proteins: from structure to clinical use, *Brazilian Journal of Medical and Biological, Research* 38 (2005) 1463–1473, <https://doi.org/10.1590/S0100-879X2005001000003>.
- [16] I. el Bialy, W. Jiskoot, M. Reza Nejadnik, Formulation, Delivery and Stability of Bone Morphogenetic Proteins for Effective Bone Regeneration, *Pharm Res.* 34 (2017) 1152–1170, <https://doi.org/10.1007/s11095-017-2147-x>.
- [17] N. Stokovic, N. Ivanjko, D. Maticic, F.P. Luyten, S. Vukicevic, Bone Morphogenetic Proteins, Carriers, and Animal Models in the Development of Novel Bone Regenerative Therapies, *Materials* 14 (2021) 3513, <https://doi.org/10.3390/ma14133513>.
- [18] T.K. Sampath, S. Vukicevic, Biology of bone morphogenetic protein in bone repair and regeneration: A role for autologous blood coagulum as carrier, *Bone* 141 (2020), 115602, <https://doi.org/10.1016/j.bone.2020.115602>.
- [19] T. Zander, A. Rohlmann, C. Klckner, G. Bergmann, Influence of graded facetectomy and laminectomy on spinal biomechanics, *European Spine Journal.* 12 (2003) 427–434. [10.1007/s00586-003-0540-0](https://doi.org/10.1007/s00586-003-0540-0).
- [20] S. Pourtaheri, C. Billings, M. Bogatch, K. Issa, C. Haraszti, D. Mangel, E. Lord, H. Park, R. Ajiyoye, A. Ashana, A. Emami, Outcomes of Instrumented and Noninstrumented Posterolateral Lumbar Fusion, *Orthopedics.* 38 (2015), <https://doi.org/10.3928/01477447-20151120-07>.
- [21] H.S. Yoon, J. Lawrence Katz, Ultrasonic wave propagation in human cortical bone—II. Measurements of elastic properties and microhardness, *J. Biomech.* 9 (1976) 459–464, [https://doi.org/10.1016/0021-9290\(76\)90089-0](https://doi.org/10.1016/0021-9290(76)90089-0).
- [22] T. Andersen, F.B. Christensen, B.L. Langdahl, C. Ernst, S. Fruensgaard, J. Østergaard, J.L. Andersen, S. Rasmussen, B. Niedermann, K. Høy, P. Helming, R. Holm, B.E. Lindblad, E.S. Hansen, N. Egun, C. Bünger, Fusion mass bone

- quality after uninstrumented spinal fusion in older patients, *Eur. Spine J.* 19 (2010) 2200–2208, <https://doi.org/10.1007/s00586-010-1373-2>.
- [23] A.M. Lehr, A.A.A. Duits, M.R.L. Reijnders, D. Nutzinger, R.M. Castelein, F.C. Oner, M.C. Kruyt, Assessment of Posterolateral Lumbar Fusion, *JBS Rev.* 10 (2022), <https://doi.org/10.2106/JBJS.RVW.22.00129>.
- [24] F.B. Christensen, M. Laursen, J. Gelineck, E.S. Hansen, C.E. Bünger, Posterolateral spinal fusion at unintended levels due to bone-graft migration: No effect on clinical outcome in 19/130 patients, *Acta Orthop Scand.* 72 (2001) 354–358, <https://doi.org/10.1080/000164701753542005>.
- [25] M.E. Cunningham, N.H. Kelly, B.A. Rawlins, O. Boachie-Adjei, M.C.H. van der Meulen, C. Hidaka, Lumbar spine intervertebral disc gene delivery of BMPs induces anterior spine fusion in lewis rats, *Sci Rep.* 12 (2022) 16847, <https://doi.org/10.1038/s41598-022-21208-1>.
- [26] H. Begam, S.K. Nandi, B. Kundu, A. Chanda, Strategies for delivering bone morphogenetic protein for bone healing, *Mater. Sci. Eng. C* 70 (2017) 856–869, <https://doi.org/10.1016/j.msec.2016.09.074>.

Comparison Of Fusion Outcomes Of Bone Morphogenetics Proteins-7 And Bone Autograft In Posterolateral Lumbar Fusion: A Systematic Review

ORIGINALITY REPORT

19%

SIMILARITY INDEX

12%

INTERNET SOURCES

15%

PUBLICATIONS

4%

STUDENT PAPERS

PRIMARY SOURCES

- 1 Submitted to Universitas Airlangga 1%

Student Paper
- 2 Fubiao Ye, Zhiyuan Zeng, Jianru Wang, Hui Liu, Hua Wang, Zhaomin Zheng. "Comparison of the use of rhBMP-7 versus iliac crest autograft in single-level lumbar fusion: a meta-analysis of randomized controlled trials", Journal of Bone and Mineral Metabolism, 2017 1%

Publication
- 3 Jike Lu, Divya Bhargav, Ai-Qun Wei, Ashish Diwan. "Posterolateral Intertransverse Spinal Fusion Possible in Osteoporotic Rats With BMP-7 in a Higher Dose Delivered on a Composite Carrier", Spine, 2008 1%

Publication
- 4 www.scilit.net 1%

Internet Source
- 5 journals.lww.com 1%

Internet Source

6	T. Zander, A. Rohlmann, C. Klöckner, G. Bergmann. "Influence of graded facetectomy and laminectomy on spinal biomechanics", European Spine Journal, 2003 Publication	1 %
7	www.mdpi.com Internet Source	1 %
8	escholarship.org Internet Source	1 %
9	J.M. Granjeiro, R.C. Oliveira, J.C. Bustos-Valenzuela, M.C. Sogayar, R. Taga. "Bone morphogenetic proteins: from structure to clinical use", Brazilian Journal of Medical and Biological Research, 2005 Publication	1 %
10	Ander Abarrategi, Syed A. Mian, Diana Passaro, Kevin Rouault-Pierre, William Grey, Dominique Bonnet. "Modeling the human bone marrow niche in mice: From host bone marrow engraftment to bioengineering approaches", The Journal of Experimental Medicine, 2018 Publication	1 %
11	iknow-imeri.fk.ui.ac.id:8080 Internet Source	1 %
12	Masahiro Kanayama, Tomoyuki Hashimoto, Keiichi Shigenobu, Shigeru Yamane, Thomas	1 %

W. Bauer, Daisuke Togawa. "A Prospective Randomized Study of Posterolateral Lumbar Fusion Using Osteogenic Protein-1 (OP-1) Versus Local Autograft With Ceramic Bone Substitute", Spine, 2006

Publication

13

Submitted to Radford University

Student Paper

<1 %

14

aura.abdn.ac.uk

Internet Source

<1 %

15

A. Mechteld Lehr, Anneli A.A. Duits, Maarten R.L. Reijnders, Don Nutzinger, René M. Castelein, F. Cumhur Oner, Moyo C. Kruyt. "Assessment of Posterolateral Lumbar Fusion", JBJS Reviews, 2022

Publication

<1 %

16

Advanced Concepts in Lumbar Degenerative Disk Disease, 2016.

Publication

<1 %

17

pubmed.ncbi.nlm.nih.gov

Internet Source

<1 %

18

Alexander R. Vaccaro, James P. Lawrence, Tushar Patel, Lee D. Katz et al. "The Safety and Efficacy of OP-1 (rhBMP-7) as a Replacement for Iliac Crest Autograft in Posterolateral Lumbar Arthrodesis", Spine, 2008

Publication

<1 %

19 medi-guide.meditool.cn <1 %
Internet Source

20 repozitorij.unizg.hr <1 %
Internet Source

21 eprints.soton.ac.uk <1 %
Internet Source

22 Andrew P. White. "Clinical applications of BMP-7/OP-1 in fractures, nonunions and spinal fusion", International Orthopaedics, 11/16/2007 <1 %
Publication

23 api.research-repository.uwa.edu.au <1 %
Internet Source

24 www.nature.com <1 %
Internet Source

25 Delawi, D., W. Jacobs, J. L. C. van Susante, L. Rillardon, D. Prestamburgo, N. Specchia, E. Gay, N. Verschoor, C. Garcia-Fernandez, E. Guerado, H. Quarles van Ufford, M. C. Kruyt, W. J. A. Dhert, and F. C. Oner. "OP-1 Compared with Iliac Crest Autograft in Instrumented Posterolateral Fusion: A Randomized, Multicenter Non-Inferiority Trial", The Journal of Bone and Joint Surgery (American), 2016. <1 %
Publication

26	scholar.unair.ac.id Internet Source	<1 %
27	Alexander R. Vaccaro. "A Pilot Study Evaluating the Safety and Efficacy of OP-1 Putty (rhBMP-7) as a Replacement for Iliac Crest Autograft in Posterolateral Lumbar Arthrodesis for Degenerative Spondylolisthesis", Spine, 09/2004 Publication	<1 %
28	Carlisle, E.. "Bone morphogenetic proteins for spinal fusion", The Spine Journal, 200511/12 Publication	<1 %
29	Finn Bjarke Christensen. "Lumbar spinal fusion: Outcome in relation to surgical methods, choice of implant and postoperative rehabilitation", Acta Orthopaedica Scandinavica, 1/1/2004 Publication	<1 %
30	Submitted to Griffith College Dublin Student Paper	<1 %
31	patents.justia.com Internet Source	<1 %
32	pure.uva.nl Internet Source	<1 %
33	online.boneandjoint.org.uk Internet Source	<1 %

34 patobriensafety.com <1 %
Internet Source

35 www.mybiosource.com <1 %
Internet Source

36 "Bone Morphogenetic Proteins: Systems
Biology Regulators", Springer Science and
Business Media LLC, 2017 <1 %
Publication

37 Alison K. Heilbronner, Alexander Dash, Beth E.
Straight, Leah J. Snyder et al. "Peripheral
cortical bone density predicts vertebral bone
mineral properties in spine fusion surgery
patients", Bone, 2023 <1 %
Publication

38 Patrícia Pereira. "Peptide and Protein
Application in Tissue Repair and
Regeneration", Peptide and Protein Delivery,
2011 <1 %
Publication

39 bmcmusculoskeletdisord.biomedcentral.com <1 %
Internet Source

40 downloads.hindawi.com <1 %
Internet Source

41 www.hca.wa.gov <1 %
Internet Source

42 Alexander R. Vaccaro, Peter G. Whang, Tushar Patel, Frank M. Phillips et al. "The safety and efficacy of OP-1 (rhBMP-7) as a replacement for iliac crest autograft for posterolateral lumbar arthrodesis: minimum 4-year follow-up of a pilot study", The Spine Journal, 2008
Publication

43 Veillette, C.J.H.. "Growth factors - BMPs, DBMs, and buffy coat products: are there any proven differences amongst them?", Injury, 200703
Publication

44 William S. Pietrzak, Stephen V. Perns, Joshua Keyes, Jennifer Woodell-May, Nicholas M. McDonald. "Demineralized Bone Matrix Graft: A Scientific and Clinical Case Study Assessment", The Journal of Foot and Ankle Surgery, 2005
Publication

45 acikerisim.baskent.edu.tr:8080
Internet Source

46 d.docksci.com
Internet Source

47 digital.library.adelaide.edu.au
Internet Source

48 f1000research.com
Internet Source

49	jss.amegroups.com Internet Source	<1 %
50	studylib.net Internet Source	<1 %
51	www.researchsquare.com Internet Source	<1 %
52	"Abstracts for Oral Presentations for EuroSpine 2012, May Amsterdam", European Spine Journal, 2012 Publication	<1 %
53	Alexander R Vaccaro, Tushar Patel, Jeffrey Fischgrund, D. Greg. Anderson et al. "A 2-year follow-up pilot study evaluating the safety and efficacy of op-1 putty (rhbmp-7) as an adjunct to iliac crest autograft in posterolateral lumbar fusions", European Spine Journal, 2005 Publication	<1 %
54	Michael S.H. Kain, Thomas A. Einhorn. "Recombinant Human Bone Morphogenetic Proteins in the Treatment of Fractures", Foot and Ankle Clinics, 2005 Publication	<1 %
55	www.cms.gov Internet Source	<1 %
56	www.ema.europa.eu Internet Source	<1 %

57

www.orthopeden.org

Internet Source

<1 %

58

www.scribd.com

Internet Source

<1 %

59

Jeffrey A. Rihn. "Graft Options in Posterolateral and Posterior Interbody Lumbar Fusion :", Spine, 08/2010

Publication

<1 %

60

"Bone morphogenetic proteins and spinal fusion", Neurosurgical FOCUS, 12/2002

Publication

<1 %

61

"Minimally Invasive Spine Surgery", Springer Science and Business Media LLC, 2019

Publication

<1 %

62

Charlotte H. Chen, Erin L. Hsu, Samuel I. Stupp. "Supramolecular self-assembling peptides to deliver bone morphogenetic proteins for skeletal regeneration", Bone, 2020

Publication

<1 %

63

Zhang, Haifei, Feng Wang, Lin Ding, Zhiyu Zhang, Deri Sun, Xinmin Feng, Jiuli An, and Yue Zhu. "A Meta Analysis of Lumbar Spinal Fusion Surgery Using Bone Morphogenetic Proteins and Autologous Iliac Crest Bone Graft", PLoS ONE, 2014.

Publication

<1 %

Exclude quotes Off

Exclude matches Off

Exclude bibliography On

Comparison Of Fusion Outcomes Of Bone Morphogenetics Proteins-7 And Bone Autograft In Posterolateral Lumbar Fusion: A Systematic Review

GRADEMARK REPORT

FINAL GRADE

/0

GENERAL COMMENTS

Instructor

PAGE 1

PAGE 2

PAGE 3

PAGE 4

PAGE 5

PAGE 6

PAGE 7

PAGE 8

PAGE 9

PAGE 10