

Fibrin Glue: An Anti-Fibrotic Agent For Contracted Socket

by Budi Utomo

Submission date: 07-Aug-2023 02:55PM (UTC+0800)

Submission ID: 2142534876

File name: Artikel_Tambahan_14.pdf (455.94K)

Word count: 3739

Character count: 20465

22
**Fibrin glue: an anti-fibrotic agent for
contracted socket**Ivon Bremmy Wydha Saputro¹, Yulia Primitasari^{1*}, Susy Fatmariyanti¹,
Dyah Fauziah², Budi Utomo³

ABSTRACT

4
28
Background: The contracted socket is caused by fibrosis leading to the shortening of the orbital tissue. Vascular endothelial growth factor (VEGF) is a profibrotic factor in postoperative wound healing. The novel option to prevent fibrosis is the use of fibrin glue. This study aims to evaluate the role of fibrin glue in reducing the VEGF expression in cells that cause post-socket surgery scar.**Methods:** An in vivo experimental study using an animal model was conducted. We used twenty eyes of white rabbit species as the study sample. The evisceration was carried out and distributed to the animals in four experimental groups consisting of the control group, the MMC group (0.1 ml of mitomycin-C (MMC) 0.4 mg/ml), the triamcinolone acetonide (TCA) group (0.1 ml of TCA 40 mg/ml), and the fibrin glue group (0.1 ml of fibrin glue). The treatment was performed through injection of the subconjunctival. After 14 days, rabbits were euthanized, and conjunctiva samples were cut. Immunoreactivity scores (IRS) were used to analyze the expression of VEGF in epithelia conjunctiva with a significant level of $p < 0.05$. Data were analyzed using SPSS version 26 for Windows.24
Results: All groups showed a statistically significant difference in VEGF expression with a p-value 0,000 ($p < 0,05$). The VEGF level was significantly lower in the three treatment groups compared with the control group. The VEGF expression was highest for the control group, followed by fibrin glue, TCA and MMC group. We found significant differences between the control group and the three treatment groups; the MMC group ($p = 0.001$), the TCA group ($p = 0.002$), and the fibrin glue group ($p = 0.005$). While differences in VEGF expression between the three treatment groups could not be proven statistically.**Conclusion:** Fibrin glue is proven to reduce VEGF expression as a marker of fibrosis; thus, fibrin glue can be an alternative anti-fibrotic agent.**Keywords:** contracted socket, fibrin glue, fibrosis, MMC, TCA, VEGF.**Cite This Article:** Saputro, I.B.W., Primitasari, Y., Fatmariyanti, S., Fauziah, D., Utomo, B. 2022. Fibrin glue: an anti-fibrotic agent for contracted socket. *Bali Medical Journal* 11(3): 1498-1502. DOI: 10.15562/bmj.v11i13.3707¹Department of Ophthalmology, Faculty of Medicine, Universitas Airlangga, Dr. Soetomo General Academic Hospital, Surabaya, Indonesia;²Department of Pathology Anatomy, Faculty of Medicine, Universitas Airlangga, Dr. Soetomo General Academic Hospital, Surabaya, Indonesia;³Department of Public Health Sciences, Faculty of Public Health, Universitas Airlangga, Surabaya, Indonesia;

*Corresponding author:

Yulia Primitasari;
Department of Ophthalmology, Faculty of Medicine, Universitas Airlangga, Dr. Soetomo General Academic Hospital, Surabaya, Indonesia;
yulia.spm@gmail.com

Received: 2022-09-08

Accepted: 2022-10-15

Published: 2022-11-09

INTRODUCTION

Socket contracture is a common problem after socket surgery. The contracted socket is caused by fibrosis leading to the shortening of the orbital tissue.^{1,2} Chawla U et al. stated that from 10 socket surgeries performed, there was one complication of socket contracture.³ A socket contracture will harm the patient in terms of cost, time, and psychological because of an eye prosthesis that cannot be installed, eyelid abnormalities, and repeated surgeries.¹ Improper wound healing process can cause scar tissue, resulting in socket contractures. The wound healing process requires several growth factors, including vascular endothelial growth factor (VEGF).⁴ Vascular endothelial growth factor is important in angiogenesis and scar formation. The role of VEGF in the

phase of scar formation by stimulating fibroblasts, endothelial cells, and inflammatory cells. Thus, VEGF is a profibrotic factor in the postoperative wound healing process.⁵

Several studies to find the prevention of fibrosis have been carried out. In their research, Tawfik HA et al. stated that administering a single injection of MMC, 5-fluorouracil, and triamcinolone in socket surgery showed promising results in reducing myofibroblast activity.⁷ Mitomycin C (MMC) is one of the antimetabolite agents used to inhibit fibroblasts. Triamcinolone acetonide (TCA) is an anti-inflammatory, glucocorticoid group that can reduce fibroblast activity to prevent recurrence in pterygium surgery.⁸ MMC has side effects such as chemosis, delayed conjunctival

healing, and thinning of the sclera to scleral melting. Meanwhile, TCA has the side effect of increasing intraocular pressure and thinning the sclera.⁶

The novel option to prevent fibrosis is using fibrin glue, which has been widely applied in the field of ophthalmology. Fibrin glue has been used in trabeculectomy, pterygium, strabismus, and vitrectomy operations.⁹ Fibrin glue is autologous, inexpensive, non-toxic, easy to decompose, and safe because minimal rejection reactions occur. However, the effectiveness of fibrin glue in socket surgery has not been studied.^{10,11} Our research aims to determine the effect of fibrin glue as an alternative anti-fibrotic agent on the evisceration of rabbit models versus MMC and TCA on VEGF expression as a marker of fibrosis.

METHODS

Study design, ethical clearance, and subject recruitment

We conducted an in vivo experimental study using an animal model. We used twenty male white rabbit species, New Zealand breed, weighing between 2.5 - 3.5 kg, the age range of 4-6 months in the study. This research was approved by the Institutional Animal Care and Use Ethics Committee of the Faculty of Veterinary Airlangga University. A veterinarian ensured healthy samples and animals had diseases excluded from this study. The dropout criteria are when the rabbits become ill, die, and have complications such as scleral perforation, infection, and bleeding during and after surgery. The study was done from February until July 2022.

We distributed the animals into four experimental groups by simple random sampling, with five eyes per group. Each animal underwent surgery and received different treatments in the operated eyes. The treatment was performed at the mid-superior bulbar conjunctiva close to the vertical meridian at the inferior fornix with an injection of medication. In the control group, we not applied treatment. We administered 0.1 ml of mitomycin-C (Mito*10, NEON, India) 0.4 mg/ml in the MMC group. In the Triamcinolone Acetonide (Flamicort, DexaMedica, Indonesia) group, we administered 0.1 ml of TCA 40 mg/ml. In the fibrin glue group, we administered 0,1 ml of fibrin glue.

All animals underwent evisceration in one eye randomly, under sterile conditions, by the same surgeon, using the same technique. Topical anesthesia was administered with 2% tetracaine hydrochloride (Pantocaine*) eye drops in all eyes, then 5 mg/kg xylazine (Xylazine 20, Pantex, Holland) and 30 mg/kg to 50 mg/kg ketamine-HCL (Keta-A-100, Agrovot Market S.A., Peru) was administered intramuscularly. A circular conjunctival peritomy was performed, excision of the corneal was performed, then removing the contents of the eyeball were with an evisceration spoon. Finally, scleral and conjunctival wounds were sutured using 6.0 polyglactin (Vicryl™, Ethicon, US). At the end of the procedure, we instilled

antibiotic chloramphenicol ointment was applied to the conjunctiva.

On day 14 after surgery, we sacrificed rabbits' conjunctiva, and Tenon capsule samples were carefully harvested and cut uniformly, approximately 10mm x 10mm near site injection. We stained the material with Hematoxylin & Eosin (HE) for all animals and evaluated the region of the operated conjunctiva H&E staining was done on each serial section sample.⁷

Fibrin Glue Preparation

A sterile sput with CPDA (Citrate Phosphate Dextrose Adenine) in a 9:1 ratio was prepared from rabbit's blood with a total volume of 40 ml. To concentrate the plasma, the blood was placed in a sterile 10 mL centrifuge tube and centrifuged for 15 minutes at 3000 rpm. The plasma portion was stored in a sterile centrifuge tube at -20°C for 24 hours. Then the second centrifugation was performed at 4°C, 3000 rpm for 15 minutes. After the second centrifugation, the upper 2/3 of the plasma was stored as much as 10 ml to prepare the fibrinogen component. The lower 1/3 (PRP) was stored in sterile micro-tubes to be prepared as a material for thrombin production. The upper 2/3 of the plasma was added with 95% ethanol, as much as 1 ml and then incubated at 4°C for 30 minutes; then third centrifugation was carried out at 4°C at 3000 rpm for 15 minutes. The sediment was used as a fibrinogen component, while the supernatant was discarded. A 0.05ml of 10% CaCl₂ was added to the PRP component to create thrombin. Fibrin glue was made by mixing fibrinogen and thrombin in a ratio of 1:1.^{12,13}

Immunohistochemistry examination

Conjunctival samples that had been formalin-fixed and paraffin-embedded were cut into four-micrometer slices. Monoclonal Vascular Endothelial Growth Factor antibody (ARG10513) (Arigobio laboratories, Inc., USA) was prediluted to 1:1000 dilution for immunohistochemical staining, and a Leica Bond Max - Fully Automated IHC/ISH Staining equipment was used. The expression of VEGF was located in the epithelium and vascular endothelium.

Quantification of cell

Semi-quantitative methods using immunoreactivity score (IRS) were used to analyze the expression of VEGF in conjunctival epithelium and vascular endothelium. IRS is a product of multiplication between positive cells proportion score and staining intensity score. The pathologist conducted this at ×400 magnification. There is only one pathologist to analyze the expression of VEGF. To reduce bias, the pathologist carried out this technique on serially numbered slides in a blinded manner using an Olympus microscope (Cx51) equipped with an Olympus camera using SIS software (Japan, Tokyo).

Statistical Analysis

The pathologist provided the data in an Excel spreadsheet (Excel 2010, Microsoft Corporation, Redmond, WA, United States), and statistical analysis was carried out using SPSS software version 26 for Windows (IBM Corporation, New York, NY, U.S.A.). Data were assumed to follow a normal distribution. Differences in IRS scores between all groups were analyzed using ANOVA, followed by a Tukey post-test to analyze differences between the two groups. P value p<0.05 was considered statistically significant.

RESULTS

There was a statistically significant difference in VEGF expression between the control group, MMC, TCA and fibrin glue group with a p-value 0.000 (p<0,05). Mean VEGF expression was highest for the control group, followed by fibrin glue, TCA and lowest expression for the MMC group, as stated in Table 1.

Based on the Immuno Reactive Score (IRS) of VEGF, there was a significant difference in VEGF expression in the MMC group (p=0.001), the TCA group (p=0.002), and the fibrin glue group (p=0.005) compared with the control group as seen in Figure 1, 2, 3 and 4. There was no significant difference in IRS of the MMC group compared to TCA (p=0.973) and Fibrin Glue (p=0.754) (Figure 2), TCA group compared to the fibrin glue group (p=0.940) (Figure 3).

Table 1. Statistical comparison of VEGF expression in all of the studied groups.

Groups	n	IRS score of VEGF (Mean ± SD)	p
Control	5	9,60 ± 2,51	0.000
Mitomycin C	5	2,60 ± 1,34	
TCA	5	3,20 ± 2,77	
Fibrin Glue	5	4,00 ± 3,51	

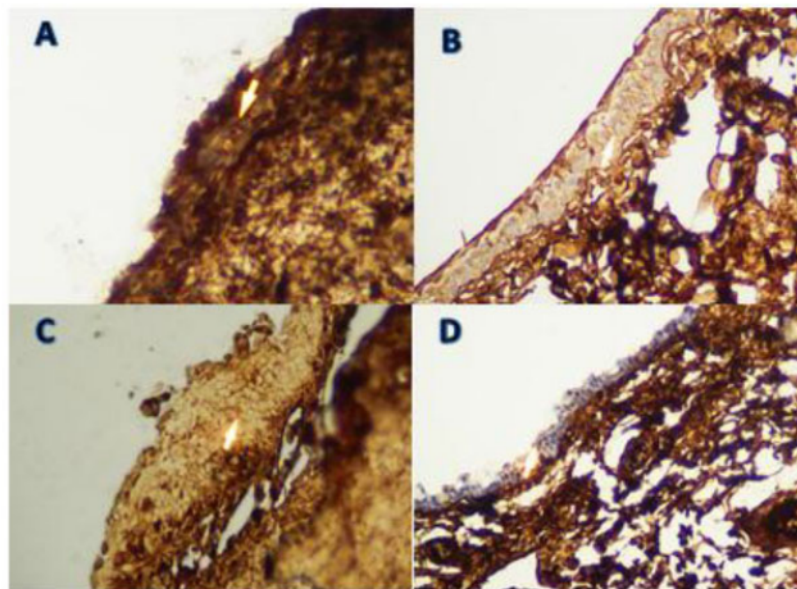


Figure 1. The IHC section. The expression of VEGF is indicated by arrows which are staining intensity in conjunctival epithelial cells. The control group (A) had the strongest intensity of VEGF expression. The MMC group (B) had the weakest intensity of VEGF expression. TCA group (C), fibrin glue group (D).

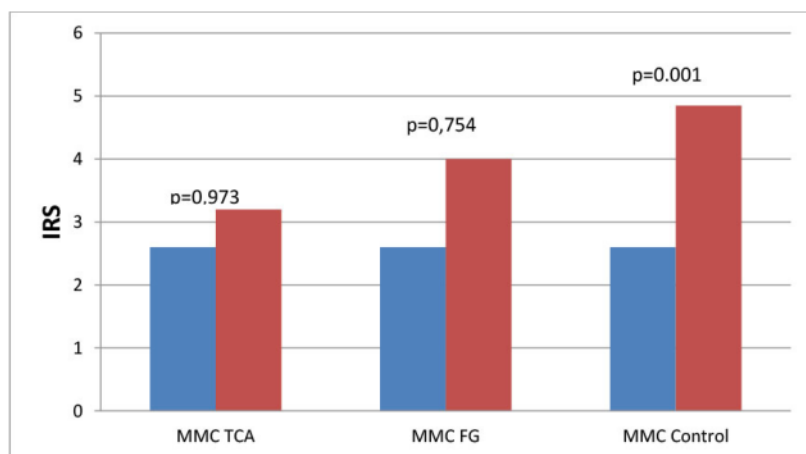


Figure 2. Comparison of the VEGF level in the mitomycin-C (MMC) group with the triamcinolone acetone (TCA) group, the fibrin glue (FG) and the control group using immunoreactivity score (IRS).

DISCUSSION

Socket contracture is caused by fibrosis leading to the shortening of the orbital tissue.¹ A wound healing process that is not good can cause scar tissue that results in socket contractures. Growth factors and fibroblasts play an essential role in wound healing.^{2,5} Several studies have been conducted to determine the prevention of fibrosis that causes socket contractures, such as Mitomycin C, 5 FU, and Triamcinolone acetonide.⁷ Some of these therapies have toxic side effects, are difficult to obtain and are less potent, so alternative treatments are needed that can be isolated autologously, are inexpensive, non-toxic, easily decomposed, and safe.^{6,14}

Our study obtained the Immunoreactivity Score (IRS) results, which described VEGF expression in each study group. The average order of VEGF expression results from highest to lowest were the control group, fibrin glue, Triamcinolone acetonide (TCA), and MMC. Statistically, there was a difference between all research groups with $p=0.000$ ($p<0.05$). In the differences between the two groups, there were statistically significant differences between the control group and each treatment group. In contrast, the differences between each treatment group were not statistically significant.

The effect of MMC and TCA on VEGF was also studied by Rangel HM et al. Their study was an experimental laboratory study using 30 New Zealand rabbits who researched the wound healing process in trabeculectomy, then measured VEGF expression by measuring vascular proliferation. The results showed that the highest VEGF expression was in the control group, followed by the TCA group. The lowest was found in the MMC group on the 14th day of measurement. The results of this study are the same as our results.¹⁵ Another study investigated the effect of TCA on VEGF expression. Hatta et al., 2020. In this study, ten patients with pterygium were divided into two groups; the first group was given TCA subconjunctival injection, and the second group was given a saline injection

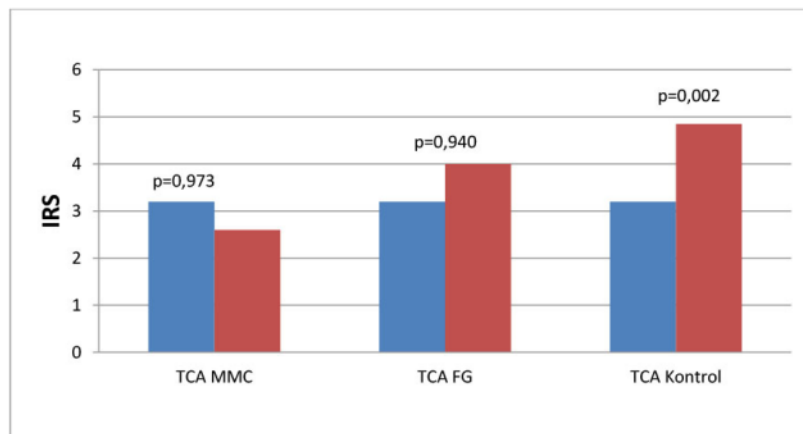


Figure 3. Comparison of the VEGF level in the triamcinolone acetone (TCA) group with the mitomycin-C (MMC) group, fibrin glue (FG) group and control group using immunoreactivity score (IRS).

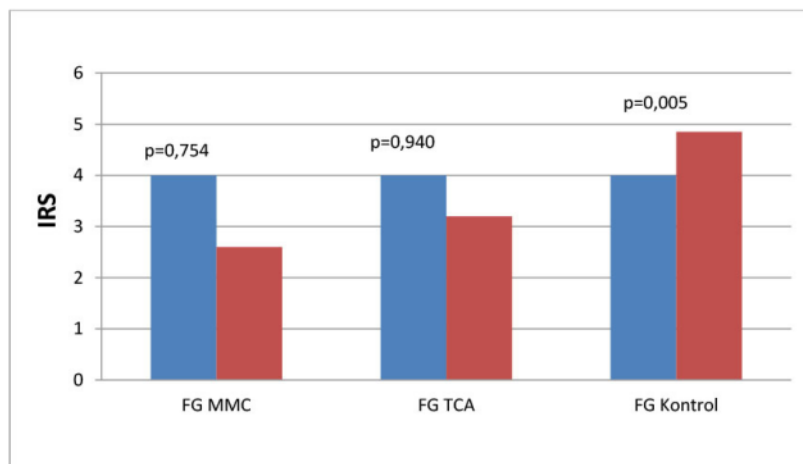


Figure 4. Comparison of the VEGF level in the fibrin glue (FG) group with mitomycin-C (MMC) group, triamcinolone acetone (TCA) group and control group using immunoreactivity score (IRS).

(placebo) a week before the excision of pterygium. One month after surgery, the VEGF mRNA expression was measured for each study sample. This study concluded that there were statistically significant differences in the first group (TCA), namely lower inflammatory reactions and recurrence rates than placebo.⁸

Research on the effect of fibrin glue on profibrotic factor VEGF has never been done before. VEGF modulates both direct and indirect wound healing mechanisms. In an indirect mechanism, VEGF modulates the recruitment and migration of macrophages. VEGF also stimulates

the formation of endothelial cells for the process of angiogenesis. In direct mechanism, VEGF stimulates fibroblast production for collagen production and degradation.^{5,17} MMC can inhibit angiogenesis and fibroblast proliferation by inhibiting NLRP3/Caspase 1 and other inflammatory factors such as TGF- β and VEGF.¹⁸ TCA as an anti-inflammatory agent, inhibits inflammation and angiogenesis from VEGF receptors by inhibiting the production rate of VEGF.¹⁹ Fibrin-contained fibrin glue exerts a protective effect on macrophages, inhibits the secretion of inflammatory cytokines

and expresses Interferon-g (IFN γ). IFN γ also functions as anti-angiogenesis.^{20,21}

MMC and TCA have also been shown in several studies to reduce fibrosis in experimental animals, fibroblast cell cultures, and clinical studies in humans.^{1,7,10,11} However, both of these agents have drawbacks, including not being widely available, expensive, and having side effects of use.⁶ The demand to be able to find alternative anti-fibrotic agents that are potent, safe, inexpensive, and easily accessible have been carried out by conducting various studies. Fibrin glue was initially used to induce fibrosis in wounds in our research and, in previous studies, has been shown to inhibit fibrosis activity.^{10,11,16} Fibrin glue autologous or from donors has advantages over commercial products, including biocompatible, biodegradable, easy and inexpensive isolation techniques, minimal risk of virus contamination, and safety.¹⁴ Our study is the first study that assessed the fibrin glue's impact on VEGF expression. Statistical tests in our study showed no significant differences in the expression of VEGF in the MMC treatment group and the fibrin glue treatment group. Based on the descriptions of several studies above, it can conclude that fibrin glue could be an alternative therapy option as an anti-fibrotic agent in eye procedures, especially socket contractures.

The main limitation of this study is the relatively short observation time of observations which only evaluated the VEGF expression at one time (day 14) and did not evaluate the complete healing phase. The other profibrotic markers, such as matrix metalloproteinase (MMP) and collagen, were not assessed. Future research suggests that a more extended evaluation day is needed to evaluate the difference in the expression on the 7th day, 14th day, and 21st day. Based on the results of this study, clinical trials in humans can be carried out in future studies by evaluating clinical appearance, for example, fornix depth and socket volume.

CONCLUSION

Our study concludes that the administration of Fibrin Glue, Mitomycin C, and Triamcinolone Acetonide in evisceration surgery reduces VEGF

expression in cells that play a role in the inflammatory process. This potential decrease can prevent the occurrence of fibrosis in socket contractures. Fibrin glue can be considered an alternative anti-fibrotic agent besides MMC and TCA.

ETHICAL CONSIDERATION

This research was conducted based on the ethical conduct of research from the institutional review board.⁵ The animal laboratory work used in this study was approved and supervised by the Animal Ethics Committee at Universitas Airlangga Faculty of Veterinary Medicine.

CONFLICT OF INTEREST

There is no conflict of interest regarding the manuscript.

FUNDING

The authors are responsible for the study's funding without the involvement of a grant, scholarship, or any other funding resource.

AUTHOR CONTRIBUTIONS

All authors equally contribute to the study from the conceptual framework, data acquisition, and data analysis until reporting the study results through publication.

REFERENCES

- Mattout HK, Fouda SM, Al-Nashar HY. Evaluation of Topical Mitomycin-C Eye Drops After Reconstructive Surgery for Anophthalmic Contracted Socket. *Clinical Ophthalmology* (Auckland, NZ). 2021;15:4621.
- Peseyie R, Raut AA. Contracted Socket. InStatPearls [Internet]. 2022 Jan 1. StatPearls Publishing.
- Chawla U, Anand N, Gupta R, Chadha G, Khurana AK. Epidemiology of Oculoplastic Surgeries Performed at Tertiary Eye Care Hospital in Northern India. *Epidemiology*. 2021;9(4).
- O'Neill CJ, Oucharek J, Learoyd D, Sidhu SB. Standard and emerging therapies for metastatic differentiated thyroid cancer. *The oncologist*. 2010;15(2):146-56.
- Wilgus TA. Vascular endothelial growth factor and cutaneous scarring. *Advances in Wound Care*. 2019;8(12):671-8.
- Verma A, DeGrado J, Hittelman AB, Wheeler MA, Kaimakliotis HZ, Weiss RM. Effect of mitomycin C on concentrations of vascular endothelial growth factor and its receptors in bladder cancer cells and in bladders of rats intravesically instilled with mitomycin C. *BJU international*. 2011;107(7):1154-61.
- Tawfik HA, Abdulhafez MH, Fouad YA, Rashed HO, Osman WM. Revisiting the role of the myofibroblast in socket surgery: an immunohistochemical study. *Ophthalmic Plastic and Reconstructive surgery*. 2016;32(4):292.
- Hatta M, Massi MN, Natzir R, Ichsan AM. The effectiveness of triamcinolone injection on risk of postoperative operations with the conjunctiva autograft technique and its association with change of VEGF mRNA expression. *Biomedical and Pharmacology Journal*. 2020;13(2):543-9.
- Panda A, Kumar S, Kumar A, Bansal R, Bhartiya S. Fibrin glue in ophthalmology. *Indian journal of ophthalmology*. 2009;57(5):371.
- Komaratih E, Suhendro G, Prakoeswa CR, Rindiastuti Y, Hendrianto E, Susilowati H, Rantam FA. Fibrin Glue Maintain Limbal Mesenchymal Stem Cells Survival: A Novel Cell-Based Therapy Strategy for Modulating Wound Healing After Trabeculectomy. *Saudi Journal of Biomedical Reserach*. 2019;4(1):11-7.
- Rindiastuti Y, Komaratih E, Susilowati H, Soebagyo HD, Rantam FA. Fibrin Glue (FG) Attenuates Fibrosis on Human Tenon's Fibroblasts 9HTFS) of Glaucomatous Eyes: Comparison with Mitomycin C. *Biochemical and Cellular Archives*. 2019;19(Supp-2):4713-20.
- Ramadhan F, Jamaluddin J, Zuhria I, Indriaswati L, Komaratih E. Matrix Metalloproteinase-3 Down-Regulation and Cell Migration Inhibition in Human Pterygium Fibroblasts by Mitomycin-C, Curcumin and Fibrin Glue. *The Indonesian Biomedical Journal*. 2022;14(2):172-9.
- Abdurrauf M, Ramadhan F, Zuhria I, Tambunan BA, Notobroto HB, Surahman B, Komaratih E. Mitomycin C, curcumin, and fibrin glue inhibit the cell proliferation and expression of TGF- β in human pterygium fibroblast. *Bali Medical Journal*. 2022;11(1):228-33.
- Komaratih E, Rindiastuti Y, Susilowati H, Hendrianto E, Suhendro G, Rantam FA. Fibrin Glue (FG) Encapsulated Limbal Mesenchymal Stem Cells (LMSCS) Decrease Bleb Fibrosis Area After Trabeculectomy Through TGF- β and MMP-9 Modulation. *Asian Journal of Microbiology, Biotechnology and Environmental Sciences*. 2018; 20: 66-73.
- Rangel HM, Rolim HT, Vidigal P, Araújo ID, Cronemberger S. Healing modulation in glaucoma surgery after application of subconjunctival triamcinolone acetate alone or combined with mitomycin C: an experimental study. *Revista do Colégio Brasileiro de Cirurgiões*. 2018;45.
- Sakarya Y, Sakarya R, Kara S, Soyulu T. Fibrin glue coating of the surgical surfaces may facilitate formation of a successful bleb in trabeculectomy surgery. *Medical Hypotheses*. 2011;77(2):263-5.
- Bao P, Kodra A, Tomic-Canic M, Golinko MS, Ehrlich HP, Brem H. The role of vascular endothelial growth factor in wound healing. *Journal of Surgical Research*. 2009;153(2):347-58.
- Guo Q, Li X, Cui MN, Liang Y, Li XP, Zhao J, Wei LN, Zhang XL, Quan XH. Low-dose mitomycin C decreases the postoperative recurrence rate of pterygium by perturbing NLRP3 inflammatory signalling pathway and suppressing the expression of inflammatory factors. *Journal of Ophthalmology*. 2019;2019.
- Tong JP, Lam DS, Chan WM, Choy KW, Chan KP, Pang CP. Effects of triamcinolone on the expression of VEGF and PEDF in human retinal pigment epithelial and human umbilical vein endothelial cells. *Mol Vis*. 2006;12(12):1490-5.
- Sungkar A, Widyatmoko D, Yarso KY, Wasita B. The effect of duration of wound skin tissue on MDA, TNF- α , IL-6, Caspase 3, VEGF levels, and granulation tissue thickness in the white rat (*Rattus norvegicus*). *Bali Medical Journal*. 2020; 9(3): 918-923.
- Hsieh JY, Smith TD, Meli VS, Tran TN, Botvinick EL, Liu WF. Differential regulation of macrophage inflammatory activation by fibrin and fibrinogen. *Acta biomaterialia*. 2017; 47:14-24.



This work is licensed under a Creative Commons Attribution

Fibrin Glue: An Anti-Fibrotic Agent For Contracted Socket

ORIGINALITY REPORT

17%

SIMILARITY INDEX

12%

INTERNET SOURCES

9%

PUBLICATIONS

5%

STUDENT PAPERS

PRIMARY SOURCES

- | | | |
|---|---|----|
| 1 | Hatem A. Tawfik, Mohamed H. Abdulhafez, Yousef A. Fouad, Hazem O. Rashed, Wesam M. Osman. "Revisiting the Role of the Myofibroblast in Socket Surgery: An Immunohistochemical Study", <i>Ophthalmic Plastic & Reconstructive Surgery</i> , 2016
Publication | 2% |
| 2 | Submitted to Universitas Nahdlatul Ulama Surabaya
Student Paper | 2% |
| 3 | isainsmedis.id
Internet Source | 2% |
| 4 | www.ijscia.com
Internet Source | 1% |
| 5 | I. Kanellos, E. Christoforidis, D. Kanellos, M. G. Pramateftakis, L. Sakkas, D. Betsis. "The healing of colon anastomosis covered with fibrin glue after early postoperative intraperitoneal chemotherapy", <i>Techniques in Coloproctology</i> , 2006
Publication | 1% |
-

6	Submitted to Universitas Muhammadiyah Yogyakarta Student Paper	1 %
7	biomedpharmajournal.org Internet Source	1 %
8	thejns.org Internet Source	1 %
9	www.hindawi.com Internet Source	1 %
10	www.frontiersin.org Internet Source	<1 %
11	www.mdpi.com Internet Source	<1 %
12	Submitted to Universitas Diponegoro Student Paper	<1 %
13	Purnamanita Syawal, Budu Budu, Mochammad Hatta, Muhammad Nasrum Massi, Andi Muhammad Ichsan, Rahmawati Minhajat. "Comparison between the triamcinolone and bevacizumab subconjunctivals and changes in Interleukin-1 mRNA expression in pterygium", Journal of Taibah University Medical Sciences, 2021 Publication	<1 %
14	doaj.org Internet Source	<1 %

15	e-journal.unair.ac.id Internet Source	<1 %
16	ism.ir Internet Source	<1 %
17	repository.unusa.ac.id Internet Source	<1 %
18	sciendo.com Internet Source	<1 %
19	www.sciencegate.app Internet Source	<1 %
20	Rajen Tailor, Konstantinos T. Tsaousis, Lei-Ai Lim, Keith Barton. "The use of fibrin glue during aqueous shunt surgery", Eye, 2020 Publication	<1 %
21	WAI-MAN CHAN, TIMOTHY Y.Y. LAI, KWOK-PING CHAN, HAITAO LI, DAVID T.L. LIU, DENNIS S.C. LAM, CHI-PUI PANG. "CHANGES IN AQUEOUS VASCULAR ENDOTHELIAL GROWTH FACTOR AND PIGMENT EPITHELIAL-DERIVED FACTOR LEVELS FOLLOWING INTRAVITREAL BEVACIZUMAB INJECTIONS FOR CHOROIDAL NEOVASCULARIZATION SECONDARY TO AGE-RELATED MACULAR DEGENERATION OR PATHOLOGIC MYOPIA", Retina, 2008 Publication	<1 %

22	scholar.unair.ac.id Internet Source	<1 %
23	www.researchsquare.com Internet Source	<1 %
24	www.scitepress.org Internet Source	<1 %
25	"20th ECP", <i>Virchows Archiv</i> , 2005 Publication	<1 %
26	Bangtao Yao, Fei Wang, Xiaogui Zhao, Bei Wang, Xiaoli Yue, Yuhua Ding, Gang Liu. "Effect of a Topical Nonsteroidal Anti-Inflammatory Drug (0.1% Pranoprofen) on VEGF and COX-2 Expression in Primary Pterygium", <i>Frontiers in Pharmacology</i> , 2021 Publication	<1 %
27	Mohammad Umar Khan, Parakh Basist, Gaurav, Sultan Zahiruddin, Naveen Reddy Penumallu, Sayeed Ahmad. "Ameliorative effect of traditional polyherbal formulation on TNF- α , IL-1 β and Caspase-3 expression in kidneys of wistar rats against sodium fluoride induced oxidative stress", <i>Journal of Ethnopharmacology</i> , 2024 Publication	<1 %
28	journals.plos.org Internet Source	<1 %

Exclude quotes Off

Exclude matches Off

Exclude bibliography On

Fibrin Glue: An Anti-Fibrotic Agent For Contracted Socket

GRADEMARK REPORT

FINAL GRADE

/0

GENERAL COMMENTS

Instructor

PAGE 1

PAGE 2

PAGE 3

PAGE 4

PAGE 5