

VOL 96 No. 02 FEBRUARY, 2019

Print ISSN 0019 - 6479

E - ISSN 0974 - 9365

₹. 80

THE INDIAN VETERINARY JOURNAL

SINCE - 1924

Journal of the
INDIAN VETERINARY ASSOCIATION

ESTD - 1922

Regd. No. Sl. No. 96/1967



No. 11, Muthuramalinga Thevar Salai (Chamiers Road),
Nandanam, Chennai - 600 035, Tamil Nadu, India

Tel. : +91 44 2435 1006

Email : ivj83@yahoo.com

ONLINE : www.ivj.org.in

THE INDIAN VETERINARY JOURNAL

(Official organ of the Indian Veterinary Association)

Vol. 96

February 2019

No. 02

CONTENTS

GENERAL ARTICLES :

Peripheral Blood of Koi Fish (<i>Cyprinus carpio</i>) Infested by <i>Argulus japonicus</i> in Mungkid and Muntilan District, Magelang, Central Java Kismiyati, Rinca Purnamawati, Ratih Dwi Yunikasari, Sri Subekti, Putri Desi Wulan Sari and Muhammad Browijoyo Santanumurti	... 09
In vitro Evaluation of Acaricidal Property of <i>Acalypha Indica</i> (Kuppaimeni) against Ticks Infesting Sheep B. Rubinibala and G.Ponnudurai	... 12
Dietary Supplementation of different Sources of Selenium on the Production Performance of Japanese Quail (<i>Coturnix coturnix japonica</i>) S. Divya, K. Premavalli, R. Richard Churchil, A.V. Omprakash, K.Vijayarani and G.Srinivasan	... 15
The Effect of OCRA (<i>Abelmoschus esculentus</i>) Ethanolic Extract on Leydig Cells in <i>Mus musculus</i> Prisylia Shintaningrum, Rimayanti and Widjiati	... 19
Goat Farming Systems in Southern Agro-Climatic Region of Tamil Nadu S.Vasantha Kumar and V.Ramesh Saravana Kumar	... 21
Toxic Insult of Methyl Mercury on Testicular Parenchyma in Rats V. Karunasri, Y. Nagamalleswari, P.V.S. Kishore and M.Raghunath	... 24
Herbal Formula for Control of Ectoparasites in Goats M.Sakthi Priya and B.Mohan	... 27
Changes in Plasma Concentrations of Estrogen and Progesterone During Pre-Partum Cervico Vaginal Prolapse in <i>Bos Indicus</i> (Cattle) K. Rajamanickam, M. Sameer Ali and V. Leela	... 30
Popularization of Nandanam Broiler Chicken-3 in Tiruvannamalai District and Study on its Weight Gain in Different Systems of Rearing C.Theophilus Anand Kumar, C.M. Jaikanth and R. Durairajan	... 32
Gross Pathology of Traumatic Reticulopericarditis and Peritonitis in Cattle K. Sasikala, G.A. Balasubramaniam, G. Vijayakumar and S. Sivaraman	... 34
Echocardiographic Evaluation of Pericardial Diseases in Dogs V.Vibin, D.Sumathi, K.Jeyaraja, A.P.Nambi and M.Venketesan	... 37
Clinico-Pathological Features of Canine Mammary Tumour with Concurrent Occurrence of Pyometra K.P.Prabhakaran, G.A.Balasubramaniam, R.Madheswaran, A.Raja, A.Kumaresan and P.Visha	... 41
Highest Cost Efficacy of TramPac on the Performance of Commercial Broilers D. Chandrasekharan, P.S. Shiva, and J. Sujith Reddy	... 44
Prevalence of Trematodes on Red Snapper (<i>Lutjanus argentimaculatus</i>) in Floating Net Cages at Lampung, Indonesia Sri Subekti, M. Kholiqul Amin and Kismiyati	... 46
<i>Neobenedeniagirellae</i> from Cultured Silver Pompano (<i>Trachinotus blochii</i>) in Floating Net Cages at Marine Culture Lombok, West Nusa Tenggara, Indonesia Ilham Fajar Aryadi, Nabilla Tri Buana Dewi, Al FathThoriq Arrizal, Dini Rahayuning Mardika, Panji Aulia Syahputra, Sri Subekti and Gunanti Mahasri	... 49
Effect of Processing on Ricin Activity in Raw and Processed Castor (<i>Ricinus Communis</i>) Bean Meal by Haemagglutination Test U.D. Wandkhade and S.K. Saha	... 52

CLINICAL ARTICLES :

Surgical Management of a Rare Angiofibroma on Tail in a Cow R. Uma Rani, R. Kalaijan and N. Pazhanivel	... 55
Oesophageal Obstruction Due to Phytobezoar in a Crossbred Cow V.Vijayanand, M.Shiju Simon, A.Methai, S.Kavitha and T.Sathiamoorthy	... 56
Successful Surgical Management of Urolithiasis Induced Cystorrhesis in a Tom Cat V. Bhuvaneshwari and M. Madeena Begum	... 58
Surgical Treatment for Mammary Gland Adlnocarcinoma in a Bitch V. Bhuvaneshwari and M. Madeena Begum	... 59
Dystocia Due to Arthrogryposis Foetus in a Goat M. Murugan, A. Ganesan, Chhavi Gupta and S. Satheshkumar	... 61
Dystocia Due to Primary Uterine Inertia in a Beagle Bitch – A Case Report A.Reshma, A.J.Shankare Gowda and Imama Hussain Gudur	... 63
Subinvolution of Placental Sites in a Labrador Bitch – A Case Report A.Reshma, A.J.Shankare Gowda and Imama Hussain Gudur	... 64
Successful Therapeutic Management of Healthy Diabetic Ketoacidosis in a Dachshund – A Case Report K.K. Ponnu Swamy, C. Lavanya, S. Sivaraman and R.Ezakial Napoleon	... 65
Successful Management of Electrocution in a Bonnet Macaque (<i>Maccaca Radiata</i>) Boon Allwin, Pa. Kalaigan and K. Sridhar	... 67
Pathomorphological Description of Mummified Fetus in a Bovine Clinical Case K.P.Prabhakaran, R.Madheswaran and G.A.Balasubramaniam	... 70
Therapeutic Management of Babesiosis in a Royal Bengal Tiger (<i>Panthera tigris tigris</i>) Boon Allwin, Bhaskaran Ravi Latha and M.G. Jayathangaraj	... 71
Surgical Management of Chronic Capped Elbow in Kathiawari Horse R.Thangadurai and S.Senthilkumar	... 74
Dystocia Due to Fetal Ascites in a Jersey Cross Bred Cow – A Case Report A.Thangamani, B.Chandra Prasad and M.Srinivas	... 75
A Rare Case of Mesothelioma in a Kangayam Bull – A Case Report K. Mohanambal, G. Vijayakumar, R. Madheswaran, B. Sudhakara Reddy, R. Ravi and S. Sivaraman	... 77
Diagnosis and Treatment of Urothelial Carcinoma in a Dog – A Case Report K. Mohanambal, G. Vijayakumar, R.Ravi, S. Sivaraman, B. Sudhakara Reddy and R.Madheswaran	... 79
Dystocia Due to Fetal Arthrogryposis in a Bannur Ewe – A Case Report A.Reshma, A.J.Shankare Gowda and Imama Hussain Gudur	... 80
Haemorrhagic Proctitis by Salmonellosis in a Cow – A Report M. Ranjithkumar, S. Krishnakumar, P. Arunachala Ramanan, B.S.M. Ronald and H. Pushkinraj	... 82

SHORT COMMUNICATIONS :

Supplementation of Licorice for Improving the Productivity and Livability in Vanaraja Birds P. Jalandha, P. Veeramani, B. Vasanthi and A. Ruba Nanthini	... 84
Increased Survival Rate of Buffalo Oocytes by Different Combination of Cryoprotectants and Vitrification Devices D. Reena, V. Dhanasekaran, D. Gopikrishnan, S.Rangasamy, S. Balasubramanian and A. Palanisammi	... 86
Tetanus Predisposed by Actinobacillosis in a Gir Cross Bred Cow S. Saravanan and K.M. Palanivel	... 88

Author and Subject Index

90 & 91

Prevalence of Trematodes on Red Snapper (*Lutjanus argentimaculatus*) in Floating Net Cages at Lampung, Indonesia

Sri Subekti¹, M. Kholiqul Amin and Kismiyati

Department of Marine, Faculty of Fisheries and Marine, Campus C, Universitas Airlangga, Jalan Mulyorejo, Surabaya 60115, Indonesia.

(Received : March, 2018 74/18 Accepted : August, 2018)

Abstract

This study was designed to identify the prevalence of trematodes on red snapper (*L. argentimaculatus*) in floating net cages at Center for Marine culture, Lampung, South Sumatra, Indonesia. The prevalence of trematodes in floating net cages was 83.33%. Among them *H. epinepheli* was 26.66%, and there were 50% mixed infestation with two species *B. epinepheli* and *H. epinepheli* and the other mixed infestation by three species of trematodes *B. epinepheli*, *N. girellae* and *H. epinepheli* were 6.67%.

Key words: Trematodes, floating net, Prevalence, Indonesia.

Only a few of red snapper (*L. argentimaculatus*) have been produced from aquaculture. Trematodes worms that often attacked red snapper are *B. epinepheli* found on the fins and skin (Jithendran *et al.*, 2005), *N. girellae* (Zafran *et al.*, 1998). *Haliotrema* spp., *Diplectanum squamatum* (Santos *et al.*, 2002). This study was carried out on red snapper (*L. argentimaculatus*) fish at Center for Marine culture, Lampung, Indonesia.

Materials and Methods

Approximately 30 fish with measuring 25-35 cm (20% of the fish captured population) (Barreiro and Albandoz, 20010). Fishes were subsequently taken to a Fish Health Laboratory, Center of Marine culture Lampung for trematodes identification. Trematodes were observed under a microscope on red snappers body surface, skin, gills, fins and operculum (Martins, *et al.*, 2015). By scrapping gills (native method) (Noga, 2010) observation was drawing and with a microscope equipped with camera lucida.

Results and Discussion

Prevalence of the trematodes was presented in Table I the results of the study revealed that there were three species of trematodes, *Benedenia epinepheli*, *Neobenedenia girellae*, and *Haliotrema epinepheli*.

Benedenia epinepheli parasite was found on the body surface (Fig 1), particularly in the dorsal, ventral, anal, caudal fins and skin of red snapper fish. This parasite is dorso-laterally flat and has a pair of attachment organ and opisthaptor in posterior body, and has a wavy shaped pharynx. This trematode is similar to the finding of Jithendran *et al.* (*loc. cit*) who found *B. epinepheli* from Indian ocean state declared that this species has sucker in anterior and opisthaptor with two pairs of hamuli and a pair of accessory sclerite in posterior body. Ogawa *et al.* (1995a) stated that the total body length of *B. epinepheli* is 1.5 - 3.0 mm and body width is 0.8-1.6 mm.

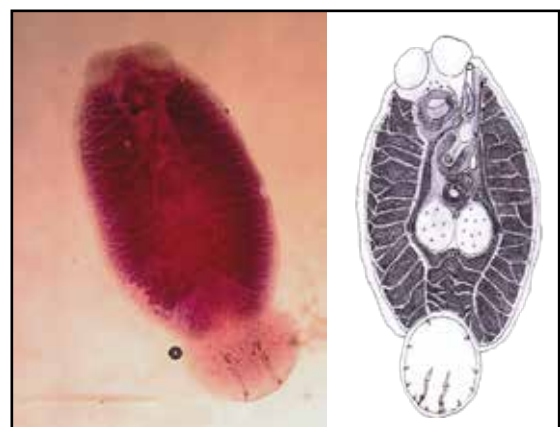


Fig 1. *Benedenia epinepheli* adult (magnification 40x; bar scale 216 mm), with Semichoen Carmine staining and *B. epinepheli* adult (bar scale 281 mm), drawing with Camera Lucida.

¹Correspondence author : Email : srisubektiunair@gmail.com

Table I. Prevalence of *B. epinepheli*, *N. girellae* and *H. epinepheli* trematode in floating net cages of red snappers at Center for Marine culture

No	Trematodes species	Total fish infested		Total	Prevalence (%)
		Single infestation	Mixed infestation		
1	<i>B. epinepheli</i> x <i>N. girellae</i> x <i>H. epinepheli</i>	0	2	2	6.67
2	<i>B. epinepheli</i> x <i>H. epinepheli</i>	0	15	15	50.00
3	<i>H. epinepheli</i>	8	0	8	26.66
Total		8	17	25	83.33

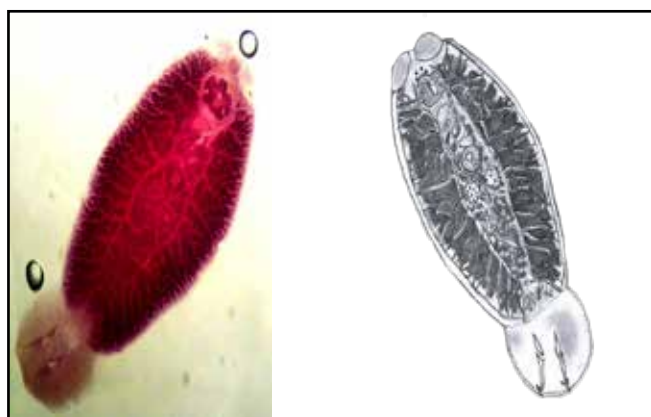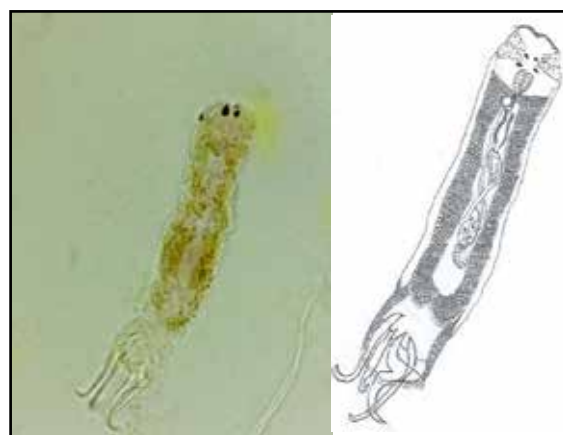Neobenedenia girellae belongs to a class Trematoda was found to be attached to dorsal fin and head skin of red snapper fish. It has a elongated rounded body with a length of 5.5 mm. *N. girellae* have a pair of anterior attachment organs, two sets of eyes, posterior portion is greater than the anterior part of the eye, which concurs the description of Ogawa *et al.* (1995 a) who stated that *N. girellae* was flatly elongated round with total length and width of the body was 3.6-5.6 mm and 1.8-3.1 mm with the thickness of 0.8- 1.3 mm and has a pair of *attachment organ* and flower shaped pharynx. *Neobenedenia girellae* found infesting skin of head only. The high infestation can cause death of fish. Ogawa *et al.* (2006) found the parasite on the skin and also in the eye which causes blindness (Fig 2).

Haliotrema epinepheli is classified under the order Monopisthocotylea and Dactylogyridae family. This trematode was ovoid in the anterior part with two pairs of eye spots and a pair of posterior part of the eye is little larger. *Halio-*

trema epinepheli has a copulatory organ which is different from other Dactylogyridae families. Klassen, (1991) stated that *H. epinepheli* has *haptor sclerities* on the posterior part of the body. They have an average body length of 200.8 µm and elongated body. The posterior part of the body is equipped with opisthaptor and two pairs of anchors (Fig 3).

The prevalence of trematodes was 83.3%, among them the mixed infestation was 56.67%, (*B. epinepheli*, *N. girrelae*; and *H. epinepheli* was group constituted to 6.67% and *B epinepheli* and *H epinepheli* was 50%). *H. epinepheli* has been reported infested grouper fish, species of genus *Epinephelus* that consists *E. fasciatus*, *E. malabaricus*, and *E. merra* species (Justine *et al.*, 2007).

The poor water quality and infestation of trematodes of fishes reared in floating net cages and high density the red snappers in the net cages can cause adverse effect on the immune

**Fig 2.** *N. girellae* adult (magnification 40x; bar scale 5,6 mm), With Semichoeh Carmine staining and *N. girellae* adult (bar scale 5,8 mm), drawing with Camera Lucida.**Fig 3.** *H. epinepheli* adult (magnification 40x; bar scale 146 µm), with Semichoeh Carmine staining and *H. epinepheli* adult (bar scale 200 µm), drawing with Camera Lucida.

system of the fish. The water quality monitoring on temperature, pH, salinity and dissolved oxygen were important criteria for successful sea farming. The floating net cages of Lampung were located in polluted water, contaminated by factory waste, household and industrial waste which were discharged near the cage farming location leading to reduction in water quality.

Summary

Based on identification of trematodes it is concluded that, the red snapper (*L. argentimaculatus*) is infested with *B. epinepheli*, *N. girellae* and *H. epinepheli*. Prevalence rate of trematodes was high (83.33%), which consisted of single infestation of *H. epinepheli* (26.66%), mixed of three infestation (6.67%); and mixed of two infestation *B. epinepheli* and *H. epinepheli* (50.00%).

References

- Barreiro, P. L. and J. P. Albandoz., (2001) Population and sample, sampling techniques. Management Mathematics for European Schools. University of Seville. pp. 1-19.
- Jithendrand. K. P, K. K. Vijayan, S. V. Alavandi and M. Kailasam., (2005) *Benedenia epinepheli* (Yamaguti 1937), A Monogenean Parasite in Captive Broodstock of Grouper, *Epinephelus tauvina* (Forsk.). *Asian Fisheries Science*, **18**: 121-126.
- Justine, J.L., (2007) Parasite biodiversity in a coral reef fish: Twelvespecies of monogeneans on the gills of the grouper *Epinephelus maculatus* (Perciformes: Serranidae) off New Caledonia, with a description of eight new species of *Haliotrema* (Monogenea: Diplectanidae). *Syst Parasitol*, **66**: 81-129.
- Klassen, G. J., (1991) Revision of *Haliotrema* species (Monogenea, Ancyrocephalidae) from Atlantic boxfishes (Tetraodontiformes, Ostraciinae)-morphology, morphometrics, and distribution. *Canadian J. Zoo*, **69(10)**: 2523-2539.
- Martins, Mauricio Laterça., Cardoso, Lucas., Marchiori, Natalia., de Pádua, Santiago Benites., (2015) Protozoan infections in farmed fish from Brazil: diagnosis and pathogenesis. *Braz. J. Vet. Parasitol., Jaboticabal*, **24(1)**: 1-20.
- Noga, E.J., (2010) Fish Disease Diagnosis and Treatment. 2nd Edition. Wiley-Balckwell. USA. pp. 538.
- Ogawa, K., J. Miyamoto, H. Wang, C. Lo and G. Kou., (2006) *Neobenedenia girellae* (Monogenea) Infection of Cultured Cobia *Rachycentron canadum* in Taiwan. *Fish Path*, **41(2)**: 51-56.
- Ogawa, K., M. G. Bondad and H. Wakabayashi (1995a) Redescription of *Benedenia epinepheli* (Yamaguti, 1937) Meservr, 1938 (Monogenea: Capsalidae) from cultured and aquarium marine fishes of Japan. *J. Fish. Aquat. Sci*, **52**: 62-70.
- Ogawa, K.M., M.G. Bondad-Reantaso, M. Fukudome and H. Wakabayashi (1995b) *Neobenedenia girellae* (Hargis, 1995) Yamaguti, 1963 (Monogenea; Capsalidae) From Cultured Marine Fishes of Japan. *J. Parasitol*, **81(2)**: 223-227.
- Santos C.P., T. James., and G. Dick., (2002) *Diplectanum squamatum* N. (Monogenea: Diplectanidae) from the gills of *Cynoscion guatucupa* (Sciecidae) in southwest Atlantic waters. *Syst. Parasitol*, **52(3)**: 199-204
- Zafran, Des Roza., D.I. Koesharyani, F.J Rivaee and K. Yuasa, (1998) Manual for Fish Disease Diagnosis, Marine Fish and Crustacean Disease in Indonesia. Gondol Research Station For Coastal Fisheries, Central Research Institute for Fisheries Agency for Agriculture Research and Development and Japan International Cooperation Agency (JICA).

Tariff

For Foreign Contributors:

Processing Fees : US \$ 20

Publication Charges : US \$ 200

Subscription Charges:

Subscriber details

Foreign individuals/Institutions

Print

US\$ 200

Online

US\$ 200

You may kindly send the payment through cheque/demand draft infavour of The Editor, Indian Veterinary Journal, payable at State Bank of India, Nandanam, Chamiers Road, Chennai - 600035, India. Alternately, the money also can be transferred through Western Union Money Transfer if such a facility is available.