

# 7

*by* Marina Hassan

---

**Submission date:** 08-Aug-2023 05:47PM (UTC+0800)

**Submission ID:** 2143043159

**File name:** 7.\_JIPK\_11\_2\_2019\_11-18.pdf (705.77K)

**Word count:** 3991

**Character count:** 22213



## Research Article

### The Toxic Effect of Ametryn on Behaviour and Histopathological Changes of Freshwater Eel (*Monopterus Albus*)

### Pengaruh Toksik Ametryn terhadap Perilaku dan Perubahan Histopatologis Belut Air Tawar (*Monopterus Albus*)

Marina Hassan<sup>\*1</sup>, Nor Azri Shah Norhan<sup>1</sup>, Wahidah Wahab<sup>1</sup>, Anur Abdalah Nagi Melad<sup>2</sup>, Kismiyati<sup>3</sup>, Mohd Fazrul Hisam Abd Aziz<sup>4</sup>, Norainy Mohd Husin<sup>1</sup>, Mohd Ihwan Zakariah<sup>1</sup>

<sup>1</sup>Institute of Tropical Aquaculture and Fisheries Research (AKUATROP), Universiti Malaysia Terengganu, 21030 Kuala Nerus, Malaysia

<sup>2</sup>Department of Biological Science, Faculty of Science, Azzaytuna University, Tarhunah, Libya.

<sup>3</sup>Department of Fish Health Management and Aquaculture, Faculty of Fisheries and Marine, Universitas Airlangga, Surabaya, Indonesia

<sup>4</sup>Faculty of Fisheries and Food Sciences, Universiti Malaysia Terengganu, 21030 Kuala Nerus, Terengganu, Malaysia.

#### ARTICLE INFO

Received: September 4, 2019

Accepted: October 20, 2019

\*) Corresponding author:

E-mail: [marina@umt.edu.my](mailto:marina@umt.edu.my)

#### Keywords:

*Monopterus albus*, herbicide, symptom, kidney, histopathological changes.

#### Kata Kunci:

*Monopterus albus*, herbisida, symptom, ginjal, perubahan histopatologi.

#### Abstract

A study on the toxicity of herbicides was investigated with emphasis on behaviour and histopathological effects. Ametryn commonly used to control weeds in paddy field. The effect of ametryn on fish especially *Monopterus albus* was unknown. This study aims to determine the acute toxicity of ametryn and its effects on the behaviour of the eels. The adult *M. albus* were exposed to 0, 0.75, 1.5 and 3.0mg/L of ametryn for 96 hours under laboratory conditions. The eels showed symptoms of abnormal behaviour responses during the exposure which are agitated behaviour, respiratory distress, and abnormal nervous behaviour. Mortality was increased by increasing the concentration of ametryn. This present study showed the effect of ametryn on kidney tissue changes. Hemorrhage and distribution of hemosiderin, hydropic degeneration, granular degeneration, tubular necrosis, narrowing tubular lumen and necrosis were major histopathological effects that occurred during the exposure to ametryn. In conclusion, ametryn is very sensitive to *Monopterus albus*. In lower concentration, they showed changes in behaviour and effect their organs.

#### Abstrak

Studi tentang toksisitas herbisida yang diamati dengan penekanan pada perilaku dan dampak histopatologis. Ametryn biasanya digunakan untuk mengawal rumpai di sawah padi. Kesan ametryn pada ikan terutama belut tidak diketahui. Penelitian ini bertujuan untuk menentukan toksisitas akut ametryn dan dampaknya terhadap perilaku belut. *M. albus* dewasa terpapar pada 0, 0.75, 1.5 dan 3.0mg / L ametryn selama 96 jam pada kondisi laboratorium. Belut menunjukkan gejala respons perilaku abnormal selama paparan yaitu gelisah, gangguan pernapasan, dan perilaku saraf abnormal. Kematian meningkat seiring meningkatnya konsentrasi ametryn. Penelitian ini menunjukkan dampak ametryn pada perubahan jaringan ginjal. Perdarahan dan distribusi hemosiderin, degenerasi hidropik, degenerasi granular, nekrosis tubular, penyempitan lumen tubular dan nekrosis adalah dampak histopatologis utama yang terjadi selama paparan ametryn. Kesimpulannya, ametryn sangat sensitif terhadap *Monopterus albus*. Dalam konsentrasi rendah, belut menunjukkan perubahan perilaku dan kesan pada organ.

Cite this as: Marina, H., Nor Azri, S. N., Wahidah, W., Anur Abdalah, N. M., Kismiyati, Mohd Fazrul, H. A. A., Norainy M. H., & Mohd Ihwan, Z. (2019). The toxic effect of ametryn on behaviour and histopathological changes of freshwater eel (*Monopterus albus*). *Jurnal Ilmiah Perikanan dan Kelautan*, 11(2):11–18. <http://doi.org/10.20473/jipk.v11i2.15713>

7  
This is an open access article under the CC BY-NC-ND license (<http://creativecommons.org/licenses/by-nc-nd/4.0/>)

## 1. Introduction

In agriculture farms, herbicides were used to control undesirable vegetation such as weeds to increase crop or field production. The indiscriminate discharge of pesticides contaminant into the water bodies is dangerous to the environment and ecosystems. Herbicides uses are may kill a target and non-target plants and also disturbing habitat and food supply for aquatic organisms. Herbicides are hydrophobic in the aquatic environment and tend to be associated with sediment particles and biological tissue (Mc Pherson *et al.*, 2000). Many researchers were focused on pesticide or herbicide effects on aquatic environment and also non-target aquatic organisms including fish but there is limited study on freshwater eel, *M. albus* (Omitoyin *et al.*, 2006; Siang *et al.*, 2007; Ayoola, 2008a; 2008b). The behaviour of the ametryn was severely affected the eel based on the natural behaviour and habitat.

Ametryn is selective herbicide to control weeds in crop fields (Anderson, 2005). Ametryn has a unique behavior that is greatly absorbed and leached in basic soil types especially on muck or clay soils more than other herbicides (PSEP, 2008). In Asia, *M. albus* is mostly found in rice fields, muddy and swamps areas (Bricking, 2002). Because of its habitat, they tend to exposed to toxic herbicides absorbed on mud or clay souls, especially when ametryn absorb in soil greater than other commercial herbicides. According to Brusle (1990), higher metals concentration accumulated in eels compared to other fish seems depend on the availability of the metals in the bottom sediments. Generally, all types of herbicides at high concentrations are known to reduce the survival, growth and reproduction fish, invertebrates and non-target organisms (Rahman *et al.*, 2002; Ayoola, 2008b).

However, the herbicides may not kill but it will stress out the eels. Stressful animals will prone many other problems such as infectious disease and physiological disturbances. Mostly, herbicides had undergone some acute toxicity testing for effects on non-target aquatic organisms. *Monopterus albus* is commonly served as food fish and believed to have medicinal value. The source of the eels are not from cultured pond because no eels cultured farm in Malaysia and the sources of eels are from the wild. The eels have a good demand and high market value. Based on habitat and value of this fishes in market food, it gives a high percentage risk effect of the toxicity to human. However, there were no information about the effect of ametryn on fish in Malaysia. Thus, this study was conducted on *M. albus* with regards to behaviour and histopathological changes after treated with ametryn.

16

## 2. Materials and Methods

### 2.1 Sample preparation

Healthy and active *M. albus* with the average standard length of 50-60cm were selected as samples. Life eels were bought from Kuala Terengganu market and placed in the aerated aquarium at the laboratory. All samples were acclimatized under laboratory conditions for a week and fed daily with commercial fish feed. The excess food or unconsumed feed and fecal were removed daily

### 2.2 Acute toxicity test

Three concentrations of the ametryn were prepared and tested for 96 hours on the *M. albus*; 0 (control), 0.75, 1.50 and 3.00mg/L. Four eels were used in each treatment. The mortality rates were recorded at 6, 12, 24, 48, 72 and 96 hours. The dead eels were removed from the tank immediately to avoid the deterioration of the water quality.

### 2.3 Behavior study

The behavioural changes of the healthy fish and fish subjected to three concentrations and one control were evaluated as regards to behaviour abnormalities. The abnormal stress behaviours were observed by visual assessment as suggested by Benli and Ozkul (2010). These behavioural responses of the eels were conducted at 1-8 hours and every 12 hours during the acute toxicity test (96 hours). Visual assessments of symptoms abnormal behaviour responses were made based on characteristics such as agitated behaviour, respiratory distress, and abnormal nervous behavior. The behaviour changes such as aggressiveness or frequently movements were score by score 0 to 3.

### 2.4 Histopathological study

In this study, histopathological examination was performed on the kidney for each eel by following a standard method (Luna, 1968; Tindall, 1989). After examination of behaviour, the kidney from dead fish was immediately taken and fixed in 10% buffered formalin. After 96 hours, all eels were killed and the kidney was taken and fixed in 10% buffered formalin. The tissue samples were analyzed according to the histopathological technique standard method. The tissue sections were stained with hematoxylin and eosin and observed under a light microscope at 10x, 40x and 100x objectives. Then, the histological changes were evaluated and described.

### 3. Results and Discussions

#### 3.1 Behavior study

*Monopterus albus* were exposed directly to various concentration of ametryn; 0.75, 1.50 and 3.00mg/L showed initial rapid movement such as frequently movement from the surface to bottom for air gulping, loss of balance, swirling movement, aggressiveness and tried many times to swim out of the aquarium (Table 1-3). The intensity of the behavioural activities of the fish decreased with the duration of exposure test with ametryn. There have no behavioural changes or mortalities were recorded in the control fish throughout the test. The series of symptoms abnormal behaviour responses on the acute toxicity of fish exposed to ametryn is included in three types is agitated behaviour, respiratory distress, and abnormal behaviour.

Based on the observation of different concentrations of ametryn tested on eels showed the abnormal behavioural occurs with increasing concentration of ametryn. Mortality at a different exposure concentrations of ametryn increased with the duration of the test become more variable with time. The strong abnormal behaviour of eels occurred in the higher concentration of ametryn, 3.0mg/L. The eels became more aggressive, frequently movement from the surface to bottom and erratic swimming when they are exposed to a high concentration. However, some eels showed excessive mucous secretion, verticle posture with exposed snouts, dart and different posture. During acute toxicity tested with 3.0mg/L of ametryn in 96 hours, the 100% mortality rate occurs less than 24 hours. From the observation of acute toxicity test on eels in 96 hours of exposure with the ametryn, the body showed pale colour. However, in the higher concentrations, severe lesions appeared such as focal haemorrhage, abrasion and high mucous (Figure 1).

**Table 1.** Agitated behaviors

Clinical signs	Extract concentration of Ametryn (mg/L)			
	0	0.75	1.5	3
Aggression	0	1	2	3
Stunned posture	0	0	0	2
FSBM (Frequent Surface to Bottom Movements)	0	1	2	3
Erratic swimming	0	1	2	3

**Table 2.** Respiratory distress

Clinical signs	Extract concentration of Ametryn (mg/L)			
	0	0.75	1.5	3
Air gulping	0	0	1	2
VPES (Vertical Posture with Exposed Snouts)	0	1	2	3
EMS (Excessive Mucus Secretion)	0	1	2	3

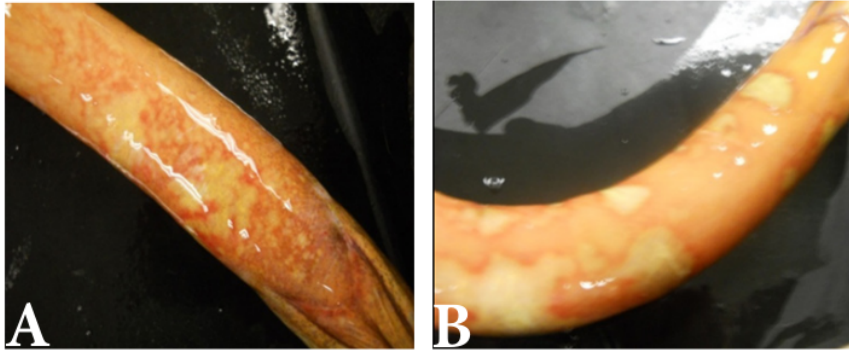
**Table 3.** Abnormal nervous behavior

Clinical signs	Extract concentration of Ametryn (mg/L)			
	0	0.75	1.5	3
SSM (Sluggish and Swirling Movements)	0	1	2	2
State of motionless	0	0	1	2
Sudden darts	0	1	2	3
DP (Different Postures)	0	1	2	3
Death	0	1	2	3

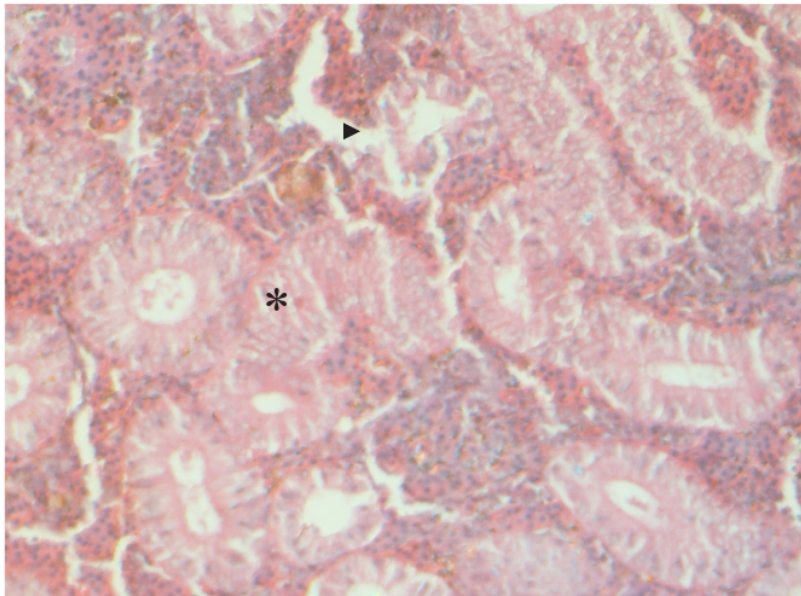
### 3.2 Histopathological studies

Histopathological changes exhibited in kidney of *M. albus* exposed to different concentration of ametryn for 96 hours is presented in Table 4. Figure 2 showed the histopathological changes from the lowest concentration. Major histopathological changes of kidney tissue is haemorrhage, severe distribution of hemosiderin, hydropic degeneration of tubular cells, narrowing tubular lumen and tubular necrosis.

The behaviour response and histopathological effect of herbicides and pesticides were studied by many researchers (Omitoyin *et al.*, 2006; Yildirim *et al.*, 2006; Ayoola, 2008a; Ayoola, 2008b; Benli and Ozkul, 2010; Abalaka and Auta, 2010; Srivastava *et al.*, 2010). However, the behaviour and histopathological effect on eels with ametryn have no report. Herbicides are widely used for farmers and it affects target and non-target organisms including fish (Omitoyin *et al.*, 2006; Ayoola, 2008a).



**Figure 1.** (A) (B) Hemorrhage and abrasion on the abdomen of *M. albus*



**Figure 2.** Histopathological appearance of present hydropic degeneration (\*), and tubular necrosis (▶) in the kidney tissue of *M. albus* after exposure to 0.75 mg/L of ametryn (H & E, x40 objective)

The behavioural response and histopathological effect in the present study of acute toxicity of ametryn *Monopterus albus* is similar studies of (Omitoyin *et al.*, 2006; Yildirim *et al.*, 2006; Siang *et al.*, 2007; Ayoola, 2008a; Ayoola, 2008b; Abalaka and Auta, 2010; Benli and Ozkul, 2010; Srivastava *et al.*, 2010) that's used different formulations of herbicides and pesticides. The toxicity of herbicides or pesticides has been reported on Southern Florida which more than 40 organic compounds (herbicide) were detected in bed sediment including ametryn and effect on aquatic organism mostly fishes in that area (Mc Person *et al.*, 2000). This present study about histopathological effects acute toxicity of ametryn and behavioural responses on *M. albus* in 96 hours. Acute toxicity of ametryn is shown increase with increasing the concentration. During the exposure in this present study, mortality rates are increased with increasing concentration.

The *M. albus* were directly exposed with different concentration of ametryn. Eels are initially aggressive, erratic swimming and came out the surface of water much more frequently and also exhibited abnormal swimming is sluggish and swirling movements and different posture. These signs exhibited of agitated behaviour in initial of exposure to ametryn caused loss of orientation (Srivastava *et al.*, 2010).

The ametryn treated eels also showed colour fades and lesion on the body such focal hemorrhage and abrasion as compared to the controls. Based on this study, previous study reported that the level of toxicity of any pesticide and herbicide depends on its bioaccumulation, the different chemistries of the compound forming the pesticides or herbicide and the reactions of the organisms receiving the toxicants (Neibor and Richardson, 1980; Ayoola, 2008a).

During the exposure of acute toxicity tested, eels exhibited respiratory distress mostly in high concentration of ametryn. The respiratory distress due to toxic effect of ametryn on the respiratory system was similar report of Yildirim *et al.*, (2006), Siang *et al.*, (2007) and Gabriel *et al.*, (2009). Eels are air gulping and movement to surface of water to vertical posture with exposed snouts are frequently. The toxicity of ametryn causes difficulty breathing in toxic water forcing the eel's frequently using air breather as substitution breathing. This compared to normal behaviour showed from control is infrequently air breather of respiration cutaneously (through the skin) which enabling them to survive long dry spells (Curnutt and Hamilton, 2000; USGS, 2012).

**Table 4.** Histopathological changes on a kidney after 96 hours exposure to different concentration of ametryn

Treatment concentration	Histopathological changes on a kidney after 96 hours exposure to ametryn
0 mg/L (Control)	Slightly hydropic degeneration
0.75 mg/L	Mild of hemorrhage Mild distribution of hemosiderin Mild of hydrophic degeneration Present of narrowing tubular lumen Present of tubular necrosis
1.5 mg/L	Severe of hemorrhage Severe distribution of hemosiderin Severe hydrophic degeneration Severe of granular degeneration Narrowing tubular lumen Severe of tubular necrosis
3.0 mg/L	Severe of hemorrhage Severe distribution of hemosiderin Narrowing tubular lumen Severe of tubular necrosis Severe of necrosis

Increased the duration of exposure toxicity of ametryn on eels exhibited motionless and sudden darts were leading to mortality. This considered as a principal sign of nervous system damage or failure effect of herbicide poisoning which affected on physiological and biochemical activities (Matsumura, 1975; Gabriel *et al.*, 2009). Excessive mucus secretion is exhibited during the exposure toxicity tested in 96 hours caused reflex from metabolic processes to resistant under the toxicity distress (Lebedeva *et al.*, 1998). The toxicity of ametryn showed no mortality in control but lower levels of mortality is started on low concentration of ametryn is 0.75 mg/L and the higher levels of mortality exhibited on high concentration of ametryn is 3.0 mg/L. This showed increased the mortality rate is directly proportional to increasing concentration of herbicide (Kane *et al.*, 2004).

*Monopterus albus* were stressed progressively with time before death. The stressful behaviour impairment due to toxic effect of ametryn on kidney was similar with the report of Ayoola, (2008b) and Omitoyin *et al.*, (2006) that herbicide impair internal organ of fish. Kidney is among the main organ of various indicator metabolic reaction and toxicity effects usually appear in kidney tissue (Benli and Ozkul, 2009). In eels exposed to ametryn concentration in 96 hours in the present study, the major histopathological changes of the kidneys were hemorrhage, and distribution of hemosiderin, hydrophic degeneration, narrowing tubular lumen, tubular necrosis and necrosis.

Control *M. albus* showed present of hydrophic degeneration were considered as normal in the kidney tissue examined by light microscope (Roberts, 2012). Major of histopathological changes in acute toxicity is hemorrhage and distribution of hemosiderin was similar with the report of Siang *et al.* (2007) and the toxicity of pesticide gives some hematological effects on *M. albus*. Hemosiderin often after hemorrhage when blood leaves a ruptured blood vessel, the red blood cell dies, and the hemoglobin of the cell is released into the extracellular space and they can lead to organ damage. Hydrophic degeneration is observed in kidney tubule epithelial cells which exposed with ametryn were exhibited swollen and cloudy in epithelial cells and also the nucleus are closed with membrane epithelial cells (Besirovic *et al.*, 2010).

Tubular necrosis give probability of impurities such as red blood cell, hemoglobin cast and cell debris infiltrate inside lumen which interfere with normal metabolism of kidney. Necrosis of some portion of the kidney and tubular necrosis that were observed probably resulted from the excessive metabolism required by the

fish to get rid of the toxicant from the body during the process of detoxification by the kidney (Ayoola, 2008b). This histopathological effects on kidney caused of toxicity ametryn were give effects on behavioural changes of eels as reaction of changes the toxic environment and the severe damage of kidney organ were lead to kidney failure and death to the fish.

#### 4. Conclusion

In conclusion, ametryn is very sensitive to some aquatic species especially freshwater eel and this pesticide should be used cautiously to avoid the number of species decline in wild.

#### Acknowledgement

The authors would like to thanks the laboratory staff of AKUATROP for their assistance in the laboratory experiment.

#### Author's Contributions

All authors discussed the results and contributed to from the start to final manuscript

#### Conflict of Interest

The authors declare that they have no competing interests

#### Funding Information

This research was supported by Institute of Tropical Aquaculture and Fisheries Research (AKUATROP)

#### References

- Abalaka, S. E. & Auta, J. (2010). Toxicity of aqueous and ethanol extracts of *Parkia biglobosa* pods on *Clarias gariepinus* juveniles. *Journal of Animal and Veterinary Advances*, 6: 1068-1072.
- Anderson, N. (2005). United States Environmental Protection Agency: Environmental Protection Agency. Prevention pesticides and toxic substances: Registration Eligibility Decision (R. E. D) for ametryn. Environmental Protection Agency Government [online]. Available from <http://www.epa.gov> [Accessed on 22 September 2011]
- Ayoola, S. O. (2008a). Hispathological effects of glyphosate on juvenile African catfish (*Clarias*

- gariepinus*). *American - Eurasian Journal Agriculture & Environment*, 3: 362-367.
- Ayoola, S. O. (2008b). Toxicity of glyphosate herbicide on Nile tilapia (*Oreochromis niloticus*) juvenile. *African Journal of Agriculture Research*, 12: 825-834.
- Benli, A. C. K., & Ozkul, A. (2010). Acute toxicity and histopathological effects of sublethal fenitrothion on Nile tilapia, *Oreochromis niloticus*. *Pesticide Biochemistry and Physiology*, 32-35.
- Besirovic, H., Alic, A., Prasovic, S., & Drommer, W. (2010). Histopathological effects of chronic exposure to cadmium and zinc on kidneys and gills of brown trout (*Salmo trutta m. fario*). *Turkish Journal of Fisheries and Aquatic Sciences*, 10: 255-262.
- Bricking, E. M. (2002). In: Danoff-Burg J. A. (eds). Asian Swamp Eel (*Monopterus albus*). Introduced Species Summary Project, Center for Environmental Research and Conservation, Columbia University, New York [online]. Available from: <http://www.columbia.edu> [Accessed on 27 September 2011].
- Brusle, J. (1990). Effects of heavy metals on eels, *Anguilla* sp. *Aquatic Living Resources*, 3: 131-141.
- Curnutt, J., & Hamilton, H. (2000). USGS scientists find new population of Asian Swamp Eels in South Florida. U.S. Geological Survey (USGS) [online]. Available from: <http://nas.er.usgs.gov> [Accessed on 4<sup>th</sup> May 2012]
- Gabriel, U. U., Mark, P., & Orlu, E. E. (2009). Toxicity and behavioural changes in *Heterobranchus bidorsalis* fingerlings treated with micronutrient fertilizer, Agrolyser. *Research Journal of Environment and Earth Science*, 1: 34-38.
- Kane, A. S. Salierno, J. D., & Brewer, S. K. (2004). Fish models in behavioral toxicology: Automated techniques, updates and perspectives. In Ostrander, G.K. (eds.). *Methods in Aquatic Toxicology*. Vol. 2. Lewis Publishers, Boca Raton, Florida. Pp 559-590.
- Lebedeva, N. E., Vosyliene, M. Z., & Golovkina T. V. (1998). Changes in the biochemical composition of mucus of fish under the effect of environmental factors. *Reports of Russian Academy of Sciences*, 362: 713-715.
- Luna, G. L. (1968). *Manual of Histologic staining methods of the armed forces Institutes of Pathology*. 3<sup>rd</sup> ed. New York, USA: McGraw-Hill Book Cooperation. Pp. 35-38.
- Matsumura, F. 1975. *Toxicology of Insecticides*. 2<sup>nd</sup> Ed. New York, London: Plenum Press. Pp 503.
- Mc Pherson, B. F., Miller, R. L., Haag, K. H. & Bradner, A. (2000). U.S. Department of the Interior and cooperative with U.S. Geological Survey Circular. Water Quality in Southern Florida Florida. U.S. Geological Survey [online]. Available from: <http://www.usgs.gov> [Accessed on 27 September 2011].
- Neibor, E. & Richardson, D. H. (1980). Replacement of non-descript term heavy metal by a biological and chemically significant classification of metal ions. *Environmental Pollution Series*, 3: 3-26.
- Omitoyin, B. O., Ajani, E. K. & Fajimi, O. A. (2006). Toxicity of gramoxone (paraquat) to juvenile African catfish, *Clarias gariepinus* (Burchell, 1822). *American - Eurasian Journal Agriculture and Environment*, 1: 26-30.
- Pesticide Safety Education Program (PSEP): Parts of the Pesticide Management Education Program and Cooperative Extensive with Cornell University (2008). Ametryn (Evik) herbicide profile 3/85. Pesticide Safety Education Program (PSEP) [online]. Available from: <http://pmep.cce.cornell.edu> [Accessed on 22 September 2011].
- Rahman, M. Z., Hossain, M. F. A., & Ahmed, G. U. (2002). Effect of Diazinon 60EC on *Anabas testudineus*, *Channa punctatus* and *Barbodes gonionotus* Naga. *The International Centre for Living Aquatic Resources Management Quarterly*, 25: 8-11
- Roberts, R. J. (2012). *Fish Pathology*. 4<sup>th</sup> ed. United Kingdom: Blackwell Publishing. 483 p.
- Siang, H. Y., Yee, L. M. & Seng, C. T. (2007). Acute Toxicity of organochlorine insecticide Endosulfan and its effect on behaviour and some hematological parameters of Asian swamp eel (*Monopterus albus*, Zuiew). *Pesticide biochemistry and physiology*, 89: 46-53.
- Srivastava, A. K., Mishra, D., Shrivastava, S., Srivastav, K. & Srivastav, A. K. (2010). Acute toxicity and behavioural responses of *Heteropneustes fossilis* to an organophosphate insecticide, dimethoate. *International Journal of Pharma and Bio Science*, 1: 359-363.
- Tindall, B. (1989). Fish pathology. In: Roberts R. J. (eds.). 2<sup>nd</sup> ed. London, England: British Library Cataloguing in Publication Data. Pp. 1-382.
- U.S. Geological Survey (USGS). (2012). Frequently



asked questions about the Asian Swamp Eel: Southeast Ecological Science Center. U.S. Geological Survey (USGS) [online]. Available from: <http://nas.er.usgs.gov> [Accessed on 4<sup>th</sup> May 2012]

Yildirim, M. Z., Benli, A. C. K., Selvi, M., Ozkul, A., Erkoc, F. & Kocak, O. (2006). Acute toxicity, behavioral changes and histopathological effects of deltamethrin on tissues (gills, liver, brain, spleen, kidney, muscle, skin) on Nile Tilapia (*Oreochromis niloticus* L.) fingerlings. Wiley Periodicals Incorporation. *Environmental Toxicology*, 21: 614-620.

## ORIGINALITY REPORT

12%

SIMILARITY INDEX

6%

INTERNET SOURCES

10%

PUBLICATIONS

0%

STUDENT PAPERS

## PRIMARY SOURCES

1

[en.wikipedia.org](http://en.wikipedia.org)

Internet Source

1%

2

[irep.iium.edu.my](http://irep.iium.edu.my)

Internet Source

1%

3

M. K. Ladipo. "Acute Toxicity, Behavioural Changes and Histopathological Effect of Paraquat Dichloride on Tissues of Catfish (*Clarias Gariepinus*)", *International Journal of Biology*, 04/06/2011

Publication

1%

4

Yii Siang Hii, Mun Yee Lee, Tse Seng Chuah. "Acute toxicity of organochlorine insecticide endosulfan and its effect on behaviour and some hematological parameters of Asian swamp eel (*Monopterus albus*, Zuiew)", *Pesticide Biochemistry and Physiology*, 2007

Publication

1%

5

Agbohessi, Prudencio T., Ibrahim I. Toko, Vincent Atchou, Roland Tonato, S.N.M. Mandiki, and Patrick Kestemont. "Pesticides used in cotton production affect reproductive

1%

development, endocrine regulation, liver status and offspring fitness in African catfish *Clarias gariepinus* (Burchell, 1822)", *Comparative Biochemistry and Physiology Part C Toxicology & Pharmacology*, 2015.

Publication

---

6

O.I. Ayanda, S.J. Oniye, J. Auta, V.O. Ajibola. "Acute toxicity of glyphosate and paraquat to the African catfish (, Teugels 1986) using some biochemical indicators ", *Tropical Zoology*, 2015

Publication

---

7

[escholarship.org](https://escholarship.org)

Internet Source

---

8

[research-repository.griffith.edu.au](https://research-repository.griffith.edu.au)

Internet Source

---

9

Aysel Çağlan Karasu Benli, Ayhan Özkul. "Acute toxicity and histopathological effects of sublethal fenitrothion on Nile tilapia, *Oreochromis niloticus*", *Pesticide Biochemistry and Physiology*, 2010

Publication

---

10

Hastiadi Hasan, Eka Indah Raharjo, Dayang Dian Ariyani. "PENGARUH EKSTRAK DAUN KEMANGI (*Ocimum basilicum* L) TERHADAP DAYA TETAS TELUR IKAN LELE DUMBO (*Clarias gariepinus*) YANG DIINFEKSI JAMUR *Saprolegnia* sp.", *Jurnal Ruaya : Jurnal*

1 %

1 %

1 %

1 %

1 %

# Penelitian dan Kajian Ilmu Perikanan dan Kelautan, 2016

Publication

11

Nur Amanina Hamdan, Mohd Effendy Abd Wahid, Anur Melad Nagi, Mohamad Badrul Moham Sahimi, Mohd Ihwan Zakariah, Marina Hassan. "Effects of Gelam, Melaleuca cajuputi Methanolic Leaves Extract to the Behavior of Freshwater Prawn (*Macrobrachium rosenbergii*)", Pakistan Journal of Biological Sciences, 2020

Publication

<1 %

12

[www.coursehero.com](http://www.coursehero.com)

Internet Source

<1 %

13

[sportdocbox.com](http://sportdocbox.com)

Internet Source

<1 %

14

Shafina Shawon Sharmin, Md Baki Billah, Md Kawser Ahmed, Md Abdus Salam. "Toxicity of sodium fluoride (NaF) to juvenile catfish, *Clarias batrachus*", Dhaka University Journal of Biological Sciences, 2013

Publication

<1 %

15

[library.med.juntendo.ac.jp](http://library.med.juntendo.ac.jp)

Internet Source

<1 %

16

[analyt.natureblink.com](http://analyt.natureblink.com)

Internet Source

<1 %

17

A. M. Al-Otaibi, H. F. A. Al-Balawi, Z. Ahmad, E. M. Suliman. "Toxicity bioassay and sub-lethal effects of diazinon on blood profile and histology of liver, gills and kidney of catfish, *Clarias gariepinus*", *Brazilian Journal of Biology*, 2019

Publication

---

&lt;1 %

18

Abalaka, Samson Eneajo, Fatihu, Muhammad Yakassai, Ibrahim, Najume Doguwar Gingiya and Kazeem, Haruna Makuojuola.

"Phytochemical composition and toxicity of the aqueous extract of *Parkiabiglobosa* pods in adult *Clarias gariepinus* ", *Nigerian Society for Experimental Biology*, 2013.

Publication

---

&lt;1 %

19

Gil Ran Kang, Ha Yeun Song, Dong Soo Kim. "Toxicity and Effects of the Herbicide Glufosinate-Ammonium (Basta) on the Marine Medaka *Oryzias dancena*", *Fisheries and aquatic sciences*, 2014

Publication

---

&lt;1 %

20

Rahin Alsadat Hashemi, Yaghoub Jaddi, Mohammad Ali Sadeghi, Samane Ghiamati, Msuod Motazedi. "Study of Toxicology Effects of Herbicide Paraquat on Heamatological Parameters of *Mesopotamichthys sharpeyi*", *Open Journal of Marine Science*, 2017

&lt;1 %

21

T. SAWADA. "Postnatal DNA synthesis in hearts of mice: autoradiographic and cytofluorometric investigations",  
Cardiovascular Research, 08/01/1988

Publication

---

<1 %

22

Toshio Mori. "Beef Tallow, but Not Perilla or Corn Oil, Promotion of Rat Prostate and Intestinal Carcinogenesis by 3,2-Dimethyl-4-aminobiphenyl", Cancer Science, 10/2001

Publication

---

<1 %

23

[www.intechopen.com](http://www.intechopen.com)

Internet Source

---

<1 %

24

[www.kindipublication.com](http://www.kindipublication.com)

Internet Source

---

<1 %

25

Bo Pang, Xue-Fei Cao, Shao-Ni Sun, Xi-Luan Wang, Jia-Long Wen, Su Shiung Lam, Tong-Qi Yuan, Run-Cang Sun. "The direct transformation of bioethanol fermentation residues for production of high-quality resins",  
Green Chemistry, 2020

Publication

---

<1 %

26

Emad M. Zidan, Amira A. Goma, Hossam G. Tohamy, Mohamed Mohamed Soliman, Mustafa Shukry. " Insight study on the impact of different salinity levels on behavioural responses, biochemical stress parameters

<1 %

# and growth performance of African catfish ( ) ", Aquaculture Research, 2022

Publication

---

---

Exclude quotes      On

Exclude matches      Off

Exclude bibliography      On

---

GRADEMARK REPORT

---

FINAL GRADE

GENERAL COMMENTS

**/0**

**Instructor**

---

PAGE 1

---

PAGE 2

---

PAGE 3

---

PAGE 4

---

PAGE 5

---

PAGE 6

---

PAGE 7

---

PAGE 8

---