

Non-motor seizure diagnosed after mild traumatic brain injury: a case report

by Drestha Pratita Windriya

Submission date: 19-Aug-2023 05:34PM (UTC+0800)

Submission ID: 2147912861

File name: 05._Non-motor_seizure_diagnosed.pdf (664.03K)

Word count: 2498

Character count: 14140

Non-motor seizure diagnosed after mild traumatic brain injury: a case report



Drestha Pratita Windriya^{1*}, Reryd Arindany Wiryawan¹,
Wardah Rahmatul Islamiyah¹, Abdulloh Machin¹

¹Department of Neurology, Faculty of Medicine, Universitas Airlangga – Dr. Soetomo General Academic Hospital, Surabaya, Indonesia

*Corresponding to:

Drestha Pratita Windriya, Department of Neurology, Faculty of Medicine Universitas Airlangga – Dr. Soetomo General Academic Hospital, Jl. Mayjend Prof. Dr. Moestopo No. 6-8, Airlangga, Gubeng, Surabaya, East Java 60286, Indonesia.
drestha.pratita.windriya-2019@fk.unair.ac.id

Received: 2023-02-26

Accepted: 2023-04-02

Published: 2023-04-30

ABSTRACT

Introduction: In 10% of head injury cases, nonmotor seizures were detected by electroencephalography (EEG) performed in the acute phase. Nonmotor seizures are often not diagnosed at the start of treatment because the symptoms are often not recognized by the patient's family or doctor. The incidence of seizures in patients with minor head injuries is very low. From the literature, it was found that the type and severity of the head injury is a significant factors in the incidence of post-traumatic seizure. Thus, in this article, we report a case of nonmotor seizures in a patient after a minor head injury.

Case description: An Indonesian female, 53 years old, complained of sudden silence when speaking after 4 days earlier, she fell and hit her head on the right side. There was no loss of consciousness, headache, vomiting or limb weakness. Complaints of motor seizures and a history of previous seizures were denied. There were no cranium defects, hematomas, or open wounds on examination. The results of laboratory tests and non-contrast head CT scans were expected. On electroencephalography (EEG) examination, epileptiform waves were found in the left temporal region. The patient was given anti-seizure drugs, and complaints improved within 2 days of therapy. It is crucial to carry out an EEG examination in the acute phase of a head injury to exclude the possibility of nonmotor seizures and brain dysfunction, which will be at risk of causing seizures later in life after trauma.

Conclusion: EEG examination in the acute phase of head injury is used to exclude the possibility of nonmotor seizures and brain dysfunction, which will be at risk of causing seizures later in life after trauma.

Keywords: Brain injury, electroencephalography, a non-motor seizure.

Cite This Article: Windriya, D.P., Wiryawan, R.A., Islamiyah, W.R., Machin, A. 2023. Non-motor seizure diagnosed after mild traumatic brain injury: a case report. *Bali Medical Journal* 12(2): 1407-1409. DOI: 10.15562/bmj.v12i2.4402

INTRODUCTION

Head injury due to trauma is one of the reasons why patients are taken to the hospital. The incidence of head injury in developed countries is estimated at 1.7 million, with a mortality rate of 52,000 patients each year.^{1,2} Severe head injury can trigger seizures up to status epilepticus in as many as 20-30% of cases in the acute phase of head injury,^{3,4} and 52% are nonmotor seizures.^{5,6}

Classification of head injuries based on the severity of the trauma is divided into three: 1) mild trauma, namely trauma that occurs followed by a decrease in consciousness for less than 30 minutes without a skull fracture; 2) moderate trauma, trauma accompanied by a decrease in consciousness for more than 30 minutes and less than 24 hours with/without skull fractures, and 3) severe trauma, namely trauma followed by loss of consciousness for more than 24

hours accompanied by skull fractures, hematomas, or contusions.^{7,8}

In 10% of head injury cases, nonmotor seizures were detected by electroencephalography (EEG) performed in the acute phase.⁹ Nonmotor seizures occur in approximately 10% of patients with seizures recognized by electroencephalography (EEG) in the acute phase of head injury. Nonmotor seizures were found in 23.5% of patients with moderate to severe head injury, and 5.9% of these cases developed nonmotor status epilepticus.⁵

Nonmotor seizures are often not diagnosed at the start of treatment because the symptoms are often not recognized by the patient's family or the examining doctor. The incidence of seizures in patients with minor head injuries is very low.¹⁰ From the literature, it was found that the type and severity of the head injury is a significant factors in the incidence of post-traumatic seizure. We report a case

of nonmotor seizures in a patient after a minor head injury.¹⁰

CASE DESCRIPTION

An Indonesian female, 53 years old, her family suckled suddenly. The patient became silent every time she spoke for about 1 minute. The patient was silent for a few seconds, accompanied by a cessation of activity. There was no stiffness, twitching, or other motor movements. The patient seemed to stop moving in the middle of her activity. After a pause, the patient spoke again as before. It is recognized that this complaint arose after the patient fell in the bathroom 4 days earlier. The patient slipped in the bathroom and hit his head on the right side. There was no loss of consciousness, headache, vomiting or limb weakness. The family denied complaints of motor seizures. Within 12 hours after the fall, according to the patient's family, he often suddenly became silent, especially

when talking, and the patient was unaware of the incident. The family recognizes that this complaint appears up to five times per day. The patient had never had seizures or similar complaints before. A new complaint appeared shortly after the patient suffered a collision to the head when he fell. The patient has a history of hypertension and diabetes mellitus. The family admits the patient regularly takes medication to control hypertension and diabetes. There is no history of previous seizures.

On examination, the patient had a blood pressure of 180/120 mmHg, a pulse of 110 times per minute, a respiratory rate of 18 times per minute, and a temperature of 36.8 Celsius. No hematomas or open wounds were found on examination of the patient's head and neck. The patient was fully conscious, with no signs of meningeal irritation, decreased vision, visual field disturbances, or other cranial nerve abnormalities. On motor examination, there was a strength of 5 in all four extremities, and no sensory or autonomic disorders were found.

Laboratory examination of complete blood and serum electrolytes showed the expected results that were normal. Furthermore, the patient underwent a non-contrast CT scan of the head to rule out a structural brain lesion due to a collision 4 days earlier. The normal results were obtained from the head CT without contrast.

The patient's complaints persisted on the second day of treatment. The patient underwent electroencephalography (EEG) examination with suspicion of non-motor seizures. The patient's EEG results showed a Sharp wave image in the left Temporal region with a trigger factor for mental activation (Figure 1).

The patient has been given anticonvulsant therapy, Valproic acid 500 mg every 8 hours. Two days after the therapy administration, the frequency of sudden silent speech was reduced to two times per day. Monitoring at the Neurology Polyclinic after the patient finished treatment showed an improvement in the patient's complaints. After 6 months after treatment, the patient had no complaints similar to the therapy given. The evaluation of the EEG showed normal results.

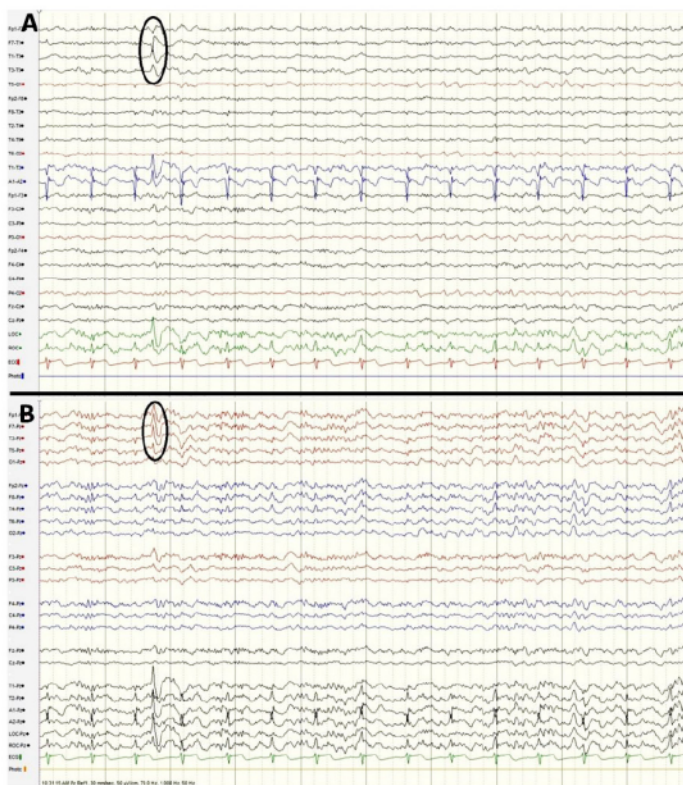


Figure 1. The bipolar (A) and monopolar (B) montage of EEG results showed a sharp wave on the temporal region.

DISCUSSION

Moderate to severe head injuries can result in seizures, which can develop over a long period. Clinicians could be tempted to believe that epileptic seizures that occur after a head injury are the cause. TBI is connected to dissociative seizures, formerly known as psychogenic non-epileptic seizures.¹¹

Dissociative seizures affect women significantly three times greater rather than men. In contrast to the predominance of males who experience epileptic seizures.¹² This might be because women are more susceptible to various risk factors. Female patients are more likely than male patients to experience post-traumatic dissociation seizures.¹³ In our case, we found a female, 53 years old, had a non-motor seizure after experiencing mild traumatic brain injury.

The symptoms of nonmotor seizures are nonspecific, so the diagnosis is often

missed. These symptoms include anorexia, aphasia/mutism, amnesia, lethargy, agitation/aggression, flickering, confusion, facial twitching, nystagmus, and tremors. Nonmotor status epilepticus can manifest as decreased consciousness, altered mental status, automatism, behavioral changes, and hallucinations. Nonmotor seizures are said to be an EEG diagnosis.⁶

The previous study found that very mild trauma, in which there was no loss of consciousness and no injuries to the head or neck, did not increase the risk of seizures in the first 1 year of post-traumatic observation. However, in patients with head injuries, the risk of seizures was found to be 1.7. Another study stated that the ratio of occurrence of seizures in patients after mild head injury was only 1.5.¹⁰ Only Christensen et al. reported that the risk of seizures in mild head injury was doubled at 10 years of post-traumatic observation.¹⁴

Structural brain lesions in neck injuries can result from an acceleration-deceleration mechanism resulting in diffuse axonal injury, venous tear, and diffuse vascular injury. Abnormalities in EEG results may not reflect an existing structural lesion but may represent transient changes due to cortical stimulation, cerebral circulation, or local post-traumatic edema. Numerous processes after injury include necrosis, micro-hemorrhage, axonal damage, apoptosis, demyelination, microgliosis, inflammation, oxidative stress, and later phases of neurodegeneration, regeneration, revascularization, and remodeling, may contribute to the circuit changes that lead to last epilepsy.¹⁵ In mild head trauma, seizures can also occur due to changes in the nervous tissue, including inflammatory changes and axonal growth, for some time after the trauma.¹⁰ However, there is still a lack of conclusive evidence regarding the causal role of neuroinflammation in epileptogenic, especially in the event of trauma.⁸

According to a Cochrane review, studies on preventive antiepileptic medications after TBI were of low quality. They discovered that therapy (phenytoin or carbamazepine) did not affect late seizures or death after TBI but may decrease the frequency of early post-traumatic seizures.¹⁶ No benefit was shown when valproate and levetiracetam were compared to phenytoin. There are no recommendations in the Brain Trauma Foundation Guideline.¹⁷ Prophylaxis for those without seizures cannot be recommended without a better risk classification.¹⁸ In this case, report the patient has been given anticonvulsant therapy Valproic acid 500 mg every 8 hours. Two days after the therapy administration, the frequency of sudden silent speech was reduced to two times per day. Monitoring at the Neurology Polyclinic after the patient finished treatment showed an improvement in the patient's complaints. After 6 months after treatment, the patient had no complaints similar to the therapy given. The evaluation of the EEG showed normal results.

CONCLUSION

EEG examination in the acute phase

of head injury is used to exclude the possibility of nonmotor seizures and brain dysfunction, which will be at risk of causing seizures later in life after trauma.

DISCLOSURE

Conflict of Interest

The authors report no conflict of interest in this work.

Informed Concern

The patient was informed and agreed that the case would be published. However, the identity of the patient was kept confidential.

Funding

None

Author Contribution

All of the authors contributed in all to the manuscript processes.

REFERENCES

- Majidi S, Makke Y, Ewida A, Sianati B, Qureshi AI, Koubeissi MZ. Prevalence and Risk Factors for Early Seizure in Patients with Traumatic Brain Injury: Analysis from National Trauma Data Bank. *Neurocrit Care*. 2016;27(1):90-5. Available from: <http://dx.doi.org/10.1007/s12028-016-0363-6>
- Wahyuhadi J, Wicaksono P, Notobroto HB. Clinical Outcome of Patients with Diffuse Axonal Injury Receiving Adrenocorticotropic Analogue at Dr. Soetomo Hospital. *Folia Medica Indones*. 2018;54(3):222. Available from: <http://dx.doi.org/10.20473/fmi.v54i3.10019>
- Andrade P, Banuelos-Cabrera I, Lapinlampi N, Paananen T, Ciszek R, Ndode-Ekane XE, et al. Acute Non-Convulsive Status Epilepticus after Experimental Traumatic Brain Injury in Rats. *J Neurotrauma*. 2019;02/25. 2019;36(11):1890-907. Available from: <https://pubmed.ncbi.nlm.nih.gov/30543155>
- Oktavian P, Romdhoni AC, Dewanti L, Fauzi A Al. Clinical and Radiological Study of Patients With Skull Base Fracture After Head Injury. *Folia Medica Indones*. 2021;57(3):192. Available from: <http://dx.doi.org/10.20473/fmi.v57i3.22824>
- Octaviana F, Harisman J, Wiratman W, Budikayanti A. Altered mental status in moderate-severe traumatic brain injury in Indonesia: the clinical manifestation and EEG features of non-convulsive status epilepticus. *Heliyon*. 2021;7(9):e08067-e08067. Available from: <https://pubmed.ncbi.nlm.nih.gov/34622071>
- Lee JH, Hur JS, Moon HJ, Kim JH, Kim JH, Kim JH, et al. Nonconvulsive Seizures of Traumatic Brain Injury Patients. *Korean J Neurotrauma*. 2013;9(2):64. Available from: <http://dx.doi.org/10.13004/kjnt.2013.9.2.64>
- Al Fauzi A, Apriawan T, Ranuh IGMAR, Christi AY, Bajamal AH, Turchan A, et al. Traumatic brain injury in pregnancy: A systematic review of epidemiology, management, and outcome. *J Clin Neurosci*. 2023;107:106-17. Available from: <http://dx.doi.org/10.1016/j.jocn.2022.12.007>
- Sharma R, Leung WL, Zamani A, O'Brien TJ, Casillas Espinosa PM, Semple BD. Neuroinflammation in Post-Traumatic Epilepsy: Pathophysiology and Tractable Therapeutic Targets. *Brain Sci*. 2019;9(11):318. Available from: <https://pubmed.ncbi.nlm.nih.gov/31717556>
- Shandra O, Robel S. Inducing Post-Traumatic Epilepsy in a Mouse Model of Repetitive Diffuse Traumatic Brain Injury. *J Vis Exp*. 2020;(156):10.3791/60360. Available from: <https://pubmed.ncbi.nlm.nih.gov/32090988>
- Gilad R, Boaz M, Sadeh M, Eilam A, Dabby R, Lampl Y. Seizures after Very Mild Head or Spine Trauma. *J Neurotrauma*. 2013;30(6):469-72. Available from: <http://dx.doi.org/10.1089/neu.2012.2625>
- Goldstein LH, Robinson EJ, Reuber M, Chalder T, Callaghan H, Eastwood C, et al. Characteristics of 698 patients with dissociative seizures: A UK multicenter study. *Epilepsia*. 2019;60(11):2182-93.
- Francis P, Baker GA. Non-epileptic attack disorder (NEAD): a comprehensive review. *Seizure*. 1999;8(1):53-61. Available from: <http://dx.doi.org/10.1053/sez.1998.0246>
- Barry E, Krumholz A, Bergey GK, Chatha H, Alemayehu S, Grattan L. Nonepileptic Posttraumatic Seizures. *Epilepsia*. 1998;39(4):427-31. Available from: <http://dx.doi.org/10.1111/j.1528-1157.1998.tb01395.x>
- Christensen J. Traumatic brain injury: Risks of epilepsy and implications for medicolegal assessment. *Epilepsia*. 2012;53(SUPPL. 4):43-7.
- Pitkänen A, Ekolle Ndode-Ekane X, Lapinlampi N, Puhakka N. Epilepsy biomarkers - Toward etiology and pathology specificity. *Neurobiol Dis*. 2018/05/18. 2019;123:42-58. Available from: <https://pubmed.ncbi.nlm.nih.gov/29782966>
- Thompson K, Pohlmann-Eden B, Campbell LA, Abel H. Pharmacological treatments for preventing epilepsy following traumatic head injury. *Cochrane Database Syst Rev*. 2015;2015(8):CD009900-CD009900. Available from: <https://pubmed.ncbi.nlm.nih.gov/26259048>
- Carney N, Totten AM, O'Reilly C, Ullman JS, Hawryluk GWJ, Bell MJ, et al. Guidelines for the Management of Severe Traumatic Brain Injury, Fourth Edition. *Neurosurgery*. 2017;81(1):E3-4. Available from: <http://dx.doi.org/10.1093/neuros/nyx087>
- Fordington S, Manford M. A review of seizures and epilepsy following traumatic brain injury. *J Neurol*. 2020;267(10):3105-11. Available from: <https://doi.org/10.1007/s00415-020-09926-w>



This work is licensed under a Creative Commons Attribution

Non-motor seizure diagnosed after mild traumatic brain injury: a case report

ORIGINALITY REPORT

15%

SIMILARITY INDEX

10%

INTERNET SOURCES

11%

PUBLICATIONS

4%

STUDENT PAPERS

PRIMARY SOURCES

1	www.dovepress.com Internet Source	1%
2	Submitted to Udayana University Student Paper	1%
3	Submitted to Oxford Brookes University Student Paper	1%
4	Vikram Rao, Karen Parko. "Clinical Approach to Posttraumatic Epilepsy", Seminars in Neurology, 2015 Publication	1%
5	www.researchsquare.com Internet Source	1%
6	www.jocmr.org Internet Source	1%
7	www.phcogj.com Internet Source	1%
8	synapse.koreamed.org Internet Source	1%

9	www.mdpi.com Internet Source	1 %
10	"Clinical Electroencephalography", Springer Science and Business Media LLC, 2019 Publication	1 %
11	repository.ubaya.ac.id Internet Source	1 %
12	repository.unair.ac.id Internet Source	1 %
13	Ángel JM. Gargiulo, Ana Colombini, Antonella Trovato, Augusto Pl. Gargiulo, Luciana D'Alessio. "Functional/dissociative seizures: Review of its relationship with trauma, dissociation and the neurobiological underpinnings", Psychiatry Research Communications, 2022 Publication	1 %
14	Gibb, Stuart L., Yuhai Zhao, Daniel Potter, Michael J. Hylin, Roberta Bruhn, Gyulnar Baimukanova, Jing Zhao, Hasen Xue, Mohamed Abdel-Mohsen, Satish K. Pillai, Anthony N. Moore, Evan M. Johnson, Charles S. Cox, Pramod K. Dash, and Shibani Pati. "TIMP3 attenuates the loss of neural stem cells, mature neurons and neurocognitive dysfunction in Traumatic Brain Injury", Stem Cells, 2015.	<1 %

15

Jae Won Park, Jong Young Lee. "Traumatic Intracerebral and Subarachnoid Hemorrhage Due to a Ruptured Pseudoaneurysm of Middle Meningeal Artery Accompanied by a Medial Sphenoid Wing Dural Arteriovenous Fistula", Korean Journal of Neurotrauma, 2017

Publication

<1 %

16

Nicolas Lejeune, Nathan Zasler, Rita Formisano, Anna Estraneo, Olivier Bodart, Wendy L. Magee, Aurore Thibaut. "Epilepsy in prolonged disorders of consciousness: a systematic review", Brain Injury, 2021

Publication

<1 %

17

biblio.ugent.be

Internet Source

<1 %

18

pdfs.semanticscholar.org

Internet Source

<1 %

19

repub.eur.nl

Internet Source

<1 %

20

www.minervamedica.it

Internet Source

<1 %

21

"Seizures in Critical Care", Springer Science and Business Media LLC, 2017

Publication

<1 %

22

"Status Epilepticus", Springer Science and Business Media LLC, 2018

Publication

<1 %

23

Ji Hye Lee, Jun Seok Hur, Hong Joo Moon, Ji Hyun Kim et al. "Nonconvulsive Seizures of Traumatic Brain Injury Patients", Korean Journal of Neurotrauma, 2013

Publication

<1 %

Exclude quotes Off

Exclude matches Off

Exclude bibliography On

Non-motor seizure diagnosed after mild traumatic brain injury: a case report

GRADEMARK REPORT

FINAL GRADE

GENERAL COMMENTS

/100

PAGE 1

PAGE 2

PAGE 3
