



Source details

Asian Pacific Journal of Tropical Medicine

Scopus coverage years: from 2010 to Present

Publisher: Wolters Kluwer Health

ISSN: 1995-7645 E-ISSN: 2352-4146

Subject area: Medicine: General Medicine

Source type: Journal

CiteScore 2022

3.8



SJR 2022

0.374



SNIP 2022

0.662



[View all documents >](#)

[Set document alert](#)

[Save to source list](#) [Source Homepage](#)

[CiteScore](#) [CiteScore rank & trend](#) [Scopus content coverage](#)

i Improved CiteScore methodology



CiteScore 2022 counts the citations received in 2019-2022 to articles, reviews, conference papers, book chapters and data papers published in 2019-2022, and divides this by the number of publications published in 2019-2022. [Learn more >](#)

CiteScore 2022 ▼

$$3.8 = \frac{1,147 \text{ Citations 2019 - 2022}}{303 \text{ Documents 2019 - 2022}}$$

Calculated on 05 May, 2023

CiteScoreTracker 2023 ⓘ

$$4.0 = \frac{1,000 \text{ Citations to date}}{253 \text{ Documents to date}}$$

Last updated on 05 August, 2023 • Updated monthly

CiteScore rank 2022 ⓘ

Category	Rank	Percentile
Medicine		
General Medicine	#219/830	73rd



[View CiteScore methodology >](#) [CiteScore FAQ >](#) [Add CiteScore to your site](#)

SJR Scimago Journal & Country Rank

Enter Journal Title, ISSN or Publisher Name

Home Journal Rankings Country Rankings Viz Tools Help About Us

Asian Pacific Journal of Tropical Medicine

<p>COUNTRY</p> <p>India</p> <p> Universities and research institutions in India</p> <p> Media Ranking in India</p>	<p>SUBJECT AREA AND CATEGORY</p> <p>Medicine</p> <p>↳ Medicine (miscellaneous)</p>	<p>PUBLISHER</p> <p>Wolters Kluwer Medknow Publications</p>	<p>H-INDEX</p> <p>67</p>
<p>PUBLICATION TYPE</p> <p>Journals</p>	<p>ISSN</p> <p>23524146, 19957645</p>	<p>COVERAGE</p> <p>2010-2022</p>	<p>INFORMATION</p> <p>Homepage</p> <p>How to publish in this journal</p> <p>daouda.sissoko@u-bordeaux.fr</p>

SCOPE

Asian Pacific Journal of Tropical Medicine (ISSN 1995-7645 CODEN: APJTB6), a publication of Editorial office of Hainan Medical University, is a peer-reviewed print + online Monthly journal. The journal's full text is available online at <http://www.apjtm.org/>. The journal allows free access (Open Access) to its contents and permits authors to self-archive final accepted version of the articles on any OAI-compliant institutional / subject-based repository. APJTM aims to provide an academic communicating platform for international physicians, medical scientists, allied health scientists and public health workers, especially those of the Asia-Pacific region and worldwide on tropical medicine, infectious diseases and public health, and to meet the growing challenges of understanding, preventing and controlling the dramatic global emergence and re-emergence of infectious diseases in the Asia-Pacific.

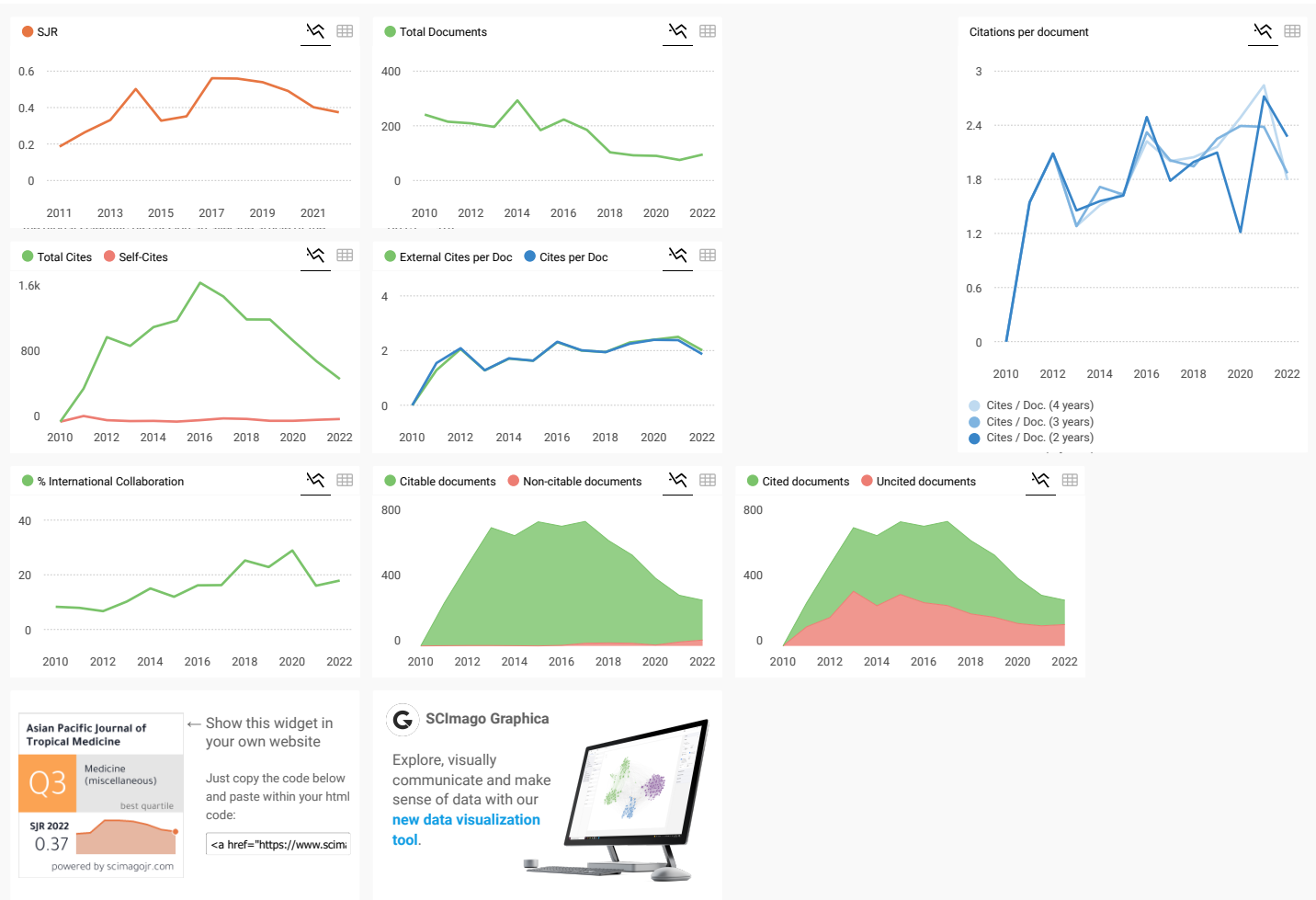
Join the conversation about this journal

Quartiles

FIND SIMILAR JOURNALS ?

options ⋮

1 Asian Pacific Journal of Tropical Biomedicine NLD 62% similarity	2 Tropical Journal of Pharmaceutical Research NGA 48% similarity	3 Pathogens and Global Health GBR 47% similarity	4 BMC Complementary and Alternative Medicine GBR 46% similarity	5 Tropical Biomedicine MYS 46% similarity
---	---	--	--	---



Metrics based on Scopus® data as of April 2023

B Bo Cui 3 years ago
 the journal is published monthly
 ↩ reply

Melanie Ortiz 3 years ago SCImago Team
 Dear Sir/Madam, thanks for your participation! Best Regards, SCImago Team


E Emeka Mgb 3 years ago
 Pls what is the frequency of publishing of this journal.Thanks
 ↩ reply

Melanie Ortiz 3 years ago SCImago Team
 Dear Emeka,
 thank you for contacting us.
 Unfortunately, we cannot help you with your request, we suggest you visit the journal's homepage or contact the journal's editorial staff, so they could inform you more deeply.
 Best Regards, SCImago Team

February 2023 - Volume 16 - Issue 2 : Asian Pacific Journal of Tropical Medicine

[Home](#) > February 2023 - Volume 16 - Issue 2

< [Previous Issue](#) | [Next Issue](#) >



February 2023 - Volume 16 - Issue 2

pp: 49-96

 [Table of Contents Outline](#)

 [eTOC Alerts](#)

 [Contributor Index](#)

Acknowledgment to Reviewers, 2022

[Acknowledgment to Reviewers, 2022](#)

Asian Pacific Journal of Tropical Medicine. 16(2):49-50, February 2023.

-  Favorite
-  PDF
- [Permissions](#)

- [Open](#)

[Table of Contents Outline](#) | [Back to Top](#)

☐ Systematic Review

[Application of next-generation sequencing in thalassemia screening: A systematic review and meta-analysis](#)

Fang, Xingyi; Gong, Yi; Ma, Yanlin; More

Asian Pacific Journal of Tropical Medicine. 16(2):51-57, February 2023.

- [⊕ Abstract](#)
- [☆ Favorite](#)
- [PDF](#)
- [Permissions](#)

- [Open](#)

[Table of Contents Outline](#) | [Back to Top](#)

☐ Original Article

[Treatment outcomes and adverse drug reactions among patients with drug-resistant tuberculosis receiving all-oral, long-term regimens: First record viewing report from Pakistan](#)

Aslam, Hira; Omar, Asad; Fatima, Razia; More

Asian Pacific Journal of Tropical Medicine. 16(2):58-64, February 2023.

- [⊕ Abstract](#)
- [☆ Favorite](#)
- [PDF](#)
- [Permissions](#)

- [Open](#)

[Coagulation abnormalities and their relationship with bleeding manifestations in patients with dengue-A single center observational study](#)

Patel, Govind R.; Thanvi, Indu; Nadeem, Mohammad; More

Asian Pacific Journal of Tropical Medicine. 16(2):65-71, February 2023.

- [⊕ Abstract](#)
- [☆ Favorite](#)

- [PDF](#)
- [Permissions](#)
- [Open](#)

[**Mutations in *Plasmodium knowlesi* Kelch protein 13 and the dihydropteroate synthase gene in clinical samples**](#)

Saif, Ahmed

Asian Pacific Journal of Tropical Medicine. 16(2):72-79, February 2023.

- [⊕ Abstract](#)
- [☆ Favorite](#)
- [PDF](#)
- [Permissions](#)
- [Open](#)

[**Molecular epidemiology of piliated pneumococcal isolates at a major tertiary hospital in the Klang Valley, Malaysia**](#)

Dzaraly, Nurul Diana; Desa, Mohd Nasir Mohd; Muthanna, AbdulRahman; More

Asian Pacific Journal of Tropical Medicine. 16(2):80-88, February 2023.

- [⊕ Abstract](#)
- [☆ Favorite](#)
- [PDF](#)
- [Permissions](#)
- [Open](#)

[Table of Contents Outline](#) | [Back to Top](#)

Case Report

[**Long-term albendazole therapy for diffuse parenchymal neurocysticercosis in an immunocompetent patient: A case report**](#)

Sugianto, Paulus; Machin, Abdulloh; Islamiyah, Wardah Rahmatul; More

Asian Pacific Journal of Tropical Medicine. 16(2):89-91, February 2023.

- [⊕ Abstract](#)
- [☆ Favorite](#)
- [PDF](#)
- [Permissions](#)

- [Open](#)

[Table of Contents Outline](#) | [Back to Top](#)

☐ Letter to Editor

[Neutralizing possibilities of whole virion and mRNA vaccine triggered antibodies of Wuhan strain of SARS-CoV-2 with receptor binding domains of spike proteins of Delta and Omicron strains](#)

Barthwal, Shilpa; Angel, Bennet; Angel, Annette; More

Asian Pacific Journal of Tropical Medicine. 16(2):92-94, February 2023.

- [☆ Favorite](#)
- [PDF](#)
- [Permissions](#)

- [Open](#)

[Seroprevalence of dengue virus among adults presenting with acute febrile illness at a tertiary care hospital in South India](#)

Mohanam, Lavanya; Shanmugam, Priyadarshini

Asian Pacific Journal of Tropical Medicine. 16(2):95-96, February 2023.

- [☆ Favorite](#)
- [PDF](#)
- [Permissions](#)

- [Open](#)

[Table of Contents Outline](#) | [Back to Top](#)

Advertisement



[lww.com](#) - make it yours.

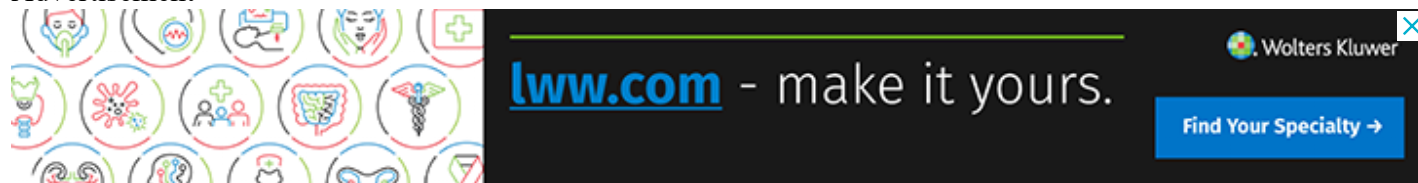
Wolters Kluwer

[Find Your Specialty →](#)

^Back to Top

Editorial Board : Asian Pacific Journal of Tropical Medicine

Advertisement



lww.com - make it yours.

Wolters Kluwer

Find Your Specialty →

Editorial Board

Editors-in-Chief

Nazni Wasi Ahmad, PhD

Institute for Medical Research Kuala Lumpur, Taxonomy and Control of Vectors of Malaria, Kuala Lumpur, Malaysia

Jeffrey M Bethony, PhD

Department of Microbiology, Immunology, and Tropical Medicine, George Washington University Medical Center, Washington DC, USA

Daouda Sissoko, MD

Department of Infectious Diseases and Tropical Medicine, University Hospital, Bordeaux, France

Ivan Dario Velez, MD, PhD

Columbia Society of Parasitology and Tropical Medicine, Universidad de Antioquia, Medellín, Colombia

Executive Editor-in-Chief

Bo Cui, MD, PhD

Hainan Medical University, Haikou, China

Deputy Editors-in-Chief

Huynh Giao, PhD

Faculty of Public Health,
University of Medicine and Pharmacy at Ho Chi Minh City, Vietnam

Jerapan Krungkrai, PhD

Department of Biochemistry,
Faculty of Medicine, Bangkok, Thailand

Alcides Troncoso, MD

Department of Microbiology and Infectious Diseases,
University of Buenos Aires, Buenos Aires, Argentina

Managing Editor

Yan Lei

Hainan Medical University, Haikou, China

Editors

Ting-chan Liang

Hainan Medical University, Haikou, China

Yin Pan

Hainan Medical University, Haikou, China

Qiao Zhang

Hainan Medical University, Haikou, China

Editorial Directors

Jing Li

Hainan Medical University, Haikou, China

Advisory Board

Dirk Engels, PhD

Former Director of Control of Neglected Tropical Diseases World Health Organization

Marcel Tanner, PhD, MPH

Swiss Academy of Sciences; University of Basel, Basel, Switzerland

Editorial Board

Kamel Adwan, PhD

Department of Biology and Biotechnology,
An-Najah N. University, West-Bank, Palestine

Mahboob Alam, PhD

Department of Internal Medicine,
Division of Cardiology, Baylor College of Medicine, Houston, USA

Silvia Angeletti, PhD

Clinical Pathology and Microbiology Laboratory,
University Hospital Campus Bio-Medico of Rome, Rome, Italy

Herbert Auer, PhD

Department of Medical Parasitology,
Institute of Specific Prophylaxis and Tropical Medicine,
Center of Pathophysiology, Infectiology and Immunology,
Medical University of Vienna, Vienna, Austria

Majid Avijgan, PhD

Traditional Persian-Iranian Medicine,
Department of Infectious Diseases,
Isfahan University of Medical Sciences, Isfahan, Iran

Ciomar Aparecida Bersani-Amado, PhD

Department of Pharmacology and Therapeutic,
State University of Maringá, Paraná, Brazil

Ioan Stelian Bocsan, PhD

Epidemiology and Primary Health Care Department,
Iuliu Hatieganu University of Medicine and Pharmacy,
Cluj-Napoca, Romania

Norbert W. Brattig, PhD

Bernhard Nocht Institute for Tropical Medicine (BNITM),
Hamburg, Germany

Jong-Yil Chai, PhD

Department of Parasitology and Tropical Medicine,
Seoul National University College of Medicine,
Seoul, Korea

Supat Chamnanchanunt, PhD

Department of Clinical Tropical Medicine,
Faculty of Tropical Medicine, Mahidol University,
Bangkok, Thailand

Jae Sue Choi, PhD

Department of Food Science and Nutrition,
Pukyong National University, Busan, Korea

Massimo Ciccozzi, PhD

Department of Infectious Parasitic and Immunomediated Diseases,
National Institute of Health in Italy, Rome, Italy

Luisa Custodio, PhD

Faculty of Sciences and Technology,
Centre of Marine Sciences, University of Algarve,
Faro, Portugal

Kusal K Das, PhD

Department of Physiology,
Faculty of Medicine, BLDE University, Bijapur, India

Nicholas PJ Day, PhD

Centre for Tropical Medicine and Global Health,
Nuffield Department of Medicine, University of Oxford,
Oxford, UK

Valentina Virginia Ebani, PhD

Department of Veterinary Science,
University of Pisa, Pisa, Italy

Jimmy Thomas Efird, PhD

Brody School of Medicine,
East Carolina University, Greenville, USA

Farouk M. F. El-Sabban, PhD

Department of Family Sciences,
Department of Food Science and Nutrition,
College of Life Sciences, Kuwait University,
Safat, Kuwait

Mma Ma A. Faridi, PhD

Department of Pediatrics, University College of Medical Sciences,
Delhi University and GTB Hospital, New Delhi, India

Folorunso Oludayo Fasina, PhD

Food and Agricultural Organization of the United Nation,
Dar es Salaam, Tanzania

Guido Favia, PhD

School of Bioscience and Veterinary Medicine,
University of Camerino, Camerino, Italy

Bernhard Fleischer, PhD

Institute for Immunology,
University Medical Center Hamburg-Eppendorf,
Hamburg, Germany

Mun Yik Fong, PhD

Department of Parasitology,
Faculty of Medicine, University of Malaya,
Kuala Lumpur, Malaysia

Owunari Abraham Georgewill, PhD

Department of Pharmacology and Toxicology,
University of Port Harcourt, Port Harcourt, Nigeria

Antonio Gomez-Muñoz, PhD

Facultad de Ciencia y Tecnología,
Departamento de Bioquímica y Biología Molecular,
Universidad del País Vasco, Bilbao, Spain

Exnevia Gomo, PhD

Department of Medical Laboratory Sciences,
University of Zimbabwe, Harare, Zimbabwe

Stephen Brian Gordon, PhD

Liverpool School of Tropical Medicine,
Institute of Infection & Global Health,
University of Liverpool, Liverpool, UK

Robert A. Harrison, PhD

Alistair Reid Venom Research Unit, Parasitology Department,
Liverpool School of Tropical Medicine, Merseyside, UK

Yasushi Hasegawa, MD

Department of Surgery, School of Medicine,
Iwate Medical University, Morioka, Japan

Andrey Karlyshev, PhD

Life Sciences, Pharmacy & Chemistry,
Kingston University, Kingston, UK

Asad Ullah Khan, PhD

Medical Microbiology and Molecular Biology Laboratory,
Aligarh Muslim University, Aligarh, India

Hamzullah Khan, PhD

Department of Pathology,
Gomal Medical College, Dera Ismail Khan, Pakistan

Remington Lee, PhD

Department of Mental Health,
Bloomberg School of Public Health,
Nevin Johns Hopkins University, Baltimore, USA

Rosemary Susan Lees, PhD

Liverpool Insect Testing Establishment (LITE),
Vector Biology Department, Liverpool School of Tropical Medicine,
Liverpool, UK

Usa Lek-Uthai, PhD

Department of Parasitology and Entomology,
Faculty of Public Health, Mahidol University,
Bangkok, Thailand

Sutherland Maciver, PhD

Centre for Integrative Physiology,
School of Medicine, University of Edinburgh,
Edinburgh, UK

Richard James Maude, PhD

Centre for Tropical Medicine and Global Health,
University of Oxford, Oxford, UK

Nada Milic, PhD

Ministry of Health, Belgrade, Serbia

Fraser De Wolfe Miller, PhD

John A. Burns School of Medicine,
University of Hawaii System, Honolulu, USA

Fawaz Mzayek, PhD

Division of Epidemiology,
University of Memphis, School of Public Health, Memphis, USA

Veeranoot Nissapatorn, PhD

Department of Parasitology, Faculty of Medicine,
University of Malaya, Kuala Lumpur, Malaysia

Francois Henry Nosten, PhD

Shoklo Malaria Research Unit,
Mahidol-Oxford University Research Unit,
Oxford University, Oxford, UK

Uchenna Nwagha, PhD

Department of Obstetrics and Gynaecology/Physiology,
College of Medicine, University of Nigeria, Nsukka, Nigeria

Wen-huang Peng, PhD

Department of Chinese Pharmaceutical Sciences and Chinese Medicine Resources,
College of Pharmacy, China Medical University, Taichung, Taiwan

Rasa Petraityte-Burneikiene, PhD

Institute of Biotechnology,
Department of Eukaryote Genetic Engineering Vilnius University,
Vilnius, Lithuania

Michael Ramharter, PhD

Department of Medicine I,
Division of Infectious Diseases and Tropical Medicine,
Medical University of Vienna, Vienna, Austria

Rajul Rastogi, PhD

Department of Radiodiagnosis,
Teerthanker Mahaveer Medical College and Research Centre,
Moradabad, India

Barbara Rath, PhD

Department of Pediatrics,
Charite-Universitätsmedizin Berlin, Berlin, Germany

Eduardo Rocha, PhD

Interdisciplinary Center for Marine and Environmental Research (CIIMAR),
CIMAR Associate Laboratory (CIMAR LA),
University of Porto, Porto, Portugal

Alfonso J. Rodriguez-Morales, MD, PhD

Public Health and Infection Research Group,
Faculty of Health Sciences, Universidad Tecnológica de Pereira,

Risaralda, Colombia

Abhay R. Satoskar, PhD

Departments of Pathology and Microbiology,
Wexner Medical Center, the Ohio State University, Ohio, USA

Jitendra Kumar Saxena, PhD

Division of Biochemistry,
CSIR-Central Drug Research Institute, Lucknow, India

Jonas Schmidt-Chanasit, PhD

Faculty of Mathematics, Informatics and Natural Sciences,
Department of Biology, University of Hamburg,
Hamburg, Germany

Mohamed Hussain Rezvi Sheriff, PhD

Faculty of Medicine, Department of Clinical Medicine,
University of Colombo, Colombo, Sri Lanka

Ajit Singh, PhD

Department of Immunology, College of Veterinary Science,
Lala Lajapat Rai University of Veterinary and Animal Sciences,
Hisar, India

Duncan R. Smith, PhD

Institute of Molecular Biosciences,
Mahidol University, Nakorn Pathom, Thailand

Kabkaew L. Sukontason, PhD

Department of Parasitology, Chiang Mai, Thailand

Mohsen Tafaghodi, PhD

School of Pharmacy, Mashhad University of Medical Sciences,
Mashad, Iran

Léon Tshilolo, PhD

Centre Hospitalier Monkole, Kinshasa, Congo

Vijaya Lakshmi Valluri, PhD

Immunology and Molecular Biology Division,
LEPRA SOCIETY-Blue Peter Public Health & Research Centre,
Secunderabad, India

Luca Vannucci, PhD


Laboratory of Tumor Biology,
Institute of Animal Physiology and Genetics,
Academy of Sciences of the Czech Republic, Libechov, Czech Republic

Lee Yeong Yeh, PhD

School of Medical Sciences,
Universiti Sains Malaysia (USM), Kelantan, Malaysia

Rong-xin Zhang, PhD

Laboratory of Immunology and Inflammatory Diseases,



apjtm.org



Case Report

Asian Pacific Journal of Tropical Medicine

doi: 10.4103/1995-7645.368014

Impact Factor: 3.041

Long-term albendazole therapy for diffuse parenchymal neurocysticercosis in an immunocompetent patient: A case report

Paulus Sugianto[✉], Abdulloh Machin, Wardah Rahmatul Islamiyah, Cindy Cecilia

Department of Neurology, Faculty of Medicine–Universitas Airlangga / Dr. Soetomo General–Hospital, Surabaya, Indonesia

ABSTRACT

Rationale: Neurocysticercosis is a neglected tropical disease caused by the larvae of *Taenia solium* and may occur in immunocompetent people. We report a case of diffuse parenchymal neurocysticercosis mimicking tuberculous meningitis in an immunocompetent patient.

Patient concerns: A 24-year-old immunocompetent woman presented with serial focal to generalized seizure, left body weakness, left abducens palsy, chronic cough, and body weight loss. She came from an area where she was unlikely to have contact with *Taenia solium*.

Diagnosis: Diffuse parenchymal neurocysticercosis.

Intervention: Valproic acid, dexamethasone and 15 months of albendazole therapy.

Outcome: Complete recovery without any neurological sequelae.

Lessons: Prolonged anthelmintic treatment may benefit neurocysticercosis patients with multiple cerebral parenchymal lesions.

KEYWORDS: Albendazole; Corticosteroid; Neurocysticercosis; Prognosis; *Taenia solium*; Tuberculous meningitis

1. Introduction

Neurocysticercosis (NCC) is the most severe form of parasitic cysticercosis disease affecting the brain. The World Health Organization (WHO) states that NCC is a neglected tropical disease caused by ingesting *Taenia solium* from raw or undercooked meat and vegetables[1]. The prevalence rate of NCC in Asia ranges from 0.8% to 41.8%, depending on each country's socioeconomic culture, diet and hygiene. Thailand, Vietnam, and the Philippines have the highest prevalence[1]. Indonesia is an archipelago country with a total NCC prevalence from 1985 to 2006, which is 5.2%–21.0%[1]. According to WHO, cysticercosis leads to 2.8 million

disability-adjusted life-years. The major manifestations are seizures, headaches, and focal neurological deficits. Anthelmintics, steroid, antiseizure drug, or surgical approach varies depending on the stage of the disease[2]. The prognosis for NCC is generally good, but in severe cases, it can lead to sequelae or death[3].

2. Case report

A 24-year-old immunocompetent woman was referred from secondary healthcare with serial right focal to secondary generalized seizure with suspicion of tuberculous meningoencephalitis.

The first seizure was noted five months before admission, with progressive headache, fever, chronic cough, and loss of body weight two months before the first seizure. Due to a lack of healthcare facilities, the patient was referred to a tertiary hospital for further diagnosis and treatment.

She was a local-born Muslim Indonesian lady who was currently a university student. She was living in a rural area in east Java. This housing residence was not near an agricultural or animal husbandry area. She had previously not traveled to the domestic or overseas area and had no contact with NCC patients or with similar symptoms. She has proper hygiene and no history of eating raw or undercooked porcine products. Her risk factor for getting NCC was eating raw vegetables. Her Housing area had a poor public water system, which is also a possible risk factor for getting NCC.

[✉]To whom correspondence may be addressed. E-mail: paulus.sugianto@fk.unair.ac.id
This is an open access journal, and articles are distributed under the terms of the Creative Commons Attribution-Non Commercial-ShareAlike 4.0 License, which allows others to remix, tweak, and build upon the work non-commercially, as long as appropriate credit is given and the new creations are licensed under the identical terms.

For reprints contact: reprints@medknow.com

©2023 Asian Pacific Journal of Tropical Medicine Produced by Wolters Kluwer-Medknow.

How to cite this article: Sugianto P, Machin A, Islamiyah WR, Cecilia C. Long-term albendazole therapy for diffuse parenchymal neurocysticercosis in an immunocompetent patient: A case report. Asian Pac J Trop Med 2023; 16(2): 89-91.

Article history: Received 26 October 2022
Accepted 5 January 2023

Revision 20 December 2022
Available online 27 February 2023

On the examination, blood pressure was 110/80 mmHg, heart rate was 80 times per minut regular, and temperature 38.5 °C. Her previous body weight before the illness was 59 kg, and she was present with 39 kg on examination. Head and neck, lung, heart, and gastrointestinal examination were normal.

Neurological examination showed higher mental function and was normal with Glasgow Coma Scale (GCS) 456, no meningeal sign, and left abducens palsy. An additional laboratory test, tuberculosis screening such as acid-fast-bacillus test, faces examination, chest X-ray, and contrast brain-MRI were performed. Laboratory findings were slight leukopenia, increase in eosinophils, normal neutrophils, negative for HIV test, and normal CD4 levels. The tuberculosis test and feces examination were unremarkable. Head MRI with contrast showed multiple vesicular cystic lesions throughout the brain parenchyma. The largest size was length 1.65 cm and width 1.73 cm which was hypointense on T1W1 hyperintensity T2W1, accompanied by leptomeningeal enhancement with scolex appearance. This result was consistent with active neurocysticercosis

(Figure 1A). Electroencephalogram (EEG) revealed epileptogenicity on the left temporo-occipital. The patient received valproic acid 500 mg twice daily, folic acid, and albendazole 400 mg/day for 15 months.

The patient was re-admitted to the emergency room 4 months after initial treatment due to status epilepticus, decreased consciousness, left hemiparesis, and increased intracranial pressure (ICP). A brain CT scan showed massive brain edema. Dexamethasone 10 mg intravenously, continued by 5 mg three times daily, was administered for five days. She was discharged with oral dexamethasone and tapered off for 2 months. Left hemiparesis and abducens palsy was improving with GCS 15. Albendazole continued until 15 months. The patient has gained 27 kg with left abducens palsy, and hemiparesis was resolved entirely after 11 months of initial treatment. The seizure was controlled after 13 months of anthelmintic treatment. Valproic acid tapered off when the EEG test showed no epileptogenicity after 2 years of therapy and no further clinical seizure. Treatment duration and timeline can be seen in Figure 2.

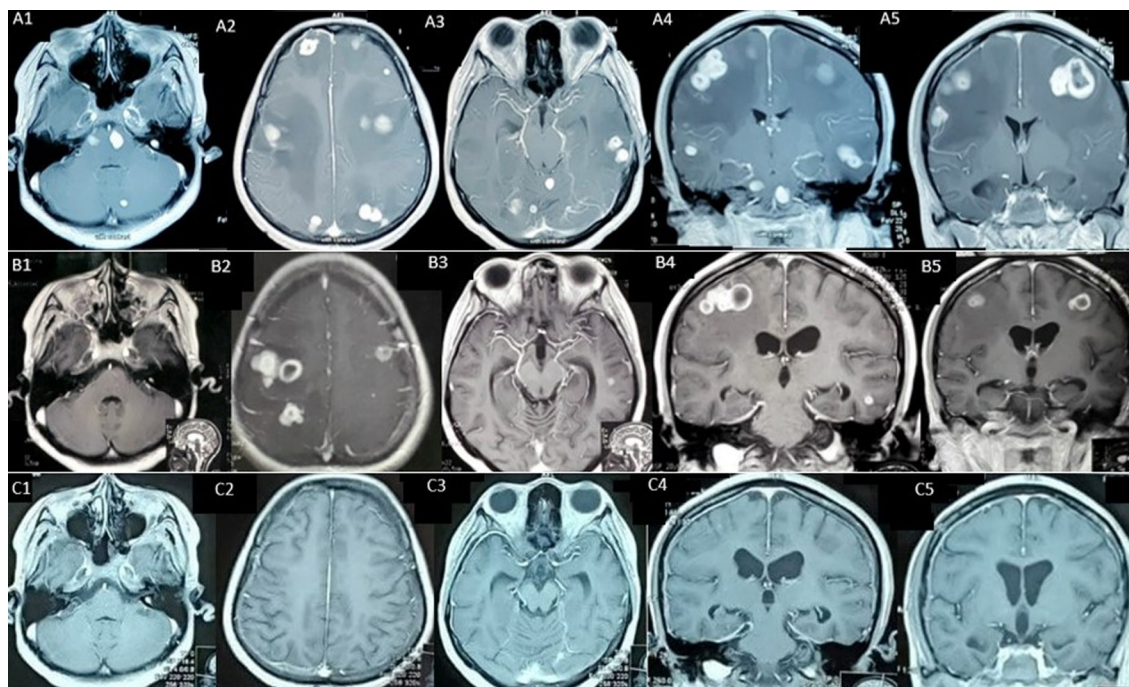


Figure 1. (A) A1-A5 initial head MRI with contrast showed multiple parenchymal cystic lesions with scolex. (B) B1-B5 head MRI with contrast after 6.5 months after initial treatment showed multiple parenchymal cystic lesions. (C) C1-C5 head MRI with contrast after 15 months of albendazole therapy showed almost diminished nodule.

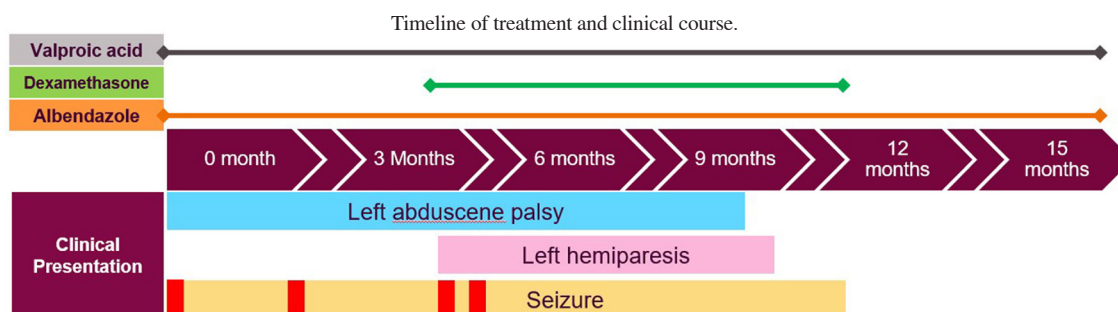


Figure 2. Timeline of treatment and clinical course. Steroids were given during the 4 months treatment period due to cerebral oedema and tapered off until 3 months. Left hemiparesis was present after 4 months, accompanied by a status epilepticus attack (shown by the red box colored).

3. Discussion

Clinical presentation of NCC might mimic other brains infectious diseases[4]. In developing tropical countries such as Indonesia, tuberculosis is endemic[5]. Muslims, as the major population of Indonesia consisting of 87.2%, usually do not eat uncooked meat. Taeniasis is only prevalent in certain districts, such as Bali province, with the majority being Hindu, North Sulawesi and Papua. Therefore, she was suspected of having tuberculous meningoencephalitis[6,7]. Due to a lack of healthcare facility, she was referred to the nearest tertiary health center. Diagnosis of NCC was made after Del-Bruto criteria with the result of definite NCC. It met 1 absolute and 2 major criteria, multiple cystic lesions with scolex showed on MRI, which was highly suggestive of NCC, and cystic resolution after albendazole administration[2].

Anthelmintic therapy, oral albendazole, was initiated with a dose of 15 mg/kg/day. Monotherapy was chosen over dual antiparasitic treatment due to the risk of raised ICP. A study showed that dual antiparasitic therapy could lead to more parasitic cell death and a shorter resolution time. Single albendazole could reach the same result with a higher dose[2].

As the active cyst was still present on brain MRI, albendazole was continued for 15 months. Adverse reactions during treatment, such as headache, dizziness, transaminitis and urticaria, were not found. This adverse reaction was uncommon in monotherapy compared to dual therapy[2]. There is no standard recommendation on the duration of treatment, repeating antihelmintic therapy. Most cases depend on clinical and imaging data.

Studies suggest steroids can accelerate seizure control and cyst resolution[8,9]. Other studies have used this steroid as a priming 3 days before albendazole treatment to prevent a sudden inflammatory brain reaction. The duration and timing of steroid administration vary depending on the patient clinical presentation[8]. The patient was given dexamethasone during readmission in the Emergency Room. There was massive brain edema with increased ICP due to parasite inflammatory response. It was switched into an oral regimen and tapered until 3-month period. It was discontinued after the patient's neurological deficit improved. Long term steroids medication can cause opportunistic infections such as *Strongyloides stercoralis*, which is co-endemic with *Taenia solium* and *Mycobacterium tuberculosis*[8,10].

There were no seizures after 13 months of anthelmintic treatment and 500 mg of valproic acid twice daily. Epileptogenicity in EEG returned to normal 2 years after treatment, and the neurological deficit resolved after 11 months without any sequelae. The patient also gained 27 kg body weight.

Appropriate treatment and monitoring in cases of NCC can provide a good outcome. Long-term use of albendazole, in this case, did not give an adverse reaction and was still proven to be effective in treating severe NCC.

In conclusion, in countries where cysticercosis is endemic, diagnosis and screening for NCC in a low-probability individual still have to be considered. There are no absolute guidelines on NCC's duration and combination of antiparasitic treatment. Different doses and duration of therapy have been applied differently, and most cases are based on expert or individual recommendations. Further study should be carried out for the patient's benefit and safety.

Conflict of interest statement

The authors declare that there is no conflict of interests.

Funding

The authors received no extramural funding for the study.

Authors' contributions

PS conceptualized the global case. WRI and CC performed diagnostic tools. PS, AM and CC monitored and collected patient data. PS and AM analysed and interpreted the case. PS, AM and CC drafted the manuscript.

References

- [1] Bizhani N, Hashemi SH, Mohammadi N, Rezaei M, Rokni MB. Human cysticercosis in Asia: A systematic review and meta-analysis. *Iran J Public Health* 2020; **49**(10): 1839-1847.
- [2] Jaime F, Randy GO, Sandra PC, Javier MF, Liliana M, Alfonso TC, et al. Long-term follow-up of patients with neurocysticercosis and the development of seizures. *J Transl Sci* 2016; **1**(2): 49-54.
- [2] Butala C, Brook TM, Majekodunmi AO, Welburn SC. Neurocysticercosis: Current perspectives on diagnosis and management. *Front Vet Sci* 2021; **8**(5): 1-10.
- [4] Garcia HH, Nash TE, Del Brutto OH. Clinical symptoms, diagnosis, and treatment of neurocysticercosis. *Lancet Neurol* 2014; **13**(12): 1202-1215.
- [5] Bintari DC, Ardiansyah D, Sugianto P. *Mycobacterium tuberculosis* infection in the central nervous system mimicking metastatic process. *Ann Rom Soc Cell Biol* 2021; **25**(6): 20360-20365.
- [6] Cupertino M, Resende M, Mayer N, Carvalho L, Siqueira-Batista R. Emerging and re-emerging human infectious diseases: A systematic review of the role of wild animals with a focus on public health impact. *Asian Pac J Trop Med* 2020; **13**(3): 99.
- [7] Garg R, Kumar N, Rizvi I, Malhotra H. Disseminated cysticercosis presenting with bilateral proptosis: A case report. *Asian Pac J Trop Med* 2019; **12**(7): 337.
- [8] Pandey S, Malhotra HS, Garg RK, Malhotra KP, Kumar N, Rizvi I, et al. Quantitative assessment of lesion load and efficacy of 3 cycles of albendazole in disseminated cysticercosis: A prospective evaluation. *BMC Infect Dis* 2020; **20**(1): 220.
- [9] Carpio A, Romo ML, Hauser WA, Kelvin EA. New understanding about the relationship among neurocysticercosis, seizures, and epilepsy. *Seizure* 2021; **90**: 123-129.
- [10] Yuzawa H, Hirose Y, Kimura T, Kimura S, Sugawara K, Yanagisawa A, et al. A case of cerebral tuberculoma mimicking neurocysticercosis. *Acute Med Surg* 2017; **4**(3): 329-333.

Publisher's note

The Publisher of the *Journal* remains neutral with regard to jurisdictional claims in published maps and institutional affiliations.