

# Case of compressive myelopathy due to juvenile xanthogranuloma of cervicothoracic junction in a 28- year-old male

*by* Eko Agus Subagio

---

**Submission date:** 21-Aug-2023 11:21AM (UTC+0800)

**Submission ID:** 2148646842

**File name:** 2023\_-\_SNI-14-17\_JXG.pdf (1.54M)

**Word count:** 2553

**Character count:** 13911

### Case Report

# Case of compressive myelopathy due to juvenile xanthogranuloma of cervicothoracic junction in a 28-year-old male

Wisnu Baskoro<sup>1</sup>, Muhammad Fakhri Raiyan Pratama<sup>1</sup>, Ayu Yoniko Christi<sup>1</sup>, Muhammad Faris<sup>2</sup>, Eko Agus Subagio<sup>2</sup>, Pandu Wicaksono<sup>2</sup>, Bidari Kameswari<sup>3</sup>

<sup>1</sup>Department of Neurosurgery, Dr. Soeradji Tirtonegoro Central Public Hospital, Klaten, <sup>2</sup>Department of Neurosurgery, Universitas Airlangga – Dr. Soetomo General Academic Hospital, Surabaya, <sup>3</sup>Department of Pathology Anatomy, Dr. Soeradji Tirtonegoro Central Public Hospital, Klaten, Indonesia

E-mail: \*Wisnu Baskoro - snu.nssby@gmail.com; Muhammad Fakhri Raiyan Pratama - eff.nsurg@gmail.com; Ayu Yoniko Christi - ayuyoniko@gmail.com; Muhammad Faris - mfarisns@fk.unair.ac.id; Eko Agus Subagio - eko.agus@fk.unair.ac.id; Pandu Wicaksono - drduwns@gmail.com; Bidari Kameswari - bidarikameswari@gmail.com



#### \*Corresponding author:

Wisnu Baskoro,  
Department of Neurosurgery,  
Dr. Soeradji Tirtonegoro  
Central Public Hospital, Klaten,  
Indonesia.

snu.nssby@gmail.com

Received : 15 December 2022

Accepted : 04 January 2023

Published : 20 January 2023

#### DOI

10.25259/SNI\_1129\_2022

#### Quick Response Code:



## ABSTRACT

**Background:** Juvenile xanthogranuloma (JXG) is a proliferative disorder of non-Langerhans histiocytes. The lesions typically occur in children as solitary cutaneous lesions, but are only rarely found in adults in their late twenties to thirties. Approximately 5–10% of JXG are extracutaneous in location, with spinal JXG being only rarely encountered. Here, we described a 28-year-old male with an extradural spinal JXG resulting in severe C6–T1 spinal cord compression and a progressive quadriparesis that warranted a decompressive laminectomy/C6–T2 fusion.

**Case Description:** A 28-year-old male presented with a progressive quadriparesis of 12 months' duration that rapidly worsened over the last 3 months. When the MRI revealed severe cord epidural C6–T1 cord compression, the patient successfully underwent a C6–T1 laminectomy for gross total tumor excision followed by a C6–T2 instrumented fusion. The histopathology confirmed the diagnosis of a spinal JXG.

**Conclusion:** Spinal JXGs in adults are only rarely encountered and should be treated with gross total tumor excision with/without fusion to achieve the best long-term outcomes.

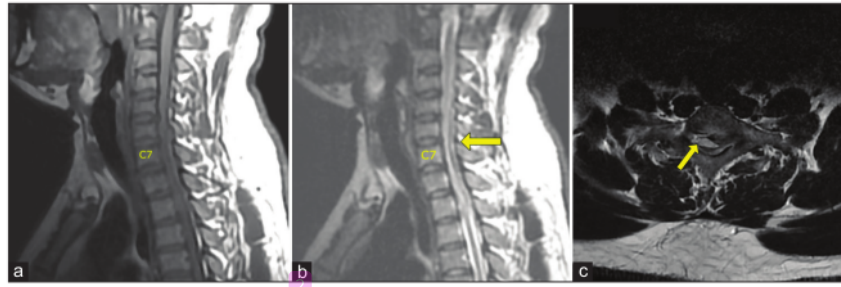
**Keywords:** Extradural tumor, Gross total removal, Juvenile xanthogranuloma, Laminectomy, Spinal tumor

## INTRODUCTION

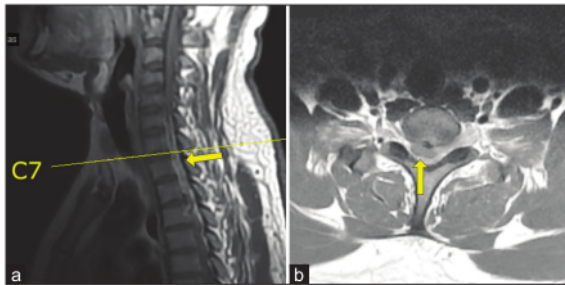
Juvenile Xanthogranuloma (JXG) is a proliferative disorder of non-Langerhans histiocytes that typically occur in children under the age of one. Often they are solitary cutaneous lesions that spontaneously resorb.<sup>[3,4]</sup> JXG rarely occurs in adults in their late 20s–30s.<sup>[3,4]</sup> Notably, approximately 5–10% of JXGs are extracutaneous in location, with spinal JXGs being extremely rare. These lesions may produce neurological deficits reflecting their anatomic spinal locations.<sup>[13]</sup> Here, a 28-year-old male presented with the 1-year onset of a progressive quadriparesis with 3 months' of precipitous worsening attributed to a C6–T1 JXG that was successfully managed with a decompressive laminectomy for gross total surgical resection and C6–T2 fusion.

This is an open-access article distributed under the terms of the Creative Commons Attribution-Non Commercial-Share Alike 4.0 License, which allows others to remix, transform, and build upon the work non-commercially, as long as the author is credited and the new creations are licensed under the identical terms.

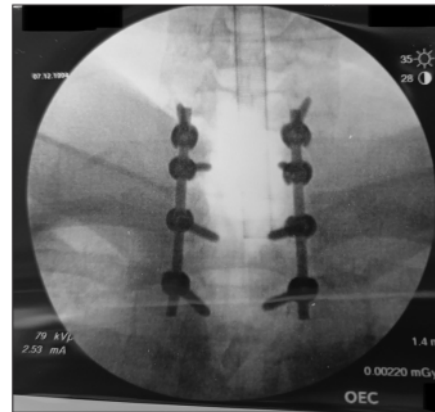
©2023 Published by Scientific Scholar on behalf of Surgical Neurology International



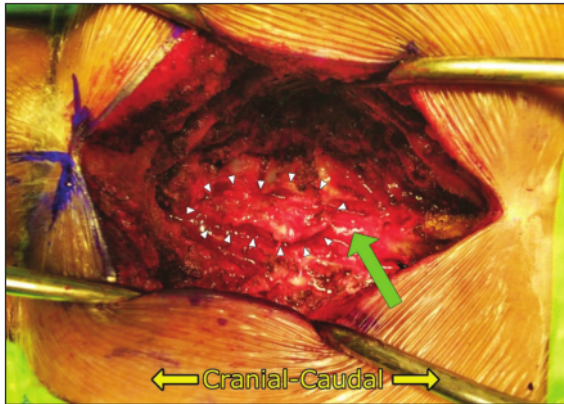
**Figure 1:** Cervicothoracic MRI. (a) Sagittal T1 and (b) sagittal T2-weighted image show isointense extradural mass (yellow arrow) in spinal canal lying from C6 until T1 levels. (c) Axial T2-weighted image shows severe compression of the cord due to posterior extradural mass (yellow arrow).



**Figure 2:** Cervicothoracic MRI with contrast. (a) Sagittal T1 MRI show posterior mass (yellow arrow) and (b) axial T1 MRI show an extradural mass (yellow arrow) that was not significantly enhanced after injection of contrast agent.



**Figure 4:** Instrumentation was implanted from C6 to T2 level.



**Figure 3:** Intraoperative finding showed extradural tumor with well demarcated border (white arrow heads) that was very adherent to duramater. After resection of the mass, it showed white and intact duramater (green arrow).

## 8 CASE PRESENTATION

A 28-year-old male presented with neck pain and tingling in both hands for 1 year followed by 3 months of progressive

quadriparesis (i.e., 4/5 upper, 1/5 weakness lower extremities, hypoesthesia below C7, and bilateral lower extremity clonus). The MR showed a posterior, extradural, and isointense soft-tissue mass, measuring  $1.0 \times 0.7 \times 3.0$  cm extending from C6 to T1 resulting in severe cord compression that did not enhance with contrast [Figures 1 and 2]. He underwent a C6–T1 laminectomy for gross total tumor removal followed by an instrumented C6–T2 fusion [Figures 3 and 4]. At surgery, the lesion's capsule was 0.75 cm thick, was adherent to the dura, and wrapped around the cord. Using the operating microscope, the capsule of the tumor was carefully dissected away from the outer layer of the dura, facilitating gross total tumor excision.

### Histopathology examination

The pathology was consistent with the diagnosis of a Xanthogranuloma. The gross examination revealed brownish-white, soft-tissue fragments (i.e., largest measurements of  $2.6 \times 1.9 \times 0.6$  cm), while the microscopic showed fibrous connective tissue with extravasation of

**Table 1:** Summary of the published spinal juvenile xanthogranuloma in adult patients.

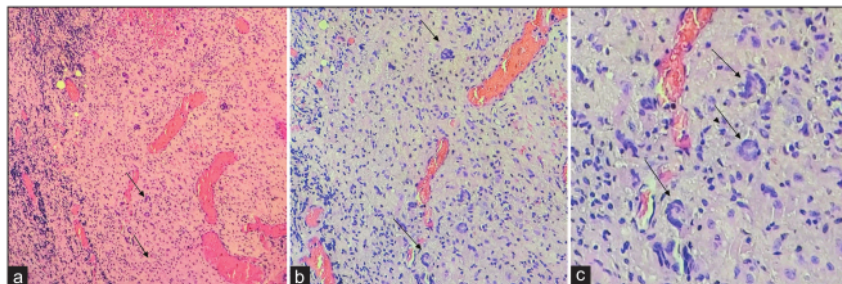
Authors (year)	Age (year)	Sex	Clinical symptom	Duration of onset	Location	Surgical approach	Surgical resection	Postoperative follow-up (time)
Oyama <i>et al.</i> (1997) <sup>[11]</sup>	18	F	Neck pain, gait disturbance, and left hemiparesis,	N/A	C1 IDEM	Suboccipital craniectomy and right hemilaminectomy C1	Total resection	Recovered completely after surgery (N/A)
Iwasaki <i>et al.</i> (2001) <sup>[6]</sup>	41	F	Slow progressive numbness and motor weakness in both legs	N/A	L5-S1 nerve root (Cauda equina)	Laminectomy L1-L5	N/A	N/A
Cao <i>et al.</i> (2008) <sup>[2]</sup>	18	F	Intermittent pain and decreased superficial sensation of right neck	1 week	C2 nerve root with bone destruction	C1 C2 laminectomy and occipital-cervical fusion with instrumentation	Total resection	No relapse of the symptom (2 year)
Agabegi <i>et al.</i> (2011) <sup>[1]</sup>	47	F	Bowel and bladder incontinence, back pain, difficulty ambulating, diminished perineal sensation	2–3 month	L2 vertebral body with bone destruction and intradural extension	T12-L3 decompressive laminectomy and T10–L4 transpedicular instrumentation	Partial resection	+ Post RT Return of bladder and bowel control, back pain was controlled by medication, able to ambulate, gradually developed perineal sensation (8 month)
Jain <i>et al.</i> (2011) <sup>[7]</sup>	22	F	Upper backache in the mid thoracic region	6–7 month	T7 Extradural with bone destruction	Decompressive laminectomy with mechanical fixation	Total	No recurrence of pain (5 month)
Inoue <i>et al.</i> (2011) <sup>[5]</sup>	38	M	Numbness of the right ring and little fingers, weakness of the right grip, difficulty in running	3 month	Intradural-extradural (dumbbell shape) with C8 nerve root involvement	Hemilaminectomy and facetectomy C7–T1	Total	Asymptomatic (2 year)
Kim <i>et al.</i> 2012 <sup>[8]</sup>	67	F	Low back pain, tingling sensation of left leg	2 month	L1 IDEM	Left hemilaminectomy L1 and partial hemilaminectomy T12	Total	Relieved of the symptoms (N/A)
Lee <i>et al.</i> 2012 <sup>[10]</sup>	29	M	Right side weakness and left side numbness below C2	N/A	C1–C2 extradural	Partial laminectomy C1–C2	Total	Fully recovery right hemiparesis (18 month)
Konar <i>et al.</i> , 2013 <sup>[9]</sup>	18	M	Neck pain, progressive quadriparesis, sensory loss below C4, urinary retention	3 month	C2–C4 IDEM	Laminectomy C2–C4	Total	Asymptomatic except mild neck pain (3 month)

(Contd...)

**Table 1:** (Continued).

Authors (year)	Age (year)	Sex	Clinical symptom	Duration of onset	Location	Surgical approach	Surgical resection	Postoperative follow-up (time)
Purohit <i>et al.</i> 2014 <sup>[13]</sup>	18	M	Lower limbs weakness	8 days	T7–T10 extradural	Laminectomy T7–T10	Total	Mild spasticity (9 month)
Pirillo <i>et al.</i> 2017 <sup>[12]</sup>	22	M	Sphincter disturbance and saddle hypoesthesia	9 month	Conus medullaris IDIM	Laminectomy T12–L1 and a median myelotomy	Partial	Recurrence lesion with worsening neurological deficit. Underwent second surgery on 18 month and third surgery on 23 month.
Wolfe <i>et al.</i> 2018 <sup>[15]</sup>	28	F	Back pain and numbness in lower extremity, left foot weakness	1 year	L4 nerve root	Laminectomy L3–L5	Partial	Refused RT, regained full motoric strength, back pain was controlled with medication (27 month)
Present case	28	M	Quadriplegia, hypoesthesia below C7 level	3 month	C6–T1 extradural	C6–T1 laminectomy and cervical-thoracic fusion (C6–T2) with instrumentation	Total	Regained full motoric strength and sensation (2 month)

F: Female, IDEM: Intradural extra medullar, IDIM: Intradural intra medullar, M: Male, N/A: Not available, RT: Radiotherapy



**Figure 5:** Histopathology revealed Touton giant cells (a) (b) (c) (black arrows) on a background of lymphocytes and histiocytes, corresponds to Xanthogranuloma.

erythrocytes, xanthoma cells, lymphocytes, histiocytes, and Touton giant cells [Figure 5].

#### Postoperative course

On postoperative day 2, the patient's lower extremity strength normalized while the sensation improved. He was discharged a few days later, was fully neurologically intact within 2 postoperative months, and continues to be followed with repeat MRI studies (i.e., every 6–12 months) that have remained negative for tumor recurrence.

## DISCUSSION

### Frequency

We combined our case with the 12 other cases of spinal JXG found in the literature [Table 1]. These 13 cases of JXG included six males<sup>[5,9,10,12,13]</sup> and seven females<sup>[1,2,6–8,11,15]</sup>, typically in their late 20s to 30s [Table 2].<sup>[3]</sup> Most were located in the cervical spine, with only our patient having a spinal tumor at the cervicothoracic junction [Table 2]. JXG lesions occurred intradural extramedullary, intradural intramedullary, extradural, within vertebral bodies, involving

**Table 2:** Cases characteristic demography.

Sex		
Male	n (%)	6 (46%)
Female	n (%)	7 (54%)
Age (year)	Mean±SD	30.3±14.0
Onset to presentation (month)	Mean±SD	4.1±3.6
Spinal level		
Cervical	n (%)	6 (46%)
Thoracic	n (%)	2 (15%)
Lumbar	n (%)	5 (38%)
Resection status		
Total	n (%)	9 (69%)
Partial	n (%)	3 (23%)

SD: Standard deviation; n: Number of people

nerve roots, or a combination of these features [Table 1].<sup>[9]</sup> As these lesions were slow-growing, symptoms/signs were usually gradual in onset (Range 8 days to 1 year; average 4.1 months: D 3.6), with resultant neurological deficits reflecting tumor locations [Table 2].

### Etiology of JXG

JXG is a histiocytic disorder of unknown etiology that belongs to the non-Langerhans dendritic cell disorders.<sup>[4]</sup> They are most commonly found in the early childhood with >15–20% of patients having lesions at birth; 75% of cases occur during the 1<sup>st</sup> year of life, with up to 81% demonstrate solitary cutaneous lesions that spontaneously regress.<sup>[4]</sup> About 5–10% of JXG are extracutaneous in location (i.e., eyes, lungs, heart, testis, oral mucosa, and central nervous system), with spinal JXGs being extremely rare.<sup>[3]</sup>

### Treatment option

Although gross total excision is the treatment of choice to attain cures for JXG, treatment options may be limited restricted by their location and/or adherence to surrounding critical structures.<sup>[14]</sup> If gross total resection of JXG is not feasible, despite no clear treatment protocols, adjuvant radiotherapy may be utilized.<sup>[1,2]</sup> In this review, three out of 13 patients (23%) undergoing just partial tumor resection required additional surgery (One patient), additional radiotherapy (i.e., with gradual improvement over 8 months), and one who refused radiotherapy controlled their residual back pain with oral medications.

### CONCLUSION

Spinal JXG in adults are extremely rare and should ideally be treated with gross total tumor excision to achieve the best long-term results.

### Declaration of patient consent

The authors certify that they have obtained all appropriate patient consent.

### Financial support and sponsorship

Nil.

### Conflicts of interest

There are no conflicts of interest.

### REFERENCES

- Agabegi SS, Iorio TE, Wilson JD, Fischgrund JS. Juvenile xanthogranuloma in an adult lumbar spine: A case report. *Spine (Phila Pa 1976)* 2011;36:E69-73.
- Cao D, Ma J, Yang X, Xiao J. Solitary juvenile xanthogranuloma in the upper cervical spine: Case report and review of the literatures. *Eur Spine J* 2008;17:S318-23.
- Collie JS, Harper CD, Fillman EP. Juvenile xanthogranuloma: In StatPearls. Treasure Island, FL: StatPearls Publishing; 2022.
- Dehner LP. Juvenile xanthogranulomas in the first two decades of life: A clinicopathologic study of 174 cases with cutaneous and extracutaneous manifestations. *Am J Surg Pathol* 2003;27:579-93.
- Inoue H, Seichi A, Yamamuro K, Kojima M, Kimura A, Hoshino Y. Dumbbell-type juvenile xanthogranuloma in the cervical spine of an adult. *Eur Spine J* 2011;20:S343-7.
- Iwasaki Y, Hida K, Nagashima K. Cauda equina xanthogranulomatosis. *Br J Neurosurg* 2001;15:72-3.
- Jain A, Mathur K, Khatri S, Kasana S, Jain SK. Rare presentation of juvenile xanthogranuloma in the thoracic spine of an adult patient: Case report and literature review. *Acta Neurochir (Wien)* 2011;153:1813-8.
- Kim SY, Park HJ, Lee SY, Chung EC, Park HW, Kook SH, et al. MRI findings of juvenile xanthogranuloma of the spinal cord: A case report. *J Korean Soc Radiol* 2013;68:251.
- Konar S, Pandey P, Yasha TC. Solitary juvenile xanthogranuloma in cervical spine: Case report and review of literature. *Turk Neurosurg* 2014;24:102-7.
- Lee SJ, Jo DJ, Lee SH, Kim SM. Solitary xanthogranuloma of the upper cervical spine in a male adult. *J Korean Neurosurg Soc* 2012;51:54.
- Oyama H, Ikeda K, Inoue S, Katsumata T, Murakami S, Doi A. A case of intradural xanthogranuloma in the upper cervical spine. *No Shinkei Geka* 1997;25:745-8.
- Pirillo V, Prontera A, Rizzo P, Cecchi PC, Maffei M, Schwarz A. A rare case of intramedullary solitary juvenile xanthogranuloma of the lumbar spine in the adult: A case report. *J Spine Surg* 2017;3:504-8.
- Purohit D, Chanduka A, Sharma V, Mittal R, Singhvi S. Juvenile xanthogranuloma of adult spine: A rare case and review of literature. *Asian J Neurosurg* 2014;9:239-9.
- Stover DG, Alapati S, Regueira O, Turner C, Whitlock JA. Treatment of juvenile xanthogranuloma. *Pediatr Blood Cancer* 2008;51:130-3.

15. Wolfe C, El Ahmadieh TY, Aoun SG, Vance AZ, Hatanpaa KJ, Wohlfeld B. Intradural juvenile xanthogranuloma with involvement of multiple nerve roots: A case report and review of the literature. *World Neurosurg* 2018;119:189-96.

**How to cite this article:** Baskoro W, Pratama MF, Christi AY, Faris M, Subagio EA, Wicaksono P, *et al.* Case of compressive myelopathy due to juvenile xanthogranuloma of cervicothoracic junction in a 28-year-old male. *Surg Neurol Int* 2023;14:17.

#### **1** **Disclaimer**

The views and opinions expressed in this article are those of the authors and do not necessarily reflect the official policy or position of the Journal or its management. The information contained in this article should not be considered to be medical advice; patients should consult their own physicians for advice as to their specific medical needs.

# Case of compressive myelopathy due to juvenile xanthogranuloma of cervicothoracic junction in a 28-year-old male

## ORIGINALITY REPORT

**20%**  
SIMILARITY INDEX

**17%**  
INTERNET SOURCES

**18%**  
PUBLICATIONS

**0%**  
STUDENT PAPERS

## PRIMARY SOURCES

- 1** [shiga-med.repo.nii.ac.jp](http://shiga-med.repo.nii.ac.jp) Internet Source **6%**
- 2** Ayu Yoniko Christi, Wisnu Baskoro, Bidari Kameswari, Irfaanstio Akbar Hakim, Vega Sola Gracia Pangaribuan, Andrianto Purnawan. "Extradural malignant peripheral nerve sheath tumor of the thoracic spine: A rare case report", Surgical Neurology International, 2021 Publication **3%**
- 3** [repository.unair.ac.id](http://repository.unair.ac.id) Internet Source **3%**
- 4** [eprints.iums.ac.ir](http://eprints.iums.ac.ir) Internet Source **3%**
- 5** Hirokazu Inoue, Atsushi Seichi, Kenichi Yamamuro, Masahiro Kojima, Atsushi Kimura, Yuichi Hoshino. "Dumbbell-type juvenile xanthogranuloma in the cervical spine of an adult", European Spine Journal, 2011 **1%**



---

6	<a href="http://www.statpearls.com">www.statpearls.com</a> Internet Source	1 %
7	<a href="http://www.thieme-connect.com">www.thieme-connect.com</a> Internet Source	1 %
8	<a href="http://caelum.ucv.ve">caelum.ucv.ve</a> Internet Source	1 %
9	<a href="http://www.mdpi.com">www.mdpi.com</a> Internet Source	1 %
10	<a href="http://link.springer.com">link.springer.com</a> Internet Source	<1 %

---

Exclude quotes Off

Exclude matches < 10 words

Exclude bibliography On

# Case of compressive myelopathy due to juvenile xanthogranuloma of cervicothoracic junction in a 28-year-old male

---

GRADEMARK REPORT

---

FINAL GRADE

GENERAL COMMENTS

**/0**

---

PAGE 1

---

PAGE 2

---

PAGE 3

---

PAGE 4

---

PAGE 5

---

PAGE 6

---