

Indonesian Journal of Anesthesiology and Reanimation (IJAR)

eISSN : 2686021X | pISSN :

Universitas Airlangga



S3

Sinta Score

1

H-Index

1

H5-Index

9

Citations

9

5 Year Citations

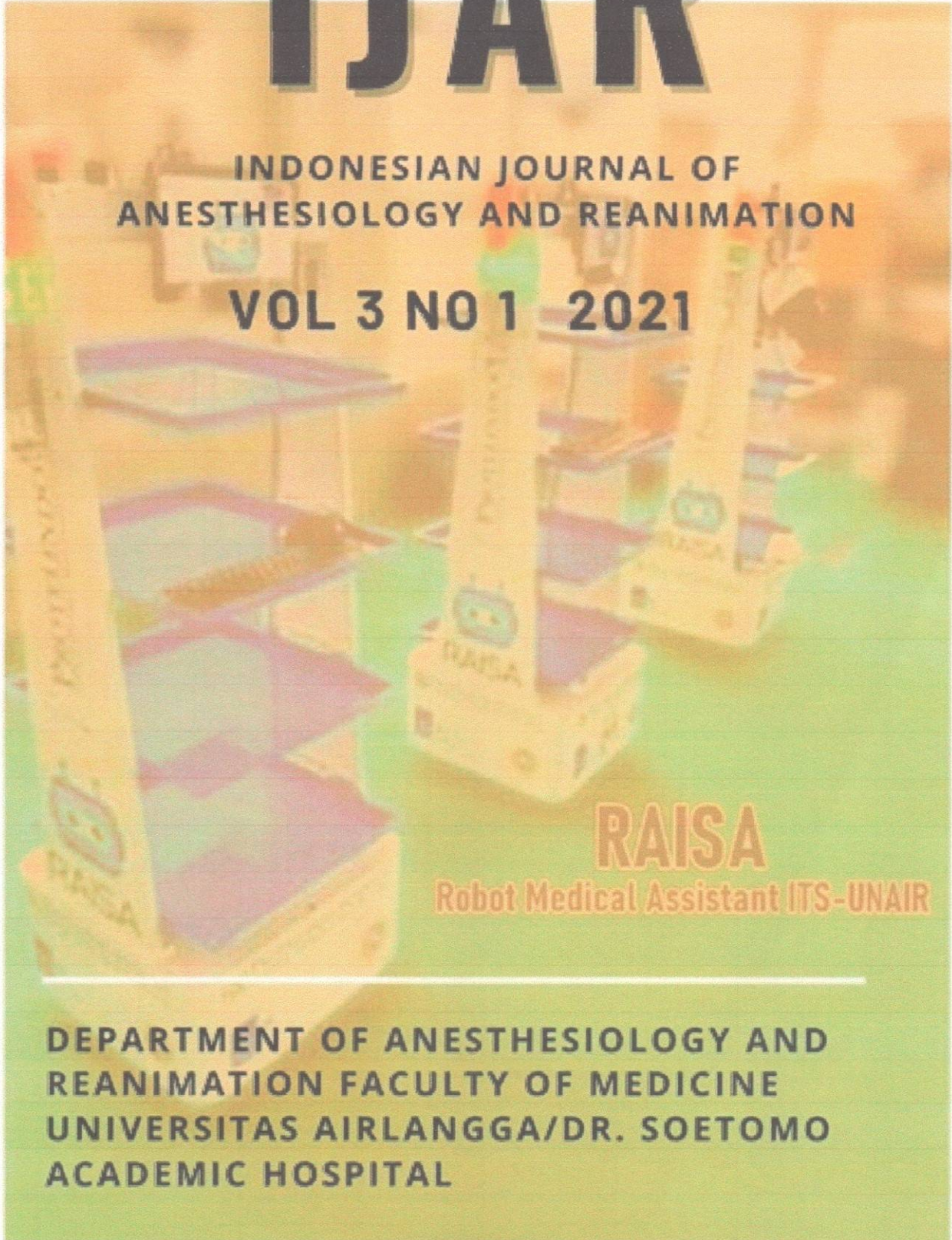


p-ISSN: 2722-4554
e-ISSN: 2686-021X

IJAR

INDONESIAN JOURNAL OF
ANESTHESIOLOGY AND REANIMATION

VOL 3 NO 1 2021



RAISA
Robot Medical Assistant ITS-UNAIR

DEPARTMENT OF ANESTHESIOLOGY AND
REANIMATION FACULTY OF MEDICINE
UNIVERSITAS AIRLANGGA/DR. SOETOMO
ACADEMIC HOSPITAL



INDONESIAN JOURNAL OF ANESTHESIOLOGY AND REANIMATION

Published by: Department of Anesthesiology and Reanimation, Faculty of Medicine, Universitas Airlangga

P-ISSN: 2722-4554 / E-ISSN: 2686-021X

[HOME](#) [ABOUT](#) [LOGIN](#) [REGISTER](#) [SEARCH](#) [CURRENT](#) [ARCHIVES](#) [ANNOUNCEMENTS](#)

[Home](#) > [About the Journal](#) > [Editorial Team](#)

EDITORIAL TEAM

CHIEF EDITOR

Prihatma Kriswidyatomo, dr SpAn, Department of Anesthesiology and Reanimation, Faculty of Medicine, Universitas Airlangga/Dr. Soetomo General Hospital Surabaya, Indonesia

MANAGING EDITOR

Dr. Anna Surgean Veterini, dr., SpAn., KIC., Department of Anesthesiology and Reanimation, Faculty of Medicine, Universitas Airlangga/Dr. Soetomo General Hospital, Surabaya, Indonesia, Indonesia
Soni Sunarso Sulistiawan, dr., SpAn., FIPM., KMN, Department of Anesthesiology and Reanimation, Faculty of Medicine, Universitas Airlangga/Dr. Soetomo General Hospital, Surabaya, Indonesia, Indonesia
Herdiani Sulisty Putri, dr., SpAn., FIPM, Department of Anesthesiology and Reanimation, Faculty of Medicine, Universitas Airlangga/Dr. Soetomo General Hospital, Surabaya, Indonesia, Indonesia

EDITORIAL BOARD

Prof An Liong Liem, MD, PhD, FIPP, Amsterdam UMC, Universitair Medische Centra (VUmc) - Medisch Centrum Jan van Goyen, Netherlands
Prof. Dr. Eddy Rahardjo, dr. SpAn., KIC., KAO, Department of Anesthesiology and Reanimation, Faculty of Medicine, Universitas Airlangga/Dr. Soetomo General Hospital, Surabaya, Indonesia, Indonesia
Prof. Dr. Nancy Margarita Rehatta, dr., SpAn., KNA., KMN, Department of Anesthesiology and Reanimation, Faculty of Medicine, Universitas Airlangga/Dr. Soetomo General Hospital, Surabaya, Indonesia, Indonesia
Dr. Mary Suma Cardosa, MBBS, MMed (Anaes), FANZCA, FFPMANZCA, FAIMM, FAMS (Hon), Hospital Selayang, Selangor, Malaysia, Malaysia
Dr. Elizeus Hanindito, dr., SpAn., KIC., KAP, Department of Anesthesiology and Reanimation, Faculty of Medicine, Universitas Airlangga/Dr. Soetomo General Hospital, Surabaya, Indonesia, Indonesia

ADMINISTRATIVE ASSISTANT

Ghea Kusgandari, Fakultas Kesehatan Masyarakat Universitas Airlangga, Indonesia

[View My Stats](#)

INDEXED BY:



P-ISSN: 2722-4554

E-ISSN: 2686-021X



This work is licensed under a [Creative Commons Attribution-ShareAlike 4.0 International License](#).

Accreditation



Download



Instruction for Author

[Guidelines for Authors](#)
[Online Submission](#)
[Disclaimer](#)

Journal Policy

[Focus and Scope](#)
[Publication Ethics](#)
[Article Processing Charge](#)
[Editorial Team](#)
[Peer Reviewers](#)
[Peer Review Process](#)
[Open Access Statement](#)
[Plagiarism Check](#)
[Article Processing Fee](#)
[Archiving](#)
[Copyright](#)
[Contact](#)

Journal Cited in Scopus





INDONESIAN JOURNAL OF ANESTHESIOLOGY AND REANIMATION

Published by: Department of Anesthesiology and Reanimation, Faculty of Medicine, Universitas Airlangga

P-ISSN: 2722-4554 / E-ISSN: 2686-021X

[HOME](#) [ABOUT](#) [LOGIN](#) [REGISTER](#) [SEARCH](#) [CURRENT](#) [ARCHIVES](#) [ANNOUNCEMENTS](#)

[Home](#) > [Archives](#) > **Vol 3, No 1 (2021)**

VOL 3, NO 1 (2021)

INDONESIAN JOURNAL OF ANESTHESIOLOGY AND REANIMATION

TABLE OF CONTENTS

ORIGINAL ARTICLES

Modified Infant Feeding Tube as an Indigenous Endotracheal Tube in Unanticipated Congenital Subglottic Stenosis

PDF
1-9

[doi](#) 10.20473/ijar.V3I12021.1-9

Rahul Gupta, Rama Chatterjee, Neelam Dogra, Dinesh Kumar Barolia, Pratibha Rathore, Pooja Mongia

CASE REPORT

Laparotomy Exploration In Pediatric With Severe Thrombocytopenia: A Report

PDF
10-16

[doi](#) 10.20473/ijar.V3I12021.10-16

Rudy Vitraludyono, Arie Utariani

Opioid-Sparing and Multimodal Analgesia as Parts of Enhanced Recovery After Surgery (ERAS) Applied In The Ksatria Airlangga Floating Hospital

PDF
17-21

[doi](#) 10.20473/ijar.V3I12021.17-21

Pratama Ananda, Bambang Pujo Semedi, Christijogo Sumartono Waloejo, Arie Utariani

REVIEW ARTICLES

Systematic Review Comparison of Endotracheal Intubation Success Rate Using McGrath® Mac Videolaryngoscope with Direct Laryngoscope (Macintosh): A Manikin Studies

PDF
22-33

[doi](#) 10.20473/ijar.V3I12021.22-33

Dicha Niswansyah Auliyah, Lilik Herawati, Prananda Surya Airlangga

The Role of "Robotic Assisted Intensivist" As Solution Of Resources Management In Covid-19 Pandemic Era

PDF
34-38

[doi](#) 10.20473/ijar.V3I12021.34-38

Anna Surgean Veterini, Bambang Pujo Semedi, Cita Rosita Sigit Prakoeswa, Damayanti Tinduh

[View My Stats](#)

INDEXED BY:



GARUDA

PKP|INDEX



Crossref



P-ISSN: 2722-4554

Accreditation



Download



Instruction for Author

[Guidelines for Authors](#)

[Online Submission](#)

[Disclaimer](#)

Journal Policy

[Focus and Scope](#)

[Publication Ethics](#)

[Article Processing Charge](#)

[Editorial Team](#)

[Peer Reviewers](#)

[Peer Review Process](#)

[Open Access Statement](#)

[Plagiarism Check](#)

[Article Processing Fee](#)

[Archiving](#)

[Copyright](#)

[Contact](#)

Journal Cited In Scopus

Scopus®

Case Report

LAPAROTOMY EXPLORATION IN PEDIATRIC WITH SEVERE THROMBOCYTOPENIA: A REPORT

Rudy Vitraludyono¹, Arie Utariani^{2a}¹ Resident of Pediatric Anesthesia Consultant, Department of Anesthesiology and Reanimation, Faculty of Medicine Universitas Airlangga/Dr. Soetomo Academic Hospital, Surabaya, Indonesia² Consultant of Pediatric Anesthesia Division, Department of Anesthesiology and Reanimation, Faculty of Medicine Universitas Airlangga/Dr. Soetomo Academic Hospital, Surabaya, Indonesia^aCorresponding author: arieutariani1955@gmail.com

ABSTRACT

Introduction: Perioperative bleeding in patients was a serious problem in the exploration of laparotomy, especially in severe thrombocytopenia patients. In addition, spontaneous bleeding often occurs in patients who have a platelet count of less than 10 to $20 \cdot 10^9$ cells L^{-1} blood. When surgery must be performed on a patient with platelet counts $< 50 \cdot 10^9$ cells L^{-1} , platelet concentrate was urgently needed to be transfused during induction of anesthesia. Benefits and risks of transfusion before surgery had to be done on a per-patient basis. The available data was very limited in informing perioperative management of patients with thrombocytopenia. However, there have been previous reports of surgery cases in 66-year-old patients with a history of immune thrombocytopenia (ITP) and diagnosed with acute appendicitis related to disseminated intravascular coagulation (DIC), showing excellent postoperative hemostasis. Another one, a seven-year-old boy who has a severe refractory case of ITP with very low platelet counts was referred to urgent splenectomy performed without increase platelet counts before, and then the patient underwent plasma exchange (PE) after surgery. Those reports aimed to present 2 cases of laparotomy exploration in pediatric patients with severe thrombocytopenia. **Case Report:** The first laparotomy exploration was conducted on an 11-year-old boy who suffered acute perforated appendicitis. The patient obtained the general anesthesia with intubation. The second laparotomy exploration was conducted on a 1-month-old baby boy with a weight of 3400 grams who suffered bowel low-level obstruction suspect *Hirschsprung* disease. The patient also obtained general anesthesia with intubation. **Discussion** The general anesthesia with oral intubation was successfully afforded to both patients for the laparotomy exploration with the preoperative condition under severe thrombocytopenia with receiving platelet transfusion therapy before surgery. Complications of spontaneous bleeding at the time of intubation were not found, no bleeding-difficult-intubation during surgery, and no symptoms of spontaneous bleeding were found. Postoperatively, platelet levels gradually improved. **Conclusion:** Exploration of laparotomy in patients with severe thrombocytopenia can be carried out with the support of platelet transfusion and providing general anesthesia with oral intubation to patients.

Keywords: Thrombocytopenia; Pediatrics; Sepsis; Anesthesia

ABSTRAK

Pendahuluan: Perdarahan perioperatif pada pasien merupakan masalah serius dalam eksplorasi laparotomi, terutama pada pasien trombositopenia berat. Selain itu, sering terjadi perdarahan spontan pada pasien yang memiliki jumlah trombosit kurang dari 10 hingga $20 \cdot 10^9$ sel L^{-1} . Padahal harus dilakukan pembedahan kepada penderita dengan jumlah trombosit di bawah $50 \cdot 10^9$ sel L^{-1} , konsentrat platelet sangat dibutuhkan untuk ditransfusikan selama induksi anestesi. Manfaat dan risiko transfusi sebelum operasi harus dinilai per pasien. Data yang tersedia sangat terbatas dalam menginformasikan manajemen perioperatif pasien dengan trombositopenia. Namun, telah ada laporan kasus operasi sebelumnya pada pasien 66 tahun dengan riwayat trombositopenia imun (ITP) dan didiagnosis dengan apendisitis akut terkait dengan koagulasi intravaskular diseminata (DIC), menunjukkan hemostasis pasca operasi yang sangat baik. Satu lagi, seorang anak laki-laki berusia tujuh tahun memiliki kasus ITP refrakter yang parah dengan jumlah trombosit yang sangat rendah dirujuk ke splenektomi segera yang dilakukan tanpa meningkatkan jumlah trombosit sebelumnya, dan kemudian pasien menjalani pertukaran plasma (PE) setelah operasi. Laporan tersebut bertujuan untuk menyajikan 2 kasus eksplorasi laparotomi pada pasien anak dengan trombositopenia berat. **Laporan Kasus:** Eksplorasi laparotomi pertama dilakukan pada anak laki-laki berusia 11 tahun yang menderita apendisitis perforasi akut. Pasien mendapatkan anestesi

umum dengan intubasi. Eksplorasi laparotomi kedua dilakukan pada bayi laki-laki berusia 1 bulan dengan berat 3400 gram yang menderita obstruksi usus tingkat rendah yang diduga penyakit *Hirschsprung*. Pasien juga mendapatkan anestesi umum dengan intubasi. **Pembahasan:** Anestesi umum dengan intubasi oral berhasil diberikan kepada kedua pasien dengan trombositopenia berat pada operasi eksplorasi laparotomi. Terapi transfusi trombosit dilakukan sebelum operasi tanpa menunggu konfirmasi hasil kadar trombosit pasca transfusi. Tidak ditemukan komplikasi perdarahan spontan pada saat intubasi, tidak ditemukan perdarahan-sulit-intubasi selama pembedahan, dan tidak ditemukan gejala perdarahan spontan. Pasca operasi, kadar trombosit berangsur-angsur membaik. Pada kondisi kegawatdaruratan bedah anak, tidak perlu menunggu sampai kadar trombosit di atas 50.10^9 sel L^{-1} mengingat semakin lama ditunda tindakan operasi jg beresiko perburukan kondisi pasien. Namun pemberian transfusi platelet pra operasi tanpa konfirmasi hasil kadar trombosit pasca transfusi diperlukan untuk mengoptimalkan fungsi pembekuan darah pra operasi. **Kesimpulan:** Eksplorasi laparotomi pada pasien trombositopenia berat dapat dilakukan dengan dukungan transfusi platelet dan pemberian anestesi umum dengan intubasi oral kepada pasien.

Kata Kunci: Trombositopenia; Pediatrik; Sepsis; Anesthesia

Article info: Received September 7th 2020, Received in Revised November 6th 2020, Accepted February 9th 2021

INTRODUCTION

The normal thrombocyte counts in humans are usually between 150 to 450.10^9 cells. L^{-1} of blood. Thrombocytes are also known as platelets, which are blood cells for blood clotting responsibility. The vital role of platelets is to control the post-operative bleeding by forming a platelet plug and degranulating, and also to release serotonin, thromboxane A₂, and adenosine diphosphate. When an abnormal condition occurs, the platelet is counted at a low level or less than 150.10^9 cells. L^{-1} ; this abnormal condition is known as thrombocytopenia. If there are no physiological or pathophysiological disorders, the platelet counts are relatively stable during the lifetime of the individual. (1)(2)(3)

Three leading causes may arise thrombocytopenia: a) decrease in platelet production by material in the bone marrow, b) acceleration of platelet destruction, c) platelets splenic sequestration. Platelets come from a giant cell called megakaryocyte which is produced in the bone marrow. In the abnormal bone marrow, the function may lose its function to produce the required amounts of the platelet. A great amount of platelets can be destructed in individuals with blood vessel

wall abnormalities, blood clotting, or the use of artificial heart valves. Besides, the presence of infections, drug use, and other changes in the immune system can also cause platelet destruction. When liver disease or spleen cancer occurs, the spleen can enlarge (splenomegaly), which causes abnormal spleen function resulting in sequestration of the spleen (blood trapped in the spleen). Platelets may be stored in the spleen (up to 90% of total platelets). The result is a decrease in platelet counts in the blood. The thrombocytopenia in splenomegaly is usually not related to bleeding. (2,4)

The decrease in platelet production is found in aplastic anemia, myelodysplastic syndrome (MDS) or leukemia or lymphoma (processes occupying bone marrow), and granulomas in the bone marrow. Acceleration of platelet damage is seen in heparin-induced thrombocytopenia (HIT), drug-induced immune thrombocytopenia (DITP), disseminated intravascular coagulation (DIC), immune thrombocytopenia (ITP), and thrombotic thrombocytopenic purpura (TTP). Splenic sequestration platelets are seen in portal hypertension with splenomegaly that is probably caused by cardiac failure or vena cava thrombosis (Budd-Chiari syndrome),

cirrhosis with congestive splenomegaly, Gaucher disease, viral infections with splenomegaly, and myelofibrosis with myeloid metaplasia and splenomegaly. (2,4)

Several expert mention at least three levels of thrombocytopenia as follows: (1) the mild thrombocytopenia; platelet range is 100 to 149.10^9 cells.L⁻¹, (2) moderate thrombocytopenia; platelet range is 50 to 99.10^9 cells.L⁻¹, and (3) severe thrombocytopenia; counted platelets are less than 50.10^9 cells.L⁻¹). The low level of thrombocytes (platelets) can cause a serious problem in surgery. Spontaneous bleeding often occurs in patients with platelet counts < 10 to 20.10^9 cells L⁻¹ (3).

When surgery has to be done with active hemorrhage, and platelet counts are < 50.10^9 cells.L⁻¹, platelet concentrates are needed to transfused at the time of anesthesia induction. Precautions shall be done to minimize the upper airway trauma during tracheal intubation. Due to the advantage and risks of preoperative transfusion shall be assessed on a patient-by-patient basis, there is limited data that explain the perioperative management of patients with thrombocytopenia. (2)

CASE REPORT

In this report, we presented 2 cases of laparotomy exploration in pediatrics with severe thrombocytopenia. The first patient (Fig 1) was an 11-year-old boy diagnosed with acute perforated appendicitis planned for laparotomy exploration. Physical status ASA 3E, sepsis repair. There was a record for recurrent seizures and thrombocytopenia (31.10^9 cells.L⁻¹). Patients received general anesthesia with intubation. Postoperatively, patients were observed in the HCU room. The patient was given platelet transfusions before and after surgery. 10 IU/ kg platelet

transfusions were given to reach platelet target to be 50.10^9 cells.L⁻¹.

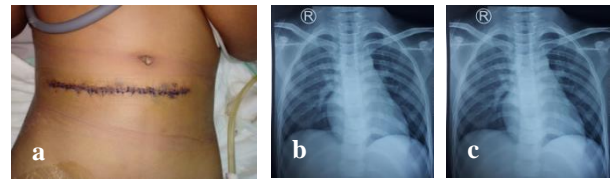


Figure 1. The first patient diagnosed with acute perforated appendicitis

In addition, the second patient (Fig 2) was a 1-month-old boy with a weight of 3400 grams with a diagnosis of bowel low-level obstruction suspect *Hirschsprung* disease, performed *sigmoidostomy* with a pediatric preoperative ASA 3E condition, sepsis (sofa score 3), slightly distended abdomen, thrombocytopenia (44.10^9 cells. L⁻¹), and anemia. The patient was given platelet transfusions before surgery. 10 IU/ kg platelet transfusions were given to reach platelet target to be 50.10^9 cells.L⁻¹. Operation started without waiting for laboratory confirmation result after platelet transfusion.

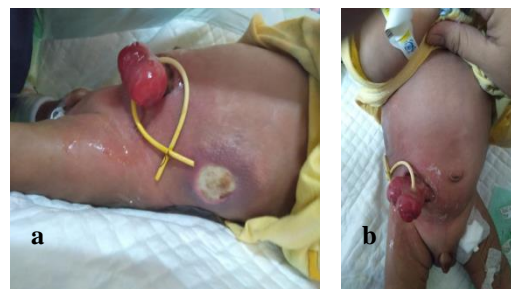


Figure 2. The second patient diagnosed with bowel low-level obstruction suspect *Hirschsprung* disease

This patient obtained general anesthesia with intubation. The general anesthesia with oral intubation was successfully afforded to both patients for the laparotomy exploration with the preoperative condition under severe thrombocytopenia. Complications of spontaneous bleeding at the time of intubation

were not found, no bleeding-difficult-intubation during surgery, and no symptoms of spontaneous bleeding were found. Postoperatively, platelet levels gradually improved.

DISCUSSION

We have reported 2 laparotomy explorations in pediatric with severe thrombocytopenia with receiving platelet transfusion therapy. We are convinced that platelet transfusions are important for patients with thrombocytopenia under preoperative management of emergency surgery.

Thrombocytopenic case also reports about a 7-year-old male patient, with a history of aplastic anemia (SAA) for 18 months who had a traumatic ulcer on the right arm. The patient was referred to a split-thickness skin grafting (STSG) due to an infection in the wound. Preoperative conditions showed: leukocytopenia (white blood cells 124.10^7 cells.L⁻¹), anemia (hemoglobin 6.7 gD⁻¹), thrombocytopenia (platelets 12.10^9 cells.L⁻¹). Preoperative optimization was carried out by transfusion of irradiated red blood cells (RBCs) and single donor plasma (SDP). STSG in patients performed under general anesthesia and platelets were transfused intraoperatively. Complications do not occur after surgery, and the patient's condition improves (5). Pre-operative or intra-operative therapy such as platelet transfusion significantly causes hemostasis to be reached intraoperatively. In our case, we do platelet transfusions before surgery, different from the case above.

Another surgical case involving severe thrombocytopenia is cardiac surgery. Most of the reports of cardiac surgical procedures in patients with low platelet count have been in the setting of ITP and HIT. In the case of the old patient (65 years old, gentleman) with

history of angina and shortness of breath referred to for coronary artery bypass grafting (CABG). Emergency surgery was necessary to do because the number of platelets deteriorates to 19.10^9 cells.L⁻¹, and he was diagnosed with myelodysplastic syndrome (MDS). Platelet transfusion was carried out before surgery so that the intraoperative platelet count increased to 52.10^9 cells.L⁻¹. Postoperative treatment showed a minimal response. After three years, the platelet count was 2.10^9 cells.L⁻¹, and he was treated with platelet and romiplostim transfusions. In conclusion, a low platelet (< $50,10^9$ cells.L⁻¹) should not exclude patients from undergoing CABG. If heart surgery still necessary to do, the possible treatment need to initiate before surgery, then after the right assessment, patients with low preoperative platelet counts can undergo surgery in an appropriate unit with proper monitoring and expertise (1). In the case above, we found that the cause of thrombocytopenia is myelodysplastic syndrome (MDS) whereas in our case it was sepsis. Myelodysplastic syndrome (MDS) decreases platelet production by material in the bone marrow, whereas in sepsis occurs acceleration of platelet destruction.

There are previous reports of cases of severe thrombocytopenia especially severe thrombocytopenia in female patients (66-year-old) with a diagnosis of appendicitis with a history of ITP. Emergency surgery needs to be done immediately because of acute appendicitis associated with DIC. A very low platelet count of 23.10^9 cells.L⁻¹ and decrease to 4.10^9 cells.L⁻¹ before surgery leads to a suspected severe ITP or DIC associated with appendicitis. In this case, pre-operative therapy is performed only with platelet transfusion. Pre-operative therapy significantly causes hemostasis to be reached intraoperatively. High-dose intravenous

immunoglobulin (IVIg) therapy is given postoperatively and causes adequate, increased, and stable platelet counts also excellent hemostasis in patients. In conclusion, the treatment makes it possible to carry out emergency surgery and good outcomes postoperatively (6).

In a pediatric case, a seven-year-old boy has a severe refractory case of ITP with platelet counts $< 10 \times 10^9$ cells.L⁻¹. Patients were unresponsive to conventional therapeutic interventions which subsequently experienced severe gastrointestinal bleeding and renal hematoma and were referred to splenectomy. Urgent splenectomy was performed without increase platelet counts, and then the patient underwent plasma exchange (PE) after surgery. Platelet counts increased rapidly to 57×10^9 cells.L⁻¹ after treatment. Weekly PE treatments were continued in four sessions with rituximab administration. PE, in this case, was likely to reduce platelet antibodies and decrease platelet destruction significantly. The PE approach is recommended to be tried in thrombocytopenic emergencies that involve the immune system (7).

Further, we suggest that the anesthesia with oral intubation in the exploration laparotomy with preoperative severe thrombocytopenia conditions was at high risk of causing Durante complications and post-action on elective surgery. Considering that in both patients the operation was emergency, the anesthesia (with the purpose of source control) was still given to patients even though they were under severe thrombocytopenia. The clinical utility of such subcategorization of thrombocytopenia is limited as the relationship between platelet count and bleeding risk is not linear and depends on platelet function and other patient-specific variables.

The previous studies suggest that the risk of spontaneous bleeding is difficult to predict

until platelet count decreases to extremely low values, below approximately 10×10^9 cells.L⁻¹. Severe thrombocytopenia seems to increase the risk of bleeding with airway manipulation. However, the evidence is limited. A study on 166 patients with a median duration of thrombocytopenia ($< 30 \times 10^9$ cells.L⁻¹) of 18 days, found only one non-epistaxis bleeding involving the airway, a mouth, and throat hemorrhage. The data on the safety of flexible bronchoscopy in thrombocytopenic patients are limited. In a retrospective study of thrombocytopenic patients who underwent bronchoscopy, only one patient experience bleeding, required continuous suctioning and resolved spontaneously. Analysis of 35 patients (platelet count $< 30 \times 10^9$ cells.L⁻¹) show no clinically significant bleeding. Several patients received prophylactic platelet transfusions. However, most of the patients not experience the elevation of platelet counts $> 50 \times 10^9$ cells.L⁻¹

Perioperative bleeding in patients with low platelet counts is high risk and become a challenge during surgery. When the low level of thrombocytes (platelets) can cause a serious problem in laparotomy exploration such as surgical bleeding thus the perioperative treatment is necessary to do to achieve hemostasis condition. Patients with a platelet count of 10×10^9 cells.L⁻¹ more often develop sepsis, adverse pulmonary outcomes, and renal complications. Although the authors did not report on the relationship between platelet count and bleeding.

The two patients in our case having sepsis condition preoperative. Sepsis may lead to precipitous decreases in the platelet count over a short period time, which may be cause disseminated intravascular coagulation (DIC) or to the secretion of neuraminidase by certain bacteria. Neuraminidase then cut sialic acids from platelets and prompted rapid platelet

destruction by the Ashwell-Morrel receptor in the liver.

Acute decompensated DIC is usually found in critically ill patients. DIC can be diagnosed in the setting of oozing from an iv line or venepuncture sites, hypofibrinogenemia, mucocutaneous, possibly deeper tissue bleeding, thrombocytopenia, increased prothrombin, and partial thromboplastin times. These patients experience elevation in D-dimer measurement, although this test may be of little utility in the postoperative patient who would be expected to have an elevated D-dimer at baseline.

There are some methods to increase the preoperative platelet count to the “safe” level. The survival time of platelet transfusion is short. However, the increase in platelet count can be expected to last for around 1 week after infusion. Therefore, platelet transfusion is necessary for preoperative management of emergency surgery. While platelet transfusion is the only currently available therapy capable of achieving a rapid, generally predictable increase in platelet count, we must consider several risks of platelet transfusion.

There are some common complications found in blood product transfusion (including volume overload and febrile non hemolytic transfusion reactions), uncommon but need to be expected (associated with platelet transfusion include transfusion-associated acute lung injury, allergic reactions, clinically-relevant immunomodulation, post-transfusion purpura, infectious risk, and alloimmunization with subsequent ineffectiveness of platelet transfusion). Platelets also have the highest risk of bacterial sepsis of any blood product because they can't store at frozen temperatures. The immunomodulatory effects of blood product transfusion also need to give attention. They are particularly salient in the surgical and critical care populations, for

whom the transient immunosuppression has been demonstrated to increase infection risk and even increase the risk of cancer relapse after oncologic surgery. Given these risks and the relative scarcity of platelets as a resource, proper alternatives to platelet transfusion should always be considered in the thrombocytopenic surgical patient. Non-specific hemostatic agents such as desmopressin, the antifibrinolytic agents (epsilon aminocaproic acid and tranexamic acid), or procoagulant bypass agents [recombinant factor VIIa and activated prothrombin complex concentrates (aPCC)] are a consideration, and the Thrombopoietin receptor agonists (romiplostim, eltrombopag, avatrombopag, and lusutrombopag) can increase the platelet count pharmacologically.

Pre-operative therapy such as platelet transfusion significantly causes hemostasis to be reached intraoperatively. Single platelet concentrate transfusion to a normal patient would be expected to elevate the platelet count to 7000–11000/mm³/m² body surface area with 4 days half-life. In addition, a high-dose intravenous immunoglobulin (IVIg) therapy which is given postoperatively can cause adequate, increased, and stable platelet amounts also excellent hemostasis for the patient, but this therapy enabled us to perform emergency surgery and achieve a good postoperative course. In conclusion, the treatment makes it possible to carry out emergency surgery and good outcomes postoperatively (5).

If there was no platelet transfusion before surgery, the patient might undergo plasma exchange (PE) after surgery. PE, severe refractory of ITP case, was likely to reduce platelet antibodies and decrease platelet destruction significantly. The PE approach is recommended to be applied in

thrombocytopenic emergencies that involve the immune system (7).

CONCLUSION

Perioperative exploration of laparotomy can be initiated by platelet transfusion and accompanied by general anesthesia with oral intubation in pediatric patients under severe thrombocytopenia.

Platelets are involved in hemostasis, and immune responses, and inflammatory also wound healing. A rapid increase in platelet count is necessary for emergency surgery. Some studies have found that platelet transfusions provide successful emergency surgeries.

REFERENCES

1. Ashoub A, Suresh L, Heyman L. Cardiac Surgery in a Patient with Severe Thrombocytopenia: How Low is Too Low? *Ann Card Anaesth.* 2013;16(3):215–7.
2. Kam PC. Anaesthetic Management of A Patient with Thrombocytopenia. *Curr Opin Anaesthesiol.* 2019;21:369–74.
3. Nagrebetsky A, H. Al-Samkari N., Davis D., Kuter, Wiener-Kronish JP. Perioperative Thrombocytopenia: Evidence, Evaluation, and Emerging Therapies. *Br J Anaesth.* 2019;122(1):19–31.
4. Izak M, James BB. Management of Thrombocytopenia. *F1000 Prime Rep.* 2014;6(45):10.
5. Kaur M, Babita G, Aanchal S, Sanjeev S. Child with Aplastic Anemia: Anesthetic Management. *Saudi J Anaesth.* 2012;6(3):298–300.
6. Toyomasu Y, Rinshun S, Hatsuo M, Daihiko E, Koichi I, Fumiaki K, et al. Successful Perioperative Management of A Patient with Idiopathic Thrombocytopenic Purpura Undergoing Emergent Appendectomy: Report of A Case. *Int J Surg Case Reports.* 2013;4:898–900.
7. Eshghi P, Malek F, Madani F, Esfahani H. Therapeutic Plasma Exchange in Pediatric Severe Immune Thrombocytopenia: A Case Report and Literature Review. *Iran J Blood Cancer.* 2015;7(3):119–22.