

Jurnal Widya Medika

eISSN : 26232723 | pISSN :

Universitas Katolik Widya Mandala Surabaya



S4

Sinta Score

3

H-Index

▲
Sinta 4

3

H5-Index

30

Citations

29

5 Year Citations



Widya Mandala
Catholic University
Surabaya - Indonesia

WM
a life-improving university
Since 20 September 1960



SERTIFIKAT



GARUDA

BASE

Google



JURNAL WIDYA MEDIKA

Print ISSN 2338-0373
Online ISSN 2623-2723

VOLUME 6 NOMOR 1 APRIL 2020

Lunardi JH

THE INTERESTING FACT OF PAPILLARY LESIONS IN THE THYROID

Suryadani RI
Hamzah
Rehanna NM
Utariani A

COMPARISON GENERAL ANESTHESIA AND COMBINED SCALP BLOCK WITH ROPIVACAINE 0.5% ON MEAN ARTERIAL PRESSURE, HEARTRATE AND FENTANYL CONSUMPTION DURING CRANIOTOMY

Pasa MA
Soemartono C
Sulistawan SS
Utariani A

EFFECTS OF REGIONAL SCALP BLOCK WITH ROPIVACAINE 0.5% PRECISION AS A PREEMPTIVE ANALGESIA AFTER CRANIOTOMY SURGERY

Bolly HMB
Sutisno AB
Faried A
Yenahse TL
Arifin MZ
Wirjomartani BA

EVALUATION OF TRAUMATIC BRAIN INJURIES DUE TO ALCOHOL INTOXICATION, STUDY IN CENTRAL HOSPITAL IN WEST JAVA

Gustina RE

THE EFFECT OF 1,25 DIHYDROXY VITAMIN D TO THE PHAGOCYTOSIS ACTIVITY OF CHILDREN MACROPHAGE IN TUBERCULOSIS INJECTION

Nugroho N
Faris M
Setiawan A

IDOPATHIC JUVENILE OSTEOPOROSIS WITH PROGRESSIVE KYPHOSCOLIOSIS: A CASE REPORT


Novita BD

CHEMOPROPHYLAISIS VERSUS IMMUNOPROPHYLAISIS TUBERCULOSIS AND LEPROSY INFECTION

Listiawaty R
Sugiarto
Wulandari E

ANALYSIS OF CUSTOMER SATISFACTION LEVEL OF QUALITY OF FRONTLINE OFFICE SERVICES OF BPJS OFFICE OF JAMBI BRANCH

Jurnal Resmi Fakultas Kedokteran Universitas Katolik Widya Mandala Surabaya
Official Journal of Widya Mandala Catholic University Surabaya Faculty of Medicine



[Home \(http://journal.wima.ac.id/index.php/JWM/index/\)](http://journal.wima.ac.id/index.php/JWM/index/) / [Archives](#)
[\(http://journal.wima.ac.id/index.php/JWM/issue/archive/\)](http://journal.wima.ac.id/index.php/JWM/issue/archive/) / [Vol 6, No 1 \(2020\)](#)
[http://journal.wima.ac.id/index.php/JWM/issue/view/293\)](http://journal.wima.ac.id/index.php/JWM/issue/view/293)

Vol 6, No 1 (2020)

April

DOI: <https://doi.org/10.33508/jwm.v6i1>
<https://doi.org/10.33508/jwm.v6i1>

Table of Contents

COVER

COVER [IMAGE](http://journal.wima.ac.id/index.php/JWM/article/view/2506/2193)
[http://journal.wima.ac.id/index.php/JWM/article/view/2506/2193\)](http://journal.wima.ac.id/index.php/JWM/article/view/2506/2193)

Table of Content

DAFTAR [PDF](http://journal.wima.ac.id/index.php/JWM/article/view/2505/2192)
 ISI [http://journal.wima.ac.id/index.php/JWM/article/view/2505/2192\)](http://journal.wima.ac.id/index.php/JWM/article/view/2505/2192)



Article V
<https://drive.google.com/file/d/1TOW32h0i...>
 Public
<http://journal.wima.ac.id/index.php/JWM/ab...>

- [ABOUT THE JOUR](#)
- [Onlin](#)
<http://journal.wima.ac.id/index.php/JWM/about...>
- [Editorial Team](#) [/index.php/JWM/about/](#)
- [Reviewer](#) [/index.php/JWM/about/](#)
- [Foc](#)
<http://journal.wima.ac.id/index.php/JWM/about...>
- [Oper](#)
<http://journal.wima.ac.id/index.php/JWM/about...>
- [Publication Ethics](#)
<http://journal.wima.ac.id/index.php/JWM/ab...>
- [Peer](#)
<http://journal.wima.ac.id/index.php/JWM/ab...>
- [Cop](#)
<http://journal.wima.ac.id/index.php/JWM/abo...>

Articles

Visitors (since Oct 19,

[Papillary Lesions In The Thyroid Gland - Interesting Facts](#)

<http://journal.wima.ac.id/index.php/JWM/article/view/2498>

Johanes Hadi Lunardhi

<http://journal.wima.ac.i>

[Comparison General Anesthesia And Combined Scalp Block With Ropivacaine 0.5% On Mean Arterial Pressure, Heartrate And Fentanyl Consumption During Craniotomy.](#)

<http://journal.wima.ac.id/index.php/JWM/article/view/2499>

Rudi Iskandar Suryadani, Hamzah Hamzah, Nancy Margarita Rehatta, Arie Utariani

guest=1).

Visitors

 ID 7,778	 IN 37
 US 427	 MY 34
 KR 125	 TR 31
 SG 45	 FR 23

<http://journal.wima.ac.i>

Pageviews: 21,079



<https://info.flagcounter.c>

[Effects Of Regional Scalp Block With Ropivacaine 0.5% Preincision As A Preemptive Analgesia After Craniotomy Surgery.](#)

<http://journal.wima.ac.id/index.php/JWM/article/view/2500>

R. Muhammad Aviv Pasa, Christrijogo Soemartono, Soni Sunarso Sulistiawan, Arie Utariani

<http://journal.wima.ac.i>

[Evaluation Of Traumatic Brain Injuries Due To Alcohol Intoxication: Study In Central Hospital In West Java](#)

<http://journal.wima.ac.id/index.php/JWM/article/view/2501>

Hendrikus Masang Ban Bolly, Agung Budi Sutiono, Ahmad Faried, Trajanus Laurens Yembise, Muhammad Zafrullah Arifin, Benny Atmadja Wirjomartani

» [For Readers](#)

<http://journal.wima.ac.i>

» [For Authors](#)

<http://journal.wima.ac.i>

» [For Librarians](#)

<http://journal.wima.ac.i>

[The Effect Of 1,25-dihydroxyvitamin D To The](#)

JURNAL WIDYA MEDIKA

Print ISSN 2338-0373
Online ISSN 2623-2723



[Home \(http://journal.wima.ac.id/index.php/JWM/index\)/](http://journal.wima.ac.id/index.php/JWM/index/) [About the Journal \(http://journal.wima.ac.id/index.php/JWM/about\)/](http://journal.wima.ac.id/index.php/JWM/about/) [Editorial Team \(http://journal.wima.ac.id/index.php/JWM/about/editorialTeam\)](http://journal.wima.ac.id/index.php/JWM/about/editorialTeam/)

Editorial Team

Editor in Chief

- **Paul L Tahalele**

([javascript:openRTWindow\('http://journal.wima.ac.id/index.php/JWM/about/editorialTeamBio/824/'\)](http://journal.wima.ac.id/index.php/JWM/about/editorialTeamBio/824/)
, Faculty of Medicine, Widya Mandala Catholic University
Surabaya, Indonesia

Managing Editor

- **Lukas Slamet Rihadi**

([javascript:openRTWindow\('http://journal.wima.ac.id/index.php/JWM/about/editorialTeamBio/825/'\)](http://journal.wima.ac.id/index.php/JWM/about/editorialTeamBio/825/)
, Faculty of Medicine, Widya Mandala Catholic University
Surabaya, Indonesia

- **Jakobus Gerick Pantouw**

([javascript:openRTWindow\('http://journal.wima.ac.id/index.php/JWM/about/editorialTeamBio/826/'\)](http://journal.wima.ac.id/index.php/JWM/about/editorialTeamBio/826/)
(/index.php/JWM/about

, Faculty of Medicine, Widya Mandala Catholic University
Surabaya, Indonesia

- **Filipus Michael Yofrido**

([javascript:openRTWindow\('http://journal.wima.ac.id/index.php/JWM/about/editorialTeamBio/827/'\)](http://journal.wima.ac.id/index.php/JWM/about/editorialTeamBio/827/)
, Faculty of Medicine, Widya Mandala Catholic University
Surabaya, Indonesia

- **Vincentius Widya Iswara**

([javascript:openRTWindow\('http://journal.wima.ac.id/index.php/JWM/about/editorialTeamBio/828/'\)](http://journal.wima.ac.id/index.php/JWM/about/editorialTeamBio/828/)
, Widya Mandala Catholic University Surabaya, Indonesia

[Article](#)

(<https://drive.google.com/file/d/1T0w32h0>

[Public](#)

(/index.php/JWM/ab

[Onli](#)

(/index.php/JWM/abou

[Editorial Team](#) (/ind

[Reviewer](#) (/index.p

[Fo](#)

(/index.php/JWM/abou

[Ope](#)

(/index.php/JWM/abou

[Publication Ethic](#)

(/index.php/JWM/ab

[Peer](#)

(/index.php/JWM/ab

[Co](#)

(/index.php/JWM/ab

[Announcements](#) (/

[Contact Us](#) (/inc

Editorial Boards

- **Inge Watimena**

([javascript:openRTWindow\('http://journal.wima.ac.id/index.php/JWM/about/editorialTeamBio/828'](http://journal.wima.ac.id/index.php/JWM/about/editorialTeamBio/828)
, Faculty of Medicine, Widya Mandala Catholic University
Surabaya, Indonesia

- **Bernadette Dian Novita**

([javascript:openRTWindow\('http://journal.wima.ac.id/index.php/JWM/about/editorialTeamBio/830'](http://journal.wima.ac.id/index.php/JWM/about/editorialTeamBio/830)
, Faculty of Medicine, Widya Mandala Catholic University
Surabaya, Indonesia

- **Gladdy L Waworuntu**

([javascript:openRTWindow\('http://journal.wima.ac.id/index.php/JWM/about/editorialTeamBio/3128'](http://journal.wima.ac.id/index.php/JWM/about/editorialTeamBio/3128)
, Faculty of Medicine, Widya Mandala Catholic University
Surabaya, Indonesia

- **Dyana Sarvasti**

([javascript:openRTWindow\('http://journal.wima.ac.id/index.php/JWM/about/editorialTeamBio/857'](http://journal.wima.ac.id/index.php/JWM/about/editorialTeamBio/857)
, Faculty of Medicine, Widya Mandala Catholic University
Surabaya, Indonesia

- **Bambang Wasito Tjipto**

([javascript:openRTWindow\('http://journal.wima.ac.id/index.php/JWM/about/editorialTeamBio/2641'](http://journal.wima.ac.id/index.php/JWM/about/editorialTeamBio/2641)
, Faculty of Medicine, Widya Mandala Catholic University
Surabaya, Indonesia

- **Chrisdina Puspita Sari**

([javascript:openRTWindow\('http://journal.wima.ac.id/index.php/JWM/about/editorialTeamBio/3129'](http://journal.wima.ac.id/index.php/JWM/about/editorialTeamBio/3129)
, Faculty of Medicine, Widya Mandala Catholic University
Surabaya, Indonesia

Visitors (since Oct 19,
2018) - 88818132
(<http://www.statcounter.com>

View Jurnal Widya

Medika Stats
(<http://statcounter.com/guest=1>)

Visitors

ID 6,279	CN 21
US 369	TR 21
KR 124	MY 21
JP 30	SG 21
IN 28	FR 21

Pageviews: 17,263

FLAG

(<https://info.flagcounter.com>

Journal Help

([javascript:openRTWindow\('http://journal.wima.ac.id/index.php/JWM/about/editorialTeamBio/3129'](http://journal.wima.ac.id)

Information

» **For Readers**

(<http://journal.wima.ac.id>

» **For Authors**

(<http://journal.wima.ac.id>

» **For Librarians**

(<http://journal.wima.ac.id>

Keywords

1,25 dihydroxyvitamin D,

Phagocytosis, Tuberculosis

(<http://journal.wima.ac.id>

subject=1%2C25%20dih

JURNAL

WIDYA MEDIKA

Print ISSN 2338-0373
Online ISSN 2623-2723



[Home \(http://journal.wima.ac.id/index.php/JWM/index\)](http://journal.wima.ac.id/index.php/JWM/index).> **Vol 6, No 1**
(2020) (<http://journal.wima.ac.id/index.php/JWM/issue/view/293>).> **Pasa**
(<http://journal.wima.ac.id/index.php/JWM/article/view/2500/0>)

Effects Of Regional Scalp Block With Ropivacaine 0.5% Preincision As A Preemptive Analgesia After Craniotomy Surgery

*R. Muhammad Aviv Pasa, Christrijogo Soemartono, Soni Sunarso
Sulistiawan, Arie Utariani*

Abstract

Studies reported that more than 55% of patients complained of moderate to severe pain up to 48 hours post craniotomy. Fentanyl is the drug of choice to manage acute pain with disadvantages. Regional scalp block (RSB) technique using local anesthesia may be an alternative for post craniotomy pain management. Objective: to analyze the effects of RSB using ropivacaine 0.5% before incision compared to general anesthesia alone on the pain scale and opioid requirements 24-hour post craniotomy. This is a single-blind randomized experimental study. 14 Subjects were divided into two intervention groups. Patients were 18–64 years. GCS (Glasgow

[Article](#)

(<https://drive.google.com/file/d/1T0w32h0>)

[Public](#)

(</index.php/JWM/about>)

[ABOUT THE JOURNAL](#)

[Onli](#)

(</index.php/JWM/about>)

[Editorial Team](#) (</index.php/JWM/about>)

[Reviewer](#) (</index.php/JWM/about>)

[Fo](#)

(</index.php/JWM/about>)

[Ope](#)

(</index.php/JWM/about>)

[Publication Ethics](#)

(</index.php/JWM/about>)

[Peer](#)

(</index.php/JWM/about>)

[Co](#)

(</index.php/JWM/about>)

[Announcements](#) (</index.php/JWM/about>)

[Contact Us](#) (</index.php/JWM/about>)

Visitors (since Oct 19,
2018): **00018129**

intervention groups. Patients were 16–67 years, GCS (Glasgow Coma Scale) 15, physical status ASA (American Society of Anesthesiologists) 1–3, undergoing craniotomy. In this study, the mean of fentanyl dose in RSB group was smaller than the group without RSB, which was statistically significant ($p=0.017$). Pain was also significantly reduced in RSB group at 30 minutes ($p=0.009$), 1 hour ($p=0.003$), 2 hours ($p=0.003$), 4 hours ($p=0.001$), 8 hours ($p=0.050$), and 12 hours ($p=0.003$) post-surgery. There was no difference in pain scale between the two groups at 24 hours post-surgery ($p=0.393$). RSB using ropivacaine 0.5% preincision is more effective in reducing pain scale up to 12 hours and also reduced the requirement of fentanyl within 24-hours post craniotomy compared to general anesthesia alone.

Save to Mendeley



[https://www.mendeley.com/import/?](https://www.mendeley.com/import?url=http%3A%2F%2Fjournal.wima.ac.id%2Findex.php%2FJWM%2Farticle%2Fview%2F2500)

[url=http%3A%2F%2Fjournal.wima.ac.id%2Findex.php%2FJWM%2Farticle%2Fview%2F2500](http://journal.wima.ac.id/index.php/JWM/article/view/2500)

Keywords

Craniotomy, Fentanyl, Pain Scale, Regional Scalp Block

Full Text:

[PDF](http://journal.wima.ac.id/index.php/JWM/article/view/2500/2186)

<http://journal.wima.ac.id/index.php/JWM/article/view/2500/2186>

References

Arbour C., Vranic J.T., Loisel C.G., Gelinas C. 2014. Can Fluctuations in Vital Signs Be Used for Pain Assessment in Critically Ill Patients with a Traumatic Brain Injury? Pain Research and Treatment. ID 175794.

Bloomfield EL, Schubert A, Secic M, Barnett G, Shutway F, Ebrahim ZY. 1998. The influence of scalp infiltration with bupivacaine on hemodynamics and postoperative pain in adult patients undergoing craniotomy. *Anesth Analg.* 87(3):579–582.

<http://www.statcounter.com>

[View Jurnal Widya](#)

[Medika Stats](#)

<http://statcounter.com/guest=1>

Visitors

ID 6,279	CN 21
US 369	TR 21
KR 124	MY 21
JP 30	SG 21
IN 28	FR 21

Pageviews: 17,280



<https://info.flagcounter.com>

About The Authors

R. Muhammad Aviv

Pasa

Resident of
Department/SMF of
Anesthesiology and
Intensive Therapy,
Faculty of Medicine,
Airlangga University
– RSUD Dr. Soetomo
Surabaya
Indonesia

Christrijogo

Soemartono

Staff of
Department/SMF of
Anesthesiology and
Intensive Therapy,
Faculty of Medicine,
Airlangga University
– RSUD Dr. Soetomo
Surabaya

- Dunn, L.K., B.I. Naik, E.C. Nemergut, dan M.E. Drieux. 2016. Post-Craniotomy Pain Management: Beyond Opioids. *Current Neurology and Neuroscience Reports*. 16:93.
- Ebru, C., U. Doguş, Y. Timur, dan Y. Ali. 2017. Our Scalp Block Results in Craniotomy Cases. *J of Anesthesia & Intensive Care Medicine* 2(4): 555-592.
- Fanelli G, Casati A, Beccaria P, Aldegheri G, Berti M, Tarantino F, Torri G. 1998. A double-blind comparison of ropivacaine, bupivacaine, and mepivacaine during sciatic and femoral nerve blockade. *Anesth Analg*. Sep;87(3):597-600.
- Gelinas, C. Fillion L., Puntillo K.A., Viens C., Fortier M. 2006. Validation of the Critical-Care Pain Observation Tool in Adult Patients. *American Association of Critical-Care Nurses. Am J Crit Care*. Jul;15(4):420-7.
- Gelinas C. 2010. Nurses' evaluations of the feasibility and the clinical utility of the Critical-Care Pain Observation Tool. *Pain Manag Nurs*. Jun;11(2):115-25.
- Greenberg, M. S. 2010. *Handbook of Neurosurgery*. 7th Edn. New York: Thieme Medical Publishers.
- Greengrass R.A., Klein S.M., D'Ercole F.J., Gleason D.G., Shimer C.L., Steele S.M. 1998. Lumbar plexus and sciatic nerve block for knee arthroplasty: comparison of ropivacaine and bupivacaine. *Can J Anaesth*. Nov;45(11):1094-6.
- Guilfoyle, M.R., A. Helmy, D. Duane, dan P.J. Hutchinson, P.J. 2013. RSB for Postcraniotomy Analgesia: A Systematic Review and Meta-Analysis. *J. Anesthesia & Analgesia* 116: 1093–1102.
- Hansen, T.G. 2004. Ropivacaine: a Pharmacological Review. *Expert Nerv. Neurotherapeutic*. 4(5).
- Jia, Y., C. Zhao, H. Ren, dan T. Wang. 2019. Pre-emptive scalp infiltration with dexamethasone plus ropivacaine for postoperative pain after craniotomy: a protocol for a prospective, randomized controlled trial. *Journal of Pain Research* 12: 1709–1719.
- Lord B. and Woollard M. 2011. The reliability of vital signs in estimating pain severity among adult patients treated by

Indonesia

Soni Sunarso

Sulistiawan

Staff of

Department/SMF of
Anesthesiology and

Intensive Therapy,

Faculty of Medicine,

Airlangga University

– RSUD Dr. Soetomo

Surabaya

Indonesia

Arie Utariani

Staff of

Department/SMF of
Anesthesiology and

Intensive Therapy,

Faculty of Medicine,

Airlangga University

– RSUD Dr. Soetomo

Surabaya

Indonesia

Journal Help
(javascript:openHe

Information

» **For Readers**

(<http://journal.wima.ac.i>

» **For Authors**

(<http://journal.wima.ac.i>

» **For Librarians**

(<http://journal.wima.ac.i>

paramedics. *Emerg Med J*; 28:147e150.

Kaye, A.D., R.D. Urman, dan N.Vadivelu. 2018. *Essentials of Regional Anesthesia*. Cambridge: Springer International Publishing AG. 446-452.

Song, J., Li, L. Yu, P. Gao, T. Liu, K. 2015. Preemptive scalp infiltration with 0.5% ropivacaine and 1% lidocaine reduces postoperative pain after craniotomy. *Acta Neurochirurgica*, Issue: 157(6):993–998.

Vacas, S. And Van de Wiele, B. 2017. Designing a pain management protocol for craniotomy: A narrative review and consideration of promising practices. *Surgical Neurology International*. Issue; 8: 291.

Vadivelu, N., Kai, A. Tran, D. Kodumudi, G. Legler, A. & Ayrian, E. 2016. Options for perioperative pain management in neurosurgery. *Journal of Pain Research*. Issue: :9 37–47.

Velayudhan, A., Bellingham, G., Morley-Forster, P. 2014. Opioid-induced hyperalgesia. *Continuing Education in Anaesthesia. Critical Care & Pain J*. Vol:14 (3)

Wahyuhadi J., W. Suryaningtyas, R.I. Susilo, M. Faris, dan T. Apriawan. 2014. *Pedoman Tatalaksana Cedera Otak*. RSUD dr. Soetomo Fakultas Kedokteran Universitas Airlangga. 2:1.

Yang, X., J. Ma, K. Li, L. Chen, dan R. Dong. 2019. A Comparison Effect of Scalp Nerve Block and Local Anesthetic Infiltration on Inflammatory Respons, Hemodynamic Respons, and Postoperative Pain in Patient Undergoing Craniotomy for Cerebral Aneurysms: a Randomized Control Trial. *BMC Anesthesiol*. 19:91.

DOI: <https://doi.org/10.33508/jwm.v6i1.2500>

(<https://doi.org/10.33508/jwm.v6i1.2500>)

Keywords

[1,25 dihydroxyvitamin D](#),
[Phagocytosis, Tuberculosis](#)
(<http://journal.wima.ac.id>
[subject=1%2C25%20dih](#)
[Alcohol, Intoxication,](#)
[traumatic brain injury,](#)
[prevalence](#)
(<http://journal.wima.ac.id>
[subject=Alcohol%2C%20](#)
[Craniotomy, Fentanyl, Pain](#)
[Scale, Regional Scalp Block](#)
(<http://journal.wima.ac.id>
[subject=Craniotomy%2C](#)
[Craniotomy, fentanyl, heart](#)
[Rate, MAP, scalp block](#)
(<http://journal.wima.ac.id>
[subject=Craniotomy%2C](#)
[Customer Satisfaction,](#)
[Importance Performance](#)
[Analysis](#)
(<http://journal.wima.ac.id>
[subject=Customer%20Sa](#)
[Diarrhea, exclusive](#)
[breastfeeding, immunity](#)
[properties](#)
(<http://journal.wima.ac.id>
[subject=Diarrhea%2C%2](#)
[Human papillomavirus \(HPV\),](#)
[human immunodeficiency](#)
[virus \(HIV\), HPV vaccination.](#)
(<http://journal.wima.ac.id>
[subject=Human%20papil](#)
[Intravascular Lymphoma,](#)
[Lymphoma Non-Hodgkin](#)
(<http://journal.wima.ac.id>
[subject=Intravascular%2](#)
[Kyphoscoliosis, Children,](#)
[Osteoporosis](#)
(<http://journal.wima.ac.id>
[subject=Kyphoscoliosis%](#)
[Malaria. Acmena](#)

***EFFECTS OF REGIONAL SCALP BLOCK WITH ROPIVACAINE 0.5%
PREINCISION AS A PREEMPTIVE ANALGESIA AFTER CRANIOTOMY
SURGERY***

R. Muhammad Aviv Pasa ¹⁾, Christrijogo Soemartono ²⁾, Soni Sunarso Sulistiawan ³⁾,
Arie Utariani ⁴⁾

ABSTRACT

Studies reported that more than 55% of patients complained of moderate to severe pain up to 48 hours post craniotomy. Fentanyl is the drug of choice to manage acute pain with disadvantages. Regional scalp block (RSB) technique using local anesthesia may be an alternative for post craniotomy pain management. Objective: to analyze the effects of RSB using ropivacaine 0.5% before incision compared to general anesthesia alone on the pain scale and opioid requirements 24-hour post craniotomy. This is a single-blind randomized experimental study. 14 Subjects were divided into two intervention groups. Patients were 18–64 years, GCS (Glasgow Coma Scale) 15, physical status ASA (American Society of Anesthesiologists) 1–3, undergoing craniotomy. In this study, the mean of fentanyl dose in RSB group was smaller than the group without RSB, which was statistically significant ($p=0.017$). Pain was also significantly reduced in RSB group at 30 minutes ($p=0.009$), 1 hour ($p=0.003$), 2 hours ($p=0.003$), 4 hours ($p=0.001$), 8 hours ($p=0.050$), and 12 hours ($p=0.003$) post-surgery. There was no difference in pain scale between the two groups at 24 hours post-surgery ($p=0.393$). RSB using ropivacaine 0.5% preincision is more effective in reducing pain scale up to 12 hours and also reduced the requirement of fentanyl within 24-hours post craniotomy compared to general anesthesia alone.

Keywords: Craniotomy, Fentanyl, Pain Scale, Regional Scalp Block.

ABSTRAK

Penelitian menunjukkan lebih dari 55% pasien melaporkan nyeri sedang hingga berat sampai dengan 48 jam pascakraniotomi. Penggunaan fentanyl merupakan pilihan untuk menangani nyeri akut tetapi memiliki efek samping merugikan. Teknik *regional scalp block* (RSB) dengan anestesi lokal dapat menjadi pilihan tatalaksana nyeri pascakraniotomi. Objektif: menganalisis efek kombinasi RSB menggunakan ropivacain 0,5% sebelum insisi dibandingkan dengan anestesi umum saja terhadap skala nyeri dan

jumlah kebutuhan opioid selama 24 jam pascakraniotomi. Penelitian ini merupakan analitik *experimental single blind randomized*. Terdapat 2 kelompok perlakuan. Pasien usia 18-64 tahun dengan GCS (Glasgow Coma Scale) 15 dan status fisik ASA (*American Society of Anesthesiologists*) 1-3 yang menjalani operasi kraniotomi. Hasil menunjukkan rerata penggunaan fentanyl pada kelompok RSB lebih kecil dibandingkan dengan kelompok tanpa RSB ($p=0,017$). Kelompok RSB bermakna mengurangi nyeri pada waktu 30 menit ($p=0,009$), 1 jam ($p=0,003$), 2 jam ($p=0,003$), 4 jam ($p=0,001$), 8 jam ($p=0,050$), dan 12 jam ($p=0,003$) pascakraniotomi. Tidak terdapat perbedaan skala nyeri yang bermakna ($p=0,393$) pada 24 jam pascakraniotomi. Penggunaan anestesi umum kombinasi RSB menggunakan ropivacain 0,5% prainsisi lebih efektif dalam menurunkan skala nyeri sampai dengan 12 jam dan membutuhkan dosis akumulasi fentanyl lebih sedikit dalam 24 jam pascakraniotomi dibandingkan dengan anestesi umum tanpa RSB.

Kata Kunci : Kraniotomi, Fentanyl, *Regional Scalp Block*, Skala Nyeri.

1) Resident of Department/SMF of Anesthesiology and Intensive Therapy, Faculty of Medicine, Airlangga University – RSUD Dr. Soetomo Surabaya, Email : *apipasa@yahoo.com*. 2,3,4) Staff of Department/SMF of Anesthesiology and Intensive Therapy, Faculty of Medicine, Airlangga University – RSUD Dr. Soetomo Surabaya

INTRODUCTION

A craniotomy is a neurosurgical technique performed by opening or removing a portion of the skull as a surgical procedure with a specific purpose. The indications include biopsy or resection of an intracranial mass lesion, treatment of intracranial vascular pathology, epilepsy treatment, and management of trauma (Greenberg, 2010; Vadivelu *et al.*, 2016). In 2007, in the United States of America, there were estimated to be 70.849 tumor craniotomy surgical procedure, 2.237 vascular

surgical craniotomy procedure, and 56.405 other craniotomy surgical procedure (Vacas and Van de Wiele, 2017). Whereas at Dr. Soetomo General Hospital Surabaya in 2013, there were 1.411 patients with brain injury, 166 of them were severe brain injury, and 18,87% - 25,27% surgical craniotomy performed of all brain injury patients (Wahyuhadi *et al.*, 2014).

An intracranial procedure was once considered a procedure with a low level of pain compared to other surgical procedures. Subsequent research has

contradicted this finding. As many as 80% of patients report moderate to severe pain up to 48-hours post intracranial surgery. Retrospective study shows that 70% of patients experience moderate to severe pain in the first 24-hour postoperative craniotomy (Dunn *et al.*, 2016). About 55-87% reported have moderate to severe pain in the first 24 hours postoperative (Jia *et al.*, 2019). Another study reports that about 40 – 84% of patients have moderate to severe pain in the first 12-hour postoperative (Song *et al.*, 2015). Pain management of postoperative craniotomy needs to be considered and challenging the anesthesiologist (Ebru *et al.*, 2017).

Fentanyl is an option for treating acute pain postoperative craniotomy and has side effects such as sedation, miosis, hypercarbia, respiratory distress, postoperative nausea-vomiting, intracranial hypertension, masking effect on acute cerebral edema, neurological alteration, or disturbances in neurological assessment (Velayudhan, Bellingham and Morley-Forster, 2014; Vadivelu *et al.*, 2016; Ebru *et al.*, 2017). Many physicians choose to reduce postoperative opioids to avoid their adverse effects, so patients do not get adequate analgesia postoperative,

resulting in a disruption in postoperative rehabilitation, depression, increased stress reaction, and hypertension can be triggered by sympathetic mediation so that it has consequences that affect the results of surgery, such as cerebral edema, bleeding, the longer length of stay, even death (Dunn *et al.*, 2016; Jia *et al.*, 2019; Song *et al.*, 2015).

Local or regional anesthesia is better than systemic analgesia in relieving pain postoperative craniotomy. Several clinical studies show scalp infiltration with bupivacaine or ropivacaine can reduce the incidence and severity of postoperative pain. Preemptive analgesia with regional scalp block (RSB) before incision of craniotomy surgery can prevent pain stimulation in the peripheral nerve (Kaye *et al.*, 2018). This can prevent the formation of central hypersensitization (Song *et al.*, 2015).

METHODS

This research is a single-blind randomized trial and has been ethically approved by the Ethics Committee. The sample of this study was 14 subjects who have undergone an elective craniotomy surgery with general anesthesia during November–December 2019 that met the inclusion and exclusion criteria. Those

subjects divided into two groups: the first group of subjects was performed with general anesthesia combined RSB using 0.5% ropivacaine, the second group was performed with general anesthesia without combination.

Each group will be given a special code and randomized, with inclusion criteria: (1) age 18–64 years old; (2) physical status ASA (American Society of Anesthesiologists) 1–3; (3) patient with elective surgery; (4) GCS 15; (5) patient /surrogate agrees to sign informed consent to be involved in the research. Meanwhile, the exclusion criteria of this study were: (1) patient with the anomaly of anatomy; (2) anomaly function and heart rhythm; (3) kidney and liver function impairment; (4) patient has a history of allergic to the medicine used for research; (5) patient who refused to be included in this study. Drop Out Criteria include: (1) failed to RSB; (2) postoperative GCS score less than 8; (3) research data not complete; (4) patient/surrogate resign from the research.

RSB anesthesia technique performed by infiltrating certain nerve points in head. Identification using landmark on 6 area points. Injection with ropivacaine 0.5% every 2 ml in

supraorbital, supratrochlear, zygomaticotemporal, auriculotemporal, minor occipital nerve, major occipital nerve, performed on the right and left of the head. Prepare ropivacaine 0.75% in 20 ml, decrease concentration to 0.5%, is done by pharmacist. The maximum dose is 3 mg/kg body weight. On an adult, with bodyweight 50 kg, maximum and safe dose is 150 mg. The dose of ropivacaine used in this study 120 mg in each patient.

After the operation, the subjects were observed in the intensive care unit until 24 hours postoperative. The pain scale was assessed by Critical Pain Observational Tools (CPOT), and the total fentanyl consumption was recorded after 24 hours. The data collected then being analyzed with SPSS software. The descriptive data valued with their frequency, average, and standard deviation. The significance limit was 5%, and a confidence interval was 95%.

RESULTS

This study was conducted on patients who underwent elective tumor excision craniotomy surgery with GCS 15 at the Central Surgery on Dr. Ramelan hospital. A total of 14 patients were taken from November to December 2019. All subjects were included in the inclusion

criteria, and no one dropped out until the research data collection was completed.

Table 1.1 Subject Characteristic based on age

Age (year)	n (%)		Total 14 (100)	p
	Non-RSB 7 (50%)	RSB 7 (50%)		
< 20	0 (0)	1 (14.3)	1 (7.3)	0.948
21 – 30	0 (0)	0 (0)	0 (0)	
31 – 40	1 (14.3)	0 (0)	1 (7.3)	
41 – 50	1 (14.3)	3 (42.6)	4 (28.4)	
51 – 60	5 (71.4)	2 (28.8)	7 (49.7)	
61 – 65	0 (0)	1 (14.3)	1 (7.3)	
Average	48.42 ± 9.34	48.00 ± 14.29		

*Non-RSB: without regional scalp block; RSB: regional scalp block; p: probability.

*Average (Mean±Standard Deviation).

In this study, the highest distribution of subjects was in the age range of 51-60 years, as much 49.7%, the majority of body weight in the range of 51-60 kg, which is about 50% (table 1.1).

There were no significant differences in weight in subjects in the two treatment groups, duration of surgery, and duration of anesthesia was described in table 1.2.

Table 1.2 Duration of surgery and duration of anesthesia

Parameter	Technique		p
	Non-RSB	RSB	
Anesthesia Duration	357.14 ± 95.78	331.42 ± 91.82	0.617
Surgery Duration	310.71 ± 63.66	275.71 ± 96.23	0.438

*Non-RSB: without regional scalp block; RSB: regional scalp block; p: probability.

*Average (Mean±Standard Deviation).

The average difference in the total dose of fentanyl in RSB compared to non-RSB was 105.72 ± 72.52 micrograms. The mean in the RSB group was smaller compared to the non-RSB

group. Statistically, the mean total fentanyl dose in the two treatment groups was significantly different was described in table 1.3

Table 1.3 Mean total fentanyl dose in Non-RSB and RSB groups

Parameter	Technique		p
	Non-RSB	RSB	
Total Dosage Fentanyl	150.00 ± 67.70	44.28 ± 17.18	0.017

*Non-RSB: without regional scalp block; RSB: regional scalp block; p: probability.

*Average (Mean±Standard Deviation).

The RSB group was statistically significant in reducing pain and maintaining a mild pain at 30min, 1h, 2h, 4h, 8h, and up to 12h postoperative compared to the non-RSB group. There

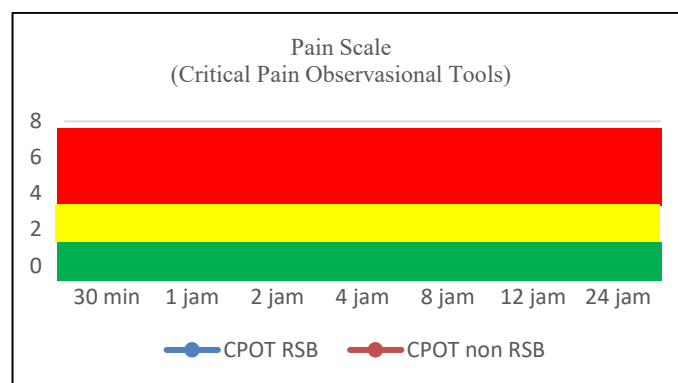
was no significant difference in pain scale at 24 hours postoperative between the RSB and non-RSB groups in table 1.4 and figure 1.

Table 1.4 Mean pain scale 24 hour postoperative

Parameter	Pain Scale (CPOT)		p
	Non-RSB	RSB	
Preoperative	0.57 ± 0.96	1.42 ± 1.13	0.142
30min	1.14 ± 0.89	0.00 ± 0.00	0.009
1h	1.42 ± 0.96	0.00 ± 0.00	0.003
2h	1.57 ± 0.79	0.00 ± 0.00	0.001
4h	2.43 ± 0.98	0.00 ± 0.00	0.001
8h	1.86 ± 0.69	0.85 ± 0.89	0.050
12h	2.29 ± 0.76	0.71 ± 0.76	0.003
24h	2.29 ± 0.95	1.85 ± 0.69	0.393

*Non-RSB: without regional scalp block; RSB: regional scalp block; p: probability.

*Average (Mean±Standard Deviation).



*CPOT RSB: Critical pain observational tools on regional scalp block; CPOT non-RSB: Critical pain observational tools on without regional scalp block

Figure 1 Mean pain scale on 24 hours interval postoperative in RSB and non-RSB groups

Mean changes in Mean Arterial Pressure (MAP) were not significantly different between the RSB and non-RSB

groups at 30min, 1h, 2h, 4h, 8h, and 12h postoperative was described in table 1.5.

Table 1.5 Mean MAP changes in 24 hours post-operative

Parameter	MAP		p
	Non-RSB	RSB	
Preoperative	83.85 ± 6.36	84.28 ± 10.07	0.926
30min	98.00 ± 8.56	90.43 ± 7.59	0.106
1h	93.43 ± 7.98	92.29 ± 6.13	0.769
2h	92.86 ± 5.30	93.29 ± 6.68	0.896
4h	93.71 ± 7.85	90.71 ± 6.63	0.455
8h	90.86 ± 4.22	94.00 ± 7.44	0.350
12h	91.57 ± 9.78	95.43 ± 5.60	0.109
24h	89.28 ± 8.48	101.00 ± 6.16	0.112

*MAP: mean arterial pressure; Non-RSB: without regional scalp block; RSB: regional scalp block; p: probability.

*Average (Mean±Standard Deviation).

There was a statistically significant difference in pulse between RSB and non-RSB groups on 1h, 2h, and 24h postoperative. There were no pulse

differences between the two groups on 30 min, 4h, 8h, 12h postoperative were describe in table 1.6.

Table 1.6 Mean heart rate changes 24 hours post-operative

Parameter	Heart Rate		p
	Non-RSB	RSB	
30min	80.42 ± 5.74	74.43 ± 8.75	0.103
1h	82.00 ± 5.69	75.57 ± 5.06	0.045
2h	85.86 ± 8.36	74.43 ± 7.52	0.020
4h	83.71 ± 6.26	79.14 ± 8.09	0.260
8h	82.57 ± 9.47	80.00 ± 5.68	0.549
12h	83.00 ± 7.77	85.57 ± 6.29	0.509
24h	79.42 ± 8.75	68.00 ± 4.51	0.010

*Non-RSB: without regional scalp block; RSB: regional scalp block; p: probability.

*Average (Mean±Standard Deviation)

In this study, there was no significant difference in respiratory rate

between RSB and non-RSB groups was explained in table 1.7.

Table 1.7 Mean respiratory rate changes in 24 hours post-operative

Parameter	Respiration Rate		p
	Non-RSB	RSB	
Preoperative	16.71 ± 1.25	17.43 ± 0.98	0.244
30min	16.86 ± 1.68	14.57 ± 2.23	0.660
1h	17.14 ± 1.57	15.14 ± 1.86	0.075
2h	17.57 ± 0.78	16.71 ± 2.21	0.373
4h	18.57 ± 0.98	18.14 ± 1.46	0.473
8h	18.14 ± 0.89	18.29 ± 2.14	0.840
12h	18.57 ± 0.97	18.00 ± 2.00	0.584
24h	18.57 ± 0.98	18.57 ± 0.98	1.000

*Non-RSB: without regional scalp block; RSB: regional scalp block; p: probability.

*Average (Mean±Standard Deviation).

DISCUSSION

Effective post craniotomy pain management is associated with reducing morbidity and mortality. This is a challenge for anesthesiologists to provide adequate analgesia to minimize side effects in order to better patient's prognosis and quality of life.

A craniotomy is regularly performed using general anesthesia with additional lidocaine infiltration using epinephrine adjuvant as the standard procedure for the neurosurgeon to minimize pain and scalp bleeding during incision.

RSB technique is a regional anesthesia technique, used as a combination with general anesthesia, which can inhibit scalp nerves in both superficial and deep soft tissue layers (Guilfoyle *et al.*, 2013). This gives an advantage in blunting hemodynamic response during neurosurgical stimulation (for example, in

headpin application and skin incision) in addition to control post-operative pain, therefore, may reduce pain scale and opioid requirements post-surgery.

Previous studies have reported the inconsistent efficacy of infiltration analgesia in the wound site, both pre-incision or post-surgery. In addition, the infiltration technique does not inhibit afferent nociceptive to deeper tissue, such as temporalis muscle (Guilfoyle *et al.*, 2013). Other studies showed meaningful pain scale reduction using RSB during the first 24 hours, but few have compared the efficacy of scalp nerve block and local infiltration as pain control post-surgery.

Based on a study done by Fanelli *et al.*, ropivacaine action duration reached 670 minutes or around 11 hours, while a study by Greengrass *et al.* documented analgesia duration of ropivacaine 0.5% lasted up to 13 hours during peripheral nerve block.

Therefore, subject characteristics are required based on surgery duration ($p=0.617$) and anesthesia duration ($p=0.438$) between RSB and non-RSB group. There was no significant difference between the two groups, which showed homogeneity in both intervention groups.

Pain scale in this study used Critical Care Pain Observation Tools (CPOT) which measure scale based on patient's behavior on four parts, where every part has different category: face expression, body movement, muscle tension, and obedience using ventilator in intubated patients or vocalization in patients who are not intubated. CPOT was used because using CPOT pain scale can be measure in two conditions: intubated or not intubated in the intensive care unit. CPOT is considered valid to measure pain scale in adults, evaluated using behavioral indicators compared to physiological ones. The total score accumulated is between 0 to 8 (Gelinas *et al.*, 2006).

The maximum dose recommendation for ropivacaine is 3 mg/kg body weight (Hansen, 2004). Each patient received 125mg nerve block infiltration; none of them had mild or serious side effects in this study. Inintensive care, evaluation of MAP, pulse, respiratory rate, consciousness, pain scale, and side effect risks were performed up to 24 hours post-surgery.

This study showed that general anesthesia combined with RSB before surgery using ropivacaine 0.5% reduced pain scale during 12 hours interval post-operation and fentanyl consumption as analgesia maintenance and rescue in 24 hours interval post-surgery compared to general anesthesia only. Among 14 subjects, as many as 10 complained mild pain, one subject complained moderate pain, and the others reported no pain. However, 24 hours postsurgery, 78.5% complained of mild pain, and the rest complained of moderate pain, which required rescue analgesia. This data is in accordance with other research that evaluated pain scale post-craniotomy (Dunn *et al.*, 2016; Jia *et al.*, 2019; Yang *et al.*, 2019; Song *et al.*, 2015).

Certain procedures in intensive care affect patient's anxiety, which in turn affect their vital signs, but these variables were not measured in this study. Etiology of vital sign changes may include pain and analgesia rescue using fentanyl (opioid), which has sedative effects and may cause respiratory depression that can cause bias in the evaluation of MAP, pulse, and respiratory rate in subjects. This is made into consideration because of the lack of specificity of vital signs changes to detect pain. Many confounding factors in monitoring MAP, pulse, and respiratory rate in intensive care to detect pain. These

findings have been explained in a study done by Bloomfield et al., which observed patients receiving scalp nerve block who claimed that pain was reduced post-surgery significantly, but pain score was not correlated to pulse or mean blood pressure (MAP) (Bloomfield *et al.*, 2010).

The absence of clinical signs related to stress response does not mean patients do not experience pain; therefore, tools to measure pain objectively should be used. This is supported by the previous study that reported that there was no correlation between hemodynamic response and pain scale (Lord and Wollard, 2011; Gelinas *et al.*, 2006; Gelinas, 2010; Arbour *et al.*, 2014). Despite physiological indicators showing good validity, they are not associated with the pain scale itself (Arbour *et al.*, 2010). This underlines that behavior indicators are more valid in measuring pain scale compared to physiologic ones.

CONCLUSION

Anesthesia combination with RSB ropivacaine 0.5% preincision in craniotomy patients was more effective in reducing pain scale on 30min, 1 h, 2 h, 4 h, 8 h, and 12 h ($p < 0.05$) postoperation compared to the use of general anesthesia alone. There was no significant difference in the CPOT scale on 24 hours post-operative between the two groups ($p > 0.05$). Meanwhile, fentanyl dose accumulation consumed was

fewer in 24-hour receiving general anesthesia alone. There was no significant difference in MAP and respiratory rate between patients receiving combination anesthesia with RSB ropivacaine 0.5% preincision compared to those receiving general anesthesia alone ($p > 0.05$). There were differences ($p < 0.05$) between the quantitative pulse of RSB and non-RSB groups, although only on 1 h, 2 h, and 24 h. Anesthesia technique for patients undergoing craniotomy is suggested to be the combination of RSB pre-incision using ropivacaine 0.5%. Further studies are required to analyze cost-effectivity, analgesics post-operative during the hospital stay, and long-term outcome of chronic pain risks in patients given RSB technique.

REFERENCES

1. Arbour C., Vranic J.T., Loisel C.G., Gelinas C. 2014. Can Fluctuations in Vital Signs Be Used for Pain Assessment in Critically Ill Patients with a Traumatic Brain Injury? *Pain Research and Treatment*. ID 175794.
2. Bloomfield EL, Schubert A, Secic M, Barnett G, Shutway F, Ebrahim ZY. 1998. The influence of scalp infiltration with bupivacaine on hemodynamics and postoperative pain in adult patients undergoing

- craniotomy. *Anesth Analg.* 87(3):579–582.
3. Dunn, L.K., B.I. Naik, E.C. Nemergut, dan M.E. Drieux. 2016. Post-Craniotomy Pain Management: Beyond Opioids. *Current Neurology and Neuroscience Reports.* 16:93.
 4. Ebru, C., U. Doguş, Y. Timur, dan Y. Ali. 2017. Our Scalp Block Results in Craniotomy Cases. *J of Anesthesia & Intensive Care Medicine* 2(4): 555592.
 5. Fanelli G, Casati A, Beccaria P, Aldegheri G, Berti M, Tarantino F, Torri G. 1998. A double-blind comparison of ropivacaine, bupivacaine, and mepivacaine during sciatic and femoral nerve blockade. *Anesth Analg.* Sep;87(3):597-600.
 6. Gelinac, C. Fillion L., Puntillo K.A., Viens C., Fortier M. 2006. Validation of the Critical-Care Pain Observation Tool in Adult Patients. American Association of Critical-Care Nurses. *Am J Crit Care.* Jul;15(4):420-7.
 7. Gelinac C. 2010. Nurses' evaluations of the feasibility and the clinical utility of the Critical-Care Pain Observation Tool. *Pain Manag Nurs.* Jun;11(2):115-25.
 8. Greenberg, M. S. 2010. *Handbook of Neurosurgery.* 7th Edn. New York: Thieme Medical Publishers.
 9. Greengrass R.A., Klein S.M., D'Ercole F.J., Gleason D.G., Shimer C.L., Steele S.M. 1998. Lumbar plexus and sciatic nerve block for knee arthroplasty: comparison of ropivacaine and bupivacaine. *Can J Anaesth.* Nov;45(11):1094-6.
 10. Guilfoyle, M.R., A. Helmy, D. Duane, dan P.J. Hutchinson, P.J. 2013. RSB for Postcraniotomy Analgesia: A Systematic Review and Meta-Analysis. *J. Anesthesia & Analgesia* 116: 1093–1102.
 11. Hansen, T.G. 2004. Ropivacaine: a Pharmacological Review. *Expert Nerv. Neurotherapeutic.* 4(5).
 12. Jia, Y., C. Zhao, H. Ren, dan T. Wang. 2019. Pre-emptive scalp infiltration with dexamethasone plus ropivacaine for postoperative pain after craniotomy: a protocol for a prospective, randomized controlled trial. *Journal of Pain Research* 12: 1709–1719.
 13. Lord B. and Woollard M. 2011. The reliability of vital signs in estimating pain severity among adult patients treated by paramedics. *Emerg Med J;* 28:147e150.

14. Kaye, A.D., R.D. Urman, dan N.Vadivelu. 2018. *Essentials of Regional Anesthesia*. Cambridge: Springer International Publishing AG. 446-452.
15. Song, J., Li, L. Yu, P. Gao, T. Liu, K. 2015. Preemptive scalp infiltration with 0.5% ropivacaine and 1% lidocaine reduces postoperative pain after craniotomy. *Acta Neurochirurgica*, Issue: 157(6):993–998.
16. Vacas, S. And Van de Wiele, B. 2017. Designing a pain management protocol for craniotomy: A narrative review and consideration of promising practices. *Surgical Neurology International*. Issue; 8: 291.
17. Vadivelu, N., Kai, A. Tran, D. Kodumudi, G. Legler, A. & Ayrian, E. 2016. Options for perioperative pain management in neurosurgery. *Journal of Pain Research*. Issue: :9 37–47.
18. Velayudhan, A., Bellingham, G., Morley-Forster, P. 2014. Opioid-induced hyperalgesia. Continuing Education in Anaesthesia. *Critical Care & Pain J*. Vol:14 (3)
19. Wahyuhadi J., W. Suryaningtyas, R.I. Susilo, M. Faris, dan T. Apriawan. 2014. *Pedoman Tatalaksana Cedera Otak*. RSUD dr. Soetomo Fakultas Kedokteran Universitas Airlangga. 2:1.
20. Yang, X., J. Ma, K. Li, L. Chen, dan R. Dong. 2019. A Comparison Effect of Scalp Nerve Block and Local Anesthetic Infiltration on Inflammatory Respons, Hemodynamic Respons, and Postoperative Pain in Patient Undergoing Craniotomy for Cerebral Aneurysms: a Randomized Control Trial. *BMC Anesthesiol*. 19:91.