

Prolonged Resolution

by Sarah Fitria Andini

Submission date: 25-Sep-2023 11:15AM (UTC+0800)

Submission ID: 2175894541

File name: Prolonged_Resolution.pdf (639.45K)

Word count: 5703

Character count: 33317



Case Report

Prolonged Resolution of Intrauterine Fetal Tachyarrhythmia Treatment

Sarah Fitria Andini¹, Manggala Pasca Wardhana^{1,*}, Agus Sulistyono¹, I Ketut Alit Utamayasa², Alisia Yuana Putri³

¹Department of Obstetrics and Gynecology, Faculty of Medicine, Universitas Airlangga, Dr. Soetomo Academic Hospital, Surabaya, Indonesia

²Department of Pediatric, Faculty of Medicine, Universitas Airlangga, Dr. Soetomo Academic Hospital, Surabaya, Indonesia

³Department Cardiology, Faculty of Medicine, Universitas Airlangga, Dr. Soetomo Academic Hospital, Surabaya, Indonesia

ARTICLE INFO

Article history

Receive: 2023-07-14

Received in revised: 2023-08-18

Accepted: 2023-08-18

Manuscript ID: JMCS-2308-2236

Checked for Plagiarism: Yes

Language Editor:

Dr. Fatima Ramezani

Editor who approved publication:

Dr. Ali Delpisheh

DOI:10.26655/JMCHMSCL.2023.12.30

KEYWORDS

Fetal tachyarrhythmia
Transplacental treatment
Prolonged resolution

ABSTRACT

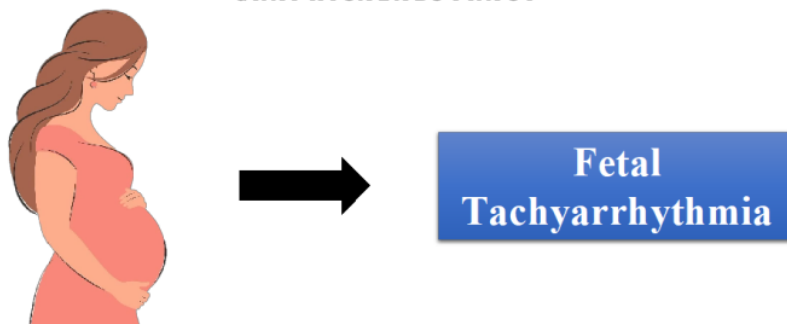
Fetal tachyarrhythmia is a rare condition associated with a high risk of fetoplacental circulatory failure, fetal hydrops, and intrauterine fetal death. This report, present a case of fetal tachyarrhythmia that was successfully managed with a multidisciplinary approach in a tertiary hospital, but with prolonged prenatal resolution. A 36-year-old multigravida was diagnosed with fetal tachyarrhythmia at 30 weeks of gestational age. No secondary cause of fetal tachyarrhythmia was identified. A basic ultrasound examination revealed a normal heart structure without hydrops or polyhydramnios. The fetal heart rate was consistently at 230 bpm during the examination. M-mode echocardiography presented the 1:1 atrioventricular contraction with short intervals, confirming the diagnosis of sustained supraventricular tachycardia. Transplacental treatment was initiated using digoxin at a dose of 0.5 mg, followed by 0.25 mg intravenously every 8 hours. On the fifth day, the arrhythmia was not improved, thus oral combination therapy commenced with digoxin at a dose of 0.25 mg every 12 hours, along with propranolol at a dose of 40-20 mg, and this treatment was continued for the subsequent 5 weeks. Fetal heart rate, movement, and treatment toxicity were monitored daily, while fetal well-being was assessed on a weekly basis. Prenatal resolution was achieved 6 weeks after the treatment initiation. Digoxin levels reached a therapeutic concentration (1.75 ng/mL) without any signs of intoxication. A cesarean section was performed at 38/39 weeks of gestational age. The postnatal evaluation did not reveal any recurrence of tachyarrhythmia or neurodevelopmental disorders. Evaluation of atrioventricular contractions using M-mode echocardiography proved to be a straightforward method. In this case of sustained supraventricular tachycardia, the absence of fetal hydrops was likely attributed to ventricular contractions remaining below 230 beats per minute. The use of combination therapy demonstrated superiority over monotherapy in achieving prenatal resolution. Transplacental anti-arrhythmic combination therapy can be considered for cases of refractory tachyarrhythmia. Further large-scale population studies are necessary to determine appropriate therapeutic doses and adjust available drug options to achieve faster prenatal resolution of fetal tachyarrhythmias.

* Corresponding author: Manggala Pasca Wardhana

✉ E-mail: manggala.pasca@fk.unair.ac.id

© 2023 by SPC (Sami Publishing Company)

GRAPHICAL ABSTRACT



Introduction

The conduction system in the heart begins to develop around 5 weeks of gestation, characterized by the emergence of cardiac pacemaker activity through the sinus node [1]. As heart chambers develop, other components of the conduction system, such as the AV node, bundle of His, right and left branch bundles, and Purkinje fibers, are fully formed by 16 weeks of gestation [2].

Fetal arrhythmia is a rare disorder with an approximate prevalence of 2% [1]. Regular heart rate assessments are the primary means of screening for arrhythmias, and fetal arrhythmias often prompt referrals for fetal cardiac evaluation. Fetal arrhythmias are classified into tachyarrhythmias and bradyarrhythmias, with tachyarrhythmias being more prevalent at 41.4% compared to bradyarrhythmias at 17.2% [3]. In the general population, fetal tachyarrhythmias complicate approximately 0.4-0.6% of pregnancies [4], with a tachyarrhythmic mortality rate of 8-9% [5].

Brief episodes of fetal tachyarrhythmias typically do not cause clinical problems, but sustained tachyarrhythmias can lead to heart failure, fetal hydrops, and even death [6]. Unfortunately, misdiagnoses of tachyarrhythmias can occur, leading to the decisions to terminate pregnancies without proper treatment, resulting in preterm labor and fetal complications. Short-term complications include hemodynamic

disturbances in 43% of cases and an 81% increased recurrence rate in neonates [7], while long-term effects may lead to neurological developmental disorders [8].

The tachyarrhythmias incidence in Indonesia is currently unknown due to its rarity. Understanding the pathophysiology of fetal tachyarrhythmias is crucial for enhancing the success rate of therapeutic interventions [9]. In this case report, we present our first experience in managing fetal tachyarrhythmia in a multidisciplinary tertiary hospital, which resulted in successful prolonged prenatal resolution.

Case

A 36-year-old female patient presented to the obstetric outpatient clinic at Dr. Soetomo Academic General Hospital on May 25th, 2021. The patient sought a second medical opinion after undergoing treatment at a previous hospital, where it was observed that the fetal heartbeat was excessively fast. At the previous hospital, the patient received lung maturation injections as part of a two-day treatment. Following the completion of fetal lung maturation, the patient was offered the choice of either terminating or continuing the pregnancy due to the persistently elevated fetal heart rate. Opting to proceed with the pregnancy, the patient was advised to seek further care at Dr. Soetomo Academic Hospital.

Throughout the course of this pregnancy, there had been no prior instances of a rapid fetal heart rate, and the patient had no history of autoimmune disease, infections (Table 1), or use of medications other than pregnancy vitamins. During the general physical examination, the patient's weight was recorded as 65 kilograms, height as 146 centimeters, and body mass index (BMI) as 30.49. Vital signs were as follows: blood pressure 105/67 mmHg, pulse rate 89 beats per minute, respiratory rate 20 breaths per minute, and body temperature 36.5 °C. No clinical signs of

hyperthyroidism were observed. Anatomy screening ultrasound results conducted at Dr. Soetomo Academic Hospital on May 27th, 2021, showed appropriate fetal growth for gestational age without any structural abnormalities in the heart, hydrops fetalis, or fetal anemia (Figure 1). A diagnosis of fetal tachyarrhythmia was made, and the patient was informed about the need for hospitalization with a plan for transplacental fetal digoxin treatment, to which the patient consented.

Table 1: Laboratory results (May, 25th 2021)

Hb	10.1 g/dl
WBC	14,080
Plt	400,000 10 ³ /μL
Hct	30.6 %
Random Blood Sugar	78 mg/dL
Na/K/Cl	140/3.8/106 mmol/L
TSH	2,734 (0.55-4.78 mIU/L)
FT4	0.90 (0.89-1.76 ng/dL)
ANA Test	7.832 (≤ 40)
Anti dsDNA	<10.0 (<100 IU/mL)
Blood group	B, rhesus (+)
HbSag/HIV/Sifilis	Nonreactive

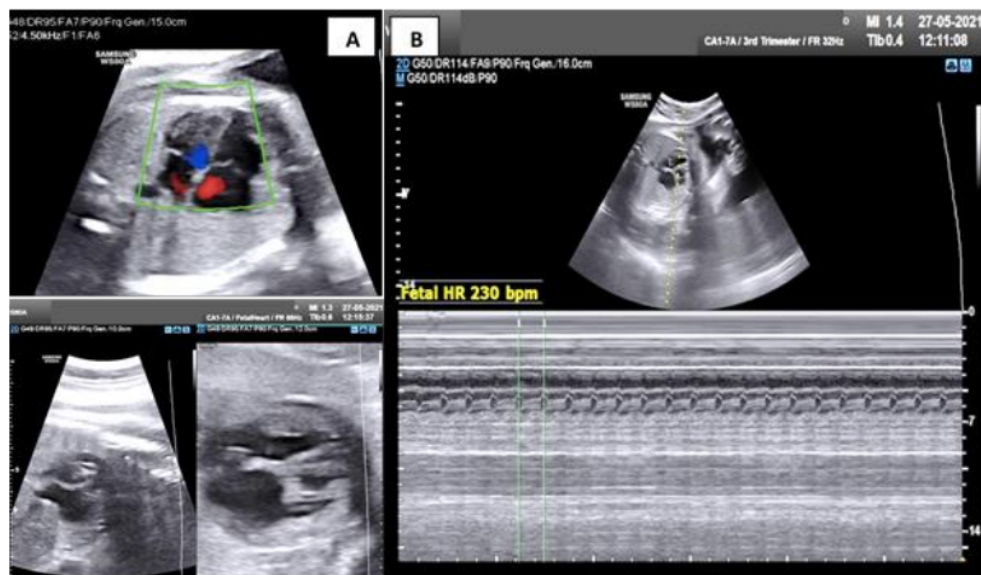


Figure 1: M-mode echocardiography results at Dr. Soetomo Academic Hospital (Date: May 27th, 2021). (A) The structure of the heart was normal and (B) fetal heart rate of 230 bpm

The selection and monitoring of transplacental digitization were conducted in collaboration with a cardiologist for seven days (Table 2). The therapy commenced with digoxin monotherapy for two days, followed by combination therapy of digoxin and propranolol for five days. Total digoxin monotherapy was performed for seven days without tachyarrhythmias resolution. Throughout the treatment, there were no sign of digoxin or propranolol intoxication. Subsequently, the patient received outpatient care with continued oral administration of digoxin (0.25 mg/12 hours) and propranolol (40 mg, 20 mg, and 20 mg). On June 16, 2021, an M-mode fetal echocardiogram evaluation revealed a sustained supraventricular tachyarrhythmia (Figure 2). The mother's ECG results

demonstrated sinus rhythm with ST depression (Salvador Dali) without clinical signs of digitalis intoxication.

Due to unresolved fetal tachyarrhythmias, a multidisciplinary discussion was held with cardiology and pediatric cardiologist on June 24, 2021, to evaluate serum digoxin level. If digoxin level found low, it could be increased until it reached the optimal level. The first line of transplacental digitalization therapy used was digoxin, followed by a combination with propranolol, and as a final option, amiodarone. If no resolution was achieved, termination of pregnancy would be performed, followed by postnatal therapy with amiodarone at a loading dose of 1 mg/kg BW for 10-15 minutes, with close observation.

Table 2: Observation and therapy at Dr. Soetomo Academic Hospital (May 29th-June 3rd, 2021)

Date	Fetal Heart Rate	Therapy
May 29, 2021	220	Digoxin injection of 0.5 mg intravenously, followed by that of 0.25 mg/8 hours intravenously.
May 30, 2021	220	Digoxin injection of 0.25 mg/h hours intravenously.
May 31, 2021	220	- Digoxin injection of 0.25 mg/12 hours intravenously (maintenance dose), tapering off. - Evaluation of clinical signs of digitalis intoxication (nausea, vomiting, dizziness, and blurred vision) and ECG.
June 1, 2021	220	Digoxin injection of 0.25 mg/24 hours intravenously
June 2, 2021	232	Tablet digoxin administration of 0.25 mg/24 hours per oral. Tablet Propanolol administration of 20 mg/8 hours per oral.
June 3, 2021	216	- Digoxin administration of 0.5 mg/12 hours per oral. - Propanolol administration of 40 mg, 20 mg, 20 mg per oral.

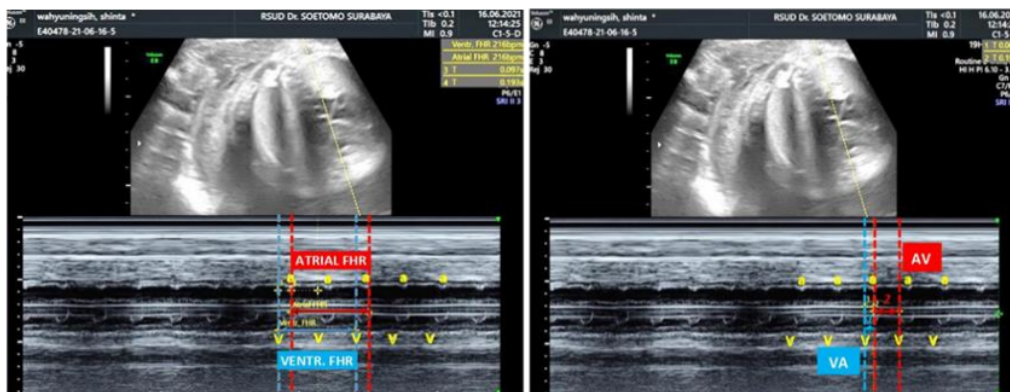


Figure 2: Results of the M-mode echocardiogram (Date: June 16, 2021). It showed each atrial and ventricular heart rates of 216 bpm during all examinations and regular. The relationship of atrial and ventricular contractions was 1:1, with a short VA interval (VA:AV ratio <1) indicating a sustained supraventricular tachyarrhythmia. There was no fetal hydrops or polyhydramnios

In case of hemodynamic disturbances, cardioversion would be carried out.

On July 1st, 2021, during a pregnancy check-up at the Pregnant Polyclinic at Dr. Soetomo Academic Hospital, the patient had no complaints and was educated about the option of hospitalization for digitization. However, the patient refused and chose to continue taking digoxin 0.25 mg/12 hours and propranolol 40 mg, 20 mg, and 20 mg orally. The planned termination of pregnancy by cesarean section was scheduled for 38/39 weeks of gestation (July 20th, 2021). On July 14th, 2021, during a follow-up pregnancy check-up, resolution of the fetal heart rate was observed (Figure 3). Combination therapy was continued until the termination of pregnancy.

Digoxin levels were examined in the prenatal patient at 1.75 ng/mL (therapeutic range: 0.8-2.0 ng/mL). On July 21st, 2021, the baby was born via cesarean section, female, weighing 2,900 grams with an Apgar score of 7-8. No abnormalities were found in the fetus. The baby's ECG results showed normal sinus rhythm (pulse 130-140 beats/minute), with no supraventricular tachycardia (SVT) or Wolff-Parkinson-White (WPW) syndrome detected. The patient was educated that in postnatal cardiac evaluation, no anatomic abnormalities or heart rhythms were found, so there is no need for further evaluation or follow-up. The child's growth and development were assessed on March 13th, 2023, revealing normal weight and good nutrition. The child's development was evaluated using the

Prescreening Developmental Questionnaire (PDQ) at the age of 18 months, and the results indicated normal development according to the appropriate stage [10].

Results and Discussion

The fetal heart rate is regulated by the cardiac conduction system at 16 weeks' gestation [11]. The normal fetal heart rate ranges from 110 to 160 beats per minute. Heart rate abnormalities occur when the heart rate falls outside this range, or an irregular rhythm is detected. These abnormalities are referred to as fetal arrhythmias. The rate, duration, and origin of the heartbeat, as well as the degree of irregularity, can impact the hemodynamics of the fetus. Approximately 10% of pregnancies are associated with heart rhythm abnormalities with the potential to cause complications for the fetus [12].

Fetal arrhythmias are categorized into two groups: bradyarrhythmias and tachyarrhythmias. Fetal bradyarrhythmia is diagnosed when the fetal heart rate is below 110 beats per minute, while fetal tachyarrhythmia is defined as a fetal heart rate above 180 beats per minute [13]. Fetal tachyarrhythmias are estimated to complicate 0.4 to 0.6% of all pregnancies [4]. Tachyarrhythmias are potentially more life-threatening than bradyarrhythmias, with a mortality rate of 8 to 9%, and they can progress to ventricular dysfunction or fetal heart failure, ultimately leading to intrauterine fetal death.

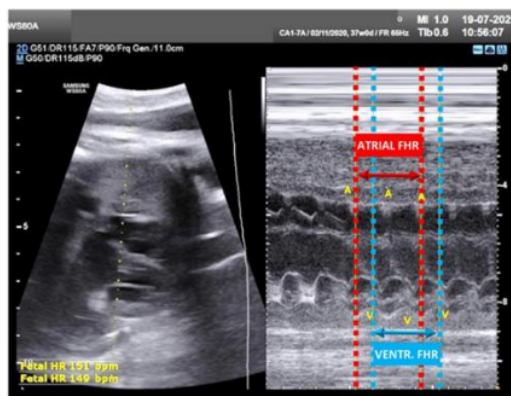


Figure 3: Results of the M-mode echocardiogram (Date: July 19th, 2021). It showed the resolution of tachyarrhythmias, a regular atrial heart rate of 151 bpm, and a ventricular heart rate of 149 bpm

Fetal tachyarrhythmia is often the primary finding. Around 5 to 10% of cases are associated with congenital cardiac abnormalities, including Ebstein anomaly, atrioventricular canal defects, hypoplastic left heart syndrome, and intracardiac tumors [14]. Continuous fetal tachyarrhythmias can lead to congestive heart failure, resulting in increased right atrial and systemic pressure, non-immune hydrops, placental edema, and polyhydramnios [13].

The history of the patient focuses on identifying the cause of fetal tachyarrhythmia. Determining the cause is essential to exclude external factors. If external factors are identified, therapy is provided accordingly. In this case, based on the anamnesis, there were no complaints or a history of diseases associated with increased catecholamine levels. The patient also denied using beta-adrenergic drugs, parasympatholytic drugs, antihistamines with cholinergic effects, or opioids during pregnancy. Blood group and infection tests during pregnancy have been conducted and ruled out as secondary causes of fetal tachyarrhythmias.

In this case, there were no anemia, fever, pain, or clinical signs of thyrotoxicosis as a secondary cause of fetal tachyarrhythmia [15]. On vaginal examination, there were no signs of chorioamnionitis. The fetal tachyarrhythmia was first discovered during the evaluation of the fetal heart rate at 30 weeks of gestation. Any abnormal fetal heart rate finding then followed by a basic ultrasound evaluation. The primary goal of pregnancy ultrasound is to confirm the presence of fetal tachyarrhythmias, evaluate cardiac structure and function, assess fetal well-being through biophysical profile assessment, and observe for signs of fetal hydrops. Generally, fetal tachyarrhythmias are an isolated finding, but in 5-10% of cases, they are accompanied by structural and functional cardiac abnormalities [14]. Associated congenital heart abnormalities include Ebstein anomaly, hypoplastic left heart syndrome, intracardiac tumors, and atrioventricular canal defects, which can lead to atrial enlargement.

The ultrasound examination was followed by echocardiography. Heart wall and valves motion, veins, and arteries, assessed by M-mode, pulsed-

wave Doppler, and/or color Doppler M-mode which then establish the type of fetal tachyarrhythmia. During the M-mode echocardiogram, the cursor was positioned on the atria and ventricles to evaluate the relationship between atrial and ventricular contractions, which helps in diagnosing the type of tachyarrhythmia [13]. Supraventricular tachycardia has the 1:1 atrioventricular relationship with rate 190-280 beat per minute. It is often found with rate 200-220 beat per minute. Sinus tachycardia is commonly considered as a differential diagnosis; however, the difference is the presence of short VA in SVT [13].

In this case, the examination of the 4-chamber views and outflow tract of the heart revealed no structural or functional abnormalities. The M-mode echocardiographic evaluation showed a 1:1 atrial-ventricular relationship with a ventricular rate of less than one for more than 50% of the time, indicating sustained supraventricular tachycardia. Short VA intervals are characteristic of supraventricular tachycardia, which accounts for 70-75% of fetal tachyarrhythmias [13]. Supraventricular tachycardia involves conduction through accessory pathways with orthodromic or antidromic conduction currents. Accessory bundles form due to interference with regulators like Bone Morphogenetic Protein (BMP), leading to the failure of fibrous tissue formation and myocyte differentiation into working myocardium with fast electrical transmission characteristics [16]. This insulation disorder causes direct contact between the atrial and ventricular myocardium, altering cardiac conduction physiology through accessory scars instead of the atrioventricular node [17].

During the observation, no fetal hydrops was detected as the ventricular rate ranged from 220-230 beats per minute. The risk of hydrops appears when ventricular contractions exceed 230 beats per minute for more than 12 hours, indicating the onset of ventricular dysfunction. No secondary causes were found, suggesting that the tachyarrhythmias were likely due to primary conduction abnormalities of the fetal heart.

A transplacental therapy was administered for six weeks with a multidisciplinary team comprising

obstetricians, cardiologists, and pediatric cardiologists. A pre-therapy evaluation was conducted by a cardiologist. In the first week of treatment, therapy was given in the hospital, and fetal movement and heart rate were monitored daily, with an evaluation of therapy toxicity signs every day and an assessment of fetal well-being once a week. After 1 week of therapy, a decrease in fetal heart rate was observed, reduced to 210 beats per minute. As no further progress was noted, the patient opted to continue with outpatient transplacental therapy. The patient was educated about evaluating fetal movement and recognizing danger signs, such as decreased fetal movement, labor, rupture of membranes, and signs of intoxication from transplacental therapy. Fetal well-being was evaluated every 2 weeks. A resolution was achieved six weeks after the initiation of transplacental therapy at 37/38 weeks.

6
Currently, there is no consensus regarding the treatment of fetal tachyarrhythmias, and the choice of therapy is made on a case-by-case basis [13, 18]. The AHA recommends prenatal antiarrhythmic therapy [19]. For supraventricular tachycardia less than 200 beat per minute, without hydrops or ventricular dysfunction, it is recommended to do observation. For supraventricular tachycardia more than 200 bpm without hydrops or ventricular dysfunction, the first- and the second-line therapy is digoxin, flecainide and sotalol while the third-line therapy is amiodarone. Antiarrhythmic therapy can be administered transplacentally, orally, or intravenously to the mother or injected into the fetus through the umbilical vein, intramuscular, peritoneal, amnion, or directly into the heart [1]. The most common method of direct therapy to the fetus is umbilical vein injection because it allows the drug to directly enter the fetal blood circulation, facilitating concentration evaluation to monitor therapy. In general, direct therapy to the fetus is administered in cases of hydrops if repeated transplacental administration is not successful. Digoxin is a cardiac glycoside commonly used as first-line therapy for fetal tachyarrhythmias, especially non-hydrops supraventricular tachycardia (SVT) [13, 19]. The half-life of digoxin

is 40 hours, and it is excreted by the kidneys, so dose adjustment is necessary if there are kidney abnormalities [20, 21]. Some literature recommends administering a loading dose of 1 mg intravenously within 24 hours, followed by two additional doses of 0.25 mg orally in cases of fetal hydrops [18]. For non-hydrops fetuses, the loading dose is typically given orally for 6-7 days [22]. The target blood concentration is 1-2 µg/L, which is checked 6-8 hours after drug consumption. Serum digoxin levels above 2 µg/L carry a higher risk of toxicity [23].

The selection of digoxin as the first-line therapy, in this case, is consistent with many studies that recommend it as the primary treatment for non-hydrops SVT [13, 19]. The relatively safe characteristics of the drug during pregnancy, relatively fast response, and widespread use underlie this choice [24]. However, the initial and maintenance doses may vary from one center to another. In this case, digoxin was administered as monotherapy with an initial dose followed by maintenance doses for 3 days with gradual dose reduction. The dosing approach is similar to the findings in Miyoshi's research (2019), but the maintenance dose was not tapered off [6]. The dose was maintained for 3 days after reaching maternal serum levels of 1.5-2 ng/ml. This non-randomized multisite trial showed a success rate of 54.8% with the use of this digoxin dose as monotherapy. Several other studies reported digoxin monotherapy success rates ranging from 30% to 70% [25-28].

In this case, there have been several cohort studies comparing the effectiveness of digoxin, flecainide, and sotalol in resolving fetal tachyarrhythmias. However, due to the rarity of these cases, the sample sizes in each study were small, and some studies showed conflicting results. Nonetheless, when it comes to cases with hydrops, many pieces of literature consistently demonstrate the reduced effectiveness of transplacental digoxin monotherapy in fetuses with hydrops, with a decrease in the effectiveness of up to 10-15% [29, 30].

Before administering transplacental therapy in this case, maternal ECG and serum electrolytes were performed, and the results were normal.

Throughout the transplacental therapy, daily evaluations of signs of clinical toxicity of digoxin therapy and ECG were conducted, with no indications of toxicity. Maternal serum digoxin levels after six weeks of digoxin therapy reached therapeutic levels of 1.75 ng/mL. This is in line with the literature, where signs or symptoms of side effects typically do not appear when digoxin levels remain below therapeutic levels, which are generally considered to be 2 ng/mL [31]. Furthermore, no side effects of propranolol were observed in the infant, which is supported by the normal weight output of the baby.

The prognosis in cases of fetal tachyarrhythmias depends on various factors, including the resolution of the arrhythmia during prenatal care, the presence or absence of hydrops, and the specific type of tachyarrhythmia. Generally, long-term fetal outcomes are positive when the prenatal conversion of the arrhythmia is achieved, and hydrops is prevented [32]. However, it is important to note that the success of conversion and prevention of hydrops does not solely rely on the drug's transplacental transfer ability. There are rare subtypes of tachyarrhythmias, such as Permanent Junctional Reciprocating Tachycardia (PJRT) and Atrial Ectopic Tachycardia (AET), which are resistant to antiarrhythmic drugs [7]. Cases of arrhythmic Rheumatic Heart Disease (RHD) are also challenging to treat with antiarrhythmic drugs postnatally, and approximately 50% of infants with RHD may require intervention due to the associated arrhythmic cardiomyopathy [33]. AET Recurrence rarely appears after the age of 18 months [34].

In this specific case, the prognosis is favorable as the patient experienced resolution of prenatal tachyarrhythmias with transplacental therapy, and no hydrops was detected. The pregnancy was terminated at term through a cesarean section for obstetric indications, considering the patient's history of previous cesarean section. Some literature allows for a vaginal delivery if fetal well-being can be adequately monitored [35]. Close monitoring of fetal hypoxia can be achieved either invasively with repeated fetal scalp blood sampling or non-invasively with fetal arterial oxygen saturation sensors during labor [36]. In

cases of non-hydrops and tachyarrhythmic SVT fetuses, the risk of intrapartum hypoxemia is generally not increased, making vaginal delivery a feasible option. However, cesarean section is recommended for cases of sustained tachyarrhythmias and/or if there is no resolution with transplacental therapy [37]. At the postpartum evaluation up to 1 week later, there was no recurrence of tachyarrhythmias, and the risk of developmental disorders is minimal, as indicated by the current condition of normal child growth and development according to the age.

Conclusion

Understanding the pathophysiology of the cardiac conduction system is crucial in determining the therapeutic response and prognosis of fetal tachyarrhythmias. Cases of fetal tachyarrhythmias require early identification and treatment at specialized tertiary hospitals with the collaboration of a multidisciplinary team. Transplacental therapy is recommended for tachyarrhythmias in fetuses under 37 weeks' gestation or term with hydrops. However, there is currently no consensus on the choice of antiarrhythmic drugs, and the selection of therapy depends on the availability of the drug in the center and the clinician's familiarity with it. In this case report, it is proven combination transplacental therapy has shown beneficial towards sustained fetal tachyarrhythmia. Therapeutic evaluation with prenatal resolution goal, fetal complication, clinical, electrocardiography, and laboratory monitoring is essential. Successful treatment that achieve prenatal resolution leads to favorable short- and long-term outcomes for the infant.

Conflict of Interest

No potential conflict of interest was reported by the authors.

Funding

This research did not receive any specific grant from funding agencies in the public, commercial, or not-for-profit sectors.

Authors' Contributions

All authors contributed to data analysis, drafting, and revising of the article and agreed to be responsible for all the aspects of this work.

ORCID

Sarah Fitria Andini

<https://orcid.org/0009-0007-1728-0968>

Mangala Pasca Wardhana

<https://orcid.org/0000-0001-8013-4639>

Agus Sulistyono

<https://orcid.org/0000-0001-8894-5591>

I Ketut Alit Utamayasa

<https://orcid.org/0000-0001-8972-0044>

Alisia Yuana Putri

<https://orcid.org/0009-0007-0975-2611>

References

- [1]. Bravo-Valenzuela N.J., Rocha L.A., Nardoza M.L.M., Junior E.A., Fetal cardiac arrhythmias: current evidence, *Annals of Pediatric Cardiology*, 2018, **11**:148 [Crossref], [Google Scholar], [Publisher]
- [2]. Anis A., Marcionara N.I.C., Improvement of Severe Maternal Covid-19 Outcome with the Use of EMCO (Extracorporeal Membrane Oxygenation) at Dr. Soetomo General Hospital Surabaya: Serial Case Study, *Journal of Medicinal and Chemical Sciences*, 2023, **6**:3072 [Crossref], [Publisher]
- [3]. Tytarenko N., Kukuruzza I., Zasadniuk O., Kostyuchenko A., Vozniuk A., Tactics of Treatment of Catastrophic Anti-Phospholipid Syndrome in Pregnant Woman: Based on a Clinical Case. *Journal of Medicinal and Chemical Sciences*, 2023, **6**:2569 [Crossref], [Google Scholar], [Publisher]
- [4]. Hasanah M., Hernaningsih Y., Hemolytic Anemia in Pregnancy: A Rare and Challenging Case in Indonesia, *Journal of Medicinal and Chemical Sciences*, 2023, **6**:2679 [Crossref], [Google Scholar], [Publisher]
- [5]. Abdulameer S.J., Effect of Different Plasma Concentrations Human Plasma and Goat Plasma on Human Blood Cell Growth In Vitro, *Journal of Medicinal and Chemical Sciences*, 2023, **6**:1872 [Crossref], [Google Scholar], [Publisher]
- [6]. Baker L.A.A., Aldin S.Z.J., Ahmed A.S., Role of Oxidative Stress in Molar Pregnancy, *Journal of Medicinal and Chemical Sciences*, 2023, **6**:1383 [Crossref], [Google Scholar], [Publisher]
- [7]. Van Weerd J.H., Christoffels V.M., The formation and function of the cardiac conduction system, *Development*, 2016, **143**:197 [Crossref], [Google Scholar], [Publisher]
- [8]. Gozar L., Marginean C., Toganel R., Muntean I., The role of echocardiography in fetal tachyarrhythmia diagnosis. A burden for the pediatric cardiologist and a review of the literature, *Medical Ultrasonography*, 2017, **19**:232 [Crossref], [Google Scholar], [Publisher]
- [9]. Southall D.P. Richards J., Hardwick R.A., Shinebourne E.A., Gibbens G.L., Thelwall-Jones H., De Swiet M., Johnston P.G., Prospective study of fetal heart rate and rhythm patterns, *Archives of Disease in Childhood*, 1980, **55**:506 [Crossref], [Google Scholar], [Publisher]
- [10]. Qin J., Deng Z., Tang C., Zhang Y., Hu R., Li J., Hua Y., Li Y., Efficacy and safety of various first-line therapeutic strategies for fetal tachycardias: a network meta-analysis and systematic review, *Frontiers in Pharmacology*, 2022, **13**:935455 [Crossref], [Google Scholar], [Publisher]
- [11]. Miyoshi T., Maeno Y., Hamasaki T., Inamura N., Yasukochi S., Kawataki M., Horigome H., Yoda H., Taketazu M., Nii M., Hagiwara A., Kato H., Shimizu, W., Shiraishi, I, Sakaguchi, H., Ueda, K., Katsuragi S., Yamamoto H., Sho H., Ikeda T., Antenatal therapy for fetal supraventricular tachyarrhythmias, *Journal of the American College of Cardiology*, 2019, **74**:874 [Crossref], [Google Scholar], [Publisher]
- [12]. Bartin R., Maltret A., Nicloux M., Ville Y., Bonnet D., Stirnemann J., Outcomes of sustained fetal tachyarrhythmias after transplacental treatment, *Heart Rhythm O2*, 2021, **2**:160 [Crossref], [Google Scholar], [Publisher]
- [13]. Krapp M., Baumann K., Axt-Fliedner R., Gembruch U., OP02. 07: Long term outcome of fetal tachyarrhythmia, *Ultrasound in Obstetrics & Gynecology*, 2007, **30**:462 [Crossref], [Google Scholar], [Publisher]
- [14]. Prasetyo B., Damayanti H., Pranadyan R., Pandu Hanindito Habibie N., Romdhoni A.C., Islami D., Maternal mortality audit based on district maternal health performance in East Java

- Province, Indonesia, *Bali Medical Journal*, 2018, **7**:61 [[Google Scholar](#)], [[Publisher](#)]
- [15]. Widiyanti N., Suryawan A., Irmawati M., Validity test of pre-screening developmental questionnaire (PDQ) and mother and child health (MCH) handbook for determining children's readiness to enter elementary school, *Bali Medical Journal*, 2023, **12**:211 [[Crossref](#)], [[Publisher](#)]
- [16]. Macones G.A., Hankins G., Spong C., Hauth J., Moore T., The 2008 National Institute of Child Health and Human Development workshop report on electronic fetal monitoring: update on definitions, interpretation, and research guidelines, *Obstetrics and gynecology*, 2008, **112**:661 [[Crossref](#)], [[Google Scholar](#)], [[Publisher](#)]
- [17]. Wacker-Gussmann A., Strasburger J.F.M., Cuneo B.F., Wakai R.T., Diagnosis and treatment of fetal arrhythmia, *American Journal of Perinatology*, 2014, **31**:617 [[Crossref](#)], [[Google Scholar](#)], [[Publisher](#)]
- [18]. Gembruch U., Embryology, genetics, physiology, echocardiographic evaluation, diagnosis, and perinatal management of cardiac diseases', in *Fetal Cardiology*. 3rd edn, 2019, 530 [[Google Scholar](#)], [[Publisher](#)]
- [19]. Singh G.K., Management of fetal tachyarrhythmias, *Current Treatment Options in Cardiovascular Medicine*, 2004, **6**:399 [[Crossref](#)], [[Google Scholar](#)], [[Publisher](#)]
- [20]. Berghella V., *Maternal-Fetal Evidence Based Guidelines*, Boca Raton: CRC Press, 2022 [[Crossref](#)], [[Google Scholar](#)], [[Publisher](#)]
- [21]. Gaussin V., Morley G.E., Cox L., Zwijsen A., Vance K.M., Emile L., Tian Y., Liu J., Hong, Conway S.J., Depre C., Myers D., Conway S.J., Depre C., Mishina Y., Behringer R.R., Hanks M.C., Schneider M.D., Huylebroeck D., Fishman G.I., Burch J.B.E., Vatner S.F., Alk3/Bmpr1a receptor is required for development of the atrioventricular canal into valves and annulus fibrosus, *Circulation Research*, 2005, **97**:219 [[Crossref](#)], [[Google Scholar](#)], [[Publisher](#)]
- [22]. Hahurij N.D., Kolditz D.P., Bökenkamp R., Markwald R.R., Schali J.M., Poelmann R.E., Groot A.C.G., Blom N.A., Accessory atrioventricular myocardial pathways in mouse heart development: substrate for supraventricular tachycardias, *Pediatric Research*, 2011, **70**:37 [[Crossref](#)], [[Google Scholar](#)], [[Publisher](#)]
- [23]. Kleinman C.S., Nehgme R.A., Cardiac Arrhythmias in the Human Fetus, *Pediatric Cardiology*, 2004, **25**:234 [[Crossref](#)], [[Google Scholar](#)], [[Publisher](#)]
- [24]. Donofrio M.T., Moon-Grady A.J., Hornberger L.K., Copel J.A., Sklansky M.S., Abuhamad A., Cuneo B.F., Huhta J.C., Jonas R.A., Krishnan A., Lacey S., Lee W., Michelfelder E.C., Rempel G.R., Silverman N.H., Spray T.L., Strasburger J.F., Tworetzky W., Rychik J., Diagnosis and treatment of fetal cardiac disease : a scientific statement from the american heart association, *Circulation*, 2014, **129**:2183 [[Crossref](#)], [[Google Scholar](#)], [[Publisher](#)]
- [25]. Mitani G.M., Steinberg I, Lien E.J., Harrison E.C., Elkayam U., The pharmacokinetics of antiarrhythmic agents in pregnancy and lactation, *Clinical Pharmacokinetics*, 1987, **12**:253 [[Crossref](#)], [[Google Scholar](#)], [[Publisher](#)]
- [26]. Indarini P.F., Truncus Arteriosus Type I: A Case Report, *Indonesia Journal of Biomedical Science*, 2016, **10**:5 [[Google Scholar](#)], [[Publisher](#)]
- [27]. Simpson J., *Fetal arrhythmia, Textbook of Fetal Cardiology*. London: Greenwich Medical Media, 2000 [[Publisher](#)]
- [28]. Malhamé I., Ghandi C., Tarabulsi G., Esposito M., Lombardi K., Chuu A., Chen K.K., Maternal monitoring and safety considerations during antiarrhythmic treatment for fetal supraventricular tachycardia, *Obstetric Medicine*, 2019, **12**:66 [[Crossref](#)], [[Google Scholar](#)], [[Publisher](#)]
- [29]. Alsaied T., Baskar S., Fares M., Alahdab F., Czosek R.J., Murad M.H., Prokop L.J., Divanovic A.A., First-line antiarrhythmic transplacental treatment for fetal tachyarrhythmia: a systematic review and meta-analysis, *Journal of the American Heart Association*, 2017, **6**:e007164 [[Crossref](#)], [[Google Scholar](#)], [[Publisher](#)]
- [30]. Simpson J.M., Sharland G.K., Fetal tachycardias: management and outcome of 127 consecutive cases, *Heart*, 1998, **79**:576 [[Crossref](#)], [[Google Scholar](#)], [[Publisher](#)]
- [31]. Jaeggi E.T., Carvalho J.S., Groot E.D., Api O., Clur A.B., Rammeloo L., McCrindle B.W., Ryan G., Manlhiot C., Blom N.A., Comparison of transplacental treatment of fetal supraventricular

- tachyarrhythmias with digoxin, flecainide, and sotalol, *Circulation*, 2011, **124**:1747 [[Crossref](#)], [[Google Scholar](#)], [[Publisher](#)]
- [32]. Sridharan S., Sullivan I., Tomek V., Janousek J., Dominguez T.E., Marek J., Flecainide versus digoxin for fetal supraventricular tachycardia: Comparison of two drug treatment protocols, *Heart Rhythm*, 2016, **13**:1913 [[Crossref](#)], [[Google Scholar](#)], [[Publisher](#)]
- [33]. Broom E., Thomas J.T., Petersen S., Gooi A., Ward C., Gardener G., Kostner K., Lee-Tannock A., Kumar S., Management of fetal supraventricular tachycardia: case series from a tertiary perinatal cardiac center, *Fetal Diagnosis and Therapy*, 2021, **48**:794 [[Crossref](#)], [[Google Scholar](#)], [[Publisher](#)]
- [34]. Krapp M., Baschat A.A., Gembruch U., Geipel A., Germer U., Flecainide in the intrauterine treatment of fetal supraventricular tachycardia, *Ultrasound in Obstetrics & Gynecology*, 2002, **19**:158 [[Crossref](#)], [[Google Scholar](#)], [[Publisher](#)]
- [35]. Krapp M., Review of diagnosis, treatment, and outcome of fetal atrial flutter compared with supraventricular tachycardia, *Heart*, 2003, **89**:913 [[Crossref](#)], [[Google Scholar](#)], [[Publisher](#)]
- [36]. Kurosawa K., Noguchi S., Nishimura T., Tomi M., Chiba K., Transplacental pharmacokinetic model of digoxin based on ex vivo human placental perfusion study, *Drug Metabolism and Disposition*, 2022, **50**:287 [[Crossref](#)], [[Google Scholar](#)], [[Publisher](#)]
- [37]. Oudijk M.A., Ruskamps, J.M., Ververs F.F.T., Ambachtsheer, E.B., Stoutenbeek, P., Visser G.H.A., & Meijboom E.J., Sotalol in the treatment of fetal dysrhythmias, *Circulation*, 2000, **101**:2721 [[Crossref](#)], [[Google Scholar](#)], [[Publisher](#)]
- [38]. Gaita F., Antonio M., Riccardi R., Giustetto C., Grossi S., Caruzzo E., Bianchi F., Vivalda L., Gabbarini F., Calabro R., Cryoenergy catheter ablation: a new technique for treatment of permanent junctional reciprocating tachycardia in children, *Journal of Cardiovascular Electrophysiology*, 2004, **15**:263 [[Crossref](#)], [[Google Scholar](#)], [[Publisher](#)]
- [39]. Salerno J.C., Kertesz N.J., Friedman R.A., Fenrich A.L., Clinical course of atrial ectopic tachycardia is age-dependent: results and treatment in children < 3 or > =3 years of age, *Journal of the American College of Cardiology*, 2004, **43**:438 [[Crossref](#)], [[Google Scholar](#)], [[Publisher](#)]
- [40]. Darmaputra, I.G.N., Herwanto N., Rusyati L.M., Riawan W., Endaryanto A., Prakoeswa C.R.S., Distribution of iNOS expressions and TNF neutrofil cells as well as PGE2 and S100 Schwann cell dermal nerves in the erythema nodosum leprosum patients, *Bali Medical Journal*, 2018, **7**:262 [[Crossref](#)], [[Google Scholar](#)], [[Publisher](#)]
- [41]. Levine J.C., Alexander M.E., Fetal arrhythmias. Edited by T.W. Post. UpToDate, Waltham, MA, 2022 [[Publisher](#)]
- [42]. Amano K., Hirano S., Maeda M., Nishijima M., Should C-section be applied to fetal arrhythmia? *European Journal of Obstetrics & Gynecology and Reproductive Biology*, 1997, **72**:S73 [[Crossref](#)], [[Google Scholar](#)], [[Publisher](#)]
- [43]. Husain A., Hubail Z., Al Banna R., Fetal supraventricular tachycardia, treating the baby by targeting the mother, *Case Reports*, 2013, **2013**:bcr2012008515 [[Crossref](#)], [[Google Scholar](#)], [[Publisher](#)]

HOW TO CITE THIS ARTICLE

Sarah Fitria Andini, Manggala Pasca Wardhana, Agus Sulistyono, I Ketut Alit Utamayasa, Alisia Yuana Putri. Prolonged Resolution of Intrauterine Fetal Tachyarrhythmia Treatment. *J. Med. Chem. Sci.*, 2023, 6(12) 3167-3177.

DOI: <https://doi.org/10.26655/JMCHMSCI.2023.12.30>

URL: https://www.jmchemsci.com/article_177815.html

Prolonged Resolution

ORIGINALITY REPORT

14%

SIMILARITY INDEX

8%

INTERNET SOURCES

12%

PUBLICATIONS

%

STUDENT PAPERS

PRIMARY SOURCES

1	www.chemmethod.com Internet Source	1%
2	e-journal.unair.ac.id Internet Source	1%
3	kupdf.net Internet Source	1%
4	Prastiya Indra Gunawan, Nur Rochmah, Muhammad Faizi. "Comparison of 25-hydroxy vitamin D serum levels among children with epilepsy in therapy with single versus multiple antiseizure medications", <i>Epilepsy & Behavior Reports</i> , 2023 Publication	1%
5	<i>Pediatric and Congenital Cardiology Cardiac Surgery and Intensive Care</i> , 2014. Publication	1%
6	www.mdpi.com Internet Source	1%
7	www.ncbi.nlm.nih.gov Internet Source	1%

8	synapse.koreamed.org Internet Source	1 %
9	d2jw81rkebrcvk.cloudfront.net Internet Source	<1 %
10	dokumen.pub Internet Source	<1 %
11	Mary T. Donofrio, Anita J. Moon-Grady, Lisa K. Hornberger, Joshua A. Copel et al. "Diagnosis and Treatment of Fetal Cardiac Disease", <i>Circulation</i> , 2014 Publication	<1 %
12	A. Galindo, A. Mendoza. "Current Concepts on Prenatal Diagnosis and Management of Fetal Tachyarrhythmias", <i>Current Cardiology Reviews</i> , 2007 Publication	<1 %
13	Oya Demirci, Öykü Tosun, Güher Bolat. "Prenatal diagnosis and management of fetal supraventricular tachyarrhythmia and postnatal outcomes", <i>Journal of Gynecology Obstetrics and Human Reproduction</i> , 2022 Publication	<1 %
14	de.scribd.com Internet Source	<1 %
15	journals.sagepub.com Internet Source	<1 %

16	Batra, A.S.. "Arrhythmias: medical and surgical management", Paediatrics and Child Health, 200701 Publication	<1 %
17	tcpharm.org Internet Source	<1 %
18	www.si.mahidol.ac.th Internet Source	<1 %
19	"Maternal and Fetal Cardiovascular Disease", Springer Science and Business Media LLC, 2019 Publication	<1 %
20	Kaiyu Zhou, Yimin Hua, Qi Zhu, Hanmin Liu, Sen Yang, Rong Zhou, Nan Guo. "Transplacental digoxin therapy for fetal tachyarrhythmia with multiple evaluation systems", The Journal of Maternal-Fetal & Neonatal Medicine, 2011 Publication	<1 %
21	misc.medscape.com Internet Source	<1 %
22	onlinelibrary.wiley.com Internet Source	<1 %
23	"Cardiac Problems in Pregnancy, 4th Edition", Wiley, 2019 Publication	<1 %

24

Ali Ekiz, Basak Kaya, Helen Bornaun, Deniz Kanber Acar, Muhittin Eftal Avci, Aysegul Bestel, Gokhan Yildirim. "Flecainide as first-line treatment for fetal supraventricular tachycardia", The Journal of Maternal-Fetal & Neonatal Medicine, 2017

Publication

<1 %

25

Julene S. Carvalho. "Fetal dysrhythmias", Best Practice & Research Clinical Obstetrics & Gynaecology, 2019

Publication

<1 %

26

M. Da'i, M. Mirzaei, F. Toiserkani, S.M. Mohealdeen, Y. Yasin, M.M.S. Bekhit, R. Akhavan-Sigari. "Sensing the Formaldehyde Pollutant by an Enhanced BNC18 Fullerene: DFT Outlook", Chemical Physics Impact, 2023

Publication

<1 %

27

Olus Api, Julene S. Carvalho. "Fetal dysrhythmias", Best Practice & Research Clinical Obstetrics & Gynaecology, 2008

Publication

<1 %

28

Runxuan Du, Fangna Wang, Yuewen Dong, Wei Chu, Lishuang Ma, Jian Gao. "Intrauterine management and outcomes of persistent fetal atrial flutter: A case report", Birth Defects Research, 2023

Publication

<1 %

29

Sutopa Purkayastha, Michael Weinreich, Joao D. Fontes, Joe F. Lau, Diana S. Wolfe, Anna E. Bortnick. "Fetal Supraventricular Tachycardia: What the Adult Cardiologist Needs to Know", *Cardiology in Review*, 2020

Publication

<1 %

30

TERRENCE CHUN, BHAWNA ARYA. "Perinatal Arrhythmias", Elsevier BV, 2024

Publication

<1 %

31

Zhou, Kaiyu, Rong Zhou, Qi Zhu, Yifei Li, Chuan Wang, Chaomin Wan, Dezhi Mu, and Yimin Hua. "Evaluation of therapeutic effect and cytokine change during transplacental Digoxin treatment for fetal heart failure associated with fetal tachycardia, a case-control study", *International Journal of Cardiology*, 2013.

Publication

<1 %

32

japsonline.com

Internet Source

<1 %

33

"Urogynecology", *Journal of Obstetrics and Gynaecology Research*, 2020

Publication

<1 %

34

A. Chakladar. "Dangers of listening to the fetal heart at home", *BMJ*, 11/05/2009

Publication

<1 %

35

Alison Cahill. "Fetal monitoring and assessment", Wiley, 2015

Publication

<1 %

36

Hany M. Abd El-Lateef, Mai M. Khalaf, Amer A. Amer, Mahmoud Kandeel, Antar A. Abdelhamid, Aly Abdou. "Synthesis, Characterization, Antimicrobial, Density Functional Theory, and Molecular Docking Studies of Novel Mn(II), Fe(III), and Cr(III) Complexes Incorporating 4-(2-Hydroxyphenyl azo)-1-naphthol (Az)", ACS Omega, 2023

Publication

<1 %

37

J. S Carvalho. "Evaluation of fetal arrhythmias from simultaneous pulsed wave Doppler in pulmonary artery and vein", Heart, 12/12/2006

Publication

<1 %

38

Michael K. Fritsch, Nina Gotteiner, Jamaal A. Rehman, Erica Price, Linda M. Ernst. "Fetal Supraventricular Tachycardia: Histologic Evidence of Accessory Pathways Due to Incomplete Annulus Fibrosus Formation", Pediatric and Developmental Pathology, 2023

Publication

<1 %

Exclude bibliography On

Prolonged Resolution

GRADEMARK REPORT

FINAL GRADE

GENERAL COMMENTS

/100

PAGE 1

PAGE 2

PAGE 3

PAGE 4

PAGE 5

PAGE 6

PAGE 7

PAGE 8

PAGE 9

PAGE 10

PAGE 11
