

The Managerment of Monocharionic Monoamniotic

by Ernawati Ernawati

Submission date: 25-Sep-2023 11:24AM (UTC+0800)

Submission ID: 2175913496

File name: The_Managerment_of_Monocharionic_Monoamniotic.pdf (306.62K)


Word count: 4193

Character count: 22729





CASE REPORT

The management of Monochorionic Monoamniotic (MCMA) twin pregnancy

Ernawati¹, Jihan Qonitatillah², Agus Sulistyono¹

¹Department of Obstetrics and Gynecology, Universitas Airlangga, Dr. Soetomo General Academic Hospital, Surabaya, Indonesia. 

²Postgraduate Program, Faculty of Medicine, Universitas Airlangga, Surabaya, Indonesia.

Article Info	ABSTRACT 
<p>Received May 10, 2023 Revised Jun 27, 2023 Accepted Jul 5, 2023 Published Aug 1, 2023</p> <p>*Corresponding author: Ernawati ernawati@fk.unair.ac.id </p> <p>Keywords: Monochorionic Monoamniotic Twin pregnancy Delivery Management </p> <p>This is an open access article under the CC BY-NC-SA license (https://creativecommons.org/licenses/by-nc-sa/4.0/)</p> 	<p>Objectives: To present the management of monochorionic monoamniotic (MCMA) twin pregnancy.</p> <p>Case Report: Advanced prenatal treatment has improved the prognosis for Monochorionic Monoamniotic (MCMA) pregnancies; however, there is still no agreement on how to handle MCMA twins. The authors report 2 cases of monoamniotic monochorionic twin pregnancies. In the first case, a 30-years-old primi pregnant woman detected MCMA at 14 weeks of gestation; no complications related to MCMA were found; she planned delivery at 32 weeks, but one of the babies died in the womb at 31/32 weeks pregnant, a live baby born by cesarean section. The second case was a 36-year-old pregnant woman, on her third pregnancy, diagnosed with MCMA after 12 weeks of pregnancy, no complications related to MCMA, the baby was born at 32 weeks pregnant, and both babies survived. The management was the same in both cases, but different outcomes were obtained; in case 1, the baby died allegedly due to cord entanglement, which could not be detected during pregnancy.</p>

How to cite: Ernawati, Qonitatillah J, Sulistyono A. When is the optimum time to deliver for Monochorionic Monoamniotic (MCMA) twin pregnancy? A Case Report. *Majalah Obstetri & Ginekologi*. 2023;31(2):103-109. doi: 10.20473/mog.V31I22023.103-109.

Highlights:

1. Monochorionic monoamniotic (MCMA) twin pregnancy has a significant risk of perinatal morbidity and mortality, including intrauterine fetal death (IUFD).
2. The risk of prematurity, the risk of death due to MCMA complications, the availability of the NICU, also high costs on preterm care were factors in deciding to terminate the pregnancy.
3. The ideal time to deliver monochorionic twins in order to reduce the risks of cord entanglement, growth discrepancies, and intrauterine fetal death is still a point of controversy.
4. Early diagnosis, intensive antenatal monitoring, patient and family decision would contribute to antenatal mortality reduction.

INTRODUCTION

Monochorionic monoamniotic twin pregnancy shares the same amniotic sac with a single fertilized egg and embryo as a result of a single fertilization. Typically, it is diagnosed by the first trimester ultrasound, showing a single placenta and amniotic cavity that are shared.^{1,2} After 8 to 12 days of fertilization and zygote division, MCMA twin pregnancies occur.³ The incidence of MCMA twins is only about 5% among monochorionic pregnancies, or one in every 10,000 pregnancies.⁴

Assisted reproductive techniques, ethnicity, advanced maternal age, genetic and epigenetic mechanisms have been implicated as MCMA twin pregnancy risk factors.³ Advanced prenatal treatment has improved the prenatal prognosis for MCMA pregnancies, however there is still no agreement on how to handle MCMA twins. Monochorionic monoamniotic (MCMA) twin pregnancy has a significant risk for poor pregnancy outcomes, increasing perinatal morbidity and mortality, including intrauterine fetal death (IUFD) correlated to double twin demise due to severe fetal hypovolemia and anemia caused by twin-to-twin transfusion syndrome and also a risk of cord entanglement compare to the risk of prematurity and their complications due to earlier delivery time.⁵⁻⁹ Early diagnosis usually at early semester and proper management can reduce the risk of complications. It is a challenging decision to decide on a delivery time because there is less evidence regarding the optimal timing or method of delivery due to their rarity.¹⁰

There is no consensus regarding the timing of delivery in monochorionic monoamniotic pregnancies. This case report will present the management of MCMA twins pregnancy and reporting two cases of monochorionic monoamniotic twin with a single fetal loss in the 31st week of gestation and surviving both twins in second cases.

CASE REPORT

Case I

Mrs. S, 26-year-old, primigravida, attended the Obstetrics and Gynecology Polyclinic type B Hospital with a one-month history of delayed menstruation. There was no family history of past medical illness or twin pregnancies. The physical assessment and vital signs were normal. According to 6 weeks gestation age, an abdominal ultrasound examination showed a gestational sac containing a yolk sac with no apparent fetal pole. The patient returned at 14 weeks of gestation; an ultrasound examination showed an intrauterine

gestational sac with two fetuses in one sac and a positive fetal heart rate. There was no visible amniotic membrane, but the fetal growth was normal. The patient was given folic acid, iron, and calcium supplements and planned for pregnancy control a month later.

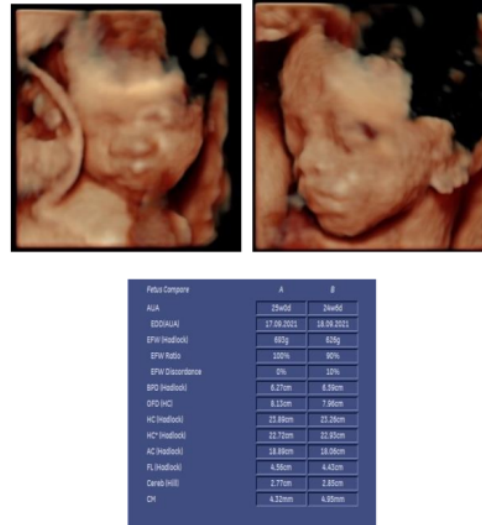


Figure 1. Case I: Normal fetal biometry on both of the fetus. No sign of twin-to-twin transfusion syndrome (TTTS)

Second-trimester screening examination at 24 weeks gestation showed a normal general condition. Ultrasound obtained twin babies; the first fetus was in a transverse position, equal to 24 weeks and three days gestational age, and the second fetus was in a breech position, equal to 23 weeks and five days gestational age (Figure 1). The placenta was located in the front wall, grade 2, and the amniotic fluid index was sufficient. No dividing amniotic membrane was found, concluding a monochorionic monoamniotic twin pregnancy. The patient was planned for outpatient care, iron and calcium supplementation, and delivery at 30- or 31-weeks gestation. The patient was planned for control every two weeks and asked to monitor daily fetal movements. During antenatal care, fetal growth was normal, and there were no signs of discrepancies in the fetus.

The fetus was in the head/head position, there was no cord entanglement, the estimated fetal weight was 1100–1200g, and the fetal movement was active according to anamnesis at 30 weeks of gestation. We decided to delay delivery until 32 weeks due to the



fetus's all-head positioning, average fetal growth, and the possibility of preterm for small newborns. Patients were checked every week, and if they saw a change in the fetus' movements or experienced any contractions, they were urged to go back to the hospital right away.

A week later, the patient returned, uncomplaining and with frequent fetal movements. The second fetus, however, had no heartbeat, according to an ultrasound. As the first pregnancy reached 31 or 32 weeks, the fetus was still in good health. The patient was admitted to the hospital, got fetal lung maturation, and underwent cesarean delivery preparation. During the procedure, cord entanglements and red-black amniotic fluid were discovered. The first fetus, which weighed 1330 g, was still alive; the second, which weighed 1220 g, passed away. The infant was then given surfactant and put on a ventilator in the NICU for treatment. No neurological damaged detected. The infant was released in good health following a four-week stay in the hospital.

Case 2

A 36-year-old female, gravida 3, para 2, was attended to the hospital and diagnosed with an MCMA twin pregnancy at 12 weeks of gestation. She is from a mid to high-income family. No medical and pregnancy complications were recorded in her previous pregnancy and delivered by C-section. The two living children were normal—no history of assisted reproduction in this pregnancy. An abdominal ultrasound examination showed no signs of twin-to-twin transfusion syndrome (TTTS) and normal fetal growth during antenatal care. Maternal laboratory examination also showed a normal result. The patient was planned to undergo monthly monitoring until 24 weeks gestation, every two weeks until 30 weeks gestation, and weekly monitoring until delivery.

Considering the risk of umbilical cord entanglement and prematurity, patients were informed of the option to terminate pregnancies after 30 weeks. As a result of the evaluation showing normal fetal growth, the patient was encouraged to decide either delivering the baby at 30/31 weeks or expecting as of 31/32 weeks. The family decided to wait until 32 weeks, with fetal movement monitoring and weekly hospital monitoring after 30 weeks gestation.

The baby was born at 32 weeks gestation after being given lung maturation for two days. Due to the patient's prior two caesarean sections, caesarean delivery was chosen as the delivery method. Infants born weighing

1900 g and 2000 g; despite the infant weighed more than 1500 g, respiratory distress syndrome (RDS) still occurred (Figure 2). The infants were discharged after three weeks of ventilator support.

DISCUSSION

Monoamniotic twin pregnancies are distinguished by a single shared placenta and amniotic cavity.² The absence of a dividing membrane, rather than the number of yolk sacs present, is used to diagnose an MCMA twin pregnancy.¹¹ If the membrane is less than 2 millimeters thick or there are only two layers visible, the pregnancy is monochorionic. It has been found that the number of membrane layers can accurately predict prenatal chorionicity with an accuracy of better than 98 percent.¹² Sometimes the transvaginal approach allowed for accurate representation of chorionicity and amnionicity.^{2,7}

In the first case MCMA undetected on the 6th weeks of pregnancy, but detected when she was attend the second time at 14th weeks of pregnancy. During the first few weeks of pregnancy, when the membrane is almost undetectable, MCMA twins are frequently misdiagnosed. It is recommended to determine amnionicity prior to 14 weeks of gestation and to repeat the ultrasound examination in cases where the dividing membrane cannot be identified.^{6,13} It is advantageous to be able to predict amnionicity at an early stage since the diagnostic precision of recognizing monoamniotic twin pregnancies is crucial for management strategies. The aim of MCMA management is to reduce the mortality associated with undetected cases and minimize false-positive diagnosis that lead to improper interventions.¹¹

After the first trimester, we typically perform ultrasounds every two weeks to check the viability of the fetuses and screen for growth restriction and TTTS. Cord entanglement is difficult to detect in cases of MCMA; no examination can predict it. Weakening of fetal movement after previously moving quickly is a subjective symptom that can be known but cannot be used as a reference. The presence of decelerations on cardiotocography examination during labor is one of the signs. However, seeing if the patient has yet to give birth will be difficult. When delivery and postnatal care become an option, often between 24 and 28 weeks of gestation, the frequency of follow-up visits is increased; from that point on, we are able to intervene in the event of findings indicating imminent fetal mortality.^{2,14}

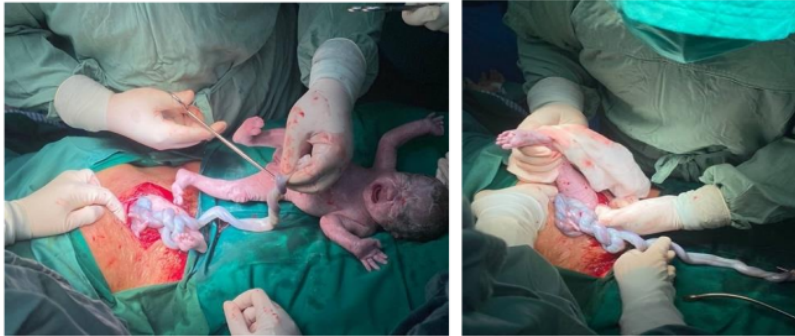

Figure 2. Case 2: Twisted umbilical cords at risk of cord entanglement to fetal death were found at surgery.
Left: The first baby. Right: The second baby.

There is not enough evidence currently available to recommend which method of monitoring is the most effective; hence, the majority of professionals will use a combination of ultrasound surveillance and monitoring of the fetal heart rate.^{2,14} In cases of monochorionic diamniotic twin pregnancy, it is recommended that ultrasonography be performed at least once every two weeks, with attention paid to discrepancies in amniotic fluid volume and fetal growth, in order to detect TTTS.⁶ Regular ultrasound monitoring can help predict pregnancies with an increased risk of fetal growth restriction and growth discordance.^{5,15} Observational studies show that once surveillance is implemented, the prospective risk of fetal death decreases by 5% compared to before surveillance was implemented. It is recommended to refer monoamniotic twin pregnancies to specialized centers for management and delivery.²

The ideal time to deliver monochorionic twins in order to reduce the risks of cord entanglement, growth discrepancies, and intrauterine fetal death is still a point of controversy. However, the number of previous studies indicates that the best timing for delivery of MCMA twins is between 32 and 34 weeks of gestation.^{5,13} The crude perinatal mortality rate for women with monoamniotic twins at 22 weeks of gestation is approximately 15%.⁶ Many researchers consider that inpatient management, thorough monitoring of monoamniotic twins, and early birth at 32 to 34 weeks of gestation may enhance outcomes,⁶ although this has not yet been confirmed.

Despite the findings of cord entanglement, expectantly managed monoamniotic twins at 20 weeks have a very better prognosis. Expectant management was started during the late second or early third trimester, with a targeted delivery between 32 to 34 weeks. Perinato-

logists at the tertiary care facilities where the patients were transferred for confirmation and consultation prepared these strategies. Considering that the fetus in this case was less than 32 weeks, the patient was managed as an outpatient. Also, recent studies indicate that prolonged hospital stays have considerable economic, societal costs, and family disruption including psychiatric symptoms such as hopelessness and despair, which the inpatient group experienced more than the outpatient group did.²

Due to the larger placenta and greater uterine capacity in monochorionic monoamniotic twin pregnancies, monoamniotic twin pregnancies are associated with a higher risk of pregnancy problems compared to singleton pregnancies.² Studies stated between 28 to 47 percent of monochorionic monoamniotic twin pregnancies result in perinatal mortality.^{7,9} Frequent and adversely severe problems are associated with a shared placental circulation. TTTS and TAPS are caused by imbalanced blood flow across the placental vascular anastomoses, while fetal growth restriction is mostly caused by unequal placental sharing.^{16,17} Most fetal deaths occur during the first two trimesters of pregnancy, however, even after 24 weeks, the risk of fetal death in monoamniotic pregnancies is nine times greater than in dichorionic twin pregnancies. Cord entanglement or abrupt hemodynamic imbalances resulting from massive placental anastomoses commonly contribute to fetal deaths.²

In the Case 1, during follow-up to 31/32 weeks of gestational age, an ultrasound examination showed normal fetal growth and no signs of discrepancy in the fetus or umbilical cord, but we could not find the second fetal heart rate. In a monochorionic twin pregnancy, single IUFD is fatal for the surviving twin due to severe

fetal hypovolemia and anemia caused by blood transfusion from the surviving fetus to the deceased fetus.⁷ In the case of a single fatality, 57% of the surviving twin is at risk of sustaining a serious brain injury. The presence of extensive placental artery-to-artery anastomoses allows the surviving fetus to exsanguinate into the dead fetus.²

Elective preterm delivery of monochorionic twin pregnancy is recommended when the possible risks of postponing delivery exceed the risk of delivery.^{2,18} Premature newborns, particularly those delivered prior to 32 weeks of gestation, are susceptible to a variety of health complications. Cordero et al.⁹ reported a high incidence of perinatal depression, respiratory distress, early and late onset sepsis, patent ductus arteriosus, necrotizing enterocolitis, intracranial hemorrhage, prolonged hospitalization, and poor neurological outcomes in premature newborns. Therefore, although elective very preterm delivery has a low fatality rate, it should be reevaluated due to its high morbidity rate.⁷ Delivery of the baby should be considered while there are prolonged episodes of fetal tachycardia or repeated heart rate decelerations. Due to the lack of evidence on optimal delivery triggers and poor response to subtle indicators of fetal distress, physician experience plays an important role in preventing unnecessary early delivery.²

Delivery at 31/32 weeks of gestational age in both case were decided by cesarean section after receiving lung maturation. Considering monoamniotic twins, most centers would suggest a cesarean delivery to prevent cord prolapse or accidental clamping of the second twin's cord, which could be securely wrapped around the neck of the first twin.^{7,15} A cesarean section is recommended to be done at 32 to 34 weeks of gestation age.⁴ To reduce the risk of cord prolapse for the remaining fetus,⁶ fetoscopic cord transection of the deceased fetus may be considered on a case-by-case basis.^{2,19} There is still no consensus in the evidence regarding the management and mode of delivery of these rare cases.

The risk of prematurity and the risk of death due to MCMA complications must be considered in MCMA pregnancy care, so parents must be involved in decision-making in order to comprehend the risks. In the two cases above, there were no complications associated with MCMA, such as TTTS. However, in case 1, there appeared to be a risk of cord entanglement, where this diagnosis was difficult to make due to the constant movement of the fetus. While the second case did not occur, we were able to manage to get both infants alive. It was difficult to predict the occurrence of these complications; therefore, a joint decision with the

parents to consider the risks and benefits, as well as the availability of the NICU, was the factor in deciding whether to terminate the pregnancy. Basnet et al.²⁰ reported that 40.6% of preterm infants in tertiary care center had neonatal intensive care unit admissions, which may then improve preterm outcomes and significantly associated with lower mortality.^{20,21} Other study reported NICU admission has increased from 6.4% in 2007 to 7.2% in 2018 as the number of newborns requiring intensive care has increased.²² In the two cases above, all infants needed a NICU for treatment, hence in cases of twins and MCMA, a hospital with a NICU was required for care.

The strength of this case report is that it presents the management of a rare case of monoamniotic twins and the challenges of their management. Handling must be reviewed case by case because each type of case has its uniqueness. While the weakness in this case report is that the number of cases reported is only two because the types of cases are rare, so they cannot be presented in a case series. However, these two cases can provide an overview of the management of monoamniotic twin cases.

CONCLUSION

Monochorionic monoamniotic twin pregnancy is at a significant risk for poor pregnancy outcomes, and due to their rarity, there is less evidence regarding their management. Guiding expert opinions to the current best practice, risks can be avoided through close monitoring and following viability. Monitoring should include ultrasonography and monitoring of the fetal heart rate; however, the optimal frequency of monitoring, the optimal management, whether inpatient or outpatient, and the delivery triggers have not been determined. To improve outcomes, monoamniotic twins should be delivered by elective cesarean section between 32 and 34 weeks of gestation. Early diagnosis, intensive antenatal monitoring in the hospital beginning at the time of fetal viability, and elective delivery at 32 weeks would contribute to antenatal mortality reduction.

DISCLOSURES

Acknowledgment

Thanks to all the study participants and the fetomaternal team of Dr. Soetomo General Academic Hospital, Surabaya, Indonesia, for their support.

Conflict of interest

The authors report there are no competing interests to declare.

Patient consent for publication

The patient signed the informed consent form and agreed that this case report is published.

Funding

This research has received no external funding.

Author Contribution

All authors have contributed to all processes in this research, including preparation, data gathering and analysis, drafting and approval for publication of this manuscript.

REFERENCES

1. Svelato A, Vergatti MC, Rinaldo D, et al. Cord entanglement in a monochorionic-monoamniotic twin pregnancy: A case report. *Int J Gynaecol Obstet*. 2021;154(3):570-1. doi: [10.1002/ijgo.13780](https://doi.org/10.1002/ijgo.13780). Epub 2021 Jun 25. PMID: 34101825.
2. Miegheem TV, Abbasi N, Shinar S, et al. Monochorionic monoamniotic twin pregnancies Definition and epidemiology. *Am J Obstet Gynecol*. 2021;3(4):100520. doi: [10.1016/j.ajogmf.2021.100520](https://doi.org/10.1016/j.ajogmf.2021.100520).
3. Ozler S, Oztas E, Uygur D, et al. Monoamniotic monokoryonik ikiz sirkumvallat plasenta ve konglomere umbilikal kord. *Cukurova Medical Journal (Çukurova Üniversitesi Tıp Fakültesi Dergisi)*. 41(18992):604-6. doi: [10.17826/cukmedj.55644](https://doi.org/10.17826/cukmedj.55644).
4. Glinianaia SV, Rankin J, Khalil A, et al. Prevalence, antenatal management and perinatal outcome of monochorionic monoamniotic twin pregnancy: a collaborative multicenter study in England, 2000-2013. *Ultrasound Obstet Gynecol*. 2019;53(2):184-92. doi: [10.1002/uog.19114](https://doi.org/10.1002/uog.19114). Epub 2018 Dec 30. PMID: 29900612.
5. Al Riyami N, Al-Rusheidi A, Al-Khabori M. Perinatal outcome of monochorionic in comparison to dichorionic twin pregnancies. *Oman Med J*. 2013;28(3):173-7. doi: [10.5001/omj.2013.49](https://doi.org/10.5001/omj.2013.49). PMID: 23772282; PMCID: PMC3679607.
6. Morikawa M, Yamada T, Yamada T, et al. Prospective risk of intrauterine fetal death in monoamniotic twin pregnancies. *Twin Res Hum Genet*. 2012;15(4):522-6. doi: [10.1017/thg.2012.30](https://doi.org/10.1017/thg.2012.30). PMID: 22853819.
7. Eserdag S, Zulfikaroglu E, Ozer A. Cord entanglement in monochorionic monoamniotic twins. *Bratisl Lek Listy*. 2010;111(12):673-5. PMID: [21384739](https://pubmed.ncbi.nlm.nih.gov/21384739/).
8. Machino H, Iriyama T, Nakayama T. A case of a surviving co-twin diagnosed with porencephaly and renal hypoplasia after a single intrauterine fetal death at 21 weeks of gestation in a monochorionic monoamniotic twin pregnancy. *Oxf Med Case Reports*. 2017;2017(1):omw096. doi: [10.1093/omcr/omw096](https://doi.org/10.1093/omcr/omw096). PMID: 28116109; PMCID: PMC5241712.
9. Cordero L, Franco A, Joy SD. Monochorionic monoamniotic twins: neonatal outcome. *J Perinatol*. 2006;26(3):170-5. doi: [10.1038/sj.jp.7211457](https://doi.org/10.1038/sj.jp.7211457). PMID: 16467856.
10. Aggarwal P, Terhase N. Cord entanglement in monochorionic monoamniotic twins: a case report. *Int J Reprod Contracept Obstet Gynecol*. 2015; 4(6):2091-2. doi: [10.18203/2320-1770.ijrcog20151326](https://doi.org/10.18203/2320-1770.ijrcog20151326).
11. Murakoshi T, Ishii K, Matsushita M, et al. Monochorionic monoamniotic twin pregnancies with two yolk sacs may not be a rare finding: a report of two cases. *Ultrasound Obstet Gynecol*. 2010;36(3):384-6. doi: [10.1002/uog.7710](https://doi.org/10.1002/uog.7710). PMID: 20533442.
12. Fuchs KM, D'Alton ME. Chorionicity of multiple gestations. In: *Obstetric imaging: Fetal diagnosis and care: Second Edition*. Elsevier Inc.; 2017. p. 639-641.e1.
13. Baud D, Windrim R, Van Miegheem T, et al. Twin-twin transfusion syndrome: a frequently missed diagnosis with important consequences. *Ultrasound Obstet Gynecol*. 2014;44(2):205-9. doi: [10.1002/uog.13328](https://doi.org/10.1002/uog.13328). Epub 2014 Jun 27. PMID: 24549628.
14. MONOMONO Working Group. Inpatient vs outpatient management and timing of delivery of uncomplicated monochorionic monoamniotic twin pregnancy: the MONOMONO study. *Ultrasound Obstet Gynecol*. 2019;53(2):175-83. doi: [10.1002/uog.19179](https://doi.org/10.1002/uog.19179). Epub 2018 Dec 30. PMID: 30019431.
15. Júnior JE, Félix E, Santana M, et al. Monochorionic twin pregnancy-potential risks and perinatal outcomes. In *IntechOpen*; 2015. doi: [10.5772/58951](https://doi.org/10.5772/58951).
16. Lopriore E, Lewi L, Khalil A. Monochorionic twins: A delicate balance. *J Clin Med*. 2019; 8(10):1711. doi: [10.3390/jcm8101711](https://doi.org/10.3390/jcm8101711). PMID: 31627398; PMCID: PMC6832893.
17. Hack KE, van Gemert MJ, Lopriore E, et al. Placental characteristics of monoamniotic twin pregnancies in relation to perinatal outcome.



- Placenta. 2009;30(1):62-5. doi: [10.1016/j.placenta.2008.09.016](https://doi.org/10.1016/j.placenta.2008.09.016). Epub 2008 Nov 17. PMID: 19010539.
18. Van Mieghem T, De Heus R, Lewi L, et al. Prenatal management of monoamniotic twin pregnancies. *Obstet Gynecol*. 2014;124(3):498-506. doi: [10.1097/AOG.0000000000000409](https://doi.org/10.1097/AOG.0000000000000409). PMID: 25162249.
 19. Greimel P, Csapo B, Haeusler M, et al. A modified technique for cord transection in monochorionic monoamniotic twin pregnancies. *Fetal Diagn Ther*. 2018;44(3):236-40. doi: [10.1159/000489882](https://doi.org/10.1159/000489882). Epub 2018 Aug 8. PMID: 30089297.
 20. Basnet S, Adhikari S, Jha J, et al. Neonatal intensive care unit admissions among preterm babies in a tertiary care centre: A descriptive cross-sectional study. *JNMA J Nepal Med Assoc*. 2022; 60(248):364-8. doi: [10.31729/jnma.7240](https://doi.org/10.31729/jnma.7240). PMID: 35633222; PMCID: PMC9252253.
 21. Watson SI, Arulampalam W, Petrou S, et al.; Neonatal Data Analysis Unit and the NESCOPE Group. The effects of designation and volume of neonatal care on mortality and morbidity outcomes of very preterm infants in England: retrospective population-based cohort study. *BMJ Open*. 2014; 4(7):e004856. doi: [10.1136/bmjopen-2014-004856](https://doi.org/10.1136/bmjopen-2014-004856). PMID: 25001393; PMCID: PMC4091399.
 22. Fu M, Song W, Yu G, et al. Risk factors for length of NICU stay of newborns: A systematic review. *Front Pediatr*. 2023;11:1121406. doi: [10.3389/fped.2023.1121406](https://doi.org/10.3389/fped.2023.1121406). PMID: 36994438; PMCID: PMC10040659.

The Management of Monocharionic Monoamniotic

ORIGINALITY REPORT

16%

SIMILARITY INDEX

7%

INTERNET SOURCES

14%

PUBLICATIONS

%

STUDENT PAPERS

PRIMARY SOURCES

- 1 Delima.khairudin, Asma Khalil. "MONOCHORIONIC monoamniotic twin pregnancies", Best Practice & Research Clinical Obstetrics & Gynaecology, 2022
Publication 1%
- 2 www.omjournal.org
Internet Source 1%
- 3 T. Murakoshi, K. Ishii, M. Matsushita, T. Shinno, H. Naruse, Y. Torii. "Monochorionic monoamniotic twin pregnancies with two yolk sacs may not be a rare finding: a report of two cases", Ultrasound in Obstetrics and Gynecology, 2010
Publication 1%
- 4 academic.oup.com
Internet Source 1%
- 5 Mamoru Morikawa, Takashi Yamada, Takahiro Yamada, Shoji Sato, Hisanori Minakami. "Prospective Risk of Intrauterine Fetal Death in Monoamniotic Twin Pregnancies", Twin Research and Human Genetics, 2012 1%

6	"Protocols for High-Risk Pregnancies", Wiley, 2010 Publication	1 %
7	"Perinatology", Springer Science and Business Media LLC, 2022 Publication	1 %
8	www.nature.com Internet Source	1 %
9	Patricia Steenhaut, Corinne Hubinont. "Chapter 5 Perinatal Mortality in Multiple Pregnancy", IntechOpen, 2012 Publication	1 %
10	mafiadoc.com Internet Source	1 %
11	vyshows.com Internet Source	1 %
12	www.glowm.com Internet Source	1 %
13	Jena L. Miller. "Twin to twin transfusion syndrome", Translational Pediatrics, 2021 Publication	1 %
14	"Keeling's Fetal and Neonatal Pathology", Springer Science and Business Media LLC, 2022 Publication	<1 %

15 Noa Gilad, Vagisha Pruthi, Shiri Shinar, Johannes Keunen, Greg Ryan, Tim Van Mieghem. "Chapter 18 Monochorionic Monoamniotic Twin Pregnancy", Springer Science and Business Media LLC, 2021
Publication

<1 %

16 Delabaere Amélie, Bouchet Pamela, Sendy Ferras, Petillon Fanny, Gallot Denis. "Management of monoamniotic twin pregnancies: Where, when, how?", Journal of Gynecology Obstetrics and Human Reproduction, 2022
Publication

<1 %

17 www.journal-jams.org
Internet Source

<1 %

18 repository.unair.ac.id
Internet Source

<1 %

19 Yvon Chitrit, Diane Korb, Cecile Morin, Thomas Schmitz, Jean-François Oury, Olivier Sibony. "Perinatal mortality and morbidity, timing and route of delivery in monoamniotic twin pregnancies: a retrospective cohort study", Archives of Gynecology and Obstetrics, 2020
Publication

<1 %

20 ÖZLER, Sibel, ÖZTAŞ, Efser, UYGUR, Dilek, KIRBAŞ, Ayşe and NANIŞMAN, Nuri.

<1 %

"Monochorionic monoamniotic twins circumvallate placenta and conglomerated umbilical cord", Çukurova Üniversitesi, 2016.

Publication

21

Ishii, Keisuke. "Prenatal diagnosis and management of monoamniotic twins :", Current Opinion in Obstetrics & Gynecology, 2015.

Publication

22

T. Van Mieghem, A. Shub. "Management of monoamniotic twins: the question is not 'where?', but 'how?'" , Ultrasound in Obstetrics & Gynecology, 2019

Publication

23

pubmed.ncbi.nlm.nih.gov

Internet Source

24

www.frontiersin.org

Internet Source

25

www.mdpi.com

Internet Source

26

A. Khalil, B. Liu. "Controversies in the management of twin pregnancies", Ultrasound in Obstetrics & Gynecology, 2020

Publication

27

Sanne Deneckere, Isabel Couck, Roland Devlieger, Luc Catte, Jan Deprest, Frédéric Chantraine, Liesbeth Lewi. "Placental vascular

<1 %

<1 %

<1 %

<1 %

<1 %

<1 %

<1 %

recruitment after single intrauterine demise:
A newly diagnosed phenomenon unique to
monochorionic pregnancies", Prenatal
Diagnosis, 2019

Publication

28

"1-A1: Lung Cancer 1 : Poster Sessions",
Respirology, 2013.

Publication

<1 %

29

Vedran Stefanovic, Irmeli Nupponen, Riina
Maria Jernman. "Excellent perinatal outcome
of monoamniotic twin pregnancy with timely
diagnosis and optimal management- a
retrospective cohort study", Journal of
Perinatal Medicine, 2022

Publication

<1 %

30

Benirschke, Kurt, Graham J. Burton, and
Rebecca N. Baergen. "Multiple Pregnancies",
Pathology of the Human Placenta, 2012.

Publication

<1 %

31

Wojciech Homola, Jerzy Florjański, Barbara
Królak-Olejniak, Tomasz Fuchs, Monika
Lachowska, Wiktor Bek. "The impact of
chorionicity and the type of twin growth on
the early neonatal outcome in twin
pregnancies – 20 years of experience from
one tertiary perinatal center", Taiwanese
Journal of Obstetrics and Gynecology, 2019

Publication

<1 %

Exclude quotes On

Exclude matches Off

Exclude bibliography On

The Managerment of Monocharionic Monoamniotic

GRADEMARK REPORT

FINAL GRADE

GENERAL COMMENTS

/100

PAGE 1

PAGE 2

PAGE 3

PAGE 4

PAGE 5

PAGE 6

PAGE 7