



CASE REPORTS

Transient median nerve palsy following ultrasound-guided subscapularis plane block: a case report

Syahrul Mubarak Danar Sumantri ^{a,*}, Anna Surgean Veterini^b

^a *Siloam Hospitals Jember, Department of Anaesthesiology & Critical Care, Jember, Indonesia*

^b *Dr. Soetomo General Hospital, Department of Anaesthesiology & Intensive Therapy, Surabaya, Indonesia*

Received 24 July 2020; accepted 2 April 2021

Available online 27 April 2021

KEYWORDS

Case report;
Nerve block;
Adverse effects

Abstract The subscapularis plane block is an effective approach to anesthetize axillary and upper subscapular nerves. There have been no reports regarding brachial plexus paralysis as a potential complication to date. Described here is a case of median nerve palsy following ultrasound-guided subscapularis plane block for awake frozen shoulder manipulation that was performed on a 52-year-old female diagnosed with adhesive capsulitis. The patient could not flex digits two and three, and ipsilateral inner palm numbness occurred shortly after the block commenced, with complete resolution in the next two hours. The local anesthetics spillage towards brachial plexus with possible partial paralysis should always be expected after subscapularis plane block.

© 2021 Sociedade Brasileira de Anestesiologia. Published by Elsevier Editora Ltda. This is an open access article under the CC BY-NC-ND license (<http://creativecommons.org/licenses/by-nc-nd/4.0/>).

Introduction

Subscapularis plane block (SSPB) has only been reported three times by anesthesiologists who wanted to achieve analgesia over the shoulder region, in addition to the suprascapular and lateral pectoral nerve blocks.^{1–3} Until then, there had been no reports concerning complication associ-

ated with this plane block. We present our experience with one case of median nerve palsy complicating SSPB for awake frozen shoulder manipulation and investigate its possible mechanism.

Case report

A 52-year-old female patient of 50 kg weight and 156 cm height was scheduled to undergo awake frozen shoulder manipulation for her left shoulder's painful adhesive capsulitis. The patient, however, refused her orthopedic sur-

* Corresponding author.

E-mail: caliptra36@gmail.com (S.M. Sumantri).

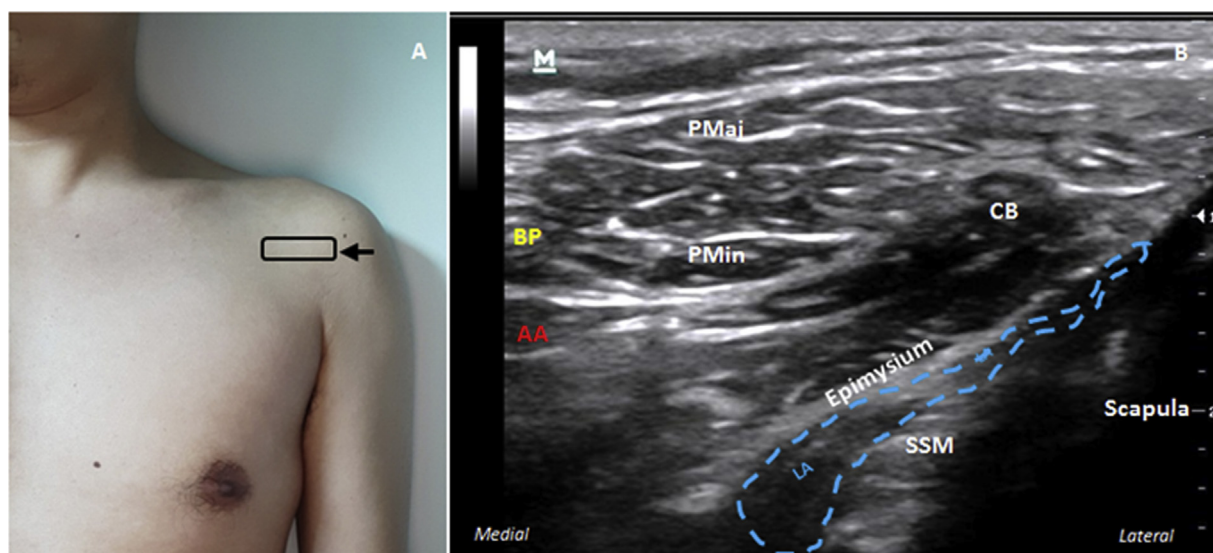


Figure 1 A, Illustration of probe positions and needle directions for subscapularis plane block (SSPB); B, Ultrasound image of local anesthetic (LA) deposited beneath subscapularis muscle (SSM) epimysium. Brachial plexus (BP) was seen at the medial of the screen above axillary artery (AA). The three layers of muscle at the anterior border of subscapularis plane were coracobrachialis (CB), pectoralis minor (P.Min), and pectoralis major (P.Maj) muscle.

geon's reference for physical rehabilitation through shoulder manipulation, leaving her with worsening pain and limited shoulder movement that went untreated for two weeks. Considering her previous history of recurrent asthma attacks and her objection to potential complication of transient unilateral phrenic nerve that might risk her respiratory status, she refused the option of ipsilateral interscalene brachial plexus (BP) block.

We presented an alternative interfascial plane shoulder block consisting of combined SSPB, pectoral and suprascapular nerve block with careful explanation of its novelty and limited evidence, earning the patient and her relative's consent. The first block given was SSPB by administering 15 ml of 1.5% lidocaine with epinephrine 0.1 mg (5 µg.mL⁻¹), guided by ultrasonography as described by Sondekoppam et al.¹ with the illustrative probe position as shown in Figure 1A.

The probe was positioned at the axial plane of shoulder, where the lesser trochanter of humerus and the subscapularis muscle were well-identified sonographically. After local skin infiltration, a non-stimulating 100-mm-long, 21G, short-beveled needle (Locoplex®, Vygon, Padova, Italy) was inserted in-plane with the ultrasound probe, in a lateral-to-medial direction. The needle was advanced until the tip is positioned in the interfascial plane between the coracobrachialis (CB) and subscapularis muscle (SSM). Color Doppler real-time evaluation during needle insertion is paramount to avoid unintentional puncture to the anterior and posterior circumflex humeral arteries. It is then advanced further, with a small amount of hydrodissection solution (normal saline) being injected carefully until a visible spread of solution dissected SSM away from its epimysium (Fig. 1B). After confirming the correct needle tip position, the author then deposited the desired amount of local anesthetics (LA) exactly beneath the SSM epimysium.

Fifteen minutes after injecting LA, before commencing with the two other blocks, the patient complained of

hypoesthesia at the lateral side of ipsilateral inner palm, followed by the inability to flex digits two and three into a compact fist, corresponding to proximal median nerve palsy. After reassuring the patient that the complication would be transient, two other blocks were given without any significant findings. Shoulder manipulation was uneventful, with a duration of 30 minutes. Two hours after SSPB commenced, symptoms of proximal median nerve palsy had been completely remitted. During the next day's follow-up evaluation by phone, the patient did not mention any complaint nor subsequent problem related to her previous transient median nerve palsy and was satisfied with the intervention.

Discussion

The subscapularis plane is a potential space between the anterior aspect of SSM and pectoralis major muscle (PMM). First described by Sondekoppam et al., this approach focuses on subscapular (SSN) and axillary nerves (AN) as these structures are present on the ventral surface of SSM. Its clinical significance is that these nerves provide sensory supply to anterior and posteroinferior quadrants of the shoulder.^{1,4}

The ideal approach to achieve optimum SSN and AN block is still debatable until recently, since there have only been three papers describing ultrasound-guided fascial block technique related to SSM by employing different methods. Earlier, Sondekoppam et al. and Drake et al. injected LA over the ventral surface of SSM at the intermuscular plane beneath PMM. Later, Tran et al. decided to put LA in the plane between SSM and anterior glenohumeral joint capsule. All authors have effectively blocked SSN and AN with a different volume of LA; 15, 10, and 2 ml, respectively.¹⁻³

Anatomically, lateral approach to SSPB with the medial border of coracobrachialis muscle as stop demarcation line of the needle tip can be considered safe as there is no major structure on the needle path. Also, the presence of

sheath towards the proximal third of the upper arm may theoretically limit LA's spread into BP, causing unwanted upper extremity paralysis.⁵ Positioning the needle tip over the ventral surface of SSM for SSPB is presumed to cause BP involvement as suggested by Drake et al. from their cadaveric dissection that showed posterior cord and radial nerve staining following methylene blue injection.³ Unfortunately, Sondekoppam et al. did not mention any BP involvement in their correspondence.¹ Given the possibility of BP involvement following SSPB from the previous approach, the author decided to inject LA beneath the epimysium of SSM.

It is reasonable that another approach by Tran et al. should instead be performed as it utilizes less volume of LA that is deposited beneath SSM and separated from BP, so then the likelihood of BP involvement would be far lower than the author's approach. Tran et al. performed such an approach merely to stain the anterior capsule of shoulder joint, not specifically targeting SSN and AN like the author did.² On his two lightly embalmed cadaveric shoulders, Tran et al. found that an amount of 3 ml dye could stain the main trunk of AN and articular branch of SSN. However, considering the anatomical variation of nerve branches, one should carefully implement this limited evidence on living subjects as no studies nor reports following said publication recommend the practice.² Nevertheless, due to the limited evidence of median nerve paralysis as a complication of SSPB, the author found patient's complete consent as lacking during the preoperative visit, resulting in patient's temporary disappointment when the unexpected event occurred.

Drake et al. were the first to show how partial BP involvement could occur as the dye might stain the posterior cord and radial nerve as it ran in the same plane where they deposited the injection. They found that the posterior cord of BP ran right on the medial side of subscapularis muscle-tendon junction at the anterior surface of the SSM, overlaid only by subcutaneous tissue.³ Apart from that, the implausibility of median nerve involvement was supported by its position, that was lateral from SSM myotendinous junction and far anterior to the axillary artery (AA). Nevertheless, throughout the extensive literature search, this report may be the first to address such an unusual complication of SSPB involving median nerve paralysis.

The first possible mechanism lies in the debatable presence of BP sheath expanding from the neck to the distal end of the axilla, as it is vital as a proposed mechanical barrier against unintentional spillage of LA from the adjacent interfascial plane block. The conflicting BP sheath anatomy may theoretically explain inadvertent LA spillage towards BP, voiding the likelihood of needle positioning failure as the

author had carefully observed needle tip under ultrasound followed by further normal saline hydrodissection to confirm its position beneath the fascia of SSM before injecting LA. The second aspect of the mechanism of SSPB involving BP paralysis is the volume of LA. There is no defined volume of LA needed for SSPB to completely cover AN and SSN other than what Sondekoppam et al. published, but many other fascial plane blocks were known to have a smaller volume to reduce unintended nerve blocks other than what was targeted.¹

The causes of median nerve paralysis following SSPB can only be hypothesized as there is an insufficient report regarding this complication. Theoretically, it has resulted from LA spillage towards BP from a large volume of LA injections and diffusion through adjacent thoracic structures. Despite its nature as self-limiting perioperative morbidity, the occurrence of BP paralysis may concern patients, in addition to increased length of stay and hospital costs. Further cadaveric and clinical studies are needed to determine the ideal LA technique and volume for SSPB without complicating PB paralysis.

Conflicts of interest

The authors declare no conflicts of interest.

Acknowledgement

Published with the written consent of the patient. No external funding or other competing interests declared.

References

1. Sondekoppam RV, Lopera-Velasquez LM, Naik L, et al. Subscapularis and sub-omohyoid plane blocks: an alternative to peripheral nerve blocks for shoulder analgesia. *Br J Anaesth*. 2016;117:831–2.
2. Tran J, Agur A, Peng P. Deep plane to subscapularis approach for anterior shoulder analgesia: a tribute to Dr Darcy Price. *Reg Anesth Pain Med*. 2019;44:759–60.
3. Drake R, Vissa D, Johnson M, et al. Subscapularis plane block - a novel phrenic nerve sparing single injection shoulder block - an anatomical study. *FASEB J*. 2017;31:903–5.
4. Tran J, Peng PWH, Agur AMR. Anatomical study of the innervation of glenohumeral and acromioclavicular joint capsules: implications for image-guided intervention. *Reg Anesth Pain Med*. 2019;44:452–8.
5. Costabeber I, De Almeida GM, Becker M, et al. Brachial plexus cords: a morphological study. *Rev Bras Anesthesiol*. 2010;60:614.