

# 13. acute permyocarditis

*by* Meity Ardiana

---

**Submission date:** 12-Oct-2023 12:02PM (UTC+0800)

**Submission ID:** 2193155599

**File name:** 13.\_acute\_permyocarditis.pdf (4.68M)

**Word count:** 4527

**Character count:** 26085

## Acute Perimyocarditis – an ST-Elevation Myocardial Infarction Mimicker: A Case Report

3

Authors' Contribution:  
Study Design: A  
Data Collection: B  
Statistical Analysis: C  
Data Interpretation: D  
Manuscript Preparation: E  
Literature Search: F  
Funds Collection: G

BEF 1, 2 **Meity Ardiana**  
BDEF 1, 2 **Muhammad Aditya**

5

1 Department of Cardiology and Vascular Medicine, Soetomo General Hospital, Surabaya, Indonesia  
2 Faculty of Medicine, Universitas Airlangga, Surabaya, Indonesia

**Corresponding Author:** Meity Ardiana, e-mail: [meityardiana@fk.unair.ac.id](mailto:meityardiana@fk.unair.ac.id)  
**Financial support:** None declared  
**Conflict of interest:** None declared

19

**Patient:** Male, 40-year-old  
**Final Diagnosis:** Probable acute perimyocarditis  
**Symptoms:** Chest pain • shortness of breath • tachycardia  
**Medication:** —  
**Clinical Procedure:** —  
**Specialty:** Cardiology

**Objective:** Challenging differential diagnosis




**Background:** A normal coronary angiogram in ST-elevation myocardial infarction (STEMI) can be considered a myocardial infarction with non-obstructive coronary arteries (MINOCA) until an alternative diagnosis is obtained. However, the COVID-19 pandemic might delay urgent coronary angiography in a resource-limited setting. Perimyocarditis often causes symptoms, such as chest pain, as well as ST-elevation and high cardiac troponin levels. This STEMI mimicker can also cause cardiogenic shock and death when not treated properly.

**Case Report:** A 40-year-old man reported having acute onset of substernal chest pain, which was suspected to be STEMI. The patient was an active smoker without any risk factors or a history of cardiovascular disease. The examination showed elevated cardiac troponin I, ST-elevation in high lateral leads, and regional wall motion abnormality (RWMA) by echocardiogram. Furthermore, thrombolytic therapy had failed, and rescue percutaneous coronary intervention was not performed due to the catheterization laboratory limitation during the COVID-19 pandemic. Before coronary angiography, the patient was scheduled for 2 consecutive days of COVID-19 polymerase chain reaction (PCR) swabs. On the second day of hospitalization, the patient experienced a cardiogenic shock. The COVID-19 PCR results were negative, while coronary angiography revealed normal coronary arteries. The patient was eventually diagnosed with probable acute perimyocarditis.

**Conclusions:** Myocarditis is implicated in young patients without typical cardiovascular risk factors or in those with recent infection and cardiovascular symptoms mimicking acute coronary syndrome. It might also be present in situations where ST-elevation distribution on the electrocardiogram is discordant with the RWMA observed on the echocardiogram.

**Keywords:** Myocarditis • Shock, Cardiogenic • ST Elevation Myocardial Infarction

**Full-text PDF:** <https://www.amjcaserep.com/abstract/index/idArt/936985>

 2657  —  5  25



## Background

Electrocardiogram (ECG) and troponin levels are modalities commonly used to diagnose acute coronary syndrome (ACS). It is crucial to immediately treat a patient presenting ST-elevation myocardial infarction (STEMI). A normal coronary angiogram in this setting can be considered myocardial infarction with non-obstructive coronary arteries (MINOCA) until an alternative diagnosis is obtained [1].

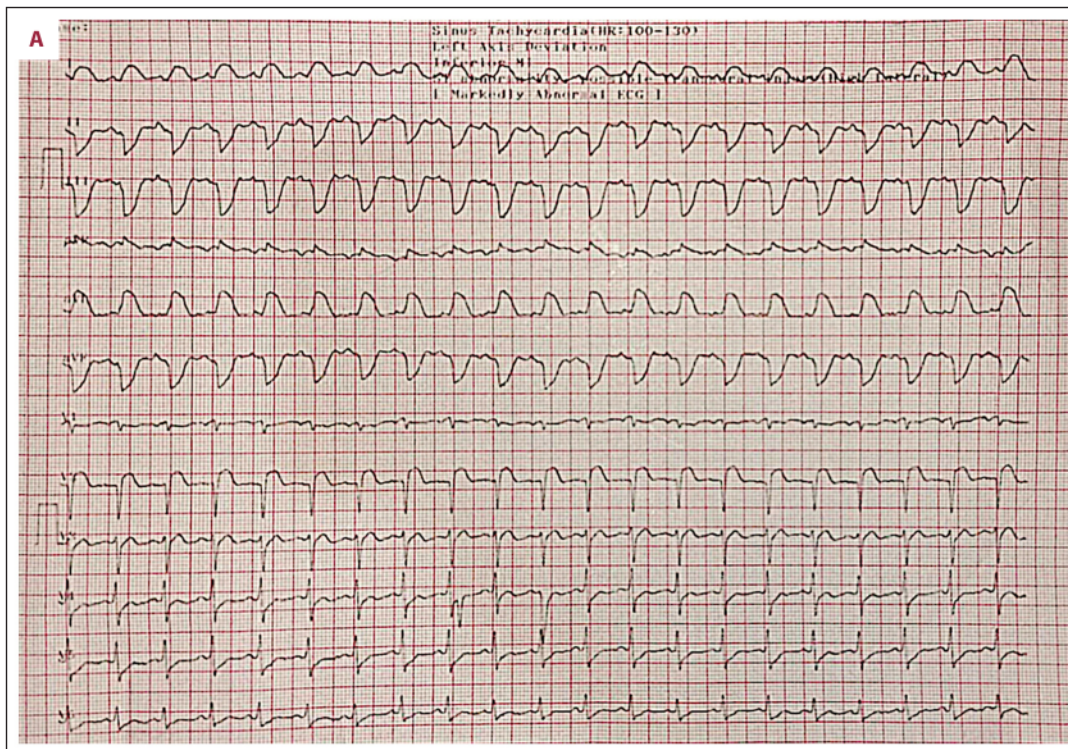
The COVID-19 pandemic might delay urgent coronary angiography in a resource-limited setting. This patient was initially diagnosed with STEMI, then identified as having MINOCA 2 days later. Therefore, the investigation of alternative diagnoses and appropriate treatment was delayed. Perimyocarditis is characterized by chest pain, as well as high cardiac troponin levels and ST-elevation [2,3]. This makes the disease a great STEMI mimicker. Severe acute myocarditis requires quick detection and appropriate management because it can lead to cardiogenic shock and death.

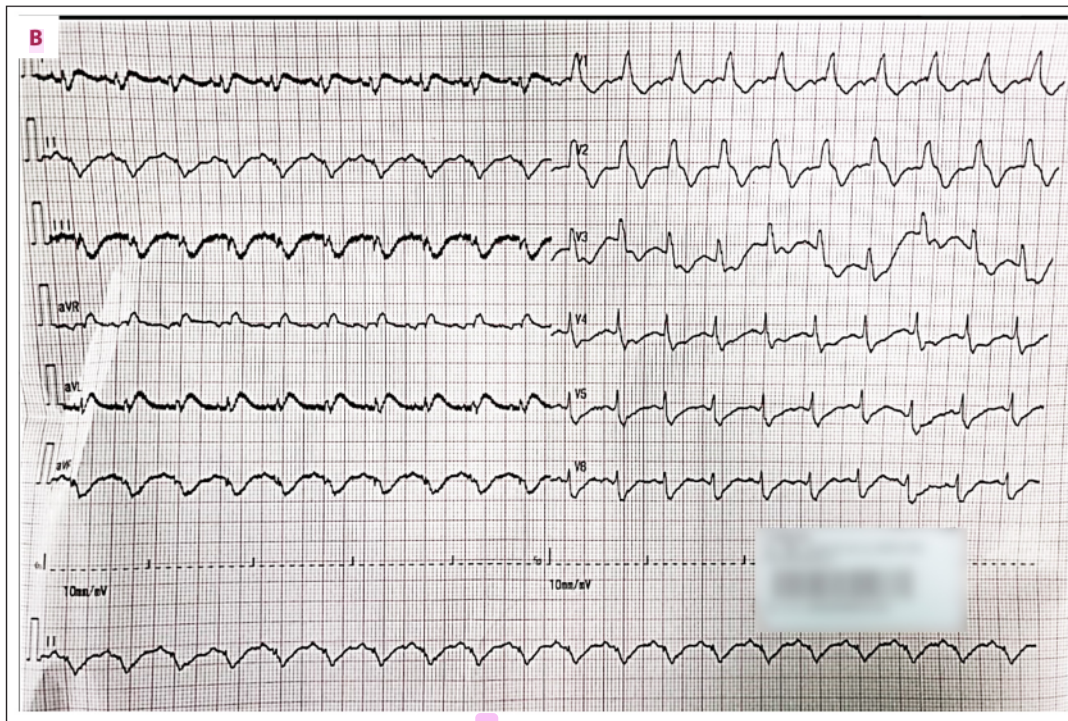
## Case Report

The patient, an Asian 40-year-old man, was referred to the Emergency Department (ED) due to a suspected high lateral

STEMI. There were concerns of substernal chest pain with 6 h of onset, which radiated to the back. The chest pain was not exacerbated by inspiration or coughing, and there was also shortness of breath, nausea, vomiting, and ongoing fever since 3 days ago with no apparent focus of infection. Furthermore, there was no prior medical history of hypertension, diabetes mellitus, heart disease, autoimmune disease, tuberculosis, COVID-19, relevant family comorbidities, or taking any drug. The patient had been smoking for 10 years, 1 pack per day. Also, a loading dose of aspirin 300 mg, clopidogrel 300 mg, as well as isosorbide dinitrate 5 mg sublingual had been administered in the referring hospital.

At presentation, the patient was fully conscious, blood pressure was normal at 118/78 mmHg, with tachycardia of 130 beats/minute, shortness of breath with respiratory rate of 30 breaths/minute, slightly elevated body temperature 37.8°C, and the peripheral oxygen saturation was 98%. The physical examination did not indicate any murmur, gallop, extrasystole, or rubs, the lungs were clear, and the extremities were warm without edema. Moreover, the ECG revealed a sinus rhythm tachycardia of 120 beats/minute with ST-elevation in leads I and aVL and reciprocal ST depression in leads II, III, and aVF (Figure 1A).





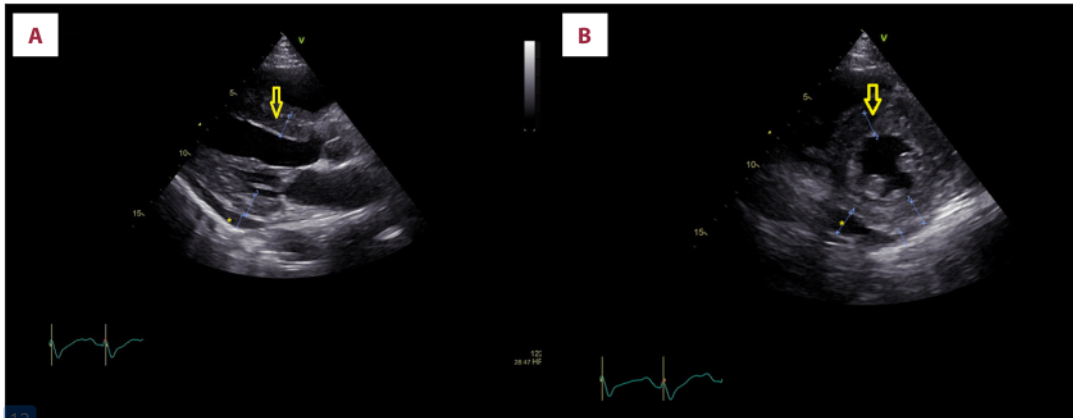
**Figure 1.** (A) Electrocardiography pre-thrombolytic showed ST-elevation in leads I and aVL with reciprocal ST depression in leads II, III, and aVF. (B) Post-thrombolytic ECG showed ST-elevation in leads I and aVL with right bundle branch block pattern.

Thrombolytic treatment was considered because the catheterization laboratory was not operating for emergencies during the COVID-19 pandemic. The treatment was performed using alteplase 15 mg intravenous (i.v.) bolus, followed by 0.75 mg/kg IV in 30 minutes, and 0.5 mg/kg i.v. in 60 min. Subsequently, bilateral basal rales were observed, then the patient was given a 40-mg i.v. bolus of furosemide, the urine output reached 700 cc, and the rales disappeared. Given that the ST-elevation was not resolved, ischemia progressed into the right bundle branch block (RBBB) pattern (Figure 1B). The patient still reported having chest pain without a significant decrease in intensity, indicating that the thrombolytic treatment had failed.

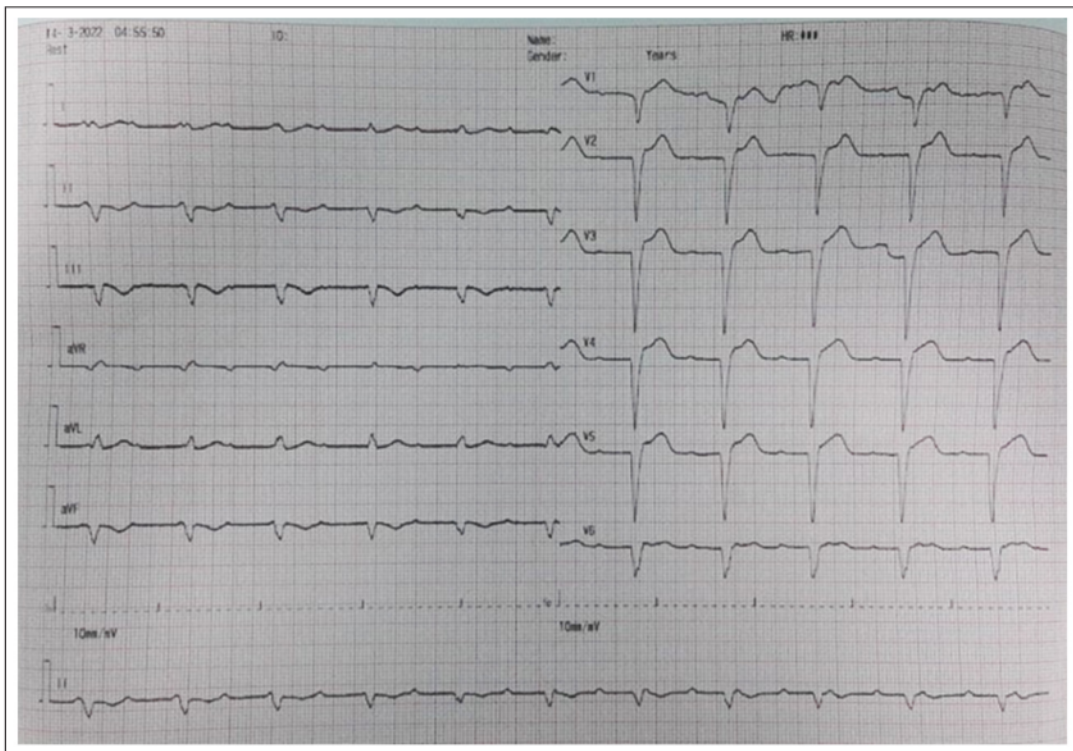
Blood tests were performed when the patient was admitted to the ED before thrombolysis, 6 h after the onset of chest pain. Laboratory results were notable for an elevated white blood cell count  $12.20 \times 10^3/\mu\text{L}$  (reference:  $3.37\text{--}10.0 \times 10^3/\mu\text{L}$ ) and troponin I 31.38 (reference:  $<0.1$  ng/mL), with normal hemoglobin 12.3 g/dL (reference 13.3–16.6 g/dL), platelet  $253 \times 10^3/\mu\text{L}$  (reference:  $150\text{--}450 \times 10^3/\mu\text{L}$ ), and eosinophil count  $0.16 \times 10^3/\mu\text{L}$  (reference:  $<0.5 \times 10^3/\mu\text{L}$ ). Transthoracic echocardiography (TTE) revealed inferoseptal and inferior hypokinesia (base and middle), with a left ventricular (LV) ejection fraction (EF) of 52%. The interventricular septum (IVS) was thickened up to 1.4

cm, with pericardial effusion at the inferior 1.4 cm and posterior 0.8 cm (Figure 2A, 2B), while the chest X-ray was normal. The patient was then given an injection of enoxaparin 30 mg i.v. bolus 15 min later, followed by 1 mg/kg every 12 h subcutaneous, furosemide 20 mg every 24 h i.v. bolus, nitroglycerin pump 10 mcg/minute, oral aspirin 100 mg, atorvastatin 40 mg, bisoprolol 1.25 mg, and ramipril  $1 \times 2.5$  mg once a day, as well as paracetamol 500 mg 3 times a day when necessary. Subsequently, the patient was admitted to the intensive cardiovascular care unit for management of the acute coronary syndrome. Before coronary angiography, the patient was scheduled for 2 consecutive days of COVID-19 polymerase chain reaction (PCR) swabs because the facility did not have a negative-pressure catheterization laboratory.

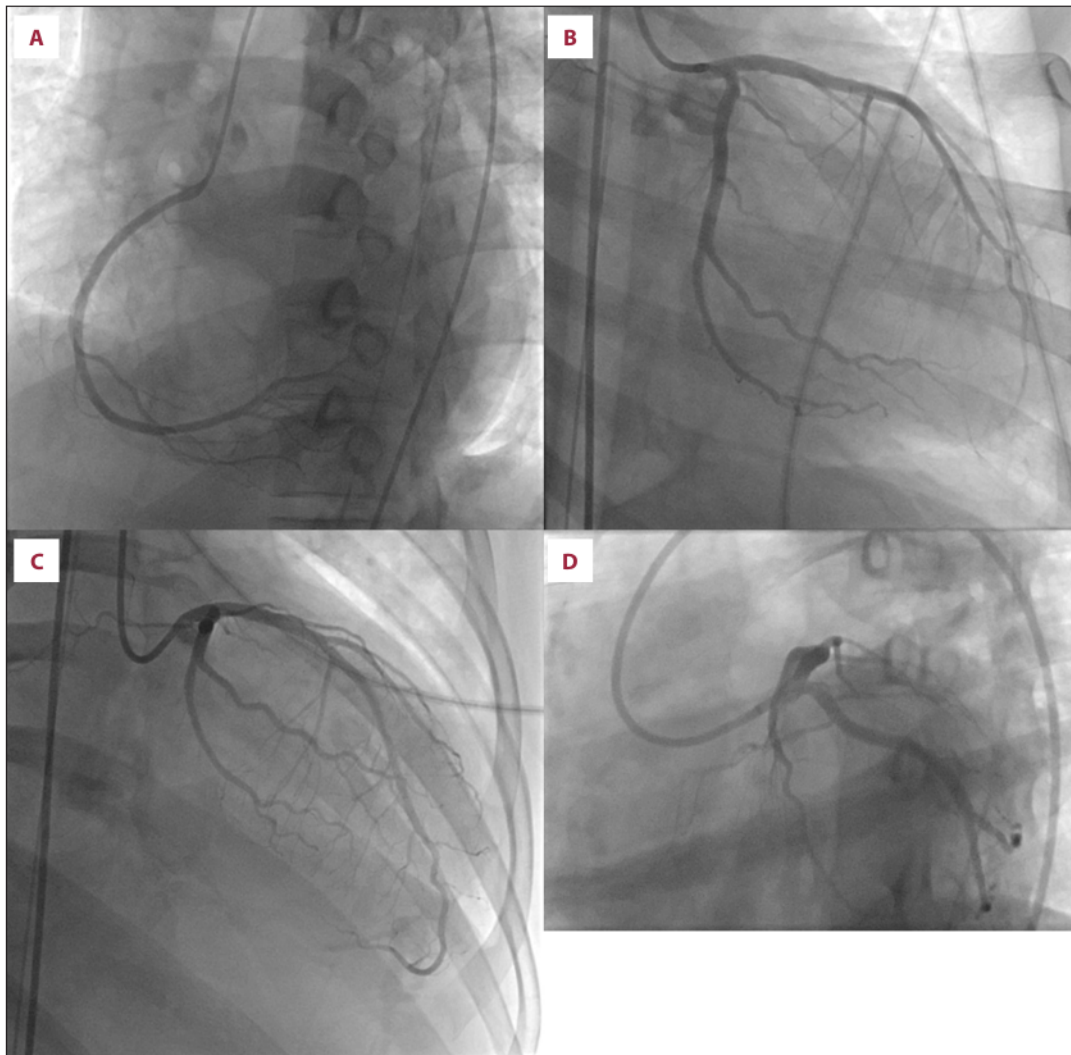
On the second day of hospitalization, the patient experienced shock accompanied by a total atrioventricular (AV) block with ventricular escape rhythm of 66 beats per minute and a resolution of ST-segment elevation (Figure 3). Rapid bedside TTE was performed and found that the regional wall motion abnormality (RWMA) had expanded. Hypokinesia segments were found in the anterior (base, middle, and apical), anteroseptal (base and middle), inferoseptal (base and middle), septal (apical), and inferior (base, middle, and apical). Echo hemodynamic parameters



**Figure 2.** Transthoracic echocardiogram parasternal long axis view at admission showed thickened interventricular septum (arrow) and pericardial effusion at posterior (asterisk) (A). Short axis view showed thickened interventricular septum (arrow) and pericardial effusion at inferior and posterior (asterisk) (B).



**Figure 3.** Electrocardiography on the second day showed total atrioventricular block with a ventricular escape rhythm of 66 beats per minute and a resolution of ST-segment elevation.

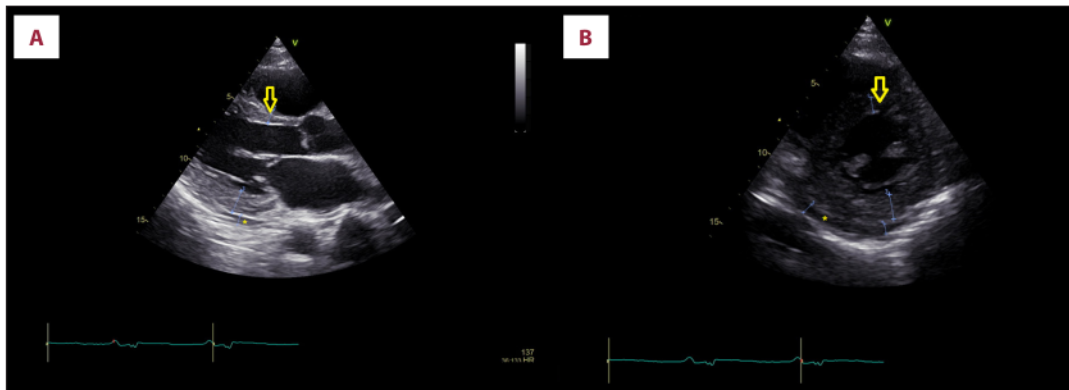


**Figure 4.** Coronary angiography revealed normal coronary artery without obstruction, embolus, or dissection. Normal right coronary artery (A). Normal left circumflex coronary artery (B). Normal left anterior descending coronary artery (C). Normal left main coronary artery (D).

obtained systemic vascular resistance 1723 dynes.sec/cm<sup>5</sup>, cardiac output 2.46 L/min, and cardiac index 1.29 L/minute/m<sup>2</sup>. The patient was given norepinephrine 0.1 mcg/kg/minute and dobutamine 7 mcg/kg/minute. The COVID-19 PCR swab results were negative, and coronary angiography was immediately performed and showed no coronary artery obstruction, signs of embolus, or dissection (Figure 4A-4D). Intravascular ultrasound (IVUS) was not performed due to national health insurance limitations. Optical coherence tomography (OCT) and endomyocardial biopsy (EMB) were also unavailable in the facility. The patient was initially diagnosed with MINOCA

and cardiogenic shock, leading to the placement on an intra-aortic balloon pump (IABP) and a temporary pacemaker. IABP was the only temporary mechanical circulatory support available in the facility.

Due to the facility's limitations, the patient did not undergo a cardiac magnetic resonance imaging (CMRI) examination or a viral panel test. Laboratory evaluations showed hypokalemia with K 3.3 mmol/l, hypocalcemia Ca 7.18 mmol/l, an increase in C-reactive protein 15.91 mg/dL (reference: 0-1 mg/dL), and procalcitonin 0.6 ng/mL (reference <0.05 ng/mL). Furthermore,



**Figure 5.** Pre-discharge transthoracic echocardiogram parasternal long axis view showed interventricular septum thickness returned to normal (arrow) and posterior pericardial effusion reduced (asterisk) (A). Short axis view showed interventricular septum thickness returned to normal (arrow) and inferior pericardial effusion was reduced (asterisk) (B).

20  
the patient was diagnosed with probable acute perimyocarditis and then treated with intravenous antibiotics using ceftriaxone 1 g every 12 h, oral colchicine 0.5 mg 2 times a day, correction of electrolyte disturbances, and discontinuation of antiplatelets, anticoagulant, angiotensin-converting enzyme inhibitor (ACEi), beta-blocker, and statins.

During the treatment, the patient's condition improved as demonstrated by the absence of chest pain or shortness of breath. The ECG no longer showed ST-elevation, RBBB, or AV block. Left ventricular systolic function improved with LV EF 64%, IVS thickness returned to normal at 0.9 cm, and pericardial effusion was reduced, as demonstrated in Figure 5A and 5B. The norepinephrine and dobutamine were then weaned on day 8 of treatment, followed by IABP weaning on the same day. Ramipril 2.5 mg and bisoprolol 1.25 mg once a day were restarted, and the total hospital stay was 11 days. At 3-days post-discharge follow-up, the patient was in good condition, had a blood pressure of 127/74 mmHg, with no concerns. Colchicine therapy 0.5 mg 2 times a day was continued for up to 3 months, while the echocardiogram evaluation 3 months later was normal.

## Discussion

The patient was first suspected of having ACS, with ST-elevation and elevated cardiac troponin I level. ST-elevation on the ECG and chest pain did not improve after thrombolytic therapy, but coronary angiography found no artery obstruction, embolus, or dissection signs. Angiography performed in the acute phase of suspected STEMI was found to be 5-15% of normal [6]. Chest pain in these cases might be due to coronary plaque disruption, cardiac causes other than the coronary artery, or extracardiac [3,6,7]. Alternative diagnoses must be sought when MINOCA is found during coronary angiography. Coronary angiography

might be delayed in the COVID-19 pandemic and in a resource-limited setting, therefore all possible and necessary examinations must be carried out immediately.

Myopericarditis is inflammatory pericarditis and myocardium culminating in myocardial cellular damage [2,8]. This condition is generally evaluated and treated as pericarditis, but when severe/prolonged ventricular dysfunction is found, it is called perimyocarditis [2]. Perimyocarditis must be evaluated and treated as myocarditis [9]. The clinical feature varies depending on the myocardial involvement, thereby making the diagnosis challenging. It can progress into temporary or permanent ventricular dysfunction. Severe ventricular dysfunction can cause hemodynamic disorders due to acute cardiogenic shock [4,5]. Fever, malaise, and myalgia tend to occur in the early stages of the disease [5]. Dyspnea is the most common symptom in adult patients, in addition to chest pain, fatigue, edema, and palpitations [5].

Myocarditis is mainly caused by viral infections rather than bacterial or parasitic infections [8]. The most common type of myocarditis is acute lymphocytic, occurring in approximately 55% of biopsy-proven cases [10]. Non-infectious etiologies include hypersensitivity reactions due to smallpox vaccination (0.01%), autoimmune diseases such as systemic sarcoidosis (2-5%), systemic lupus erythematosus (9%), and cardiotoxin substances such as immune-check inhibitor for cancer therapy (1.14%) [5,10].

Myocarditis can cause ST-elevation on ECG; the more specific ECG changes for myocarditis include localized ST-elevation in inferolateral and anterolateral leads with concordant reciprocal depression, convex ST-segment, new Q wave, and prolonged QT interval [2]. A study showed that patients with acute myocarditis might also have AV block [11].

Furthermore, myocarditis can be suspected in young patients without typical cardiovascular risk factors or those with symptoms or signs of recent infection mimicking acute coronary syndrome [9]. This also applies to situations where the distribution of ST-segment elevation on ECG is discordant with the wall motion abnormalities observed on the echocardiogram, as demonstrated in the present patient. The ST-elevation in the high lateral leads was discordant with hypokinesia at inferior and inferolateral segments on the initial echocardiogram.

Elevated cardiac troponin is common in myocarditis, especially in acute setting [5,12]. However, cardiac troponin levels are of no prognostic benefit, although they might increase similarly to acute myocardial infarction conditions [5]. Serial cardiac troponin examination often shows the biphasic rapid rise and fall patterns on acute myocardial infarction. Persistent monophasic troponinemia can be seen in myocarditis for 24-48 h before it falls [13]. This can help differentiate myocarditis from ACS when angiography cannot be performed immediately. C-reactive protein is also elevated in most adult patients but is not associated with a poorer prognosis [5].

Echocardiography is essential in a patient suspected to have myocarditis because it can reveal RWMA and chamber dilatation [9,14]. Systolic dysfunction is more often diffuse than regional or segmental [5,9]. Left ventricle ejection fraction might be normal or mildly reduced in the early stages of the disease [5], while pericardial effusion is found in about one-quarter of cases [5]. Echocardiographic features of fulminant myocarditis include myocardial edema, normal LV diastolic dimensions, and pericardial effusion [9]. In this present patient, apart from the discordant RWMA to the distribution of ST-segment elevation, pericardial effusion and thickened IVS were also found. This thickened IVS might be have been due to myocardial edema because it decreased to normal with treatment on serial inpatient echocardiograms.

The definitive diagnosis of myocarditis involves an EMB [15], but this method is invasive and less sensitive. False-negative results can be obtained when a biopsy is taken in an uninvolved region due to the characteristic patchy inflammation [16]. Stage of presentation, tissue quality, and interobserver variability also affect the result [12]. The present patient was diagnosed with probable acute perimyocarditis because there was a dominant disorder of the myocardium with pericardial involvement without EMB for histological/immune-histological evidence of myocarditis. In addition, the patient had a fever for 3 days, indicating an infection process. Cardiac troponin was elevated but serial troponin examinations were not carried out. The ST-segment elevation distribution on surface ECG was discordant with the RWMA on the initial echocardiogram, while the IVS thickness increased, presumably due to myocardial edema. On the second day, the ECG developed into total

AV block, the RWMA expanded, and LV dysfunction worsened on serial echocardiograms, accompanied by progressive hemodynamic deterioration, with a normal coronary angiogram.

The use of rate control agents, as well as negative inotropics such as verapamil, diltiazem, or metoprolol, to treat compensatory sinus tachycardia must be avoided [9]. Cardiac output can depend on increased heart rate in patients with systolic dysfunction. Furthermore, non-steroidal anti-inflammatory drugs (NSAIDs) need to be avoided because they can cause myocardial damage and sodium retention, exacerbate renal hypoperfusion, and increase the risk of mortality [2,5,9]. The use of NSAIDs on humans with myocarditis still lacks supporting evidence. Animal studies show they aggravate myocardial inflammation and necrosis, elevate viral titers, and reduce interferon [2,17]. About 50% patients made a full recovery, some developed heart failure (30%), and about 20% required heart transplantation [5].

Fulminant myocarditis is characterized by severe acute cardiac inflammation [9]; it can cause a rapid deterioration within 2-3 days, often leading to death due to cardiogenic shock, arrhythmias, or multiorgan failure [9,18]. Stabilizing myocarditis patients with cardiogenic shock requires hemodynamic support to maintain adequate tissue perfusion [9]. Temporary mechanical circulatory support devices, such as IABP, peripheral/implantable ventricular assist device, or extracorporeal life support, can be used to achieve adequate stabilization. Norepinephrine is less arrhythmic and improves survival in acute myocardial infarction with shock better than dopamine. However, it is unclear whether this can be generalized to patients with myocarditis [7]. Arrhythmias are common in myocarditis with cardiogenic shock, including atrial/ventricular tachyarrhythmia, bradyarrhythmia, or heart block [9]. A temporary pacemaker might be needed in bradyarrhythmia with unstable hemodynamic conditions. Survival rates have been reported to range from 50% to 70% [19].

Colchicine has been shown to improve cardiac outcomes in inflammatory cardiac disorders, including pericarditis, through its antifibrotic and endothelial-protective features [4]. The European Society of Cardiology recommends using colchicine as first-line therapy for various forms of pericarditis [20]. Colchicine therapy is beneficial because the inflammatory mechanisms of pericarditis and myocarditis are similar. Al-Zahari et al reported 2 cases of myocarditis with improvement in clinical symptoms after the administration of colchicine [2]. Morgenstern et al added that the complete resolution of myocarditis based on the CMRI study was more common in myocarditis patients who received colchicine than in those who did not, with values of 63% vs 38% [21]. In addition, Gultekin and Cucu Kates reported that low-dose colchicine combined with conventional heart failure therapy improved LV EF in 5 myocarditis patients [22].



The present patient completed the intravenous antibiotic course and was given colchicine combined with ACEi and beta-blocker. ECG evaluation before discharge showed no ST-segment changes. The patient also had a repeat echocardiogram that showed improved LV EF, no RWMA, and IVS thickness returned to normal.

The present case report has several limitations. First, a CMRI examination was not performed due to the limited facilities. The patient also refused to undergo CMRI outside the facility due to the considerable expenses. CMRI is the primary modality in the MINOCA algorithm to differentiate the diagnoses of Takotsubo syndrome, myocarditis, or true myocardial infarction [7]. Furthermore, blood culture was not conducted because this study focused on acute myocardial infarction and did not consider sepsis shock due to findings on echocardiography specific to cardiogenic shock, including severe left ventricular systolic dysfunction, decreased stroke volume, elevated filling pressure, and systemic vascular resistance [23-25]. The viral panel test for serological/virological testing and EMB for histological diagnosis of myocarditis was not carried out due to the facility's limitations. Intravascular imaging IVUS was not conducted due to national health insurance limitations, while OCT was unavailable.

## References:

1. Collet JP, Thiele H, Barbato E, et al. 2020 ESC Guidelines for the management of acute coronary syndromes in patients presenting without persistent ST-segment elevation. *Eur Heart J*. 2021;42:1289-367
2. Al-Zakhari R, Upadhyya G, Galligan S, Shehaj F. The myth of colchicine in treating myopericarditis: Case report and literature review. *Cureus*. 2020;12(6):e8933
3. Sethi P, Murtaza G, Sharma A, et al. ST segment elevation with normal coronaries. *Case Rep Med*. 2016;2016:3132654
4. Tschöpe C, Cooper LT, Torre-Amione G, et al. Management of myocarditis-related cardiomyopathy in adults. *Circ Res*. 2019;124:1568-83
5. Gottlieb M, Bridwell R, Petrak V, et al. Diagnosis and management of myocarditis: An evidence-based review for the emergency medicine clinician. *J Emerg Med*. 2021;61:222-33
6. Tamis-Holland JE, Jneid H, Reynolds HR, et al. Contemporary diagnosis and management of patients with myocardial infarction in the absence of obstructive coronary artery disease: A scientific statement from the American Heart Association. *Circulation*. 2019;139:E891-908
7. Ibanez B, James S, Agewall S, et al. 2017 ESC Guidelines for the management of acute myocardial infarction in patients presenting with ST-segment elevation. *Eur Heart J*. 2018;39:119-77
8. Omar HR, Fathy A, Rashad R, et al. Acute perimyocarditis mimicking transmural myocardial infarction. *Int Arch Med*. 2009;2:1-5
9. Kociol RD, Cooper LT, Fang JC, et al. Recognition and initial management of fulminant myocarditis: A scientific statement from the American Heart Association. *Circulation*. 2020;141(6):E69-92
10. Golpour A, Patriki D, Hanson PJ, et al. Epidemiological impact of myocarditis. *J Clin Med*. 2021;10:1-15
11. Ammirati E, Cipriani M, Moro C, et al. Clinical presentation and outcome in a contemporary cohort of patients with acute myocarditis; Multicenter Lombardy registry. *Circulation*. 2018;138:1088-99

## Conclusions

The diverse clinical features of myocarditis make the diagnosis of this disease challenging. The COVID-19 pandemic and resource-limited settings can delay urgent coronary angiography. Therefore, myocarditis can be suspected in young patients without typical cardiovascular risk factors or those with symptoms or signs of recent infection mimicking acute coronary syndrome. This also applies to situations where the distribution of ST-elevation on surface ECG is discordant with the wall motion abnormalities observed on the echocardiogram. Therefore, it is very important to clarify the diagnosis of STEMI before administering a thrombolytic agent. Myocarditis in severe acute inflammation can cause cardiogenic shock and even death; therefore, it requires rapid detection and appropriate management.

## Department and Institution Where Work Was Done

Department of Cardiology and Vascular Medicine, Soetomo General Hospital, Surabaya, Indonesia.

## Declaration of Figures' Authenticity

All figures submitted have been created by the authors who confirm that the images are original with no duplication and have not been previously published in whole or in part.

12. Fung G, Luo H, Qiu Y, et al. Myocarditis. *Circ Res*. 2016;118:496-514
13. Sedaghat-Hamedani F, Katus HA, Meder B. Cardiac biomarker changes after endurance sports. American College of Cardiology Foundation. <https://www.acc.org/latest-in-cardiology/articles/2016/04/14/09/58/cardiac-biomarker-changes-after-endurance-sports> [accessed 7 July 2022]
14. Uziębło-Życzkowska B, Mielniczuk M, Ryzek R, et al. Myocarditis successfully diagnosed and controlled with speckle tracking echocardiography. *Cardiovasc Ultrasound*. 2020;18:19
15. Sagar S, Liu P, Cooper L. Myocarditis. *Lancet*. 2012;379:738-47
16. Zhang T, Miao W, Wang S, et al. Acute myocarditis mimicking ST-elevation myocardial infarction: A case report and review of the literature. *Exp Ther Med*. 2015;10:459-64
17. Mirna M, Schmutzler L, Topf A, et al. Treatment with non-steroidal anti-inflammatory drugs (NSAIDs) does not affect outcome in patients with acute myocarditis or myopericarditis. *J Cardiovasc Dev Dis*. 2022;9(2):32
18. Hang W, Chen C, Seubert JM, et al. Fulminant myocarditis: A comprehensive review from etiology to treatments and outcomes. *Signal Transduct Target Ther*. 2020;5:287
19. Nakamura T, Ishida K, Taniguchi Y, et al. Prognosis of patients with fulminant myocarditis managed by peripheral venoarterial extracorporeal membranous oxygenation support: A retrospective single-center study. *J Intensive Care*. 2015;3:5
20. Adler Y, Charron P, Imazio M, et al. 2015 ESC Guidelines for the diagnosis and management of pericardial diseases. *Eur Heart J*. 2015;36:2921-64
21. Morgenstern D, Lisko J, Boniface NC, et al. Myocarditis and colchicine: A new perspective from cardiac MRI. *J Cardiovasc Magn Reson*. 2016;18:1-2
22. Gultekin N, Kucukates E. Microtubule inhibition therapy by colchicine in severe myocarditis especially caused by Epstein-Barr and cytomegalovirus co-infection during a two-year period: A novel therapeutic approach. *J Pak Med Assoc*. 2014;64:1420-23

23. Ishmael L, Zalocha J. ST-elevation myocardial infarction in the presence of septic shock. *Case Reports Crit Care*. 2020;2020:8879878
24. Simmons J, Ventetuolo CE. Cardiopulmonary monitoring of shock. *Curr Opin Crit Care*. 2017;23:223-31
25. Kim S, Lee JD, Kim BK, et al. Association between left ventricular systolic dysfunction and mortality in patients with septic shock. *J Korean Med Sci*. 2020;35:e24

# 13. acute permyocarditis

---

## ORIGINALITY REPORT

---

12%

SIMILARITY INDEX

9%

INTERNET SOURCES

7%

PUBLICATIONS

3%

STUDENT PAPERS

---

## PRIMARY SOURCES

---

1	<a href="http://hqmeded-ecg.blogspot.com">hqmeded-ecg.blogspot.com</a> Internet Source	1%
2	<a href="http://assets.cureus.com">assets.cureus.com</a> Internet Source	1%
3	Submitted to Maryville University Student Paper	1%
4	<a href="http://www.hindawi.com">www.hindawi.com</a> Internet Source	1%
5	<a href="http://www.biorxiv.org">www.biorxiv.org</a> Internet Source	1%
6	Carsten Tschöpe, Leslie T. Cooper, Guillermo Torre-Amione, Sophie Van Linthout. "Management of Myocarditis-Related Cardiomyopathy in Adults", Circulation Research, 2019 Publication	1%
7	Submitted to Massachusetts College of Pharmacy & Allied Health Sciences Student Paper	<1%

---

8	<a href="http://file.tkd.org.tr">file.tkd.org.tr</a> Internet Source	<1 %
9	<a href="http://www.nps.org.au">www.nps.org.au</a> Internet Source	<1 %
10	Beate Roxane Jaeger. "The HELP System for the Treatment of Atherothrombotic Disorders: A Review", Therapeutic Apheresis and Dialysis, 8/2003 Publication	<1 %
11	Rana Al-Zakhari, Gautham Upadhya, Sean Galligan, Fiona Shehaj. "The Myth of Colchicine in Treating Myopericarditis: Case Report and Literature Review", Cureus, 2020 Publication	<1 %
12	<a href="http://www.longdom.org">www.longdom.org</a> Internet Source	<1 %
13	<a href="http://surgicalcasereports.springeropen.com">surgicalcasereports.springeropen.com</a> Internet Source	<1 %
14	<a href="http://www.jucm.com">www.jucm.com</a> Internet Source	<1 %
15	<a href="http://www.mdedge.com">www.mdedge.com</a> Internet Source	<1 %
16	<a href="http://archive.org">archive.org</a> Internet Source	<1 %
17	<a href="http://assets.radcliffecardiology.com">assets.radcliffecardiology.com</a> Internet Source	<1 %

<1 %

18

[ndl.ethernet.edu.et](http://ndl.ethernet.edu.et)

Internet Source

<1 %

19

[www.science.gov](http://www.science.gov)

Internet Source

<1 %

20

James Jiqi Wang, Bo Yu, Xiuli Song, Hong Wang. "De novo LAMP2 insertion mutation causes cardiac-only Danon disease: A case report", *Frontiers in Cardiovascular Medicine*, 2022

Publication

<1 %

21

[digitalcommons.library.tmc.edu](http://digitalcommons.library.tmc.edu)

Internet Source

<1 %

22

[journal.nzma.org.nz](http://journal.nzma.org.nz)

Internet Source

<1 %

23

[onlinelibrary.wiley.com](http://onlinelibrary.wiley.com)

Internet Source

<1 %

24

[www.selcardiacnetwork.nhs.uk](http://www.selcardiacnetwork.nhs.uk)

Internet Source

<1 %

25

[www.unboundmedicine.com](http://www.unboundmedicine.com)

Internet Source

<1 %

26

Eugene Sharma Henry. "Fatal lymphocytic myocarditis masquerading as thoracic aortic

<1 %

dissection", Case Reports in Acute Medicine,  
2021

Publication

---

27

Pediatric and Congenital Cardiology Cardiac  
Surgery and Intensive Care, 2014.

Publication

---

28

Timothy D. Bryson, Pamela Harding.  
"Prostaglandin E2 and myocarditis; friend or  
foe?", Biochemical Pharmacology, 2023

Publication

---

29

[academic.oup.com](https://academic.oup.com)

Internet Source

---

30

[d197for5662m48.cloudfront.net](https://d197for5662m48.cloudfront.net)

Internet Source

---

31

[www.semanticscholar.org](https://www.semanticscholar.org)

Internet Source

---

32

Athanasios Samaras, Dimitrios V. Moysidis,  
Andreas S. Papazoglou, Georgios Rampidis et  
al. "Diagnostic Puzzles and Cause-Targeted  
Treatment Strategies in Myocardial Infarction  
with Non-Obstructive Coronary Arteries: An  
Updated Review", Journal of Clinical Medicine,  
2023

Publication

---

33

"Full Issue PDF", JACC: Cardiovascular  
Imaging, 2021

Publication

---

<1 %

<1 %

<1 %

<1 %

<1 %

<1 %

<1 %

---

Exclude quotes Off

Exclude matches Off

Exclude bibliography On

# 13. acute permyocarditis

---

## GRADEMARK REPORT

---

FINAL GRADE

GENERAL COMMENTS

**/100**

---

PAGE 1

---

PAGE 2

---

PAGE 3

---

PAGE 4

---

PAGE 5

---

PAGE 6

---

PAGE 7

---

PAGE 8

---

PAGE 9

---