

Prediction of histopathological grades of liver pathology in cholestasis by direct bilirubin, aspartate aminotransferase, alanine aminotransferase and albumin level

by Bagus Setyoboedi

Submission date: 25-Oct-2023 06:47AM (UTC+0800)

Submission ID: 2206250521

File name: Prediction_of_histopathological_grades.pdf (257.57K)

Word count: 2825

Character count: 15905

Prediction of histopathological grades of liver pathology in cholestasis by direct bilirubin, aspartate aminotransferase, alanine aminotransferase and albumin level

*Bagus Setyoboedi¹, Sugi Deny Pranoto Soegianto², Sjamsul Arief¹

Sri Lanka Journal of Child Health, 2023; 52(2): 142-147
DOI: <https://doi.org/10.4038/sljch.v52i2.10546>

Abstract

Background: Liver biopsy, a routine diagnostic procedure in Dr. Soetomo General Hospital Surabaya, is a valuable tool in the diagnosis, prognosis, and management of parenchymal liver disease. However, the correlation between histopathological features and direct bilirubin, aspartate transaminase (AST), alanine transaminase (ALT) and albumin level has not yet been established.

Objectives: To correlate various histopathological features with direct bilirubin, AST, ALT and albumin level of children with cholestasis.

Method: This is a retrospective study of 51 cases of cholestasis diagnosed and treated from January 2011 to December 2016. All biopsies were reviewed and graded by a semi-quantitative scoring system according to Muthukanagarajan *et al* and categorized into fibrosis, bile duct proliferation, cholestasis and duct plate malformation. Degrees of all features were compared with direct bilirubin, AST, ALT, and albumin level. Statistical analysis used one way ANOVA, Kruskal-Wallis and unpaired t-test. $p < 0.05$ was considered significant.

Results: There were 30 males and 21 females with a median age of 3 (1-9) months and a mean weight of 5 (1.41) kg. Degree of fibrosis was negative (47%),

¹Department of Child Health, Faculty of Medicine, Universitas Airlangga / Dr. Soetomo General Hospital, Surabaya, Indonesia, ²Department of Clinical Medicine, Faculty of Medicine and Veterinary Medicine, Universitas Nusa Cendana, Kupang, Indonesia

*Correspondence: bagus.setyoboedi@fk.unair.ac.id

<https://orcid.org/0000-0002-3923-6913>

(Received on 12 October 2022; Accepted after revision on 22 November 2022)

The authors declare that there are no conflicts of interest

Personal funding was used for the project.

Open Access Article published under the Creative

Commons Attribution CC-BY License

mild (22%), moderate (31%) and severe (0%). Bile duct proliferation was negative (57%), mild (21%), moderate (14%) and severe (8%). Cholestasis was negative in 0%, mild in 14%, moderate in 69% and severe in 18%; duct plate malformation was negative in 63% and positive in 37%. Direct bilirubin level showed significant difference with degree of duct proliferation ($p=0.024$). There was no significant difference of AST level with all degrees of histopathological grade. ALT level showed significant difference with degree of fibrosis ($p=0.043$). Albumin level showed significant difference with degree of fibrosis ($p=0.000$), degree of duct proliferation ($p=0.006$) and duct plate malformation ($p=0.037$).

Conclusions: This study showed that while the direct bilirubin level was significantly associated with the degree of duct proliferation and the ALT level was significantly associated with the degree of fibrosis, the albumin level was significantly associated with the degree of fibrosis, degree of duct proliferation and degree of duct plate malformation

(Key words: Histopathology, Cholestasis, Bilirubin, Albumin, Transaminase)

Introduction

Liver biopsy is still the standard procedure for obtaining liver tissue for histopathological examination and a valuable tool in the diagnosis, prognosis and management of many parenchymal liver diseases¹. Liver biopsy is the cornerstone of the diagnostic work-up of infants with cholestatic jaundice, and it is standard practice in most paediatric centres to obtain a percutaneous liver biopsy before surgical intervention². The role of liver biopsy has also evolved into a prognostic tool in a variety of liver diseases, providing information such as histologic grades of inflammation and staging of fibrosis. Histologic assessment of the liver remains an essential tool in establishing the diagnosis in numerous paediatric diseases, in combination with various clinical and laboratory data³. However, correlation between histopathological features and direct bilirubin, aspartate transaminase (AST), alanine transaminase (ALT) and albumin level have not yet been established.

Objectives

To correlate various histopathological features with direct bilirubin, AST, ALT, and albumin level of children with cholestasis.

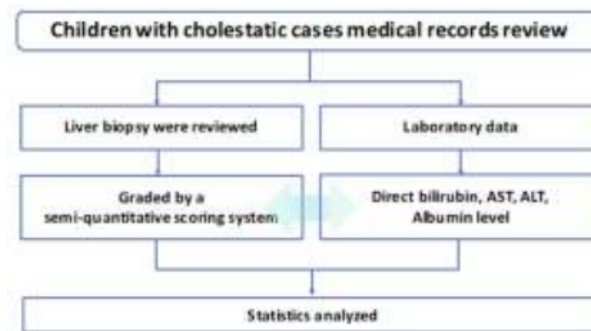
Method

Design: A retrospective study was carried out from medical records in the Hepatology Outpatient Clinic, Dr. Soetomo Hospital from 1st January 2011 to 31st December 2016.

Inclusion criteria: Infants with clinical sign of cholestasis (jaundice, pale stools, abdominal

distension and dark urine) and direct bilirubin >1 mg/dl, who were suspected of biliary atresia, neonatal hepatitis, Alagille Syndrome, α -1 antitrypsin deficiency, progressive familial intrahepatic cholestasis or secondary cholestasis due to other causes and who underwent percutaneous liver biopsy, were enrolled in this study.

Exclusion criteria: Infants with incomplete laboratory data and biopsy results were excluded from the study.



Study protocol

Liver biopsy review and grading: All liver biopsy results were reviewed by the pathologist who examined them previously and graded using the semi-quantitative scoring system of Muthukanagarajan SJ *et al*⁴.

The scoring system for grading the extent of fibrosis includes:

- Grade I (mild) fibrosis comprised cases with portal fibrous expansion to porto-portal bridging fibrosis involving 50% or less of portal tracts.
- Grade II (moderate) fibrosis included cases with porto-portal bridging fibrosis involving greater than 50% of portal tracts without nodular hepatic architecture.
- Grade III (severe) fibrosis included cases with porto-portal and porto-central bridging fibrosis involving greater than 50% of portal tracts associated with nodular hepatic architecture.

Bile duct proliferation refers to the presence of greater than 5 bile ducts per portal tract and was graded according to a semi-quantitative scoring system.

- Presence of 5 to 9 bile ducts per portal tract was graded as mild.
- Greater than or equal to 10 bile ducts per portal tract was graded as moderate.

- An average number of bile ducts per portal tract greater than or equal to 10 but the ducts were elongated attenuated and angulated was graded as severe bile duct proliferation.

Portal and periportal inflammation was graded as:

- Mild if cells were present in less than one third of portal tracts.
- Moderate if cells were present in more than one third to two-thirds of portal tracts.
- Severe when dense packing of cells was present in more than two-thirds of portal tracts.

Cholestasis was graded as:

- Absent.
- Mild (accumulation of bile in centrilobular hepatocytes).
- Moderate (accumulation of bile in centrilobular and periportal hepatocytes or even in portal tracts).
- Severe (showed presence of bile infarcts).

Duct plate malformation was identified by the presence of numerous unusual curved and concentric bile ducts arranged around a fibrous or a central vascular core in the portal tract. Histopathological examination of the biliary remnant showed fibro-inflammatory obliteration of the duct, apoptotic degeneration of the residual bile

duct epithelium and variable degrees of periductal inflammation⁴.

Ethical issues: Study protocol was approved by the Institutional Ethics Committee of Dr. Soetomo General Hospital, Surabaya, Indonesia (No. 259 / Panke.KKE / IV / 2017) on 06 April, 2017. Being a retrospective study, informed written consent was not feasible.

Statistical analysis: This was performed with SPSS, version 20 (SPSS Inc, Chicago, Illinois, USA). One way ANOVA, Kruskal-Wallis and unpaired t-test were used to compare the variables and a value of $p < 0.05$ was considered significant.

Results

There were 30 males and 21 females with a median age of 3 (1-9) months and a mean weight of 5 (1.41) kg. The follow up of all samples showed that 8 infants died and 4 infants underwent the Kasai procedure.

Degree of fibrosis was 47% negative, 31% moderate and 0% severe. Bile duct proliferation was 57% negative, 21% mild, 14% moderate and 8% severe; Cholestasis was 0% negative, 14% mild, 69% moderate and 18% severe. Duct plate malformation was 63% negative and 37% positive. (Figure 1).

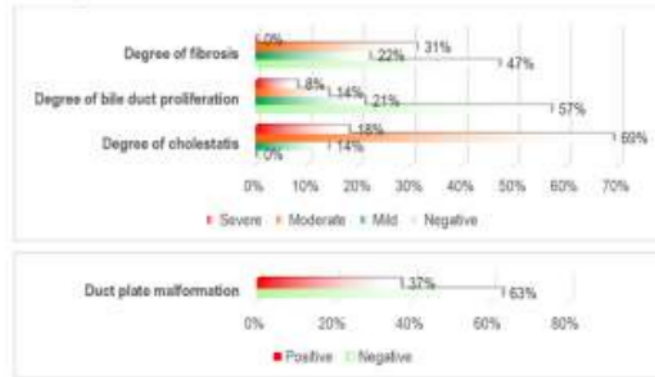


Figure 1: Distribution of clinicopathological features

Direct bilirubin level showed a significant difference with degree of duct proliferation ($p=0.024$). There was no significant difference of AST level with all degrees of histopathological grades. ALT level showed significant difference

with degree of fibrosis ($p=0.043$). Albumin level showed significant difference with degree of fibrosis ($p=0.000$), degree of duct proliferation ($p=0.006$) and duct plate malformation ($p=0.037$). (Tables 1-4)

Table 1: Comparison of histopathological features with direct bilirubin

Histopathological feature	Direct bilirubin (mg/dl)	p-value
<i>Degree of fibrosis: Mean (SD)</i>		
Negative	7.66 (5.07)	0.336 ¹
Mild	7.48 (3.28)	
Moderate	9.79 (5.40)	
Severe	-	
<i>Degree of bile duct proliferation: Median (min-max)</i>		
Negative	7.01 (1.5-23.87)	0.024 ²
Mild	6.99 (2.40-14.01)	
Moderate	10.97 (10.71-25.02)	
Severe	6.5 (2.48-11.70)	
<i>Degree of cholestasis: Mean (SD)</i>		
Negative	-	0.327 ¹
Mild	8.64 (3.49)	
Moderate	7.67 (4.72)	
Severe	10.40 (6.17)	
<i>Duct plate malformation: Mean (SD)</i>		
Negative	8.11 (4.39)	0.754 ³
Positive	8.59 (5.71)	

$p < 0.05$ significant; one way ANOVA test¹, Kruskal Wallis test², Unpaired t-test³

Table 2: Comparison of histopathological features with aspartate transaminase

Histopathological feature	Aspartate transaminase (mg/dl)	p-value
<i>Degree of fibrosis: Median (min-max)</i>		
Negative	190.00 (21.00-1517.00)	0.514 ¹
Mild	246.00 (113.00-738.00)	
Moderate	228.00 (122.00- 499.00)	
Severe	-	
<i>Degree of bile duct proliferation: Median (min-max)</i>		
Negative	207.00 (21.00-1517.00)	0.728 ¹
Mild	221.00 (122.00- 499.00)	
Moderate	272.00 (167.00-444.00)	
Severe	260.25 (184.00-446.00)	
<i>Degree of cholestasis: Median (min-max)</i>		
Negative	-	0.542 ¹
Mild	242.00 (113.00-760.00)	
Moderate	207.00 (21.00-1517.00)	
Severe	311.00 (169.70-446.00)	
<i>Duct plate malformation: Mean (SD)</i>		
Negative	266.18 (182.30)	0.316 ²
Positive	345.97 (309.96)	

p<0.05 significant; Kruskal Wallis test¹, Unpaired t-test²

Table 3: Comparison of histopathological features with alanine transaminase

Histopathological feature	Alanine transaminase (mg/dl)	p-value
<i>Degree of fibrosis: Mean (SD)</i>		
Negative	206.58 (143.87)	0.043 ¹
Mild	211.90 (124.63)	
Moderate	198.63 (59.48)	
Severe	-	
<i>Degree of bile duct proliferation: Median (min-max)</i>		
Negative	165.0 (11.0-624.0)	0.57 ²
Mild	193.0 (89.0-314.0)	
Moderate	206.0 (110.0-338.0)	
Severe	225.5 (158.1-264.0)	
<i>Degree of cholestasis: Mean (SD)</i>		
Negative	-	0.965 ¹
Mild	201.86 (114.03)	
Moderate	203.43 (127.34)	
Severe	214.88 (83.19)	
<i>Duct plate malformation: Mean (SD)</i>		
Negative	206.62 (136.97)	0.901 ³
Positive	202.90 (76.00)	

p<0.05 significant; one way ANOVA test¹, Mann-Whitney test², Unpaired t-test³

Table 4: Comparison of histopathological features with albumin

Histopathological feature	Albumin (mg/dl)	p-value
<i>Degree of fibrosis: Median (min-max)</i>		
Negative	3.83 (2.70-6.20)	0.001 ¹
Mild	3.80 (3.00-4.37)	
Moderate	2.95 (2.24-3.90)	
Severe	-	
<i>Degree of bile duct proliferation: Median (min-max)</i>		
Negative	3.82 (2.70-6.20)	0.006 ¹
Mild	3.40 (2.70-4.37)	
Moderate	3.40 (2.24-3.90)	
Severe	2.73 (2.60-3.40)	
<i>Degree of cholestasis: Median (min-max)</i>		
Negative	-	0.175 ¹
Mild	3.70 (2.70-4.56)	
Moderate	3.70 (2.70-6.20)	
Severe	3.40 (2.24-4.00)	
<i>Duct plate malformation: Median (min-max)</i>		
Negative	3.75 (2.70-6.20)	0.037 ²
Positive	3.40 (2.24-5.10)	

p<0.05 significant; Kruskal Wallis test¹, Mann-Whitney test²

Discussion

Traditional serological markers of liver function viz. 'liver function tests' give little indication of the various underlying pathological processes, including fibrosis⁵. The present method of subjective assessment of liver fibrosis and architecture by a single pathologist is reasonable in the daily diagnostic situation, but application of grading and staging scoring systems is inappropriate routinely. Histopathological stage scoring is sufficient for many clinical trials, and is the correct approach for observational studies⁵.

The serum bilirubin levels showed statistically significant differences in early and advanced stages of liver damage⁶. Conjugated hyperbilirubinaemia characteristically occurs in parenchymal liver disease and biliary obstruction⁷. In our study, the direct bilirubin level showed a significant difference with the degree of duct proliferation ($p=0.024$). Hyperbilirubinaemia is directly proportional to the degree of histological injury of hepatocytes⁸. The presence of conjugated hyperbilirubinaemia almost always signifies the existence of liver disease. Both hepatocellular and cholestatic liver injury may lead to elevated serum bilirubin levels⁹.

We found there was no significant difference of AST level with all degrees of histopathological grade. AST is present in a wide variety of tissues like the heart, skeletal muscle, kidney, brain and liver. Large increases in mitochondrial AST occur in serum after extensive tissue necrosis⁸. The ensuing centrilobular necrosis results in a rapid rise in aminotransferases, with AST value greater than ALT in the initial days of hepatic injury⁹. Initial portal and periportal fibrosis of varying degree may progress to cirrhosis¹⁰. In this study, ALT level showed a significant difference with the degree of fibrosis ($p=0.043$). ALT is primarily localized to the liver and more frequently increased as compared to AST. ALT also may reflect the extent of hepatocellular necrosis⁸. Relative levels of alkaline phosphatase elevation could be used as markers to indicate cholestatic problems, whereas elevated ALT or AST levels would indicate hepatocellular injury¹¹.

Albumin is quantitatively the most important protein in plasma synthesized by the liver and is a useful indicator of hepatic function. Low albumin suggests underlying poor synthetic activity of the liver and thereby underlying end-stage liver disease^{7-9,12}. Albumin level in this study showed a significant difference with the degree of fibrosis ($p=0.001$), degree of duct proliferation ($p=0.006$) and duct plate malformation ($p=0.037$). In one study, all the cases with duct plate malformation had very severe fibrosis with nodular transformation of the liver and also had increased biliary proliferation⁴. Serum concentration of albumin depends upon several

other factors such as nutritional, hormonal, sepsis, systemic inflammatory disorders, urinary and gastrointestinal losses. These should be considered when interpreting low albumin levels in patients with chronic liver disease⁷.

Conclusions

This study showed that while the direct bilirubin level was significantly associated with the degree of duct proliferation and the ALT level was significantly associated with the degree of fibrosis, the albumin level was significantly associated with the degree of fibrosis, degree of duct proliferation and degree of duct plate malformation.

References

1. Dezsöfi A, Baumann U, Dhawan A, Durmaz O, Fischler B, Hadzic N, *et al*. Liver biopsy in children. *Journal of Pediatric Gastroenterology and Nutrition* 2015; **60**: 408–20. <https://doi.org/10.1097/MPG.0000000000000632> PMID: 25383787
2. Russo P, Magee JC, Boitnott J, Bove KE, Raghunathan T, Finegold M, *et al*. Design and validation of the biliary atresia research consortium histologic assessment system for cholestasis in infancy. *Clinical Gastroenterology and Hepatology* 2011; **9**: 357–62. <https://doi.org/10.1016/j.cgh.2011.01.003> PMID: 21238606 PMID: PMC3400532
3. Ovchinsky N, Moreira RK, Lefkowitz JH, Lavine JE. Liver biopsy in modern clinical practice: a paediatric point-of-view. *Advances in Anatomic Pathology* 2012; **19**: 250–62. <https://doi.org/10.1097/PAP.0b013e31825c6a20> PMID: 22692288 PMID: PMC3404724
4. Muthukanagarajan SJ, Karnan I, Srinivasan P. Diagnostic and prognostic significance of various histopathological features in extrahepatic biliary atresia. *Journal of Clinical and Diagnostic Research* 2016; **10**: 23–7. <https://doi.org/10.7860/JCDR/2016/19252.8035> PMID: 27504296 PMID: PMC4963656
5. Standish RA, Cholongitas E, Dhillon A, Burroughs AK, Dhillon AP. An appraisal of the histopathological assessment of liver fibrosis. *Gut* 2006; **55**: 569–78.

- <https://doi.org/10.1136/gut.2005.084475>
PMid: 16531536 PMCID: PMC1856155
6. Gupta L, Gupta SD, Bhatnagar V. Extrahepatic biliary atresia: Correlation of histopathology and liver function tests with surgical outcomes. *Journal of the Indian Association of Pediatric Surgery* 2012; **17**: 147–52.
<https://doi.org/10.4103/0971-9261.102326>
PMid: 23243365 PMCID: PMC3518991
 7. Sharma P. Value of liver function tests in cirrhosis. *Journal of Clinical and Experimental Hepatology* 2022; **12**: 948–64.
<https://doi.org/10.1016/j.jceh.2021.11.004>
PMid: 35677506
 8. Thapa BR, Walia A. Liver function tests and their interpretation. *Indian Journal of Pediatrics* 2007; **74**: 663–71.
<https://doi.org/10.1007/s12098-007-0118-7>
PMid: 17699976
 9. Woreta TA, Alqahtani SA. Evaluation of abnormal liver tests. *Medical Clinics of North America* 2014; **98**: 1–16.
<https://doi.org/10.1016/j.mcna.2013.09.005>
PMid: 24266911
 10. López P, Eugenia L, Barberi J. Neonatal and infantile cholestasis: An approach to histopathological diagnosis. *Revista Colombiana de Gastroenterología* 2014; **29**: 294–301.
 11. Senior JR. Alanine aminotransferase: A clinical and regulatory tool for detecting liver injury-past, present, and future. *Clinical Pharmacology and Therapeutics* 2012; **92**: 332–9.
<https://doi.org/10.1038/clpt.2012.108>
PMid: 22871997
 12. Giannini EG, Testa R, Savarino V. Liver enzyme alteration: a guide for clinicians. *CMAJ* 2005; **172**: 367–79.
<https://doi.org/10.1503/cmaj.1040752>
PMid: 15684121 PMCID: PMC545762

Prediction of histopathological grades of liver pathology in cholestasis by direct bilirubin, aspartate aminotransferase, alanine aminotransferase and albumin level

ORIGINALITY REPORT

18%

SIMILARITY INDEX

11%

INTERNET SOURCES

16%

PUBLICATIONS

1%

STUDENT PAPERS

PRIMARY SOURCES

- 1** Deepak Kumar Singh. "Independent Predictors of Steatohepatitis and Fibrosis in Asian Indian Patients with Non-Alcoholic Steatohepatitis", *Digestive Diseases and Sciences*, 07/2008 2%

Publication
- 2** Özge Karadağ, Serap Balci. "WPŁYW OSŁONY INKUBATORA CHRONIĄCEJ PRZED HAŁASEM I ŚWIATŁEM NA PARAMETRY FIZJOLOGICZNE WCZEŚNIAKÓW NA NOWORODKOWYM ODDZIALE INTENSYWNEJ TERAPII", *Health Problems of Civilization*, 2022 1%

Publication
- 3** www.medigraphic.com 1%

Internet Source
- 4** pghn.org 1%

Internet Source
- 5** diagnosticpathology.biomedcentral.com 1%

Internet Source

6	doaj.org Internet Source	1 %
7	Senior, J R. "Alanine Aminotransferase: A Clinical and Regulatory Tool for Detecting Liver Injury–Past, Present, and Future", <i>Clinical Pharmacology & Therapeutics</i> , 2012. Publication	1 %
8	ctajournal.biomedcentral.com Internet Source	1 %
9	"Liver & Pancreas", <i>Laboratory Investigation</i> , 2008 Publication	1 %
10	Submitted to Regent's College Student Paper	1 %
11	doczz.net Internet Source	1 %
12	www.gastrocol.com Internet Source	1 %
13	Emad Hamdy Gad, Yasmin Kamel, Tahany Abdel-Hameed Salem, Mohammed Abdel-Hafez Ali, Ahmed Nabil sallam. "Short- and long-term outcomes after Kasai operation for type III biliary atresia: Twenty years of experience in a single tertiary Egyptian center-A retrospective cohort study", <i>Annals of Medicine and Surgery</i> , 2021 Publication	1 %

14

"Scientific Abstracts", Reproductive Sciences, 2010.

Publication

1 %

15

Ashkan Jahangirnia, Irina Oltean, Youssef Nasr, Nayaar Islam, Arielle Weir, Joseph de Nanassy, Ahmed Nasr, Dina El Demellawy. "Peri-Operative Liver Fibrosis and Native Liver Survival in Pediatric Patients with Biliary Atresia: A Systematic Review and Meta-Analysis", Pediatric Gastroenterology, Hepatology & Nutrition, 2022

Publication

<1 %

16

Nicholas E. Handoyo, Mora Claramita, Marselino K. P. Abdi Keraf, Julie Ash, Lambert Schuwirth, Gandes R. Rahayu. "The importance of developing meaningfulness and manageability for resilience in rural doctors", Medical Teacher, 2022

Publication

<1 %

17

Pokorska-Śpiewak, Maria. "Is liver biopsy still needed in children with chronic viral hepatitis?", World Journal of Gastroenterology, 2015.

Publication

<1 %

18

hrcak.srce.hr

Internet Source

<1 %

19

naspghan.org

Internet Source

<1 %

20

Behairy El-Sayed Behairy, Alif Abd El-Hakim Allam, Shymaa Galal Hegazy, Doha Maher Taie, Ahmad Mohamed Sira. "Adequacy criteria of Tru-cut needle liver biopsy in neonatal cholestasis", *Annals of Hepatology*, 2021

Publication

<1 %

21

www.tmfv.com.ua

Internet Source

<1 %

22

Chen, Gong, Ping Xue, Shan Zheng, Lian Chen, and Yangyang Ma. "A pathological scoring system in the diagnosis and judgment of prognosis of biliary atresia", *Journal of Pediatric Surgery*, 2015.

Publication

<1 %

23

virusjour.crie.ru

Internet Source

<1 %

24

www.elsevier.es

Internet Source

<1 %

Exclude quotes Off

Exclude matches Off

Exclude bibliography On

Prediction of histopathological grades of liver pathology in cholestasis by direct bilirubin, aspartate aminotransferase, alanine aminotransferase and albumin level

GRADEMARK REPORT

FINAL GRADE

GENERAL COMMENTS

/100

PAGE 1

PAGE 2

PAGE 3

PAGE 4

PAGE 5

PAGE 6
