

3. The Role of Histopathology in Patients with Hepatitis C

by Ummi Maimunah

Submission date: 08-Dec-2023 05:35PM (UTC+0800)

Submission ID: 2252330622

File name: 3_The_Role_of_Histopathology_in_Patients_with_Hepatitis_C.pdf (434.71K)

Word count: 6356

Character count: 33782

RESEARCH ARTICLE

The Role of Histopathology in Patients with Hepatitis C Leading to Hepatocellular Carcinoma

Kenneth Martino Djajapranata¹ and Umami Maimunah²✉

¹Department of Internal Medicine, Dr Soetomo Academic General Hospital, Airlangga University, Surabaya, Indonesia

²Gastroenterology and hepatobiliary division, Department of Internal Medicine, Dr Soetomo Academic General Hospital, Surabaya, Indonesia

Corresponding Author: Umami Maimunah **E-mail:** Ummima@gmail.com

ABSTRACT

Hepatocellular carcinoma (HCC) is a primary malignant tumor of the liver, where 90% of cases of primary liver tumors are caused by this tumor. About 85% of HCC tumor cases also have cirrhosis of the liver. Currently, HCC is the fifth most malignant tumor in the world. Other than that, San HCC's survival is scanty. A patient at Dr. Soetomo complained of an enlarged stomach 5 months ago. The patient was first diagnosed with Hepatitis C 3 months ago but has not been treated for hepatitis C. The patient underwent several examinations in January, March and May 2022. Supportive testing of normal AFP and anti-HCV levels was performed with a positive result for HCV RNA >11.00. When considering liver function tests to assess liver disease severity using the CTP score, the score is 7 (CTP B). X-ray examination, CT scan and tumor size 11.2 x 6.7 cm were obtained, fed from the right a. hepatica, and there was no thrombosis in v. porta/hepatica. In these patients, there was no arterial enhancement, venous phase washout, and pseudocysts. The liver tumor of the aorta to the aorta, the largest size 7.3 x 11.3 x 15.9 cm, is equal to VTh11-VL3. The link expands to ±6.8 inches. Since the AFP test was normal and the CT scan did not show these results, this patient will be followed up with a biopsy. The biopsy method was performed with FNAB considering the safety of the procedure and the patient profile. Atypical FNAB results but favorable histochemistry for HCC, where CK, glypican-3, and AFP are positive. Based on the results of the examination, it was stated that the patient had Hepatocellular Carcinoma (HCC) accompanied by cirrhosis of the liver due to chronic hepatitis C infection.

KEYWORDS

Liver Cell Carcinoma; Hepatitis C; Hepatocellular; Histopathology

ARTICLE INFORMATION

ACCEPTED: 11 May 2023

PUBLISHED: 20 May 2023

DOI: 10.32996/jmhs.2023.4.3.2

1. Introduction

Hepatocellular carcinoma (HCC) is a malignant primary tumor of the liver, in which 90% of cases of primary liver tumors are caused by this tumor. About 85% of HCC tumor cases also have hepatic cirrhosis. Currently, HCC is the fifth most malignant tumor in the world. In addition, the survival of San HCC is meager. That is, the 5-year survival is only 18%, second only to malignancy in the pancreas. One of the causes of HCC is chronic hepatitis C virus infection. (Asafo-Agyei et al., 2022; Tunissiolli et al., 2017; Llovet et al., 2021). Hepatitis C is a virus that attacks the liver. The virus is estimated to affect 185 million people in the world. Generally, about 80 – 85% of cases of acute hepatitis C virus infection eventually develop into a chronic infection. The prevalence of hepatitis C is between 1 – 2%, but it has a higher mortality rate than hepatitis A and B viruses. (Basit et al., 2022; Manns et al., 2017; Spearman et al., 2019).

This virus is a ribonucleic acid (RNA) virus from the family Flaviviridae and has 7 genotypes. Transmission occurs through blood and body fluids infected with the hepatitis C virus. Transmission can occur in people at risk, such as injecting drug users, unsterile

Copyright: © 2023 the Author(s). This article is an open access article distributed under the terms and conditions of the Creative Commons Attribution (CC-BY) 4.0 license (<https://creativecommons.org/licenses/by/4.0/>). Published by Al-Kindi Centre for Research and Development, London, United Kingdom.

tattooing/piercing practices, unsterile medical practices, perinatal mother-to-baby, and unsafe sexual behavior. Basit et al., 2022; PPHI, 2017). Chronic hepatitis C infection that does not receive adequate therapy can develop into HCC. Chronic inflammation due to hepatitis C causes fibrosis and necrosis of the liver and contributes to HCC. In hepatitis C, HCC occurs after the patient develops severe fibrosis or cirrhosis hepatitis. PPHI, 2017). Hepatitis C virus eradication therapy uses direct-acting antiviral (DAA) for 12-24 weeks. Meanwhile, for HCC, therapy is determined after evaluating and determining the classification of the Barcelona Clinic Liver Center (BCLC). Therapies of choice include ablation therapy, surgical resection, transplantation, chemoembolization, and systemic flame Chemother (Asafo Agyei et al., 2022; Ghany et al., 2019; PPHI, 2017)

1.1 Case

A male patient, Mr. S, 49 years old, Javanese, married, came to the RS Dr. Soetomo on June 14, 2022, complaining of an enlarged stomach 5 months ago. The patient was first diagnosed with Hepatitis C 3 months ago but has not been treated for hepatitis C.

1.2 Anamnesis

Patients have complained of an enlarged stomach since 5 months ago, and sometimes the stomach also feels pain. Patients also feel tight, especially after activities such as walking or if they talk too much for too long. Tightness is felt more and more severe since the stomach is felt to be getting bigger, and there is a lump in the stomach which is suspected because the liver is enlarged, so the stomach feels full and causes shortness of breath. Patients complain of reduced appetite because the stomach feels full. The patient said the weight (BB) lost 15 kg in the last 3 months; the current weight is 60kg. Complaints of nausea, vomiting, fever, and headache were previously denied. There are no complaints of defecation or urination. History of diabetes mellitus, hypertension, heart defects, liver disease, and autoimmune disorders is denied. The patient is an employee of a private office in Jombang. The patient works as a farmer, and the patient feels that he has never used illegal drugs, the use of syringes, the patient's wife is only 1, but the patient has engaged in unsafe sexual behavior (playing with others)

1.3 Physical Examination

On physical examination, sufficient general condition was obtained, competitive awareness, Glasgow Coma Scale (GCS) E4V5M6, blood pressure 125/94 mmHg, pulse frequency 98 times per minute, breathing frequency 22 times per minute, satura peripheral 99% free air, axillary temperature 36.5°C. Height (TB) 170 cm and weight (BB) 60 kg. The head and neck examination found anemis, no jaundice, cyanosis, or dyspnea. There is no increase in jugular venous pressure or enlargement of neck lymph nodes. Thoracic examination found symmetrical movements, not retraction. In the cardiac examination, single S1 and S2 were obtained regularly, and no heart noise, gallop rhythm, or pericardium friction sound was obtained. On lung examination, vesicular breathing sounds were obtained in both hemitorax and neither rhonchi nor wheezing in both lung fields.

Examination of the abdomen found normal intestinal noise. The abdomen appears slightly distended, with no dilation of collateral veins or caput medusa. No shifting dullness is obtained. There is tenderness in the epigastric region of the abdomen. Palpable mass in the epigastrium area of the left hepatic enlargement. Around 5 cm below the arcus costae, there is a swelling palpable hepatic, and the surface is slippery and palpable, like multiple masses, with obtuse angles. Lien palpable enlarged, namely Hackett grade 3 and Scuffner grade 4. Examination of the extremities obtained warm, dry, and red accruals. There is no edema in all extremities. There are no enlarged lymph nodes in the armpits and thigh folds.

1.4 Supporting Examination

Laboratory tests Hb 9.7 g/dL, HCT 29.7%, MCV 83.2 fl, MCH 25.5 pg, leukocytes 11510/ul, neutrophils 60.9%, lymphocytes 13%, platelets 254000/ul, SGOT 50 U/L, SGPT 30 U/L, BUN 25 mg/dL, serum creatinine 1.53 mg/dL, Na 137 mmol/L, K 4.7 mmol/L, Cl 103 mmol /L, albumin 2.8 g/dL, Total Bilirubin 0.52 mg/dL, Direc Bilirubin 0.19 mg/dL, PPT 17.4 sec, APTT 36 sec, non-reactive HbsAg, HIV 3 non-reactive method. Blood Gas Analysis Results pH 7.28; pO2 67 mmHg; pCO2 48 mmHg; HCO3 22.6 mmol/l; BE - 4.1 mmol/l; SO2 90%; P/F ratio 319 mmHg.

The patient's working diagnosis is HCC (*Hepatocellular Carcinoma*) with chronic Hepatitis C. Initial management included a hepatic diet of 2100 kcal/day, infusion of NaCl 0.9% 500 ml/24 hours, and paracetamol tablets 3x500 mg per oral.

1.5 Course Of The Disease

In mid-January 2022, patients often experience pain in the epigastrium; Moreover discomfort in the abdominal area; patients have seen an internal medicine specialist at Jombang and were initially diagnosed with dyspepsia syndrome. Then because there was no change after being treated for about 2 months, finally, on March 8, 2022, an abdominal ultrasound was carried out at Jenggolo Diagnostic Center Jombang; the results were obtained. Description of multiple nodules with multiple cysts in the abdominal aorta effect of gastritis, malignant lymphoma. So it is recommended to do a CT scan of the abdomen. On March 22, 2022, an abdominal CT scan without contrast was carried out at Jombang Hospital, and the following images were obtained: Hepar enlarged to size 18

cm, homogeneous parenchyma density, irregular edges, normal IHBD / EHBD, portal vein and hepatic vein Normal, no visible mass/cyst. Lien size enlarged 15 cm, homogeneous parenchyma density, and no visible mass. Multiple KGB enlargement conglomerates along the paraaorta measuring 13.8 x 4.8 cm long 16 cm. The conclusion leads to the picture of lymphoma in the paraaorta, hepatosplenomegaly. Then, an internal medicine specialist in Jombang diagnosed him with suspected paraaortic Malignant Lymphoma and referred him to Dr. Soetomo Hospital Surabaya for further examination.

On March 31, 2022, the patient came to RS Dr. Soetomo Surabaya's gastro hepatology poly and conducted several examinations. Results of GDA 87 mg/dL, SGOT 56 U/L, SGPT 64 U/L, BUN 8.0 mg/dL, serum creatinine 0.99 mg/dL, Na 146 mmol/L, K 4.2 mmol/L, Cl 104 mmol/L, Calcium 8.4 mg/dL, albumin 3.34 g/dL, Total Bilirubin 0.51 mg/dL, Direc Bilirubin 0.24 mg/dL, Uric acid 5.3 mg/dL, LDH 216 U/L, non-reactive HbsAg, Reactive Anti-HCV which was examined for the first time, AFP 5.4 ng/ml, CEA 1.16 ng/ml, CA 19-9 27.08 U/ml. On April 1, 2022, an Abdominal CT Scan with contrast was carried out. The following picture was obtained, Hepar: standard size with irregular parenchyma edges, multiple nodules appear in segments II/III left lobe of the liver with the most significant dimensions of 11.2 x 6.7 cm, which looks slightly enhanced compared to the normal parenchyma of the liver in the arterial phase, the impression of getting feeding from the right a. hepatica, IHBD/EHBD dilation visible, a/v fistula visible, thrombus v.porta/hepatica invisible. There are multiple KGBs conglomerated in the paraaorta, aortocaval to para cava, with the most significant dimensions of 7.3x 11.3x 15.9 cm as high as VTh11-VL3, entreating the abdominal aorta and inferior vena cava. Lien: Enlarged size with midclavicular craniocaudal length 16.8cm, normal parenchyma density, no visible mass. Paraseptal and centrilobular emphysema appear in the posterobasal of the left lung, and fibrosis appears in the basal of the left-right lung. The above findings lead to a picture of hepatic cirrhosis accompanied by malignant degeneration d/ hepatoma. Then on April 22, 2022, FNAB carried out the abdominal region. The deletion found distribution and small groups of atypical cells with nuclei of varied shapes (round oval), chromatin nuclei rough, some rough, some with a prominent core child. Appears the distribution pattern of inflammatory cells of neutrophils, lymphocytes, and histiocytes against the background of erythrocyte cells. In conclusion, atypical cells were obtained.

Then on May 10, 2022, painting (immunohistochemistry) was carried out with antibodies CK, Glypican 3, and AFP and obtained the following results: CK: Positive in the cytoplasm of tumor cells, Glypican 3: Positive in the cytoplasm of cells tumor, AFP: Positive on the membrane and cytoplasm of tumor cells, and conclusions are obtained in favor of hepatocellular carcinoma.

On June 7, 2022, an HCV RNA examination was carried out with a result of >11.00. The patient was prescribed sofosbuvir and daclatasvir, but they were not taken because the stock of drugs was empty then.

2. Discussion

Hepatocellular carcinoma (HCC) is a malignant primary tumor in the liver that feels (?) from hepatocyte cells, where 90% of cases with malignant liver tumors are these tumors. Currently, HCC is the 5th most common tumor in the world, the second lowest survival after pancreatic malignancy, and the fourth highest cause of death from malignancy. Incidence and mortality are reported to increase annually worldwide, but the highest is reported in East Asia and Africa. The highest average incidence for HCC is reported at an advanced age of 45 – 65. (Asafo- Agyei et al., 2022; Tunisiolli et al., 2017; Llovet et al., 2021)

Several etiologies, including hepatitis C virus infection, can cause HCC malignancy. Generally, 80 – 85% of acute hepatitis C infection cases will develop into chronic infection. The prevalence of hepatitis C is 1 – 2%, whereas, for Southeast Asia, it is 1%, with an estimated 6.6 million patients. In Indonesia alone, the prevalence based on anti-HCV is 0.8 – 1%. Stalet et al., 2022; Manns et al., 2017; PPHI, 2017). Hepatitis C is an RNA virus of the family Flaviviridae, genus Hepacivirus with a length of 9,600 nucleotide bases. Currently, 7 genotypes have been identified, namely:

- Genotype 1: Eropa, North America, Japan, most commonly found worldwide, 60 – 70% of cases.
- Genotype 2: Central and West African, associated with blood transfusions
- Genotype 3: Asian, linked to injecting drug use
- Genotype 4: North Africa and the Middle East
- Genotype 5: South Africa
- Genotype 6: Asia
- Genotype 7: Canada, Belgium, Central Africa

46

For Indonesia itself, the most frequent genotype is genotype 1, followed by genotypes 2 and 3. (Basit et al., 2022; PPHI., 2017)

Transmission of the hepatitis C virus occurs through blood and body fluids infected with the hepatitis C virus. Transmission can occur in people at risk, such as injecting drug users, unsterile tattooing/piercing practices, unsterile medical practices, perinatal from mother to baby, and unsafe sexual behavior. The rate of hepatitis C infection is also increasing in the specific population,

namely prisoners, injecting drug users, vagrants, and hemodialysis patients who routinely get blood transfusions. (Basit et al., 2022; Manns et al., 2017; Spearman et al., 2019).

The incubation period of the hepatitis C virus is between 14 – 180 days, with an average incubation rate of 45 days. The clinical manifestations of acute hepatitis infection can vary, ranging from asymptomatic to symptomatic, but only 20% of cases report symptoms. Symptoms often include malaise, fatigue, anorexia, jaundice, hepatomegaly, and increased liver enzymes. After 6 months, if anti-HCV and hepatitis C virus RNA is still detected, then hepatitis C virus infection develops into a chronic infection. (Basit et al., 2022; PPHI., 2017)

Generally, 80-85% of acute cases will develop into chronic infections. Some risk factors known to affect the risk of chronicity are male sex, age >25 years at the time of infection, asymptomatic, African-American ethnicity, co-infection with HIV, immunosuppression, obesity, alcoholism, insulin resistance, and type 2 diabetes mellitus. The progression of the disease is slow, lasting between 20 – 40 years. (Basit et al., 2022; PPHI., 2017)

Carcinogenesis of hepatitis C infection is mediated by immunological factors induced by the virus and host. Core proteins in this virus can encourage lipogenesis and damage oxidative stress metabolism. Viral proteins can work directly on cell signaling pathways to promote myogenic, angiogenic, and metastatic, preventing cell death, triggering chronic inflammation and the production of oxidative stress, and disrupting the metabolism of host fats. If the process occurs repeatedly, mutations accumulate that can turn healthy hepatocyte cells into malignant. The telomerase reverse transcriptase gene, tumor protein 53, and β-catenin are the genes found to be most commonly mutated. (Tunissiolli et al., 2017; Llovat et al., 2021; Axley et al., 2018)

Clinical symptoms depend on the staging tumor and the severity of cirrhosis. (Asafo-Agyei et al.)

1. HCC without cirrhosis: found early in the disease, patients present without symptoms, present in patients with hepatitis B
2. HCC with cirrhosis: found in more advanced conditions, symptoms in the form of signs of decompensated cirrhosis, such as jaundice, pruritus, hepatic encephalopathy, ascites, palpable mass in the upper right abdomen, fever, malaise, weight loss, satiety, abdominal distention, cachexia, and abdominal pain.
3. Complications: patients may also be diagnosed due to esophageal varicose bleeding, intra-abdominal hemorrhage, obstructive jaundice, and pyogenic liver abscesses; metastases in HCC are most commonly found in the lungs and intra-abdomen. Intraabdomen is found in the lymph nodes of the nodes, bones, and adrenaglands I.

24
 In this case, the patient was a 49-year-old male. The patient came because his stomach felt big and like a lump 5 months ago.

Complaints are also accompanied by abdominal pain, easy to feel full, and decreased body weight. History of being diagnosed with hepatitis C 3 months ago but has not received therapy. On physical examination, patients with compos mentis, anemia, abdominal distension, epigastric tenderness, hepatomegaly and multiple, and splenomegaly. Based on the history and physical examination, the patient has HCC accompanied by cirrhosis hepatis due to chronic hepatitis C virus infection. The lab also found anti-HCV reactive with normal AFP. We think that because of a history of hepatitis C that does not receive therapy, hepatomegaly is one that we Suspect as a mass, and the presence of signs of cirrhosis, such as splenomegaly.

For supporting examinations to ensure the presence of hepatitis C infection, an anti-HCV examination is carried out, if positive, followed by hepatitis C virus RNA. Furthermore, liver function tests were carried out, which included SGOT / SGPT, total bilirubin / direct, albumin, PT / aPTT, and INR. This examination will help assess the severity of liver disease using the Child – Turcotte – Pugh (CTP) scoring system. This scoring system will assess clinical symptoms in ascites and encephalopathy, as well as bilirubin, albumin, and PT/INR laboratory tests. (Basit et al., 2022; PPHI, 2017; Ruf et al., 2022)

Table 1. Child – Turcotte – Pugh (CTP) Classification

Parameters	Value		
	1	2	3
Ascites	None	Light	Keep
Bilirubin	< 2 mg/dl	2 – 3 mg/dl	> 3 mg/dl
Albumin	> 3.5 mg/dl	2.8 – 3.5 mg/dl	< 2.8 mg/dl
Lengthening of PT or INR	< 4 seconds < 1.7	4 – 6 seconds 1.7 – 2.3	> 6 seconds > 2.3
Encephalopathy	None	Grades 1 - 2	Grades 3 – 4

Score 5 – 6 = CTP A, Score 7 – 9 = CTP B, Score 10 – 15 = CTP C

27

Alpha-fetoprotein (AFP) is a glycoprotein with a molecular weight of 70,000 kD. These glycoproteins are synthesized by the liver, intestines, and *yolk sac* fetal. In HCC, AFP values can be found to increase as hepatocytes undergo differentiation processes, such as fetal liver cells. This examination has been used as a marker of HCC, with a sensitivity of 66% and specificity of 80%. Normal AFP values < 20 ng/ml. A value of > 20 ng/ml can be suspected of HCC. However, in some cases of HCC, normal AFP levels are reported. HCC patients with normal AFP levels are generally older, have lower viral counts, milder cirrhosis, smaller tumor size, vascular invasion lighter, and cell differentiation is good. (Asafo-Agyei et al., 2022; Llovet et al., 2021; Lee et al., 2019). Despite the fact that the poor diagnostic ability of serum AFP to detect HCC, a clinically increased serial AFP value may help as a complementary method in patients whose chronic hepatitis is monitored for the occurrence of HCC. (Bruix J, 2011)

For radiological examination, HCC can be diagnosed using ultrasound, CT scan, and MRI. (Asafo-Agyei et al., 2022; Tunissiolli et al., 2017; Llovet et al., 2021, Hennedige and Venkatesh, 2012)

1. Ultrasound: widely used as a screening tool in patients at risk of HCC with a sensitivity of 51 – 87% and specificity of 80 – 100%. This examination can help assess the size, morphology, and location of the tumor. HCC tumors can look hypoechoic or hyperechoic depending on fat infiltration or fibrosis. Tumors of small size < 2cm are less useful with this examination.
2. CT scan: 3-phase contrast CT scan examination has 65% sensitivity and 96% specificity. However, in small tumors, sensitivity and specificity decrease. Using contrast in multiphase, diagnosis is established when blood vessel support is obtained in tumors measuring > 2cm with the presence or absence of deceleration in the *washout* phase on the portal with pseudocapsule around the perimeter of the tumor. Other typical findings were the *internal mosaic* pattern, the presence of fat, vascular invasion, and tumor enlargement >50% on the serial examination within <6 months. Complications can also be found in the form of thrombosis in the portal vein. If thrombosis has occurred, it means that the tumor flows from the hepatic artery and flows directly into the portal vein. Defiance in the arterial phase is caused due to vascularization. KSH Mostly originates in the hepatic artery; consequently, When contrast reaches the hepatic ery, this hypervascularization will appear as a stinging of the tumor relative to the surrounding liver parenchyma. This characteristic picture occurs because, along with the accretion of KSH nodules, there is a growth of the hepatic artery that is not balanced with the growth of the portal vein., further When contrasting reaching the portal vein (portal vein phase), the picture seen in KSH nodules is washout or less bright than the surrounding normal liver tissue., this is due to Because normal liver tissue is flowed by blood coming from arteries or from portal veins containing contrast substances.
3. MRI: This examination has a sensitivity of 77 – 90% and a specificity of 84 – 97%. Performed in a typical HCC image is found in patients who do not suffer from liver cirrhosis and require further examination such as MRI with contrast; MRI with contrast is also useful for Distinguish malignant nodules from regenerating and dysplastic nodules in the liver undergoing cirrhosis.

A liver biopsy is not a routine examination performed on HCC because of the risk of bleeding, *tumor seeding* (spreading tumors), and false negatives. This test has a sensitivity of 66 – 93%, depending on the size of the tumor and 100% specificity. This examination is recommended on an atypical tum or HCC to confirm the diagnosis. If the tumor is <2 cm without radiological signs or normal AFP levels, a biopsy can be performed to confirm the diagnosis. Today, *fine needle aspiration* biopsy (FNAB) is widely used as a method of biopsy sampling. This method is done with consideration of better safety and patient profile, where the risk of bleeding and *tumor seedling* is lower. This technique is also recommended in patients with advanced tumors or who are not recommended for surgery. FNAB sensitivity is 90% and specificity 100%. It should be noted that the FNAB method relies heavily on the operator in taking, isolating, and reading samples. FNAB can also be repeated easily. (Asafo-Agyei et al., 2022; Tunissiolli et al., 2017; Llovet et al., 2021; Wee A, 2012). According to a study conducted by Chiang, FNAB is superior to Core Biopsy because the needle is longer, the procedure is easy, and it has a relatively rend spread; ah, but the two methods (FNA and Core Biopsy) complement each other if they can be combined. (Chhieng, 2004). PPHI 2017 also recommends FNA is safer in terms of bleeding and that longer needles than Core Biopsy (20-23 gauge by 18 gauge) can access nodules that are hard to reach. There is also a study conducted by McGahan that compares FNAB with Core Biopsy; it was found that FNAB is more specific in diagnosing primary neoplasms in the liver compared to core biopsy, while in Core Biopsy was superior; it was also found that DNA in the liver had a sensitivity of more than 85% and specificity as high as 100% with the highest sensitivity when FNA was combined with Core Biopsy (McGahan JP et al., 2013). This study also found limitations between DNA and Core Biopsy to vague diagnoses, but rarely found in cases of a definitive diagnosis of hepatocellular carcinoma rather than metastases; some literacy combines with core biopsy to improve diagnostic accuracy. However, there is some literature that states that the addition of immunohistochemistry to FNA can already diagnose HCC (Wee A, 2006)

Diagnosis of hepatocellular carcinoma is particularly challenging in FNAB and Core Biopsy because all HCCs are not equal; HCCs are pathologically assessed based on grades I to IV, reflecting tumor differentiation. (Edmondson & Kanai). In HCC with grade IV very poorly differentiated and difficult to distinguish from high-grade tumors of non-hepatocellular origin, this diagnostic dilemma can be affected by the background of the disease in patients, such as degeneration, inflammation, infiltrate and apoptosis can mimic the characteristics of hepatocellular carcinoma so it is very difficult to distinguish.

Histochemical examination plays a role in helping to establish the diagnosis and distinguish between HCC and non-HCC. The diagnosis is taken by combining biopsy and histochemical results. A histochemical examination can be done in the form of HSP70, glypican-3, and GS histochemical examinations. (Asafa-Agyei et al., 2022; Tunissiolli et al., 2017; Llovet et al., 2021; Wee A, 2012). Hepatocyte Paraffin Antigen-1 (Hep Par 1), Glypican-3, and CD-34, to name a few, have been touted as sensitive markers to help distinguish HCC from non-HCC malignancies; important also for doctors to know that there are IHC markers that can help you get an equivocal biopsy, and the best markers are glypican-3, Hepar-1 and Moc-31 and the best found Other. (Hong H, 2011). The European Association for The Study of Liver (EASL) 2012 recommends immunostaining for GPC3, HSP70, and glutamine synthetase and /or gene expression profiles (GPC3, LYVE1, and survivin) recommended to distinguish dysplastic nodules with high levels of early HCC. Additional staining may be considered to detect features of progenitor cells (K19 and EpCAM) or assess neovascularization (CD34)". Other recent studies have shown that immunohistochemical panels of Golgi 73 (GP73), glypican-3 (GPC 3), and CD34 proteins, as well as reticulum staining, are highly specific in HCC diagnosis. (Yao S, 2013).

The European Association for The Study of Liver (EASL) and the American Association for the Study of Liver Diseases (AASLD) provide the latest guidelines and guidelines regarding non-invasive diagnosis established with one imaging technique on nodules 1-2 cm in diameter or in the above 2cm, which adopts the characteristics of radiological HCC namely contrast uptake in the arterial phase, and washout in the venous/late phase, can be accompanied by pseudocapsule. The AFP value is omitted in this scheme; broadly speaking, this recommendation is not much different from the 2017 PPHI.

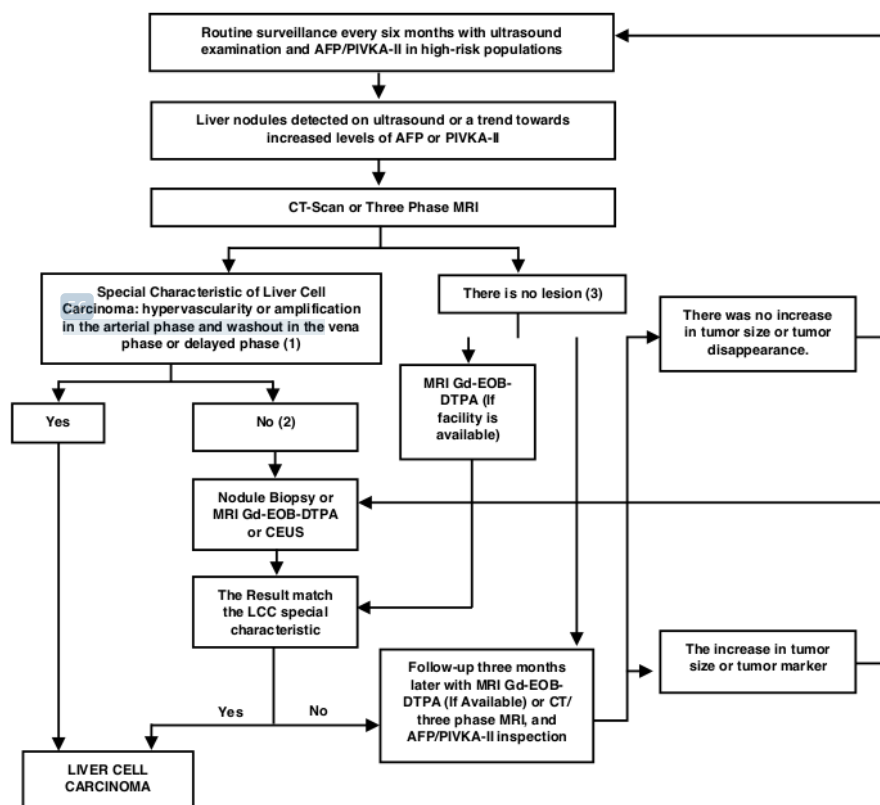


Figure 1. Liver cell carcinoma diagnosis algorithm (PPHI, 2017)

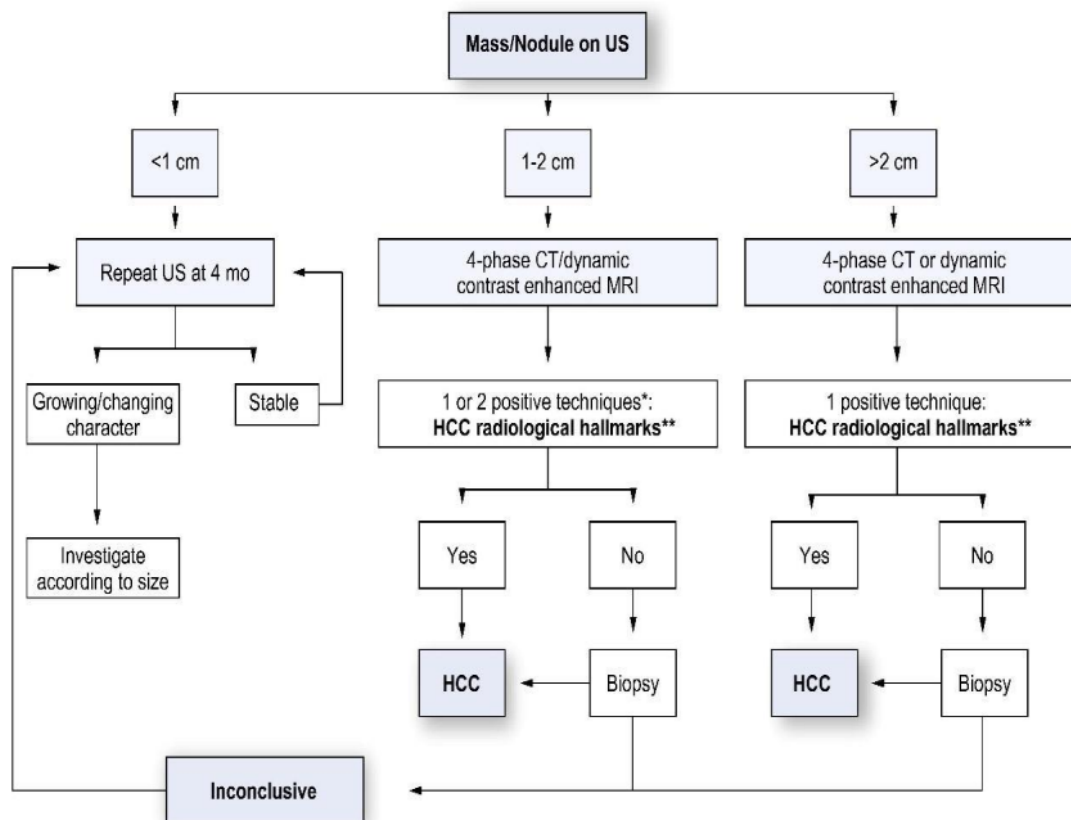


Figure 2. Diagnostic algorithm in HCC (European Association for The Study of Liver)

In this patient, a supporting examination of normal AFP and anti-HCV levels was carried out with positive results with HCV RNA > 11.00. In the examination of liver function tests to assess the severity of liver disease using CTP scoring, a score of 7 (CTP B) was obtained. For radiological examination, a CT scan was performed, and a tumor size of 11.2 x 6.7 cm was obtained, feeding from the right a. hepatica, and no thrombus in v. porta/hepatica. In these patients, there is no arterial enhancement or washout in the venous phase and pseudocapsule. Tumors in the aortic lung, aortocaval to para cava, with the largest dimensions of 7.3x 11.3x 15.9 cm as high as VTh11-VL3. Lien enlarges to a size of \pm 16.8 cm. Because the AFP examination is normal and the CT scan does not contain the findings above, then in this patient, a follow-up examination is carried out in the form of a biopsy. The biopsy method is performed with FNAB with consideration of the safety of the procedure and patient profile. FNAB results are atypical but histochemical results are supportive for an HCC, where CK, glypican-3, and AFP are positive. Based on these examinations supports the initial diagnosis, namely HCC accompanied by cirrhosis hepatis due to chronic hepatitis C virus infection.

Management in patients with HCC according to PPHI is determined from the degree of liver function, namely using Child-Pugh scoring, the presence of vascular invasion, extrahepatic spread, and size; this algorithm adapting the management algorithm issued by the Asia Pacific Association for the Study of the Liver (APASL) 2017, the algorithm was specially prepared because the condition of HCC sufferers in Indonesia is not the same as other countries (PPHI, 2017)

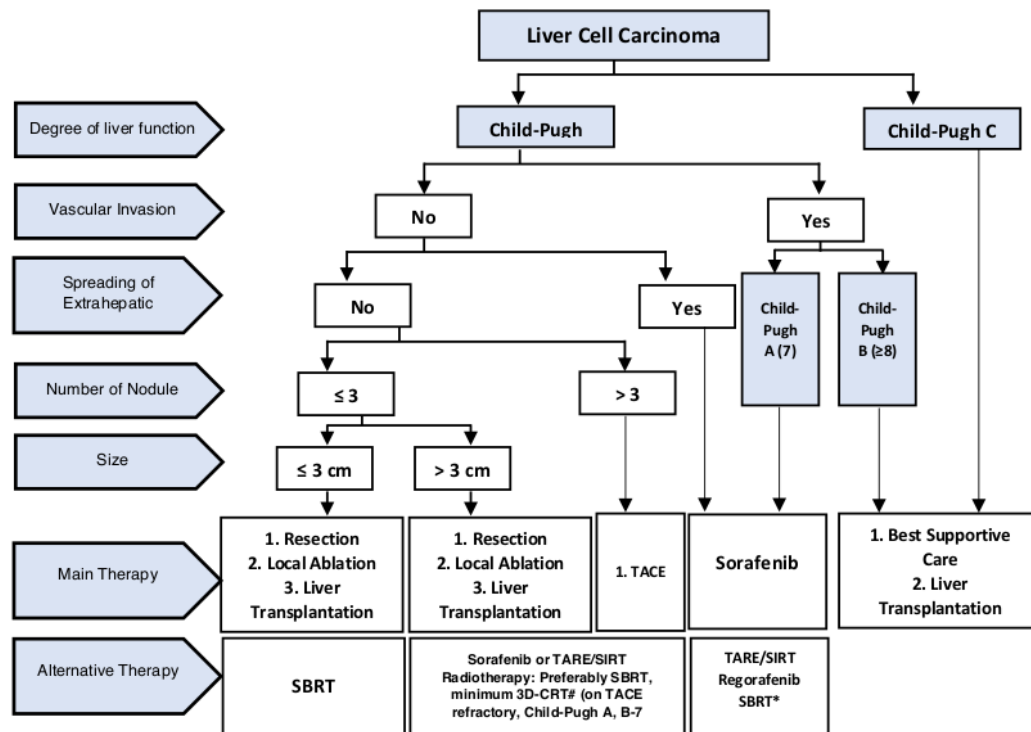


Figure 3. Liver cell carcinoma management algorithm (PPHI, 2017)

25
SBRT: Stereotactic Body Radiation Therapy, SIRT: Selective Internal Radiation Therapy, TACE: Transarterial Chemoembolization, TARE: Transarterial Radioembolization, *SBRT: on the Liver Cell Carcinoma with portal vein thrombus which other therapy is not amenable, size <8 cm, Child-Pugh A. #:

14
According to the guidelines, what is meant by vascular invasion is the discovery of a thrombus in the portal vein or inferior vena cava on imaging. Vascular invasion is a strong predictor of a poor prognosis. The next step after assessing vascular invasion is to determine the presence of extrahepatic spread, where multiple KSH is found in more than one liver lobe or KSH that has been invading the main branch of the portal vein/hepatic vein, the portal vein thrombus can be a source of cystic metastases.

18
The three most commonly found metastatic sites are pulmonary, intra-abdominal lymph nodes (KGB), and bone. Sorafenib is the first oral multi-tyrosine kinase inhibitor shown to improve survival in patients with KSH. Sorafenib can improve overall survival and time-to-progression (TTP) in advanced KSH patients with good liver function. Sorafenib is the only first-line systemic therapy for KSH. This therapy is indicated for KSH patients with good liver function (CTP A/B with a score of 7) and advanced tumors (BCLCC). (PPHI 2017) Sorafenib works by inhibiting the molecular components of the Raf–MEK–ERK signaling pathway, which would inhibit VEGFR-1, VEGFR 2, and 3, thereby inhibiting angiogenesis. By such a mechanism, sorafenib can delay the progression of the disease.

41
In the study, sorafenib could prolong the overall survival by 10.7 months, and the median TTP was 5.5 months, which was only 2.8 months. In line with another study by Lopez (2006), sorafenib increased survival by 3 months in patients with advanced stages of KSH. This finding is important, given the increasing incidence of this disease worldwide and the lack of existing therapeutic options for anticancer agents in KSH that have been carried out over the past 30 years, including systemic chemotherapy, intraarterial, and immunotherapy. (Wilhelm 2004)

3. Prognosis

About 80 – 85% of cases of acute hepatitis C infection will develop into chronic hepatitis C infection. Furthermore, only 20% of patients with chronic hepatitis infection will progress to cirrhosis hepatitis, but only 1-5% eventually develop HCC.

Patients with hepatitis C have higher mortality than hepatitis B. In addition, HCC has the second lowest 5-year survival after pancreatic malignancies, which is 18%. (Axley et al., 2018; Asafo-Agyei et al., 2022)

4. Conclusion

We have reported a case of a 49-year-old male with HCC accompanied by cirrhosis due to chronic hepatitis C infection. Patients complain of an enlarged stomach since 5 months ago accompanied by pain, easy to feel full, and weight loss. In the physical examination peme, hepatomegaly is obtained with splenomegaly. Supporting examinations obtained positive Anti-HCV, normal AFP, the severity of liver disease CTP B, CT scan obtained liver tumors and splenomegaly with an unusual picture as not found the presence of arterial enhancement, washout in the venous phase, and pseudocapsule. So anatomical pathology and immunohistochemistry examination was carried out for further examination, and it was found that the examination supported the carcinoma of liver cells.

Funding: This research received no external funding.

Conflicts of Interest: The authors declare no conflict of interest.

Publisher's Note: All claims expressed in this article are solely those of the authors and do not necessarily represent those of their affiliated organizations, or those of the publisher, the editors and the reviewers.

References

- [1] Asafo-Agyei KO, Samant H. (2022). Hepatocellular Carcinoma. [Updated 2022 May 8]. In: StatPearls [Internet]. Treasure Island (FL): StatPearls Publishing; 2022 Jan-.
- [2] Axley P, Ahmed Z, Ravi S (2018). Hepatitis C Virus and Hepatocellular Carcinoma: A Narrative Review. *J Clin Transl Hepatol*. 28;6(1):79-84.
- [3] Basit H, Tyagi I, Koirala J. Hepatitis C. (2022). In: StatPearls [Internet]. Treasure Island (FL): StatPearls Publishing; 2022 Jan-.
- [4] Bruix J, Sherman M (2011). Management of hepatocellular carcinoma: an update. *Hepatology*. 53(3):1020–1022.
- [5] Chhieng, D.C. (2004). Fine needle aspiration biopsy of liver – an update. *World J Surg Onc* 2, 5.
- [6] Edmondson HA, Steiner PE (1954). Primary carcinoma of the liver: a study of 100 cases among 48,900. *Cancer*. (3):462–503
- [7] European Association for The Study Of The L. Treatment Of C (2012). EASL-EORTC clinical practice guidelines: management of hepatocellular carcinoma. *Journal of Hepatology*.;56(4):908–943.
- [8] Ghany MG, Morgan TR. (2020). AASLD-IDSA Hepatitis C Guidance Panel. Hepatitis C Guidance 2019 Update: American Association for the Study of Liver Diseases-Infectious Diseases Society of America Recommendations for Testing, Managing, and Treating Hepatitis C Virus Infection. *Hepatology*. 2020 Feb;71(2):686-721.
- [9] Guarino M, Sessa A, Cossiga V. (2018). Special Interest Group on "Hepatocellular carcinoma and new anti-HCV therapies" of the Italian Association for the Study of the Liver. Direct-acting antivirals and hepatocellular carcinoma in chronic hepatitis C: A few lights and many shadows. *World J Gastroenterol*. 2018 June 28;24(24):2582-2595.
- [10] Henneidge T, Venkatesh SK. (2011) Imaging of hepatocellular carcinoma: diagnosis, staging and treatment monitoring. *Cancer Imaging*. Feb 8;12(3):530-47
- [11] Hong H, Patonay B, Finley (2011). Unusual reticulin staining pattern in well-differentiated hepatocellular carcinoma. *Diagnostic Pathology*. 2011;6(1):p. 15.
- [12] Kakar S, Gown AM, Goodman ZD, Ferrell LD (2007). Best practices in diagnostic immunohistochemistry: hepatocellular carcinoma versus metastatic neoplasms. *Archives of Pathology and Laboratory Medicine*. 131(11):1648–1654.
- [13] Kanai T, Hirohashi S, Upton MP (1987). Pathology of small hepatocellular carcinoma. A proposal for a new gross classification. *Cancer*. 60(4):810–819
- [14] Lee CW, Tsai HI, Lee WC (2019). Normal Alpha-Fetoprotein Hepatocellular Carcinoma: Are They Really Normal? *J Clin Med*. 19;8(10):1736.
- [15] Llovet JM, Kelley RK, Villanueva A (2021). Hepatocellular carcinoma. *Nat Rev Dis Primers*. 2021 Jan 21;7(1):6.
- [16] Lopez PM, Villanueva A, Llovet JM (2006). Systematic review: evidence-based management of hepatocellular carcinoma -- an updated analysis of randomized controlled trials. *Aliment Pharmacol Ther* 2006;23:1535-1547
- [17] Manns MP, Buti M, Gane E (2017). Hepatitis C virus infection. *Nat Rev Dis Primers*. 2;3:17006.
- [18] McGahan JP, Bishop J, Webb J, (2013). Role of FNA and Core Biopsy of Primary and Metastatic Liver Disease. *Int J Hepatol*. 2013:174103.
- [19] Indonesian Heart Research Association (2017). National Consensus on Hepatitis C Management in Indonesia. Jakarta.
- [20] Indonesian Heart Research Association (2017). National Consensus on Management of Liver Cell Carcinoma. Jakarta.
- [21] Ruf A, Dirchwolf M, Freeman RB (2022). From Child-Pugh to MELD score and beyond Taking a walk down memory lane. *Ann Hepatol*. Jan-Feb;27(1):100535.
- [22] Spearman CW, Dusheiko GM, Hellard M (2019). Hepatitis C. *Lancet*. 2019 Oct 19;394(10207):1451-1466.
- [23] Tunissiolli NM, Castanhole-Nunes MMU, Biselli-Chi cote PM, (2017). Hepatocellular Carcinoma: a Comprehensive Review of Biomarkers, Clinical Aspects, and Therapy. *Asian Pac J Cancer Prev*. (4):863-872.
- [24] Wee A (2011). Fine-needle aspiration biopsy of hepatocellular carcinoma and related hepatocellular nodular lesions in cirrhosis: controversies, challenges, and expectations. *Pathology Res Int*. 2011;2011:587936.
- [25] Wee A (2005). Fine needle aspiration biopsy of the liver: Algorithmic approach and current issues in the diagnosis of hepatocellular carcinoma. *Cytojournal*. 2005;2:7. Published 2005 Jun 8.
- [26] Wilhelm SM, Carter C, Tang L (2004). BAY 43-9006 exhibits broad spectrum oral antitumor activity and targets the RAF/MEK/ERK pathway and receptor tyrosine kinases involved in tumor progression and angiogenesis. *Cancer Res* 64:7099-7109
- [27] Yao S, Zhang J, Chen H, (2013). Diagnostic value of immunohistochemical staining of GP73, GPC3, DCP, CD34, CD31, and reticulin staining in hepatocellular carcinoma. *Journal of Histochemistry & Cytochemistry*. 61(9):639–648

3. The Role of Histopathology in Patients with Hepatitis C

ORIGINALITY REPORT

16%

SIMILARITY INDEX

12%

INTERNET SOURCES

12%

PUBLICATIONS

%

STUDENT PAPERS

PRIMARY SOURCES

1	umu.diva-portal.org Internet Source	1%
2	vdocuments.site Internet Source	1%
3	www.thieme-connect.com Internet Source	1%
4	www.coursehero.com Internet Source	1%
5	Yeo Wool Kang, Yang Hyun Baek, Sung Wook Lee, Sung-Jae Park et al. "Real-world Effectiveness and Safety of Direct-acting Antiviral Agents in Patients with Chronic Hepatitis C Genotype 2 Infection: Korean Multicenter Study", Journal of Korean Medical Science, 2021 Publication	<1%
6	repository.medri.uniri.hr Internet Source	<1%
7	www.nepjol.info Internet Source	<1%

8	ndl.ethernet.edu.et Internet Source	<1 %
9	www.minervamedica.it Internet Source	<1 %
10	e-journal.unair.ac.id Internet Source	<1 %
11	insightsimaging.springeropen.com Internet Source	<1 %
12	www.ncbi.nlm.nih.gov Internet Source	<1 %
13	www.nejm.org Internet Source	<1 %
14	"2022 KLCA-NCC Korea Practice Guidelines for the Management of Hepatocellular Carcinoma", Korean Journal of Radiology, 2022 Publication	<1 %
15	www.stdaware.com Internet Source	<1 %
16	healthdocbox.com Internet Source	<1 %
17	lib.medilam.ac.ir Internet Source	<1 %
18	www.wjgnet.com Internet Source	<1 %

19

Parsia A. Vagefi. "Downstaging of Hepatocellular Carcinoma Prior to Liver Transplant: Is There a Role for Adjuvant Sorafenib in Locoregional Therapy?", *Journal of Gastrointestinal Cancer*, 05/05/2010

Publication

<1 %

20

Alan W. Hemming. "Biliary Tract and Primary Liver Tumors", *Surgical Oncology Clinics of North America*, 2019

Publication

<1 %

21

liu.diva-portal.org

Internet Source

<1 %

22

Colombo, Massimo, Jean-Luc Raoul, Riccardo Lencioni, Peter R. Galle, Jessica Zucman-Rossi, Rafael Bañares, Daniel Seehofer, Peter Neuhaus, and Philip Johnson.

"Multidisciplinary strategies to improve treatment outcomes in hepatocellular carcinoma : a European perspective", *European Journal of Gastroenterology & Hepatology*, 2013.

Publication

<1 %

23

www.ekjm.org

Internet Source

<1 %

24

"Abstracts from the 30th Annual Meeting of the Society of General Internal Medicine", *Journal of General Internal Medicine*, 2007

Publication

<1 %

25

Arvinder Soin, Mickaël Lesurtel, Prashant Bhangui, Lorenzo Cocchi, Mohamed Bouattour, Pierre-Alain Clavien. "Are patients with hepatocellular carcinoma and portal vein tumour thrombosis candidates for liver transplantation?", *Journal of Hepatology*, 2023

Publication

<1 %

26

Umar, Muhammed, Aamir G. Khan, Zaigham Abbas, Sanjeev Arora, Naqvi Asifabbas, Andre Elewaut, Gamal Esmat, Graham Foster, Michael Fried, Khean-L Goh, Tul Bushra Khaar Hamama, Michio Imawari, Vasily Isakov, Justus Krabshuis, Douglas LaBrecque, Anton LeMair, Peter Malfertheiner, Steve Ryder, Peter Schiedermaier, Davor Stimac, Rakesh Tandon, Federico Villamil, Rodrigo Zapata, and Peter Ferenci. "World Gastroenterology Organisation Global Guidelines : Diagnosis, Management and Prevention of Hepatitis C April 2013", *Journal of Clinical Gastroenterology*, 2014.

Publication

<1 %

27

patents.google.com

Internet Source

<1 %

28

journals.lww.com

Internet Source

<1 %

29

www.bishyboys.org.uk

Internet Source

<1 %

30

www.mona.uwi.edu

Internet Source

<1 %

31

Chong Zhong. "A randomized controlled trial of hepatectomy with adjuvant transcatheter arterial chemoembolization versus hepatectomy alone for Stage III A hepatocellular carcinoma", *Journal of Cancer Research and Clinical Oncology*, 05/01/2009

Publication

<1 %

32

Takeharu Enomoto, Shinya Mikami, Takehito Otsubo, Takashi Tsuda, Motohiro Chosokabe. "Ten-year follow-up after chemotherapy (S1 + cisplatin + trastuzumab) and surgery for human epidermal growth factor receptor 2-positive stage IV esophagogastric junction cancer with pathological complete response: a case report", *Research Square Platform LLC*, 2023

Publication

<1 %

33

link.springer.com

Internet Source

<1 %

34

podcasters.spotify.com

Internet Source

<1 %

35

www.eurchembull.com

Internet Source

<1 %

36 Nirmeen Sabry, Ahmed M. Kamel, Ahmed Cordie, Gamal Esmat. "Daclatasvir as a hepatitis C infection treatment option: an up-to-date evaluation", Expert Opinion on Pharmacotherapy, 2022
Publication <1 %

37 R. Badea, Simona Ioanimescu. "Chapter 7 Ultrasound Imaging of Liver Tumors – Current Clinical Applications", IntechOpen, 2012
Publication <1 %

38 bsdwebstorage.blob.core.windows.net
Internet Source <1 %

39 downloads.hindawi.com
Internet Source <1 %

40 wjso.biomedcentral.com
Internet Source <1 %

41 Giuseppe Lombardi, Fable Zustovich, Fabio Farinati, Umberto Cillo et al. "Pegylated liposomal doxorubicin and gemcitabine in patients with advanced hepatocellular carcinoma", Cancer, 2011
Publication <1 %

42 Peter Spieler, Matthias Rössle. "Nongynecologic Cytopathology", Springer Science and Business Media LLC, 2012
Publication <1 %

43 Shuzhe Yao, Jianping Zhang, Haiyan Chen, Yan Sheng, Xiaoying Zhang, Zhiyan Liu, Cuijuan Zhang. "Diagnostic Value of Immunohistochemical Staining of GP73, GPC3, DCP, CD34, CD31, and Reticulin Staining in Hepatocellular Carcinoma", Journal of Histochemistry & Cytochemistry, 2013
Publication

44 Tian-Yang Chen, Jing-Yin Mai, Ping Zhang, Jian-Hua Xue, Sheng-Li He, Jun Xi, Jian-Jie Chen, Yang Cheng. "Efficacy of erzhu jiedu recipe on hepatitis B cirrhosis with hyperalphafetoproteinemia", Medicine, 2021
Publication

45 cjpgim.ca
Internet Source

46 multimedia.elsevier.es
Internet Source

47 orlando.mediabistro.com
Internet Source

48 rcastoragev2.blob.core.windows.net
Internet Source

49 www.amc.edu
Internet Source

50 www.esciencecentral.org
Internet Source

51

"Sub-Saharan Political Cultures of Deceit in Language, Literature, and the Media, Volume I", Springer Science and Business Media LLC, 2023

Publication

<1 %

52

Gokce Askan, Vikram Deshpande, David S. Klimstra, Volkan Adsay, Carlie Sigel, Jinru Shia, Olca Basturk. "Expression of Markers of Hepatocellular Differentiation in Pancreatic Acinar Cell Neoplasms", American Journal of Clinical Pathology, 2016

Publication

<1 %

53

Henryk Dancygier. "Clinical Hepatology", Springer Science and Business Media LLC, 2010

Publication

<1 %

54

Xin Xu, Yuquan Tao, Liang Shan, Rui Chen, Hongyuan Jiang, Zijun Qian, Feng Cai, Lifang Ma, Yongchun Yu. "The Role of MicroRNAs in Hepatocellular Carcinoma", Journal of Cancer, 2018

Publication

<1 %

55

d-nb.info

Internet Source

<1 %

56

d.docksci.com

Internet Source

<1 %

57	Internet Source	<1 %
58	pdffox.com Internet Source	<1 %
59	wjgnet.com Internet Source	<1 %
60	www.annalsofafricansurgery.com Internet Source	<1 %
61	www.scribd.com Internet Source	<1 %
62	www.tandfonline.com Internet Source	<1 %
63	Francisco Tustumi, Fabricio Ferreira Coelho, Daniel de Paiva Magalhães, Sérgio Silveira Júnior et al. "Treatment of hepatocellular carcinoma with macroscopic vascular invasion: A systematic review and network meta-analysis", Transplantation Reviews, 2023 Publication	<1 %
64	Josep M. Llovet, Jordi Bruix. "Molecular targeted therapies in hepatocellular carcinoma", Hepatology, 2008 Publication	<1 %
65	Yuhchyan Chen. "Phase II and pharmacokinetic (PK) study of induction	<1 %

docetaxel/cisplatin followed by pulsed docetaxel chemoradiation for stage III non-small cell lung cancer", Journal of Thoracic Oncology, 08/2007

Publication

66

"Daclatasvir/sofosbuvir", Reactions Weekly, 2023

Publication

<1 %

67

General Surgery, 2009.

Publication

<1 %

68

Young-Sun Lee, Eunjung Ko, Eileen L. Yoon, Young Kul Jung et al. "Multiplexed Proteomic Approach for Identification of Serum Biomarkers in Hepatocellular Carcinoma Patients with Normal AFP", Journal of Clinical Medicine, 2020

Publication

<1 %

Exclude quotes On

Exclude matches Off

Exclude bibliography On

3. The Role of Histopathology in Patients with Hepatitis C

GRADEMARK REPORT

FINAL GRADE

GENERAL COMMENTS

/100

PAGE 1

PAGE 2

PAGE 3

PAGE 4

PAGE 5

PAGE 6

PAGE 7

PAGE 8

PAGE 9