

Get More with SINTA Insight

Go to Insight



0.36842
1
Impact Factor

58
Google Citations

Sinta 4
Current Accreditation

[Google Scholar](#) [Garuda](#) [Website](#) [Editor URL](#)

History Accreditation

2020 2021 2022 2023 2024

Garuda [Google Scholar](#)

Increasing Smartphone Usage Correlates With Worsening Sleep Quality Among Students

Universitas Airlangga [Journal of Community Medicine and Public Health Research Vol. 4 No. 1 \(2023\): Journal Community Medicine and Public Health Research 1-8](#)
2023 DOI: 10.20473/jcmphr.v4i1.39159 **Accred : Sinta 4**

Effectiveness of Video Conferencing Education in Childhood Functional Gastrointestinal Disorders Knowledge in Limited Resource Health Care Workers

Universitas Airlangga [Journal of Community Medicine and Public Health Research Vol. 4 No. 1 \(2023\): Journal Community Medicine and Public Health Research 9-13](#)
2023 DOI: 10.20473/jcmphr.v4i1.40163 **Accred : Sinta 4**

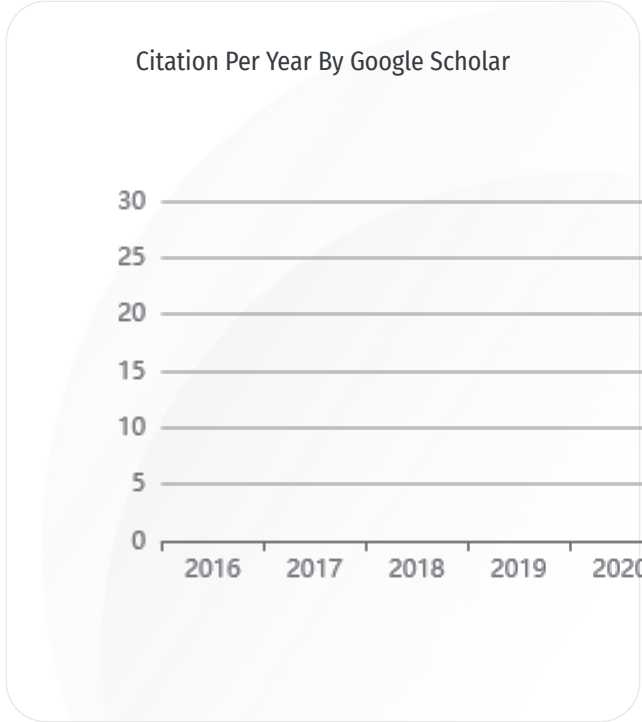
Giving Birth By Caesarean Section in Women Infected With Covid-19 and The Incidence of Covid-19 in Newborn. A Systematic Review

Universitas Airlangga [Journal of Community Medicine and Public Health Research Vol. 4 No. 1 \(2023\): Journal Community Medicine and Public Health Research 55-64](#)
2023 DOI: 10.20473/jcmphr.v4i1.41512 **Accred : Sinta 4**

Blood Pressure and anthropometry obesity indices in first professional medical students at a private medical college of Pakistan-a cross-sectional study: Blood Pressure and anthropometry obesity indices

Universitas Airlangga [Journal of Community Medicine and Public Health Research Vol. 4 No. 1 \(2023\): Journal Community Medicine and Public Health Research 14-24](#)
2023 DOI: 10.20473/jcmphr.v4i1.41832 **Accred : Sinta 4**



Attitude and Behavior Towards Covid-19 Control Among High School Students in



Journal By Google Scholar

	All	Since 2019
Citation	58	58
h-index	4	4
i10-index	1	1

**JOURNAL OF
COMMUNITY MEDICINE
AND PUBLIC HEALTH
RESEARCH**



VOLUME 4, NUMBER 2, DECEMBER 2023



JOURNAL OF COMMUNITY MEDICINE AND PUBLIC HEALTH RESEARCH

email: jcmphr@journal.unair.ac.id, website: <https://e-journal.unair.ac.id/JCMPHR/>

Vol. 4, No. 2, December 2023

E-ISSN 2723-035X

Editorial Team

Editor-in-Chief

Dr. Nyilo Purnami, dr., Sp.THTKL (K), FICS, FISCM

Associate Editor

Dr. Pudji Lestari, dr., M.Kes

Dr. Linda Dewanti dr., M.Kes., MHSc., Ph.D

Rizki Pradayan, dr., Sp.OG

Dr. Lilik Djuari, dr., M.Kes

Editorial Board

Dr. Sulistiawati, dr., M.Kes (Faculty of Medicine, Universitas Airlangga, Surabaya, Indonesia), Dr. Margarita Maria Maramis, dr Sp.KJ(K), FISCM (Faculty of Medicine, Universitas Airlangga, Surabaya, Indonesia), Dr. Hazli B. Zakaria (Department of Psychiatry, The National University of Malaysia, Malaysia), Dr. Suneela Garg, MD, FIPHA FIAPSM, FIAGP (Department of Community Medicine, Maulana Azad Medical Center New Delhi, India), Dr. Juan José Barajas (Universidad de la Laguna, San Cristobal de La Laguna, Spain), Prof. Khin Hla Hla (Department of Otorhinolaryngology, Head & Neck, Grand Hantha International Hospital, Myanmar), Prof. Dr. dr. Tengku Siti Hajat Haryuna, Sp. THTKL (K) (Faculty of Medicine, Universitas Sumatera Utara, Indonesia), Prof. Dr. Afzal Mahmood (Adelaide Health and Medical Sciences, University of Adelaide, Australia), Wienta Diarsvitri, dr., M.Sc., Ph.D, FISPH, FISCM (Medicine Faculty, Universitas Hang Tua, Surabaya, Indonesia)

Assistant Editor

Amiliyatul Mawaddah, S.Si., M.T

Address

Faculty of Medicine Universitas Airlangga
Jl. Mayjen Prof Moestopo 47 Surabaya, Indonesia
Email : jcmphr@journal.unair.ac.id



Table of Contents

Pages	Original Articles :
84 - 90	Direct Health Education Effect on Mandangin Island Public's Knowledge of The Most Common Diseases in Children <i>Alpha Fardah Athiyah, Reza Gunadi Ranuh, Andy Darma, Dwiyanti Puspitasari, Khadijah Rizky Sumitro, Muhammad Faizi, Subijanto Marto Sudarmo</i>
91 - 97	Smoking, Physical Activity, and Hypertension Incidence Among Older Adults in Malang, Indonesia <i>Maimanah Zumaro Ummi Faiqoh, Ardiar Rahmannanda Laksanadi, Safira Shafa Rachmah Hartawan, Felisita Maritza Abidanovanty, Ikhsanuddin Qoth'i, Karindra Amadea Susetiyo, Anastasia Pearl Angeli, Samsriyaningsih Handayani, Heri Sugeng Widodo</i>
98 - 103	Breast Cancer Early Detection Training Through Correct Sadari and Sadanis to Midwives and Nurses <i>Bambang Arianto, Een Hendarsih, Pravica Juti Arumasari</i>
104 - 112	Knowing is Half The Battle: The Effect of Diagnosing Diabetes on Alcohol Consumption in China <i>Yichen Shen</i>
113 - 122	Online Education Posters As A Media For Understanding The New Variant of Covid-19 and Its Prevention <i>Rozana Alfi Sania, Dwi Rachmawati, Salsabila Fabianca Alsaid, Maftuchah Rochmanti</i>
123 - 129	The Relationship Between Exclusive Breastfeeding History to Stunting Incidence in Children Aged 6-24 Months in The Working Area of The Gunung Anyar Community Health Center, Surabaya, Indonesia <i>Latiful Elisia, Risa Etika, Dwi Aprilawati, Hodimatun Mahiroh</i>
130 - 137	The Relationship of Physical Activity and Sleep Quality Toward Hypertension Prevalence in Sumberngepoh Village, Malang, Indonesia <i>M. Gita Jayanata, Fauziah Adhima, Khansa Talitha Rafif, Ludy Diana Wiradhika, Muhamad Bagus Wira Utama, Ramidha Syaharani, Sarah Nia Amru, Khulbizzabidi, Samsriyaningsih Handayani</i>
138 - 146	Profile of Syphilis Risk Factors in The Productive Age Group at Dermatology and Venereology Clinic RSUD DR. Saiful Anwar, Malang Indonesia <i>Rona Lintang Harini, Lita Setyowatie</i>
147 - 159	Systematic Reviews : Drinking Water Quality As A Risk Factor of Stunting: A Systematic Review <i>Ahmad Zaerozi, Nurjazuli, Tri Joko, Slamet Wardoyo, Akina Shrestha, Biniyam Sahiledengle, Biruk Woldesenbet, Ijaz ul Haq</i>
160 - 165	Case Report : The Successful Administration of Steroid in Extrahepatic Cholestasis <i>Anindya Kusuma Winahyu, Rendi Aji Prihaningtyas, Bagus Setyoboedi Sjamsul Arief</i>

THE SUCCESSFUL ADMINISTRATION OF STEROID IN EXTRAHEPATIC CHOLESTASIS: A CASE REPORT

Anindya Kusuma Winahyu, Rendi Aji Prihaningtyas, Bagus Setyoboedi ,
Sjamsul Arief

Child Health Department, Dr. Soetomo General Academic Hospital, Faculty of Medicine, Universitas Airlangga, Surabaya, Indonesia

ABSTRACT

Biliary atresia is the most common cause of liver transplantation in children. Kasai surgery is still a bridging therapy for biliary atresia, but patients are often late for treatment. Based on the currently proposed theory, biliary atresia results from a progressive inflammatory process and progresses to fibrosis of the bile ducts. A case of a 1.5-month-old boy with prolonged jaundice followed by acholic stools and dark urine was presented. He had cholestasis, elevated GGT levels, and a liver biopsy suggesting extrahepatic cholestasis. He was treated with methylprednisolone, ursodeoxycholic acid, and vitamin supplementation was started orally. After steroid therapy, direct bilirubin levels decreased rapidly to 0.55 mg/dl on day 14. Jaundice, acholic stools, cholestasis, and liver function tests were improved. Therapeutic opportunities based on the pathogenesis of inflammation in biliary atresia using steroids may provide new opportunities for non-surgical management of biliary atresia in the early phase of the disease.

How to cite:

Winahyu, A.K., Prihaningtyas, R. A., Setyoboedi, B., Arief, S., 2023. The Successful Administration of Steroid in Extrahepatic Cholestasis: A Case Report. Journal of Community Medicine and Public Health Research, 4(2): 76-81.



Open access under Creative Commons Attribution-ShareAlike 4.0 International License (CC-BY-SA)

ARTICLE HISTORY

Received: July, 18, 2023
Revision: September, 28, 2023
Accepted: October, 13, 2023
Online: November, 15, 2023

doi:
10.20473/jcmphr.v4i2.47751

KEYWORDS

Extrahepatic cholestasis, biliary atresia, steroid, infant

Corresponding author

Bagus Setyoboedi

✉ bagus.setyoboedi@fk.unair.ac.id

Child Health Departement Dr. Soetomo General Academic Hospital, Faculty of Medicine University Airlangga Surabaya

INTRODUCTION

Cholestasis in infants with jaundice is abnormal. The most common cause of cholestasis in infants is biliary atresia (BA). Inflammation is the pathogenesis of biliary atresia, which is currently being developed. The opportunity for drug therapy to suppress the inflammatory process is not widely known for its benefits in biliary atresia.^{1,2}

We reported the presentation of extrahepatic cholestasis jaundice in infants. This case provided an overview of the clinical and diagnostic examination of

infants with extrahepatic cholestasis and the opportunity to provide adjuvant therapy.

CASE REPORT

A boy weighing 2500 g, 37 weeks of gestation was born by cesarean section due to pre-eclampsia. Two weeks after birth, the infant had jaundice, acholic stools, and abdominal distension. He was taken to a pediatrician and was given therapy, but the jaundice did not improve. At 1.5 months old, he was referred to a hepatology outpatient clinic due to cholestasis. There was no fever, no

vomiting, the weight gain was poor, and there were no bleeding manifestations. He received exclusive breast milk. Hepatomegaly was observed. Anthropometry measurements showed a body weight of 2.6 kg, length of 51 cm, and head circumference of 33 cm.

Initial laboratory examination showed a white blood cell count (WBC) of $7.3 \times 10^3/\mu\text{L}$, a hemoglobin level (Hb) of 8.5 g/dl, and a platelet count of $325 \times 10^3/\mu\text{L}$. C-reactive protein (CRP) was 0.4 mg/dl. He received a PRC transfusion. The hepatic function test results were normal, with an aspartate aminotransferase (AST) level of 31 IU/L, and alanine amino-transferase (ALT) level of 21 IU/L, the coagulation parameters were normal (Plasma Prothrombin Time (PPT) of 10.9 s (9-12 s), Activated Partial Thromboplastin Time (APTT) of 30.2 s (23-33 s)), albumin of 3.56 mg/dl, total bilirubin (TB) level of 8.04 mg/dl, direct bilirubin (DB) level of 7.06 mg/dl, and Gamma Glutamyl Transferase (GGT) of 478 U/L. IgM and IgG Rubella were non-reactive, IgM anti-Cytomegalovirus (CMV) and Toxoplasma were non-reactive, but IgG anti-CMV and Toxoplasma were reactive, and HbsAg was

non-reactive. Thyroid function was normal. Other causes of neonatal cholestasis, such as galactosemia and $\alpha 1$ antitrypsin deficiency, were not evaluated due to limited facilities.

The gallbladder was determined to be in normal size, and ultrasonography failed to detect a triangular cord sign that might indicate biliary atresia. Liver pathology tests showed extrahepatic cholestasis with a few bile pigments and within the bile. Hepatocytes were found with some dilated canaliculi containing bile pigment, and some multinucleated giant cell hepatocytes. There were foci of inflammatory infiltration of lymphocytes and neutrophils between the liver lobules. Hepatic extra nodular foci were also found. No fibrosis was found (Figure 1).

He was treated with methyl-prednisolone, ursodeoxycholic acid, and vitamin supplementation was started orally. After steroid therapy, direct bilirubin levels decreased rapidly to 0.55 mg/dl on day 14. His cholestasis and acholic stools improved gradually (Figure 2).

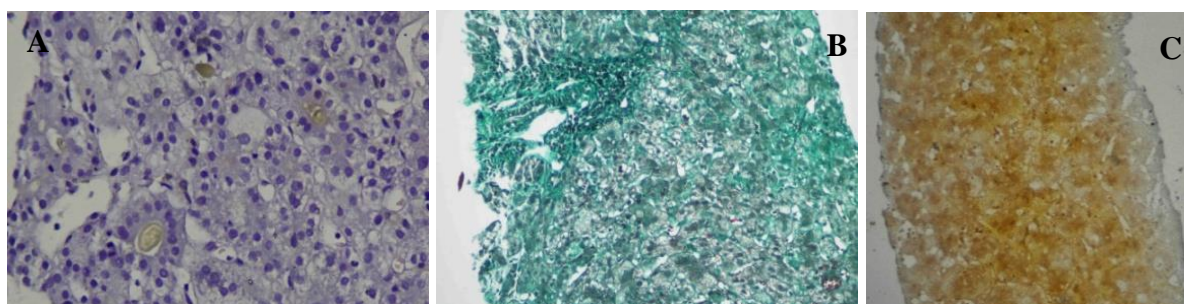


Figure 1. (A) Light microscopic images of the liver biopsy specimen; (B) Mason trichrome staining showed no fibrosis; (C) Reticulin staining showed no fibrosis

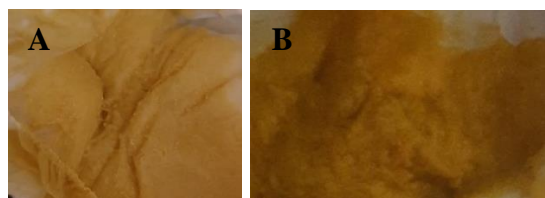


Figure 2. (A) The initial stool looks pale; (B) The stool after 14 days of receiving steroid therapy

Table 1. Time-course of laboratory parameters and therapies performed in the case

Weeks	0	2	4	6
Total bilirubin (mg/dl)	8.04	8.57	6.50	1.56
Direct bilirubin (mg/d)	7.06	7.16	5.20	0.55
AST (U/L)	31	144		78
ALT (U/L)	21	133		86
Therapy	UDCA	UDCA	MP UDCA	MP UDCA

AST: Aspartate Aminotransferase; ALT: Alanine Aminotransferase; UDCA: Ursodeoxycholic acid, MP: Methylprednisolone

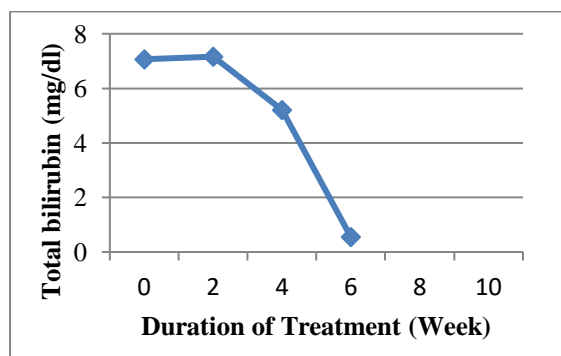


Figure 3. Total bilirubin level during treatment

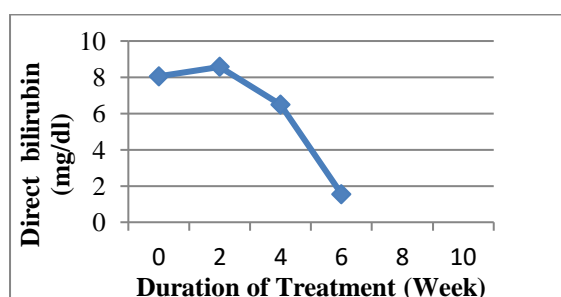


Figure 4. Direct bilirubin level during treatment

Table 1 shows the time course of the laboratory parameters during the entire observation period and the therapies performed. Evaluation of laboratory results showed a white blood cell count of $6.5 \times 10^3/\mu\text{L}$, a hemoglobin level of 12.8 g/dl, and a platelet count of $318 \times 10^3/\mu\text{L}$. Evaluation of anthropometry measurements showed a body weight of 3.7 kg, a length of 51 cm, and a head circumference of 34 cm. There was a clinical improvement and laboratory value for cholestasis after steroid administration (Figures 3 and 4).

DISCUSSION

A case of an infant who experienced prolonged jaundice at the age of more than two weeks, followed by acholic stools and dark urine, was presented. There was no history of significant previous illnesses. The infant was born prematurely. Physical examination revealed jaundice and hepatomegaly. Based on laboratory examination, cholestasis was found, an increase in direct bilirubin levels $> 20\%$ of total bilirubin. An abdominal ultrasound examination and liver biopsy were also performed to establish the etiology of cholestasis. In this case, the abdominal ultrasound results showed normal, but the liver biopsy showed extrahepatic cholestasis with no fibrosis.

The sensitivity and specificity of the triangular cord sign in diagnosing biliary atresia were 74% and 97%, respectively.³⁻⁶ However, this appears to be operator-dependent.⁶⁻⁹ A percutaneous liver biopsy can help differentiate BA from other etiologies.¹⁰⁻¹² Liver biopsy can predict BA with an accuracy of 85-95%, sensitivity (99%), and specificity (92%), which is a valuable tool in the diagnosis of

BA in infant who have normal ultrasound.^(7,13) As many as 50% to 99% of patients with BA are correctly identified by liver biopsy.⁷ Cholestasis and acholic stools, followed by elevated GGT levels, are more specific markers for extrahepatic BA in infants.^{11,14,15} In this case, an infant with prolonged jaundice, cholestasis, acholic stools, elevated GGT levels, and liver biopsy results suggested extrahepatic cholestasis. These conditions lead to BA.

The etiology of BA is unknown. However, the theory suggests that BA occurs due to genetic and acquired factors.¹⁶ Currently, the pathogenesis of BA has been widely studied due to the inflammatory process that occurs in the biliary tract, which can be triggered by a virus. Rotavirus, CMV, and reovirus type 3 have been extensively studied as perinatal animal models that produce biliary atresia. Inflammatory and infectious processes are thought to play a role in the pathogenesis of the disease.^{16,17} Immune-related damage to the bile ducts has been suggested to play a role in the development of BA.^{18,19} This is consistent with evidence that as many as 50% of BA patients have colored stools early in life and later become acholic.^{17,20}

In this case, an infant with prolonged jaundice, cholestasis, acholic stools, elevated GGT levels, and liver biopsy results suggest extrahepatic cholestasis. These conditions lead to BA. The patient received steroids based on the pathogenesis of BA due to inflammation. The steroid given was methylprednisolone at 2 mg/kg/day and the dose was tapered-off every week. Therapeutic evaluations, such as clinical and laboratory tests, were performed every two weeks. In addition to steroids, the patient also received ursodeoxycholic acid and vitamins according to the standard therapy. There

was improvement in clinical and laboratory results for cholestasis after therapy. New therapeutic options with steroids may provide new hope for preventing fibrosis in BA. Further study is needed to prove the benefit of steroids early in preventing cholestasis progression to BA.

CONCLUSION

This case report highlights the potential for steroid therapy in infants with extrahepatic cholestasis and acholic stools who are at risk of developing biliary atresia.

ACKNOWLEDGMENT

The authors would like to give the highest gratitude towards the parent. There is no conflict of interest in this case report.

CONFLICT OF INTEREST

All Authors certify that have no involvement in any organization or entity with any financial interest such as educational grants, participation in speakers bureaus membership, employment, consultancies, expert testimony or patent-licensing arrangements or non-financial interest (such as personal or personal or professional relationships, affiliations, knowledge or beliefs in the subject matter discussed in this manuscript.

PATIENT CONSENT FOR PUBLICATION

Letter of approval for publication was signed by the patient's parent and there is no coercion while signing. Letter of approval attached.



FUNDING

None

AUTHOR CONTRIBUTION

All authors have contributed to all processes in this research, including preparation, data gathering and analysis, drafting and approval for publication of this manuscript.

REFERENCES

1. Di Dato F, Capalbo D, Mirra R, Del Vecchio Blanco F, Salerno M, Iorio R. Case Report: Neonatal Cholestasis as Early Manifestation of Primary Adrenal Insufficiency. *Front Pediatr* [Internet]. 2021 Nov 11 [cited 2023 Jul 18];9. Available from: /pmc/articles/PMC8632351/
2. Fawaz R, Baumann U, Ekong U, Fischler B, Hadzic N, Mack CL, et al. Guideline for the evaluation of cholestatic jaundice in infants: Joint recommendations of the North American society for pediatric gastroenterology, hepatology, and nutrition and the European society for pediatric gastroenterology, hepatology, and nutrition. *J Pediatr Gastroenterol Nutr*. 2017;64(1):154–68.
3. Zhou LY, Wang W, Shan QY, Liu BX, Zheng YL, Xu ZF, et al. Optimizing the US Diagnosis of Biliary Atresia with a Modified Triangular Cord Thickness and Gallbladder Classification. *Radiology* [Internet]. 2015 Oct 1 [cited 2023 Jul 18];277(1):181–91. Available from: <https://pubmed.ncbi.nlm.nih.gov/25955579/>
4. Ramaswamy PK, Jana M, Sharma R, Kandasamy D, Gupta AK, Bhatnagar V, et al. Novel Scoring Systems and Age-Based Hepatic Shear Wave Stiffness Cut-Offs for Improving Sonographic Diagnosis of Biliary Atresia. *Indian J Pediatr* [Internet]. 2023 Jun 29 [cited 2023 Jul 18]; Available from: <https://pubmed.ncbi.nlm.nih.gov/37380918/>
5. Zhou L, Shan Q, Tian W, Wang Z, Liang J, Xie X. Ultrasound for the Diagnosis of Biliary Atresia: A Meta-Analysis. *AJR Am J Roentgenol* [Internet]. 2016 May 1 [cited 2023 Jul 18];206(5):W73–82. Available from: <https://pubmed.ncbi.nlm.nih.gov/27010179/>
6. Dong B, Weng Z, Lyu G, Yang X, Wang H. The diagnostic performance of ultrasound elastography for biliary atresia: A meta-analysis. *Front Public Health*. 2022 Oct 26;10.
7. Moyer V, Freese DK, Whittington PF, Olson AD, Brewer F, Colletti RB, et al. Guideline for the evaluation of cholestatic jaundice in infants: recommendations of the North American Society for Pediatric Gastroenterology, Hepatology and Nutrition. *J Pediatr Gastroenterol Nutr* [Internet]. 2004 [cited 2023 Jul 18];39(2):925. Available from: <https://pubmed.ncbi.nlm.nih.gov/15269615/>
8. Lee SM, Cheon JE, Choi YH, Kim WS, Cho HH, Kim IO, et al. Ultrasonographic diagnosis of biliary atresia based on a decision-making tree model. *Korean J Radiol*. 2015 Nov 1;16(6):1364–72.

9. Yoon H, Lim HJ, Kim J, Lee MJ. [Diagnostic Imaging of Biliary Atresia]. *Journal of the Korean Society of Radiology* [Internet]. 2022 Sep 1 [cited 2023 Jul 18];83(5):991–1002. Available from: <http://www.ncbi.nlm.nih.gov/pubmed/36276203>
10. Feldman AG, Sokol RJ. Recent developments in diagnostics and treatment of neonatal cholestasis. *Semin Pediatr Surg* [Internet]. 2020 Aug 1 [cited 2023 Jul 18];29(4). Available from: <https://pubmed.ncbi.nlm.nih.gov/32861449/>
11. Feldman AG, Sokol RJ. Neonatal Cholestasis: Updates on Diagnostics, Therapeutics, and Prevention. *Neoreviews*. 2021 Dec 1;22(12):e819–36.
12. Feldman AG, Sokol RJ. Neonatal cholestasis: emerging molecular diagnostics and potential novel therapeutics. *Nat Rev Gastroenterol Hepatol*. 2019 Jun 1;16(6):346–60.
13. Hirschfield GM, Beuers U, Corpechot C, Invernizzi P, Jones D, Marzioni M, et al. EASL Clinical Practice Guidelines: The diagnosis and management of patients with primary biliary cholangitis. *J Hepatol* [Internet]. 2017 Jul 1 [cited 2023 Jul 18];67(1):145–72. Available from: <https://pubmed.ncbi.nlm.nih.gov/28427765/>
14. Urganci N, Çetinkaya F, Kalyoncu D, Çakir EP, Yilmaz B. Infants with cholestasis: Diagnosis, management and outcome. *Marmara Medical Journal*. 2012;25(2):83–6.
15. Kolestaz İ, Tamı :, Ve Prognoz T. Infants with Cholestasis: Diagnosis, Management and Outcome.
16. Davenport M. Biliary atresia: clinical aspects. *Semin Pediatr Surg* [Internet]. 2012 Aug [cited 2023 Jul 18];21(3):175–84. Available from: <https://pubmed.ncbi.nlm.nih.gov/22800970/>
17. Thompson H, Davenport M. Biliary Atresia. *Pediatric Surgery: Diagnosis and Management* [Internet]. 2023 Jan 8 [cited 2023 Jul 18];1091–9. Available from: <https://www.ncbi.nlm.nih.gov/books/NBK537262/>
18. Ortiz-Perez A, Donnelly B, Temple H, Tiao G, Bansal R, Mohanty SK. Innate Immunity and Pathogenesis of Biliary Atresia. Vol. 11, *Frontiers in Immunology*. Frontiers Media S.A.; 2020.
19. Feldman AG, Mack CL. Biliary atresia: Cellular dynamics and immune dysregulation. *Semin Pediatr Surg*. 2012 Aug;21(3):192–200.
20. Patel KR. Biliary atresia and its mimics. *Diagn Histopathol*. 2023 Jan 1;29(1):52–66.