



Source details

International Journal of Surgery Case Reports

Scopus coverage years: from 2010 to Present

Publisher: Elsevier

ISSN: 2210-2612

Subject area: Medicine: Surgery

Source type: Journal

[View all documents >](#)
[Set document alert](#)
[Save to source list](#)
[Source Homepage](#)

CiteScore 2022 ⓘ
1.0

SJR 2022 ⓘ
0.193

SNIP 2022 ⓘ
0.580

[CiteScore](#)
[CiteScore rank & trend](#)
[Scopus content coverage](#)

i **Improved CiteScore methodology** ✕

CiteScore 2022 counts the citations received in 2019-2022 to articles, reviews, conference papers, book chapters and data papers published in 2019-2022, and divides this by the number of publications published in 2019-2022. [Learn more >](#)

CiteScore 2022 ⌵

$$1.0 = \frac{3,869 \text{ Citations 2019 - 2022}}{4,033 \text{ Documents 2019 - 2022}}$$

Calculated on 05 May, 2023

CiteScoreTracker 2023 ⓘ

$$0.9 = \frac{3,705 \text{ Citations to date}}{4,225 \text{ Documents to date}}$$

Last updated on 05 September, 2023 • Updated monthly

CiteScore rank 2022 ⓘ

Category	Rank	Percentile
Medicine		
↳ Surgery	#325/495	34th

[View CiteScore methodology >](#)
[CiteScore FAQ >](#)
[Add CiteScore to your site](#)



Scimago Journal & Country Rank

Enter Journal Title, ISSN or Publisher Name

- Home
- Journal Rankings
- Country Rankings
- Viz Tools
- Help
- About Us

Unleash a Spectrum of Flavors

Explore your creativity with new compact and colorful Vertuo Pop coffee machine

Nespresso Indonesia

[Learn More](#)

International Journal of Surgery Case Reports

COUNTRY

Netherlands

Universities and research institutions in Netherlands

Media Ranking in Netherlands

SUBJECT AREA AND CATEGORY

Medicine
Surgery

PUBLISHER

Elsevier BV

H-INDEX

26

PUBLICATION TYPE

Journals

ISSN

22102612

COVERAGE

2010-2022

INFORMATION

[Homepage](#)

[How to publish in this journal](#)

SCOPE

International Journal of Surgery Case Reports is an open access, broad scope journal covering all surgical specialities. It is dedicated to publishing case reports and case series. Articles must be authentic, ethical, educational and clinically interesting to an international audience of surgeons, trainees and researchers in all surgical subspecialties, as well as clinicians in related fields. All case reports and case series submitted need to comply with the relevant reporting criteria. The journal is published monthly and focuses on rapid submission to decision times. The journal covers the following areas of surgery: -Cardiothoracic surgery- General and orthopaedic surgery- Urology- Vascular

Unleash a Spectrum of Flavors

Explore your creativity with new compact and colorful Vertuo Pop coffee machine

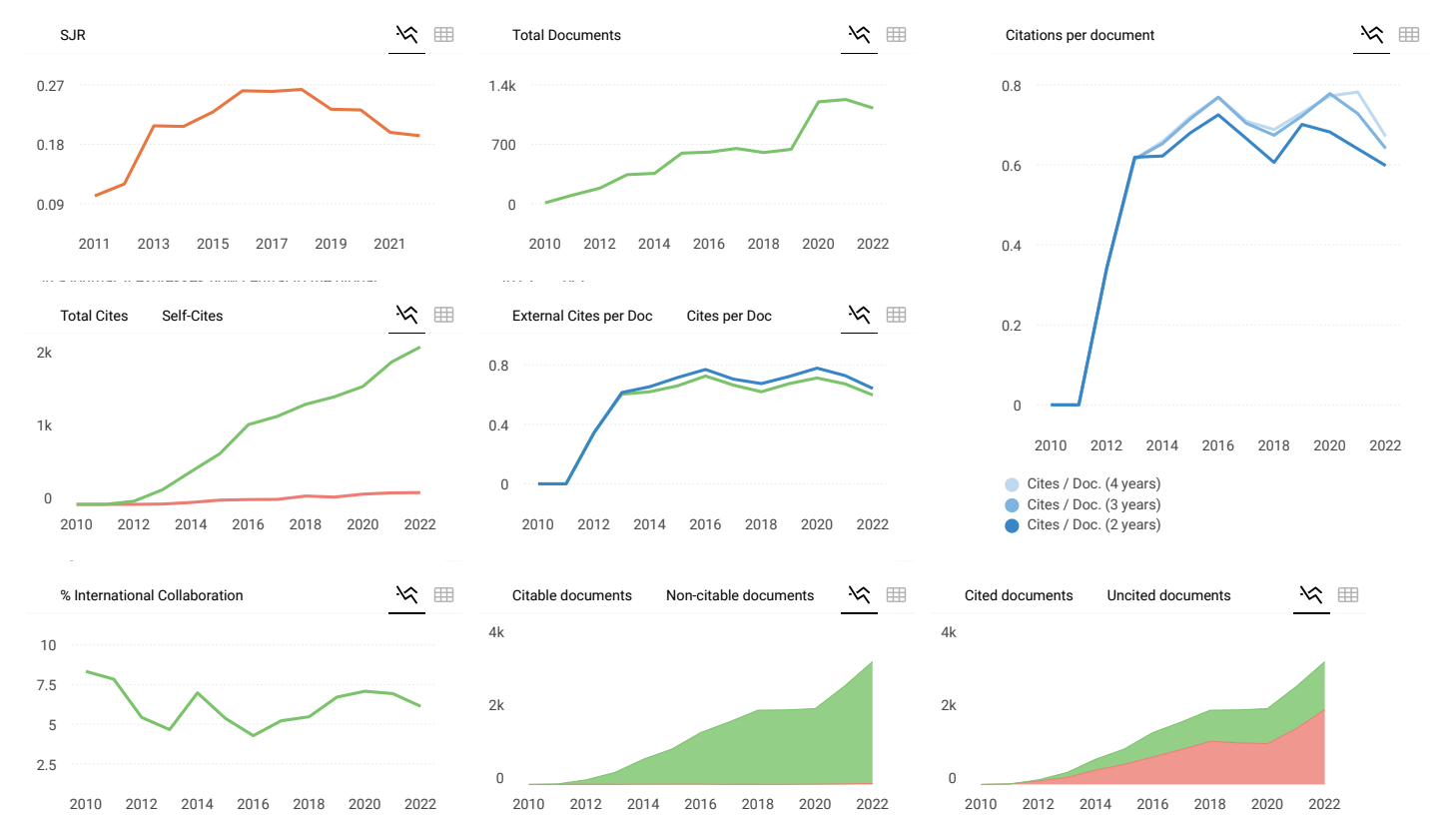
Join the conversation about this journal

Quartiles



FIND SIMILAR JOURNALS ?

<p>1 Annals of Medicine and Surgery NLD</p> <p>67% similarity</p>	<p>2 International Journal of Surgery NLD</p> <p>55% similarity</p>	<p>3 International Journal of Surgery Open GBR</p> <p>50% similarity</p>	<p>4 BMC Surgery GBR</p> <p>34% similarity</p>	<p>5 Indian Journal of Surgery IND</p> <p>3 sir</p>
---	---	--	--	---



International Journal of Surgery Case Reports ← Show this widget in your own website

SCImago Graphica

powered by scimagojr.com 

[i](#) [x](#)

Submit Paper for Publication

IJFMR - Academic Journal
Open

Metrics based on Scopus® data as of April 2023



Submit Paper for Publication

IJFMR - Academic Journal

Open

D Dharmendra 3 years ago

Want to publish a case report i this journal, si please tell me about the process.
Thanks

reply



Melanie Ortiz 3 years ago

SCImago Team

Dear Dharmendra, thank you very much for your comment, we suggest you look for author's instructions/submission guidelines in the journal's website. Best Regards,
SCImago Team

J Jayalakshmi 3 years ago

I would like to know the charge for publishing the report

reply



Melanie Ortiz 3 years ago

SCImago Team

Dear Jayalakshmi,
thank you for contacting us.
We are sorry to tell you that SCImago Journal & Country Rank is not a journal. SJR is a portal with scientometric indicators of journals indexed in Elsevier/Scopus.
Unfortunately, we cannot help you with your request, we suggest you visit the journal's homepage (See fees/charges, if there are any) or contact the journal's editorial staff , so

Leave a comment

Name

Email

(will not be published)

I'm not a robot

reCAPTCHA
Privacy - Terms

Submit



ISSN 2210-2612

INTERNATIONAL JOURNAL OF SURGERY CASE REPORTS

Advancing surgery through shared experience



ERUDITIO • DILIGENTIA • FIDES

EST. 2003



ELSEVIER



International Journal of Surgery Case Reports

Editor-in-Chief

Professor David Rosin, Barbados, West Indies

Managing and Executive Editor

Dr Riaz Agha, London, UK

Assistant Managing Editor

Maliha Agha, London, UK

Senior Editors

Professor Hasan Alam, Michigan, USA
Professor Raafat Afifi, Cairo, Egypt
Dr Juan Barret, Barcelona, Spain
Mr Ben Challacombe, London, UK
Dr Xiaoping Chen, Wuhan, China

Dr Burcin Ekser, Indianapolis, USA
Professor Joseph W Y Lau, Shatin, Hong Kong
Dr Oliver Muensterer, New York, USA
Dr Selwyn Rogers, Galveston, Texas
Professor Jamsheer Talati, Karachi, Pakistan

Dr Mangesh Thorat, London, UK
Professor Fu Chan Wei, Tapei, Taiwan
Professor Rudy Leon De Wilde, Oldenburg, Germany

Associate Editors

Professor Roberto Coppola, Rome, Italy
Dr Veerappan Kasivisvanathan, London, UK
Dr Richard Keijzer, Winnipeg, Canada, USA
Dr Boris Kirshtein, Beer Sheva, Israel

Professor James McCaul, London, UK
Miss Emma McGlone, London, UK
Dr Dattatraya Muzumdar, Mumbai, India
Professor Andy Petroianu, Minas Gerais, Brazil

Mr Shahzad Raja, London, UK
Dr Kandiah Raveedran, Ipoh, Malaysia
Dr Daniel Yeh, Boston, USA

Assistant Editors

Dr Rafid Al-Mahfoudh, Oxford, UK
Dr Hussein Atta, Boston, USA
Dr Mohammad Bashashati, Texas, USA
Professor Somprakus Basu, Varanasi, India
Mr Andrew Beamish, Cardiff, UK
Dr Anthony Charles, North Carolina, USA
Dr Amitava Das, Hyderabad, India
Dr Brian Davis, Texas, USA
Dr Susana Adriana Esquivel, Córdoba, Mexico
Professor Sheng Feng, Shanghai, China

Dr Juan Gomez Rivas, Madrid, Spain
Dr Satoshi Ieiri, Kagoshima City, Japan
Dr Haytham Kaafarani, Massachusetts, USA
Dr Yogeesh Kamat, Karnataka, India
Mr Omar Khan, London, UK
Prof. Tsuyoshi Konishi, Osaka, Japan
Dr Vito A Mannacio, Naples, Italy
Dr Todd Manning, Oxford, UK
Dr Zubing Mei, Shanghai, China
Dr Umesh Metkar, Beth, Israel

Dr Indraneil Mukherjee, Staten Island, USA
Dr Enyi Ofo, Adelaide, South Australia
Dr Lena Perger, Albuquerque, USA
Professor Prathamesh S Pai, Mumbai, India
Dr Alfredas Smailys, Kaunas, Lithuania
Prof. Peter Hyunsuk Suh, Seoul, South Korea
Dr Dieter Weber, Perth, Australia
Dr John Wee, Boston, USA
Dr Honggyi Zhu, Shanghai, China

Statistical Editors

Dr Derek Cooper, London, UK
Professor Nora Donaldson, London, UK
Professor Mary W Gray, Washington DC, USA

Society Representative

Deniz Balci, Representative of the International Society of Liver Surgeons
Rhiannon Harries, President, Association of Surgeons in Training
Gene F. Coppa, President of the New York Surgical Society
Xiao-ping Chen, President of the Chinese Chapter of International Hepato-Pancreato-Biliary Association

Social Media Editor

Dr Riaz Agha, London, UK

Assistant Commissioning Editors

Ahmed Al-Jabir, London, UK
Zaid Alsafi, London, UK
Thomas Franchi, Sheffield, UK
Christos Iosifides, London, UK

Ahmed Kerwan, London, UK
Mehdi Khan, London, UK
Ginimol Matthew, London, UK
Maria Nicola, London, UK

Niamh O'Neill, London, UK
Catrin Sohrabi, London, UK

Executive Committee

Professor David Albala, New York, USA
Sir Graeme Catto, London, UK
Professor David Cooper, Pittsburgh, USA
Lord Ara Darzi, London, UK
Professor Harold Ellis, London, UK
Ather Enam, Karachi, Pakistan

Sir Barry Jackson, London, UK
Professor Arthur Li Kwok-Cheung, Wanchai, Hong Kong
Professor C H Leong, Central, Hong Kong
Lord Ian McColl, London, UK

John Norcini, Philadelphia, USA
Professor Susan Standing, London, UK
Lord Robert Winston, London, UK
Sir Magdi Yacoub, London, UK

Editorial Board

Raj Badwe
Mumbai, India
Michael Boscoe
Middlesex, UK
Rapheal Bueno
Boston, USA
Kris Chatamra
Bangkok, Thailand
Paul Coulthard
Manchester, UK
Anil d'Cruz
Mumbai, India
Mahesh Desai
Mumbai, India
Juan Gomez Rivas
Spain, Madrid

David W. Green
London, UK
Iraj Harirchi
Tehran, Iran
Doris Henne-Bruns
Ulm, Germany
Delawir Kahn
Cape Town, South Africa
Xiaoxi Lin
Shanghai, China
Ashok Mahapatra
New Delhi, India
Todd Manning
Melbourne, Australia
Indraneel Mittra
Mumbai, India

Vijay Naraynsingh
West Indies
Fabio Nicoli
London, UK
Anibal R. Núñez De Pierro
Buenos Aires, Argentina
Reuben Orda
Tel Aviv, Israel
Vladimir Semiglazov
St. Petersburg, Russia
Tejinder Singh
Ludhiana, India
Barbara L. Smith
Boston, USA
James Tatum
California, USA

Thehnton Udwardia
Mumbai, India
Martin R. Weiser
New York, USA
Yixin Zhang
Shanghai, China
Jun Zhong
Shanghai, China
Zhao-Fan Xia
Shanghai, China

Elsevier

Executive Publisher

Ash Allan, Oxford, UK

Administrative Editor

Josie Hutchins, Oxford, UK

Marketing Manager

Jayne Dawkins, Philadelphia, USA

Journal Manager

Tamsyn Hopkins, Exeter, UK

Senior Business Development Executive (Reprints)

Emma Steel, London, UK

Advertising Sales Manager

Robert Bayliss, London, UK

Account Manager (Supplements)

Evelina Euren, Amsterdam, the Netherlands

Project Manager Supplements & E-business

Mónica Hernández-Sesma, Amsterdam, the Netherlands

International Journal of Surgery Case Reports

Open access

Submit your article

Menu



Search in this journal

Volume 92

March 2022

Download full issue

[< Previous vol/issue](#)

[Next vol/issue >](#)

Receive an update when the latest issues in this journal are published

[Sign in to set up alerts](#)

Open access

Editorial Board

Article 106941

[View PDF](#)

Case Reports

Case report *Open access*

Radiotherapy alleviates spinal cord compression caused by solitary bone plasmacytoma: A case report

Zheng Chen, Shengrong Lin, Hongwei Zhu

Article 106816

[View PDF](#) [Article preview](#)

Case report *Open access*

Floating gallbladder in exomphalos minor an exceptional condition that should be considered, a case report

Gálvez Salazar Patricio, Luis M. Figueroa G, Solarte Henao Jorge, Helena Rincón Caicedo, ... Cristhian D. García Car

[FEEDBACK](#)

International Journal of Surgery Case Reports

Submit your article



Yi Liu, Yan Fu, Ling Fan

Article 106806

 [View PDF](#) Article preview 

Case report *Open access*

Inflammatory myofibroblastic tumour: case report of a rare form of bladder tumour

Balasingam Balagobi, Sreekanthan Gobishangar, Anusha Ginige, Dayal Gamlaksha, ... Loganathan Suvethini

Article 106786

 [View PDF](#) Article preview 

Case report *Open access*

Indocyanine green fluorescence angiography-guided simultaneous laparoscopic distal gastrectomy and spleen-preserving distal pancreatectomy for conserving the gastrosplenic ligament: A case report

Shun Kawaguchi, Satoshi Okubo, Shusuke Haruta, Junichi Shindoh, ... Masaki Ueno

Article 106803

 [View PDF](#) Article preview 

Case report *Open access*

A locally advanced pancreatic body cancer presenting common bile duct invasion resected via distal pancreatectomy after gemcitabine plus nab-paclitaxel chemotherapy: A case report

Hiroshi Kawasaki, Mayumi Hoshikawa, Yusuke Kyoden, Tatsuo Iijima, ... Junji Yamamoto

Article 106818

 [View PDF](#) Article preview 

Case report *Open access*

Severe malnutrition after single anastomosis sleeve jejunal bypass (SASJ) surgery due to a rare surgical complication: Report of the case

Seyed Hadi Mirhashemi, Azadeh Hakakzadeh, Armin Fateh

Article 106824

 [View PDF](#) Article preview 

Case report *Open access*

Clear cell sarcoma at D12-L1 paraspinal region: A reported case and review of the literature

Osama N. Dukmak, Ahmad M. Daqour, Ayman A. Salman, Asad M. Aldarawish, Izzeddin A. Bakri

Article 106825

International Journal of Surgery Case Reports

Submit your article



Case report *Open access*

Partial splenectomy after preoperative embolization in a patient with metastatic melanoma – A case report

Tobias Hauge, Eric Dorenberg, Mariusz Goscinski

Article 106837



[View PDF](#)

Article preview

Case report *Open access*

Bell clapper deformity in female?

Jayalaxmi Shripati Aihole

Article 106879



[View PDF](#)

Article preview

Case report *Open access*

Extensive thrombosis with amputation of digit I pedis dextra: A case report in Indonesian adult with type 2 diabetes mellitus

Andrew Adinata Rusli, Soebagijo Adi Soelistijo

Article 106853



[View PDF](#)

Article preview

Case report *Open access*

A case report of minimally invasive percutaneous ultrasound guided tuberculous iliopsoas abscess drainage in an immunocompromised patient

Allyzain Ismail, Neelam Ismail, Athar Ali, Shabbir Adamjee, ... Zainab Fidaali

Article 106867



[View PDF](#)

Article preview

Case report *Open access*

A case involving laparoscopic decortication of a large simple renal cyst using conventional monopolar device

Kota Kobayashi, Shuko Yoneyama, Eren Iwasa, Jurii Karibe, ... Akitoshi Takizawa

Article 106866



[View PDF](#)

Article preview

Case report *Open access*

Peritonitis caused by group A streptococcus: A case report and literature review

Fusao Sumiyama, Tatsuma Sakaguchi, Keigo Yamamichi, Mitsugu Sekimoto



Case report

Extensive thrombosis with amputation of digit I pedis dextra: A case report in Indonesian adult with type 2 diabetes mellitus

Andrew Adinata Rusli, Soebagijo Adi Soelistijo *

Department of Internal Medicine, Faculty of Medicine, Universitas Airlangga – Dr. Soetomo General Academic Hospital, Surabaya, Indonesia



ARTICLE INFO

Keywords:

Diabetes mellitus
Acute limb infection
Chronic limb ischemia
Thrombectomy

ABSTRACT

Background: Diabetes mellitus (DM) is a risk factor for vascularization disorders, especially in the lower extremity that causes acute limb infection (ALI) and chronic limb ischemia (CLI).

Case presentation: A 41-year-old man has acute limb ischemia, critical limb ischemia, and diabetes mellitus. Investigation results showed vascular disorders in the lower extremity area with necrosis of the digit I pedis dextra. The patient underwent retrograde and antegrade thrombectomy of the right to left femoral artery and amputation of the digit pedis.

Discussion: Thrombectomy is still effective for the management of extensive thrombosis. Amputation of necrotic tissue needs to be conducted immediately to prevent infection.

Conclusion: Vascular disorders in the extremities are an urgent health problem that requires immediate treatment because it prevents damage to the function of the lower extremities.

1. Introduction

Diabetes mellitus (DM) is a serious long-term condition with major impacts on the lives and well-being of individuals, families, and communities around the world. The number of DM patients is estimated at 463 million people globally, and it is estimated that the number will increase by 2030 [1,2]. Diabetes mellitus is a risk factor for venous thrombosis, which several studies have shown that many DM patients have thrombosis and DM increases the risk of thrombosis by 1.4 times [3–5]. Thrombosis will block the flow of blood that supplies nutrients, oxygen, and drugs to the tissues. This disruption in perfusion causes tissue death, making it easier for bacteria to grow and thrive in necrotic tissue. Over time, amputation will be one of the solutions in diabetic patients with foot ulcers [6,7]. Based on the above explanation, we were interested in reporting a case of extensive thrombosis in an Indonesian male with DM who had his toe amputated, in which the report used the Surgical Case Report (SCARE) 2020 guidelines [8].

2. Case presentation

A 41-year-old man with complaints of diarrhea >5 times a day with yellow-brown stools, little pulp, no smell, no mucus, and blood and pain

in the abdomen. The patient also had an injury on his right foot thumb that gradually made the nail black and painful so that he could not walk. The patient had a history of hypertension and type 2 diabetes mellitus (T2DM).

Laboratory results showed some partial abnormalities as follows: HbA1C = 7.2, Albumin = 3.1 mg/dL, Potassium = 2.9 mg/dL Sodium = 126 mg/dL, Chloride = 88 mg/dL, CRP = 17.3 mg/L, uric acid = 8.7 mg/dL, partial prothrombin time (PPT) = 18.9 s, and activated partial thromboplastin time (APTT) = 31.8 s. Blood gas analysis examination of arterial blood pH: 7.51, SaO₂ = 94–100%, PaO₂ = 82 mmHg, PaCO₂ = 34 mmHg, Base excess (BE) = 4.1 mEq/L, Bicarbonate (HCO₃) = 27.1 mEq/L, SpO₂ = 100%. X-ray examination revealed no abnormalities. CT results showed very weak lower extremity vascularization (Fig. 1). The patient was diagnosed with Acute Limb Infection (ALI) in the left lower extremity and Chronic Limb Ischemia (CLI) in the right lower extremity and T2DM.

The patient was treated with a high-calorie, high-protein diet 2100 kcal/day, 1000 cc Wida KN2 infusion every 24 h, Ceftriaxone 1 g intravenous injection, Metamizole 1 g intravenous injection every 8 h, heparin pump 10 IU/kg BW/h, Dorner oral tablet 20 µg every 8 h, Cilostazole 50 mg oral tablet every 8 h, Allopurinol 100 mg oral tablet for treating gout, Lisinopril 5 mg oral tablet for hypertension, Concor 2.5

* Corresponding author at: Department of Internal Medicine, Faculty of Medicine, Universitas Airlangga – Dr. Soetomo General Academic Hospital, Jl. Mayjend Prof. Dr. Moestopo No. 6-8, Airlangga, Gubeng, Surabaya, East Java 60286, Indonesia.

E-mail address: soebagijo1121@gmail.com (S.A. Soelistijo).

<https://doi.org/10.1016/j.ijscr.2022.106853>

Received 5 December 2021; Received in revised form 21 February 2022; Accepted 22 February 2022

Available online 25 February 2022

2210-2612/© 2022 The Authors. Published by Elsevier Ltd on behalf of IJS Publishing Group Ltd. This is an open access article under the CC BY-NC-ND license

(<http://creativecommons.org/licenses/by-nc-nd/4.0/>).

mg oral tablet, Attapulgit 2 oral tablet every 8 h for diarrhea, Omeprazole 20 oral tablet mg every 12 h.

The patient underwent emergency surgery for retrograde and antegrade thrombectomy of the right to left femoral artery [9] that consisted of arteriotomy of the right to the left femoral artery, followed by retrograde thrombectomy on the right to left femoral artery along ± 35 cm with Fogarty number 5, obtained a hard thrombus of ± 8 cm. Moreover, an antegrade thrombectomy was conducted on the right to left femoral artery with a length of ± 20 cm with Fogarty number 3, obtained a thrombus of ± 10 cm. Each thrombectomy was performed 3 times, the flow was present after each thrombectomy, but it weakened again. Subsequently, a lower-extremity amputation procedure (digit I pedis destra) was performed [10]. The condition of the patient's legs before and after the amputation can be seen in Fig. 2.

Examination of the extremities after surgery was found to be warm, dry, red, and no edema. When conducting vascular evaluation in the lower extremity area, no palpable artery pulse was found. Meanwhile, palpable artery pulse was only found in the femoral artery when using Doppler. Moreover, further examinations showed hemoglobin (12.6 g/dL), Hematocrit (38.0%), Leukocytes (12.040/ μ L), Platelets (299,000/ μ L), blood sugar (117 mg/dL), creatinine (3.4 mg/dL), Albumin (2.89 mg/dL), Potassium (3.4 mg/dL), Sodium (135 mg/dL), Chloride (94 mg/dL), PPT (19.0 s), and APTT (54.3 s).

The patient was treated with Ceftriaxone 1 g intravenous injection every 12 h, Metamizole 1 g intravenous injection every 8 h, heparin pump 10 IU/kg BW/h, Dorner tablet 20 μ g every 8 h, Cilostazole 50 mg oral tablet every 12 h, Allopurinol tablet 100 mg orally. Warming right and left extremities and aortobifemoral bypass were also conducted.

3. Discussion

Surgical therapy for thrombotic cases of ALI includes thromboembolectomy with a balloon catheter (Fogarty), bypass surgery, and other adjuncts such as endarterectomy, patch angioplasty, and intraoperative thrombolysis. A combination of these techniques is often required. Surgical revascularization is preferred in patients with compromised limb conditions, suspected bypass infection, symptoms of occlusion lasting more than two weeks, or contraindications to thrombolysis [11]. In surgical intervention, a vertical incision exposes the common femoral artery and its branches. The location of the embolus in the bifurcation of the femoral artery can be detected by distally disappeared proximal femoral pulse. The artery is clamped and opened transversely over the branch. The thrombus is extracted by passing a Fogarty balloon catheter. This procedure is repeated until antegrade bleeding, indicating that the entire clot had been successfully extracted [12].

Medical therapy provided includes antithrombotic drugs which are

classified into two groups, namely antiplatelet and anticoagulant. Antiplatelet inhibits platelet aggregation that will prevent thrombus formation in blood vessels. Antiplatelet drugs include thienopyridine (e.g. ticlopidine, clopidogrel, prasugrel, ticagrelor), aspirin, nonsteroidal anti-inflammatory drugs (e.g. abciximab, roxifiban, eptifibatide, tirofiban), protease-activated receptor 1 (PAR-1) inhibitors (e.g. vorapaxar) [13–15]. Anticoagulants inhibit thrombus formation by inhibiting the hemostatic cascade in the body. This group is divided into four classes, such as vitamin K antagonists, heparin derivatives, direct oral anticoagulant (DOAC)/novel oral anti-coagulant (NOAC) consisting of factor Xa inhibitors, and thrombin inhibitors [13,16]. The mechanism of action of various antithrombotic groups is to inhibit several specific pathways [11].

Antithrombotic therapy is basically given based on the type of thrombosis (arterial or venous) and the organ involved. Factors that should be considered are that the elderly often have lower lean body mass so that the dose should be calculated more carefully based on body weight. Second, the elderly are often accompanied by various comorbidities so that receiving large amounts of drugs will increase the risk of interactions with the antithrombotic drugs given. Therefore, therapy monitoring must be carried out more carefully on the dose, drug effects, or side effects of drugs [17,18].

4. Conclusion

A 41-year-old man has acute limb ischemia, critical limb ischemia, and T2DM. The results of the investigation show vascular disorders in the lower extremity area with necrosis of the digit I pedis destra. The treatment given is endovascular revascularization and medical therapy with heparin pump injection, cilostazol, uric acid control with allopurinol, lisinopril, and concor for hypertension control, attapulgit to treat diarrhea.

Consent

Written informed consent was obtained from the patient for publication of this case report and accompanying images. A copy of the written consent is available for review by the Editor-in-Chief of this journal on request.

Guarantor

Soebagijo Adi Soelistijo.

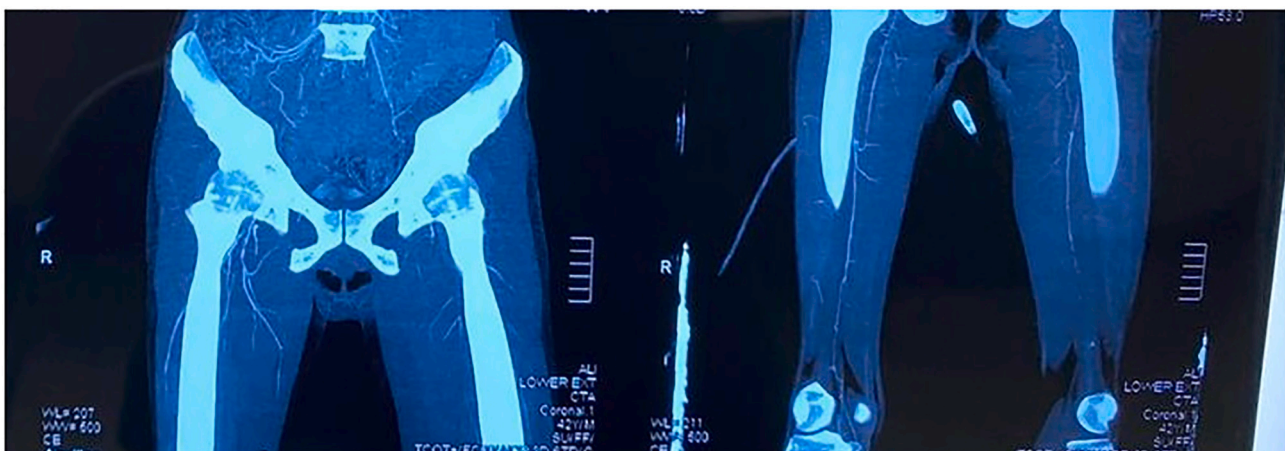


Fig. 1. CT Scan of the artery in the lower extremity.

a



b

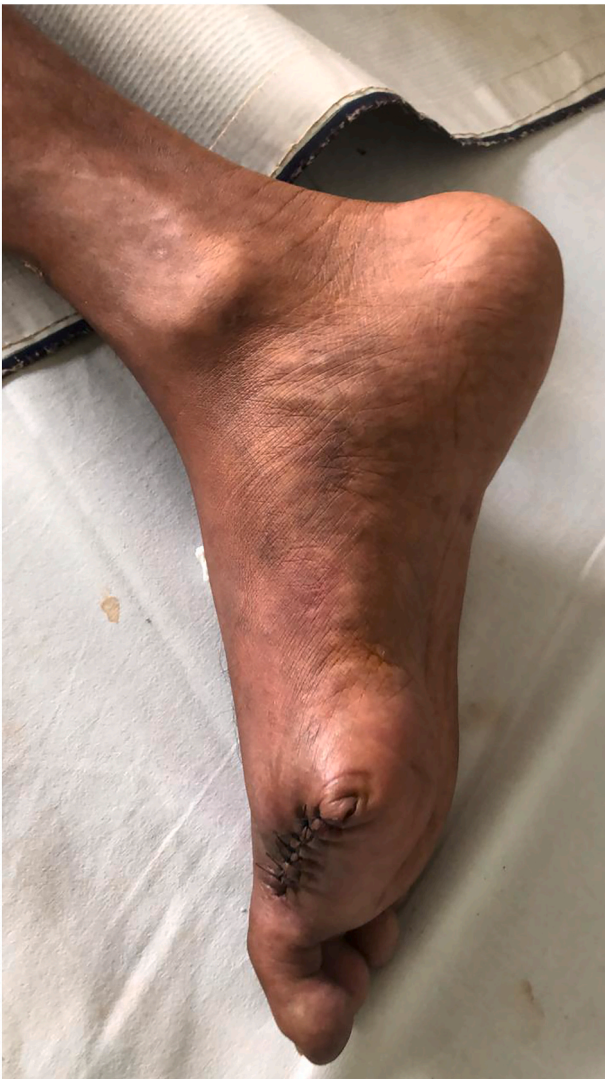

Fig. 2. Comparison of digit I pedis amputation before and after surgery.

Provenance and peer review

Not commissioned, externally peer-reviewed.

Sources of funding

None.

Ethical approval

Not applicable.

Credit authorship contribution statement

All authors contributed toward data analysis, drafting and revising the paper, gave final approval of the version to be published and agree to be accountable for all aspects of the work.

Declaration of competing interest

Andrew Adinata Rusli and Soebagijo Adi Soelistijo declare that they have no conflict of interest.

Acknowledgment

We would like to thank our editor “Fis Citra Ariyanto”.

References

- [1] P. Saeedi, I. Petersohn, P. Salpea, B. Malanda, S. Karuranga, N. Unwin, et al., Global and regional diabetes prevalence estimates for 2019 and projections for 2030 and 2045: Results from the International Diabetes Federation Diabetes Atlas, 9(th) edition, *Diabetes Res. Clin. Pract.* 157 (2019) 107843, <https://doi.org/10.1016/j.diabres.2019.107843>.
- [2] M.A.B. Khan, M.J. Hashim, J.K. King, R.D. Govender, H. Mustafa, Kaabi J. Al, Epidemiology of type 2 diabetes - global burden of disease and forecasted trends, *J. Epidemiol. Glob. Health* 10 (1) (2020) 107–111, <https://doi.org/10.2991/jegh.k.191028.001>.
- [3] J. Yuan, G.M. Xu, Early and late stent thrombosis in patients with versus without diabetes mellitus following percutaneous coronary intervention with drug-eluting stents: a systematic review and meta-analysis, *Am. J. Cardiovasc. Drugs* 18 (6) (2018) 483–492, <https://doi.org/10.1007/s40256-018-0295-y>.
- [4] J.A. Beckman, M.A. Creager, Vascular complications of diabetes, *Circ. Res.* 118 (11) (2016) 1771–1785, <https://doi.org/10.1161/circresaha.115.306884>.
- [5] Y. Mi, S. Yan, Y. Lu, Y. Liang, C. Li, Venous thromboembolism has the same risk factors as atherosclerosis: a PRISMA-compliant systemic review and meta-analysis, *Medicine* 95 (32) (2016), e4495, <https://doi.org/10.1097/md.0000000000004495>.
- [6] N. Vazzana, P. Ranalli, C. Cuccurullo, G. Davì, Diabetes mellitus and thrombosis, *Thromb. Res.* 129 (3) (2012) 371–377, <https://doi.org/10.1016/j.thromres.2011.11.052>.
- [7] N. Pechlivani, R.A. Ajjan, Thrombosis and vascular inflammation in diabetes: mechanisms and potential therapeutic targets, *Front. Cardiovasc. Med.* 5 (2018) 1, <https://doi.org/10.3389/fcvm.2018.00001>.
- [8] R.A. Agha, T. Franchi, C. Sohrabi, G. Mathew, A. Kerwan, The SCARE 2020 guideline: updating consensus Surgical CAse REport (SCARE) guidelines, *Int. J. Surg. (London, England)* 84 (2020) 226–230, <https://doi.org/10.1016/j.ijsu.2020.10.034>.
- [9] S. Cho, S.H. Lee, J.H. Joh, Complete revascularization of acute limb ischemia with distal pedal access, *Vasc. Endovasc. Surg.* 54 (1) (2020) 69–74, <https://doi.org/10.1177/1538574419873177>.
- [10] S.A. Domingos, C.N. França, I. Tuleta, M. Rezende Barbosa, Bachi ALL, L.M. Neves, Self-care in type 2 diabetes patients with urgency lower limb amputation: the influence of sex, marital status and previous amputations 15 (2021) 1083–1090, <https://doi.org/10.2147/ppa.S298537>.
- [11] J. Vojacek, Clinical monitoring of the antithrombotic treatment, *Cor Vasa* 54 (2) (2012) e97–e103, <https://doi.org/10.1016/j.crvasa.2012.01.012>.
- [12] J. Bath, J. Hartwig, V.Y. Dombrovskiy, T.R. Vogel, Trends in management and outcomes of vascular emergencies in the nationwide inpatient sample, *VASA Zeitschrift für Gefasskrankheiten* 49 (2) (2020) 99–105, <https://doi.org/10.1024/0301-1526/a000791>.
- [13] R.D. Acosta, N.S. Abraham, V. Chandrasekhara, K.V. Chathadi, D.S. Early, M. A. Eloubeidi, et al., The management of antithrombotic agents for patients undergoing GI endoscopy, *Gastrointest. Endosc.* 83 (1) (2016) 3–16, <https://doi.org/10.1016/j.gie.2015.09.035>.

- [14] M.P. Bonaca, P.G. Steg, L.J. Feldman, J.F. Canales, J.J. Ferguson, L. Wallentin, et al., Antithrombotics in acute coronary syndromes, *J. Am. Coll. Cardiol.* 54 (11) (2009) 969–984, <https://doi.org/10.1016/j.jacc.2009.03.083>.
- [15] P.G. Chassot, C. Marcucci, A. Delabays, D.R. Spahn, Perioperative antiplatelet therapy, *Am. Fam. Physician* 82 (12) (2010) 1484–1489.
- [16] J.L. Mega, T. Simon, Pharmacology of antithrombotic drugs: an assessment of oral antiplatelet and anticoagulant treatments, *Lancet (London, England)* 386 (9990) (2015) 281–291, [https://doi.org/10.1016/s0140-6736\(15\)60243-4](https://doi.org/10.1016/s0140-6736(15)60243-4).
- [17] G. Siasos, G. Skotsimara, E. Oikonomou, M. Sagris, M. Vasiliki-Chara, E. Bletsas, et al., Antithrombotic treatment in diabetes mellitus: a review of the literature about antiplatelet and anticoagulation strategies used for diabetic patients in primary and secondary prevention, *Curr. Pharm. Des.* 26 (23) (2020) 2780–2788, <https://doi.org/10.2174/1381612826666200417145605>.
- [18] R.A. Ajjan, N. Kietsiriroje, L. Badimon, G. Vilahur, D.A. Gorog, D.J. Angiolillo, et al., Antithrombotic therapy in diabetes: which, when, and for how long? *Eur. Heart J.* 42 (23) (2021) 2235–2259, <https://doi.org/10.1093/eurheartj/ehab128>.