



# Source details

## American Journal of Obstetrics and Gynecology

Scopus coverage years: from 1920 to Present

Publisher: Elsevier

ISSN: 0002-9378 E-ISSN: 1097-6868

Subject area: Medicine: Obstetrics and Gynecology

Source type: Journal

CiteScore 2022

14.3



SJR 2022

3.068



SNIP 2022

3.371



[View all documents >](#)

[Set document alert](#)

[Save to source list](#)

[CiteScore](#) [CiteScore rank & trend](#) [Scopus content coverage](#)

### i Improved CiteScore methodology



CiteScore 2022 counts the citations received in 2019-2022 to articles, reviews, conference papers, book chapters and data papers published in 2019-2022, and divides this by the number of publications published in 2019-2022. [Learn more >](#)

CiteScore 2022

$$14.3 = \frac{19,791 \text{ Citations 2019 - 2022}}{1,388 \text{ Documents 2019 - 2022}}$$

Calculated on 05 May, 2023

CiteScoreTracker 2023

$$15.9 = \frac{22,418 \text{ Citations to date}}{1,409 \text{ Documents to date}}$$

Last updated on 05 April, 2024 • Updated monthly

### CiteScore rank 2022


Category	Rank	Percentile
Medicine		
Obstetrics and Gynecology	#1/197	99th


[View CiteScore methodology >](#) [CiteScore FAQ >](#) [Add CiteScore to your site](#)

## American Journal of Obstetrics and Gynecology

### COUNTRY

[United States](#)

 Universities and research institutions in United States

 Media Ranking in United States

### SUBJECT AREA AND CATEGORY

[Medicine](#)  
[Obstetrics and Gynecology](#)

### PUBLISHER

[Elsevier Inc.](#)

### H-INDEX

**263**

### PUBLICATION TYPE

Journals

### ISSN

00029378, 10976868

### COVERAGE


1920-2023

### INFORMATION

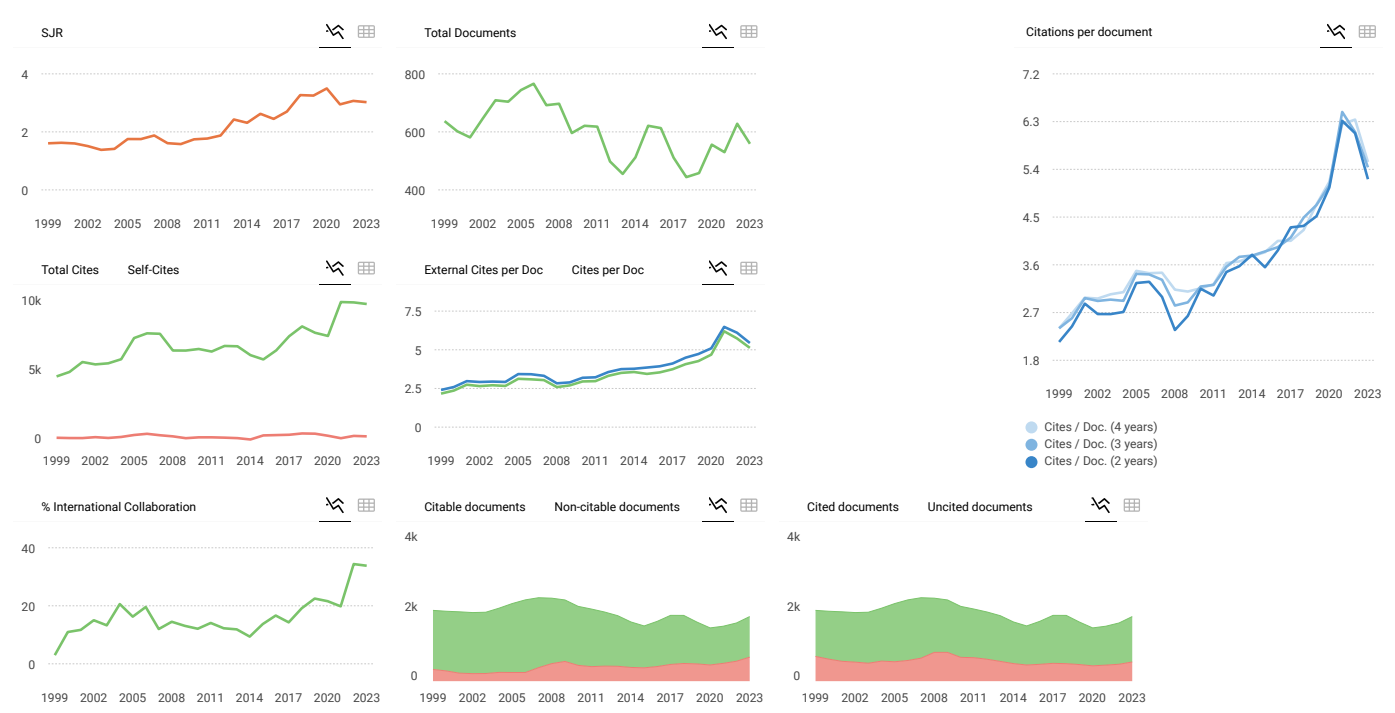
[Homepage](#)  
[How to publish in this journal](#)  
[Sandra.perrine@cox.net](mailto:Sandra.perrine@cox.net)

### SCOPE

The American Journal of Obstetrics and Gynecology, "The Gray Journal", covers the full spectrum of Obstetrics and Gynecology. The aim of the Journal is to publish original research (clinical and translational), reviews, opinions, video clips, podcasts and interviews that will have an impact on the understanding of health and disease and that has the potential to change the practice of women's health care. An important focus is the diagnosis, treatment, prediction and prevention of obstetrical and gynecological disorders. The Journal also publishes work on the biology of reproduction, and content which provides insight into the physiology and mechanisms of obstetrical and gynecological diseases.

 [Join the conversation about this journal](#)

- 1  
**Obstetrics and Gynecology**
- 2  
**Revue Sage - Femme**
- 3  
**American Journal of Perinatology**
- 4  
**Journal of Maternal-Fetal and Neonatal Medicine**
- 5  
**Journal of Perinatal Medicine**



**American Journal of Obstetrics and Gynecology**

Q1  
Obstetrics and Gynecology  
best quartile

SJR 2023  
3.02

powered by scimagojr.com

← Show this widget in your own website

Just copy the code below and paste within your html code:

```
<a href="https://www.scimagojr.com" style="color: #0070C0; text-decoration: none;">https://www.scimagojr.com
```

**SCImago Graphica**

Explore, visually communicate and make sense of data with our [new data visualization tool](#).

Metrics based on Scopus® data as of March 2024

D **Dr. K. sharmila Banu** 6 months ago  
Need Full publication in PDF  
  
reply

**Melanie Ortiz** 6 months ago

Dear Sharmila,  
Thank you for contacting us.  
We suggest you visit the journal's homepage or contact the journal's editorial staff , so they could inform you more deeply.  
Best Regards, SCImago Team

SCImago Team



ADVERTISEMENT



Search for...



# April 2024

Volume 6, Issue 4



Current Issue    Articles in Press    ●●●

Select all

Export citations

Email a colleague

Add to reading list

Register for eTOC alerts

## Volume 6, In Progress

### Systematic Review

The effects of probiotics administration during pregnancy on preeclampsia and associated maternal, fetal, and newborn outcomes: a systematic review and meta-analysis

Annie McDougall, Renae Nguyen, Phi-Yen Nguyen, ... Anne Ammerdorffer, A. Metin Almezoglu, Joshua P. Vogel



Published online: March 03, 2024

101322

[Open Access](#)

[Full-Text HTML](#) | [PDF](#) | [Supplemental Materials](#)

ADVERTISEMENT

## Original Research

### [Subcutaneous vs intravenous fentanyl for labor pain management: a multicenter randomized controlled trial](#)

Chatuporn Duangkum, Prapassara Sirikarn, Kiattisak Kongwattanakul, ... Rattana Komwilaisak, Suppasiri Hayagangchart, Pisake Lumbiganon

Published online: February 09, 2024

101310

[Open Access](#)

[Full-Text HTML](#) | [PDF](#) | [Supplemental Materials](#)

### [Randomized control trial comparing hygroscopic cervical dilators to cervical ripening balloon for outpatient cervical ripening](#)

Anjanique Mariquit R. Lu, Brenda Lin, Disha Shahani, ... Emily Nonnamaker, Joy Fest, Brigid McCue

Published online: February 26, 2024

101318

[Full-Text HTML](#) | [PDF](#)

### [Perinatal outcomes following abdominoplasty: a retrospective study and review of current literature](#)

CeCe Cheng, Scott A. Martin, Jaime A. Perez, Melissa I. March

Published online: March 03, 2024

101331

[Full-Text HTML](#) | [PDF](#)

### [The association between unintended hysterotomy extensions with cesarean delivery and subsequent preterm birth](#)

Giulia M. Muraca, Tzuria Peled, Abirami Kirubarajan, ... Hen Y. Sela, Sorina Grisaru-Granovsky, Misgav Rottenstreich

Published online: March 04, 2024

101326

[Open Access](#)

 [Full-Text HTML](#) | [PDF](#) | [Supplemental Materials](#)



[Furosemide to lower antenatal severe hypertension: a randomized placebo-controlled trial](#)

Melanie M. Maykin, Elizabeth Mercer, Kevin M. Saiki, Bliss Kaneshiro, Corrie B. Miller, Paid **ADVERTISEMENT**  
Jong Stacy Tsai

Published online: March 12, 2024

101348

[Full-Text HTML](#) | [PDF](#)

[Three-dimensional volume rendering ultrasound for assessing placenta accreta spectrum severity and discriminating it from simple scar dehiscence](#)

Theophilus K. Adu-Bredu, Robert Ridwan, Aditiawarman Aditiawarman, Grace Ariani, Sally L. Collins, Rozi A. Aryananda

Published online: March 06, 2024

101321

[Full-Text HTML](#) | [PDF](#) | [Supplemental Materials](#)

## Research Letters

[Regional differences in maternal-fetal medicine fellows' attitudes toward abortion-related training during fellowship](#)

CeCe Cheng, John J. Byrne, Brian S. Hernandez, Joel E. Michalek, Jennifer L. Kerns, Patrick S. Ramsey, Ashish Premkumar

Published online: February 17, 2024

101314

[Full-Text HTML](#) | [PDF](#)

[Abortion consideration and completion among people with a fetus affected with myelomeningocele: a single maternal-fetal surgical center experience](#)

Yuqi Bian, Steven T. Papastefan, Manmeet Singh, Joyceline A. Ito, William S. Marriott, Jessica T. Fry, Aimen F. Shaaban, Ashish Premkumar

Published online: February 23, 2024

101316

[Full-Text HTML](#) | [PDF](#)

 [redicting the need for medication in gestational diabetes using the 100-gram glucose tolerance test](#)



[Cardiovascular and obstetrical outcomes among delivering patients with Marfan or Loeys-Dietz syndrome: a retrospective analysis by hospital delivery setting](#)

Anna R. Whelan, Margaret M. Thorsen, Gretchen MacCarrick, Melissa L. Russo

Published online: March 07, 2024

101340

ADVERTISEMENT

[Full-Text HTML](#) | [PDF](#) | [Supplemental Materials](#)

[Obstetrical and neonatal outcomes in patients with surgically repaired heart disease](#)

Anne C. Laird, Allison R. Kumnick, Melissa H. Fries, Rebecca L. Chornock

Published online: March 02, 2024

101323

[Full-Text HTML](#) | [PDF](#)

<a href="#">Home</a>	<a href="#">Current Issue</a>	<b>FOR AUTHORS</b>	<a href="#">About this Journal</a>	<a href="#">Editorial Board</a>
<a href="#">Access for Developing Countries</a>	<a href="#">List of Issues</a>	<a href="#">Author Information</a>	<a href="#">Activate Online Access</a>	<a href="#">Pricing</a>
<b>ARTICLES &amp; ISSUES</b>	<b>COLLECTIONS</b>	<a href="#">Permissions</a>	<a href="#">Career Opportunities</a>	<a href="#">Reprints</a>
<a href="#">Articles in Press</a>	<a href="#">Evidence-Based Labor Management</a>	<a href="#">Submit</a>	<a href="#">Contact Information</a>	<a href="#">Sign up for eAlerts</a>
		<b>JOURNAL INFO</b>		<b>SUBSCRIBE</b>

---

**The content on this site is intended for healthcare professionals.**

---

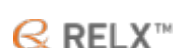We use cookies to help provide and enhance our service and tailor content. To update your cookie settings, please visit the [Cookie Settings](#) for this site.

All content on this site: Copyright © 2024 Elsevier Inc., its licensors, and contributors.

All rights are reserved, including those for text and data mining, AI training, and similar technologies.

For all open access content, the Creative Commons licensing terms apply.

[Privacy Policy](#) [Terms and Conditions](#) [Accessibility](#) [Help & Contact](#)





Search for...



## Editorial Board

### Editor-in-Chief

#### **Vincenzo Berghella, MD**

Thomas Jefferson University, Philadelphia, Pennsylvania, United States of America  
Prediction and Prevention of preterm birth, Labor, Delivery, Clinical obstetrics,  
Maternal-Fetal Medicine, Clinical trial design

### Deputy Editors

#### **Suneet P. Chauhan, M.D., Hon. D.Sc.**

The University of Texas Health Science Center at Houston John P and Katherine G  
McGovern Medical School, Houston, Texas, United States of America  
Abnormal fetal growth, Shoulder dystocia / neonatal brachial plexus palsy,  
Cesarean delivery, Amniotic fluid assessment

#### **Karin A. Fox, MD, MEd, FACOG, FAIUM**

The University of Texas Medical Branch at Galveston, Galveston, Texas, United  
States of America

Placenta Accreta Spectrum, Obstetrical hemorrhage, Complex cesarean  
delivery, Diabetes in pregnancy, Medical Education

#### **Adam K. Lewkowitz, MD, MPHS**

Brown University Warren Alpert Medical School, Providence, Rhode Island, United  
States of America

#### **Tracy Ann Manuck, MD, MS**

The University of North Carolina System, Chapel Hill, North Carolina, United States  
of America

Translational obstetrics, Pharmacogenomics, Obstetric epidemiology, Preterm  
Birth, Cervical insufficiency, Preeclampsia, Racial disparities in obstetrics

#### **Emily S. Miller, MD MPH**

Brown University, Department of Obstetrics & Gynecology, Providence, Rhode  
Island, United States of America  
Perinatal mental health, Perinatal infectious diseases, Perinatal epidemiology,  
Cervical insufficiency

#### **Molly J. Stout, MD, MSCI**

University of Michigan, Ann Arbor, Michigan, United States of America  
preterm birth, epidemiology, hypertension

### Deputy Editor, Equity, Diversity and Inclusion

#### **Terri-Ann Bennett, MD**

Memorial Healthcare System, Hollywood, Florida, United States of America  
Equity, Diversity, Inclusion, Preterm Birth, Hypertension, Cardiac Arrest, Maternal  
Mortality, Placenta Accreta

### Trustworthiness Editor

#### **Amir Aviram, MD**

Sunnybrook Research Institute, Toronto, Ontario, Canada  
placental complications, multifetal gestations, maternal-fetal medicine

### Managing Editor



**Stacy Bolzenius**

Hilliard, Ohio, United States of America  
Obstetrics, Gynecology

**Statistical Editor****Erez Lenchner, PhD**

New York University, New York, New York, United States of America

ADVERTISEMENT Stats, Retrospective Data Analysis, RCT, Administrative Data, Data Mining, Computational Statistics

**Editorial Board Members****Jon F. R. Barrett, MBBch, MD, MRCOG, FRCSC**

McMaster University, Hamilton, Ontario, Canada

Chair Southern Obstetrical Network, Multiple Pregnancy, Quality and patient Safety, Pre term Birth, Pre Term Birth, Maternal Mortality

**Federica Bellussi, MD, PhD**

Thomas Jefferson University, Philadelphia, Pennsylvania, United States of America

Prenatal diagnosis, Intrapartum Ultrasound, Maternal Fetal Medicine, Nutrition in pregnancy

**Tsungai Chipato**

University of Zimbabwe

Harare, Zimbabwe, HIV in pregnancy, Hypertension in pregnancy, Prenatal diagnosis, Fetal ultrasound, Diabetes in pregnancy

**Annie Dude, MD, PhD**

The University of North Carolina at Chapel Hill, Chapel Hill, North Carolina, United States of America

HIV in pregnancy, Hypertension in pregnancy, Maternal morbidity and mortality, Diabetes in pregnancy

**Lorraine Dugoff, MD**

University of Pennsylvania, Philadelphia, Pennsylvania, United States of America

Reproductive genetics, Prenatal diagnosis, Fetal ultrasound, Hypertension in pregnancy, Translational obstetrics

**Tullio Ghi, Prof, PhD**

University of Parma, Department of Medicine and Surgery, Parma, Italy  
Prenatal diagnosis, Fetal growth disorders/Preeclampsia, Labor and delivery, Intrapartum surveillance, Intrapartum ultrasound

**Torre Halscott, MD, MS**

The Johns Hopkins University School of Medicine, Baltimore, Maryland, United States of America

ADVERTISEMENT Obstetric Critical Care, Labor and Delivery, Collaborative Care, Cervical Insufficiency, Healthcare Policy and Advocacy, Medical Education

**Judette Louis, MD, MPH**

University of South Florida, Tampa, Florida, United States of America

Obstructive sleep apnea, Maternal morbidity, Maternal mortality, Pregnancy as a window to cardiovascular health

**Jack Ludmir, MD**

Thomas Jefferson University, Philadelphia, Pennsylvania, United States of America

Cervical function in pregnancy, Preeclampsia, Vulnerable populations, Global clinical trials

**Dhanya Mackeen, MD MPH**

Geisinger Commonwealth School of Medicine Division of Maternal-Fetal Medicine, Scranton, Pennsylvania, United States of America

Labor & Delivery, Clinical obstetrics, Maternal-Fetal Medicine, Clinical trial design, Gestational weight gain and obesity, Diabetes in pregnancy

**Jennifer McIntosh, DO, MS**

Medical College of Wisconsin, Milwaukee, Wisconsin, United States of America

Maternal Fetal Medicine, Obstetrics, Prematurity, Cervical insufficiency, Preterm Labor, Preeclampsia and Hypertensive disorders of pregnancy, Hematologic Disorders of Pregnancy, Basic and Translational Obstetric/MFM research

**Mohamed Momtaz, M.B., B.Ch., M.Sc, M.D.**

Cairo University Kasr Alainy, Faculty of Medicine, Cairo, Egypt

Prenatal Ultrasound, High risk Obstetrics, Fetal Medicine and Surgery, Maternal and Fetal Medicine

**Katsufumi Otsuki, MD, PhD**

Showa University Koto Toyosu Hospital, Koto-Ku, Japan  
Prediction and Prevention of preterm birth, Labor, Delivery, Clinical obstetrics,  
Maternal-Fetal Medicine, Cervical insufficiency, Clinical trial design

**Mario Palermo, MD**

University of Buenos Aires, Buenos Aires, Argentina  
Obstetrics, Gynecology, Perinatology, Fetal Medicine and ultrasonography

**Liona C. Poon, MD**

ADVERTISEMENT  
The Chinese University of Hong Kong, Department of Obstetrics and Gynaecology,  
Hong Kong SAR, Hong Kong, China  
Preeclampsia, Preterm birth, Fetal growth restriction, Stillbirth, Prenatal  
diagnosis, Fetal malformation, Intrapartum ultrasound, Clinical trials

**Uma M. Reddy, MD, MPH**

Yale University, Department of Obstetrics Gynecology and Reproductive Sciences,  
New Haven, Connecticut, United States of America  
Clinical trials, Perinatal epidemiology, Stillbirth, Preterm birth, Neonatal  
outcomes, Racial disparity in pregnancy outcomes, Labor management, Maternal  
morbidity and gestational diabetes

**Patrick Rozenberg, Professor**

American Hospital of Paris, Neuilly sur Seine, France  
Labor, Delivery, Induction of labor, Cesarean delivery, Intrapartum  
ultrasound, Preterm birth, Cervical insufficiency, Postpartum Hemorrhage, Placenta  
Accreta

**Stephen Rulisa, MD, PhD**

University of Rwanda  
Butare, Rwanda

**Gabriele Saccone, MD**

University of Naples Federico II, School of Medicine, Department of Neuroscience,  
Reproductive Sciences and Dentistry, Napoli, Italy  
Fetal malformation, Preterm birth, Infection in pregnancy, Meta-analysis /  
statistics, Autoimmune disease

**Neil Silverman, MD**

University of California Los Angeles David Geffen School of Medicine, Los Angeles,

California, United States of America  
Infectious diseases in pregnancy, Hematologic disorders and thrombophilias in  
pregnancy, Recurrent pregnancy loss, Drugs and pharmacology in  
pregnancy, Medical ethics

**Teresa Sparks, MD, MAS**

University of California San Francisco, San Francisco, California, United States of  
America  
fetal anomalies, hydrops fetalis, prenatal diagnosis, next generation  
ADVERTISEMENT  
sequencing, fetal intervention, maternal genetic disease, cell free DNA, prenatal  
genetic screening

**Walfrido Sumpaico, MD, FPOGS, FRCOG (Hon)**

Manila Central University, National Capital Region, Philippines  
Preeclampsia, Early Pregnancy Loss, Preterm Labor, Normal and Abnormal  
Labor, Postpartum Hemorrhage

**Jorge Tolosa, MD**

Oregon Health & Science University, Portland, Oregon, United States of America  
Hypertension in pregnancy, Preterm birth, Post partum hemorrhage, Ultrasound,  
Environmental exposures in pregnancy, Global Health.

**Erika F. Werner, MD, MS**

Women & Infants Hospital of Rhode Island, Providence, Rhode Island, United  
States of America  
Diabetes in pregnancy, Preeclampsia, Operative Deliveries, Labor & Delivery,  
Postpartum Care, Cost effectiveness

**Blair Wylie, MD MPH**

Global health, Reproductive Environmental Health, Epidemiology, Obstetric  
infectious disease

**Social Media Committee**

**Chair**

**Daniele Di Mascio, MD**

University of Rome La Sapienza, Roma, Italy

## Social Media Committee

### **Leen Alhafez, MD**

Thomas Jefferson University Hospital, Philadelphia, Pennsylvania, United States of America

### **Martina Ayad, MD**

The University of Texas Health Science Center at Houston, Houston, Texas, United States of America

ADVERTISEMENT

### **Carole Barake, MD**

The University of Texas Medical Branch at Galveston, Galveston, Texas, United States of America

### **Jaime Bastian, PharmD**

CSL Behring LLC, King Of Prussia, Pennsylvania, United States of America

### **Nathan Blue, MD**

The University of Utah, Salt Lake City, Utah, United States of America

### **Noelle Breslin, MD**

Columbia University, New York, New York, United States of America

### **Luigi Carbone, PhD**

University of Naples Federico II, Napoli, Italy

### **Georgios Doulaveris, MD**

Albert Einstein College of Medicine, Montefiore Medical Center, Bronx, New York, United States of America

### **Vicki Greenberg, MD**

Yale University, New Haven, Connecticut, United States of America

### **Yu Gu, PhD**

Peking Union Medical College Hospital, Department of Obstetrics and Gynecology, Beijing, China

### **Fabiana Interlandi, MD**

Magna Graecia University of Catanzaro, Catanzaro, Italy

### **Gabrielle Kattan, MD**

East Carolina University, Greenville, North Carolina, United States of America

### **Shilpi Mehta-Lee, MD**

New York University Grossman School of Medicine, New York, New York, United States of America

### **Claudiana Olivieri, MD**

Fetal Medicine, Di Venere H, Bari, Italy., Italy

ADVERTISEMENT

### **Sarah Pachtman, MD**

Northwell Health, New Hyde Park, New York, United States of America

### **Antonio Schiattarella**

University of Campania Luigi Vanvitelli, Department of Women and Children and General and Specialized Surgery, Naples, Italy

### **Filomena Sileo, MD**

University of Modena and Reggio Emilia, Modena, Italy

### **Tiffany Tonismae, MD**

Johns Hopkins All Children's Hospital, Saint Petersburg, Florida, United States of America

### **Jordan Winebrenner**

Edward Via College of Osteopathic Medicine - Carolinas Campus, Spartanburg, South Carolina, United States of America

### **Jessica Young, MD**

Fairbanks, United States of America

## Editorial Fellows

### **Sarah Boudova, MD, PhD**

Thomas Jefferson University, Philadelphia, Pennsylvania, United States of America

### **Laurie Griffin**

Women & Infants Hospital of Rhode Island, Providence, Rhode Island, United States of America

**Carolina Martinez-King, MD, MAS**

University of Washington, Seattle, Washington, United States of America

**John Soehl**

Women & Infants Hospital of Rhode Island, Providence, Rhode Island, United States of America

**Virginia Watkins, MD**

Duke University, Durham, North Carolina, United States of America

ADVERTISEMENT

**Tiffany Yang**

Stony Brook University, Stony Brook, New York, United States of America

**Former Editorial Fellows**

**2022**

**Advaita Punjala, MD**

Wake Forest University, Winston-Salem, North Carolina, United States of America

**Cece Cheng, MD**

The University of Texas Health Science Center at San Antonio, San Antonio, Texas, United States of America

**Brock Polnaszek, MD**

Brown University, Providence, Rhode Island, United States of America

**Jenny Mei, MD**

University of California Los Angeles, Los Angeles, California, United States of America

**2021**

**Jennifer Kidd, MD, MPH**

NYU Langone Health, New York, New York, United States of America

**Matthew Janssen, MD**

University of Pennsylvania, Philadelphia, Pennsylvania, United States of America

**Barbara K. Neuhoff, MD**

The University of Texas Health Science Center at San Antonio, San Antonio, Texas, United States of America

ADVERTISEMENT

<a href="#">Home</a>	<a href="#">Current Issue</a>	<b>FOR AUTHORS</b>	<a href="#">About this Journal</a>	<a href="#">Editorial Board</a>
<a href="#">Access for Developing Countries</a>	<a href="#">List of Issues</a>	<a href="#">Author Information</a>	<a href="#">Activate Online Access</a>	<a href="#">Pricing</a>
<b>ARTICLES &amp; ISSUES</b>	<a href="#">Supplements</a>	<a href="#">Permissions</a>	<a href="#">Career Opportunities</a>	<a href="#">Reprints</a>
<a href="#">Articles in Press</a>	<b>COLLECTIONS</b>	<a href="#">Submit</a>	<a href="#">Contact Information</a>	<a href="#">Sign up for eAlerts</a>
	<a href="#">Evidence-Based Labor Management</a>	<b>JOURNAL INFO</b>		<b>SUBSCRIBE</b>

**The content on this site is intended for healthcare professionals.**

We use cookies to help provide and enhance our service and tailor content. To update your cookie settings, please visit the [Cookie Settings](#) for this site.

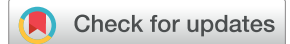All content on this site: Copyright © 2024 Elsevier Inc., its licensors, and contributors. All rights are reserved, including those for text and data mining, AI training, and similar technologies.

For all open access content, the Creative Commons licensing terms apply.

[Privacy Policy](#) [Terms and Conditions](#) [Accessibility](#) [Help & Contact](#)



# Three-dimensional volume rendering ultrasound for assessing placenta accreta spectrum severity and discriminating it from simple scar dehiscence



Theophilus K. Adu-Bredu, MSc; Robert Ridwan, MD; Aditiawarman Aditiawarman, MD; Grace Ariani, MD; Sally L. Collins, BMBCh, Dphil, FROCG; Rozi A. Aryananda, MD

**BACKGROUND:** Prenatal ultrasound discrimination between placenta accreta spectrum and scar dehiscence with underlying nonadherent placenta is challenging both prenatally and intraoperatively, which often leads to overtreatment. In addition, accurate prenatal prediction of surgical difficulty and morbidity in placenta accreta spectrum is difficult, which precludes appropriate multidisciplinary planning. The advent of advanced 3-dimensional volume rendering and contrast enhancement techniques in modern ultrasound systems provides a comprehensive prenatal assessment, revealing details that are not discernible in traditional 2-dimensional imaging.

**OBJECTIVE:** This study aimed to evaluate the use of 3-dimensional volume rendering ultrasound techniques in determining the severity of placenta accreta spectrum and distinguishing between placenta accreta spectrum and scar dehiscence with underlying nonadherent placenta.

**STUDY DESIGN:** A prospective, cohort study was conducted between July 2022 and July 2023 in the fetal medicine unit of Dr Soetomo Academic General Hospital, Surabaya, Indonesia. All pregnant individuals with anterior low-lying placenta or placenta previa with a previous caesarean section who were referred with suspicion of placenta accreta spectrum were consented and screened using the standardised 2-dimensional and Doppler ultrasound imaging. Additional 3-dimensional volumes were obtained from the sagittal section of the uterus with a filled urinary bladder. These were analyzed by rotating the region of interest to be perpendicular to the uterovesical interface. The primary outcomes were the clinical and histologic severity in the cases of placenta accreta spectrum and correct diagnosis of dehiscence with nonadherent placenta underneath. The strength of association between ultrasound and clinical outcomes was determined. Multivariate logistic regression analyses and diagnostic testing of accuracy were used to analyze the data.

**RESULTS:** A total of 70 patients (56 with placenta accreta spectrum and 14 with scar dehiscence) were included in the analysis. Multivariate logistic regression of all 2-dimensional and 3-dimensional signs revealed the 3-dimensional loss of clear zone ( $P<.001$ ) and the presence of bridging vessels on 2-dimensional Doppler ultrasound ( $P=.027$ ) as excellent predictors in differentiating scar dehiscence and placenta accreta spectrum. The 3-dimensional loss of clear zone demonstrated a high diagnostic accuracy with an area under the curve of 0.911 (95% confidence interval, 0.819–1.002), with a sensitivity of 89.3% (95% confidence interval, 78.1–95.97%) and specificity of 92.9% (95% confidence interval, 66.1–99.8%). The presence of bridging vessels on 2-dimensional Doppler demonstrated an area under the curve of 0.848 (95% confidence interval, 0.714–0.982) with a sensitivity of 91.1% (95% confidence interval, 80.4–97.0%) and specificity of 78.6% (95% confidence interval, 49.2–95.3%). A subgroup analysis among the placenta accreta spectrum group revealed that the presence of a 3-dimensional disrupted bladder serosa with obliteration of the vesicouterine space was associated with vesicouterine adherence ( $P<.001$ ).

**CONCLUSION:** Three-dimensional volume rendering ultrasound is a promising tool for effective discrimination between scar dehiscence with underlying nonadherent placenta and placenta accreta spectrum. It also shows potential in predicting the clinical severity with urinary bladder involvement in cases of placenta accreta spectrum.

**Key words:** bladder injury, cesarean hysterectomy, crystal vue, PAS disorders, placenta accreta, placenta previa, silhouette, tramline sign, 3D ultrasound

## Introduction

Placenta accreta spectrum (PAS) and uterine scar dehiscence with underlying nonadherent placenta are critical obstetrical conditions that require accurate prenatal diagnosis for optimal patient management. However, accurate prenatal discrimination between these 2

conditions remains difficult, which increases the risk of overtreatment and iatrogenic complications when scar dehiscence is mistaken for PAS.<sup>1,2</sup> The surgical morbidity associated with PAS is dependent on the placental location, extent of abnormal placental bed (focal or diffuse PAS), degree of neovascularization, and any involvement of surrounding pelvic structures.<sup>3,4</sup> In view of this, the management of PAS will be entirely different for each individual.<sup>3,5</sup> The hallmark of good PAS management is the involvement of a multidisciplinary team (MDT) approach with appropriate presurgical planning<sup>6,7</sup>; hence, detailed prenatal imaging is vital to prepare the

team for possible challenges.<sup>8</sup> Despite several advances in placental imaging research, there is currently no one method that can accurately predict intraoperative complications and potential morbidity. Consequently, surgeons may not be fully aware of the potential risks or may take unnecessary precautions with associated iatrogenic risks (such as putting in lines for interventional radiology or opening with a vertical abdominal incision). Better prediction of PAS severity would enable the appropriate precautions being taken preoperatively, while minimizing the potential for unnecessary iatrogenic morbidity.

**Cite this article as:** Adu-Bredu TK, Ridwan R, Aditiawarman A, et al. Three-dimensional volume rendering ultrasound for assessing placenta accreta spectrum severity and discriminating it from simple scar dehiscence. *Am J Obstet Gynecol MFM* 2024;6:101321.

2589-9333/\$36.00

© 2024 Elsevier Inc. All rights reserved.

<http://dx.doi.org/10.1016/j.ajogmf.2024.101321>

## AJOG MFM at a Glance

**Why was this study conducted?**

Accurate prenatal discrimination between scar dehiscence and placenta accreta spectrum (PAS) on prenatal ultrasound is often challenging, even among experts, which may lead to overtreatment and an increased risk of iatrogenic harm.

**Key findings**

This study proves the utility of 3-dimensional (3D) volume rendering ultrasound (VRU) for accurate prenatal discrimination between PAS and scar dehiscence with underlying nonadherent placenta. It also predicts the severity of PAS and involvement of the urinary bladder.

**What does this add to what is known?**

3D VRU with advanced contrast techniques provides detailed information for the uteroplacental and vesicouterine interfaces, which is useful in differentiating the scar dehiscence from PAS, as well as clinical severity of PAS with the involvement of the urinary bladder.

The advent of advanced 3-dimensional (3D) volume rendering ultrasound (VRU) techniques offers the opportunity for a detailed assessment of the uteroplacental bed and the vesicouterine interface. This technology has been embedded in most recent ultrasound machines and has been shown to provide further details that could not be seen with conventional 2-dimensional (2D) imaging.<sup>9–11</sup> However, only a few studies have investigated its use in prenatal screening for PAS.<sup>12–14</sup> In this study, we investigated the role of 3D VRU in distinguishing between scar dehiscence with a nonadherent placenta underneath and PAS and evaluating its utility in determining the severity and urinary bladder involvement in cases of PAS.

**Methods**

This prospective cohort study was conducted between July 2022 and July 2023 at the fetal medicine unit, Dr Soetomo Academic General Hospital, Surabaya, Indonesia. All pregnant individuals with previous caesarean delivery and a low-lying or previa placenta who were referred to our unit from peripheral hospitals on suspicion of PAS were approached, and an informed consent was obtained before participating in this study. Ethical approval was obtained from the institutional ethical review board in Dr Soetomo Academic General Hospital (1846/122/4/XII/2022). The study included patients with a diagnosis of scar dehiscence with a

nonadherent underlying placenta and PAS confirmed intraoperatively and histologically. Participants with uncomplicated placenta previa characterized by the absence of standardised ultrasound signs indicating high risk of PAS were excluded from our study.

Following local guidelines, all cases with the combination of previous cesarean delivery (CD) and placenta previa or low-lying placenta underwent a 2D transabdominal and transvaginal ultrasound examination, using the standardised imaging descriptors.<sup>15</sup> In accordance with our local guidelines, patients exhibiting more than 2 of these standardised 2D imaging signs were classified as a high risk of PAS. 3D VRU was obtained using Samsung Hera W10 (manufacturer: Samsung, location: Seoul, South Korea), GE voluson Expert 22 (manufacturer: GE healthcare, Location: Chicago, Illinois, USA), ultrasound systems to assess the uteroplacental bed and vesicouterine interface. Transabdominal VRU was performed with a full bladder (300–500 cc). The 3D volume rendering (12 × 6 cm) and scan angle (65°) provided a detailed focus of the uteroplacental interface and a clear 3D image of the area. After the area of suspected invasion was obtained on the 3D volume, dual screen imaging was selected (sagittal and 3D imaging) and the 3D VRU modes were used. The Z-axis panel was rotated to 90° from the Y-axis so that a clear view of the uteroplacental and uterovesical

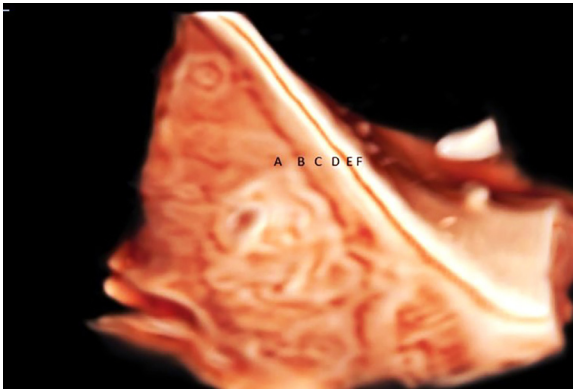
interface was obtained. The contrast, brightness, transparency, and gain were then adjusted to optimize the image for detailed assessment. The entire lower uterine segment was examined with this technique.

3D VRU was assessed for the following: retroplacental clear zone, “tramline sign,” urinary bladder wall, and vesicouterine space. The uteroplacental and vesicouterine interface underwent a thorough examination along the entire lower uterine segment to look for these features. The retroplacental clear zone was identified by the presence of a sonolucent space between the placenta and the uterine wall. The “tramline sign” was identified as the presence of hyperechoic parallel lines representing the hyperechoic uterine serosa and urinary bladder serosa with a smooth contour and a sonolucent vesicouterine space in between. The urinary bladder wall that presents as a hyperechoic line was assessed for continuity and evidence of disruption (Figure 1). The ultrasound examination was performed by an operator (R.A.) with enormous experience in PAS imaging. The imaging findings and video clips were independently assessed by a second operator (T.A.B.), and any discrepancies were resolved through discussion.

Clinical diagnosis of PAS was established by the failure of the placenta to spontaneously separate from the uterus after delivering the baby. The severity of the PAS was graded using the International Federation of Gynecology and Obstetrics (FIGO) classification as follows: grade 1, no obvious placental bulge or placenta tissue seen underneath the serosa with very minimal or no vascularity; grade 2, the appearance of bluish/purple discoloration, an obvious bulge, with the placenta not visible and hypervascularity on the serosa surface; grade 3a, thinned lower uterine segment with an obvious bulge with placenta visible and hypervascularity on the serosa surface; grade 3b, thinned lower uterine segment with hypervascularity and adherence to the urinary bladder; and grade 3c, placenta extending laterally to the broad ligament, lower parametrial aspect of the uterus



**FIGURE 1**  
Shows a 3D VRU image of an uncomplicated placenta previa



"A" represents the placenta "B" represents the retroplacental clear zone, "C" represents the myometrium, "D" represents the hyperechoic uterine serosa, "E" represents the sonolucent vesicouterine space, "F" represents the hyperechoic bladder serosa.

VRU, volume rendering ultrasound; 3D, 3-dimensional.

Adu-Bredu. 3D volume rendering ultrasound for placenta accreta spectrum assessment. *Am J Obstet Gynecol MFM* 2024.

with massive hypervascularity, with or without attachment with other surrounding organs.<sup>16</sup> Scar dehiscence with an underlying nonadherent placenta was defined as the presence of placenta underlying a transparent lower uterine segment with an obvious bulge,

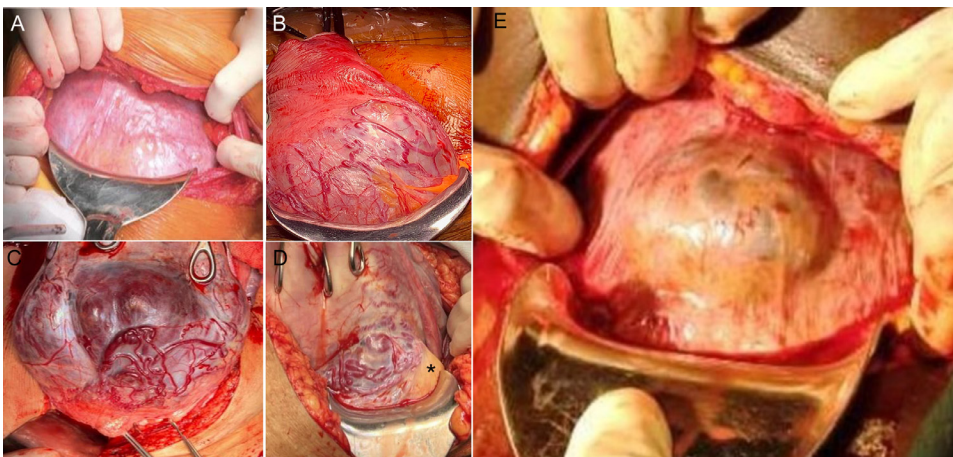
visible placenta, and absence of hypervascularity on the serosal surface and normal surrounding uterine tissue with spontaneous detachment of the placenta<sup>17</sup> (Figure 2).

The choice of the surgical approach used in both groups was based on the

intraoperative topographic classification.<sup>5</sup> One-step conservative surgery technique was performed when all of these 3 criteria were met: (1) complete separation of the bladder from the uterus, (2) at least 2 cm of healthy myometrium superior to the cervix, and (3) the size of affected area is less than 50% of the axial uterine circumference.<sup>18</sup> When all the 3 criteria were not met, a total hysterectomy was performed. Modified subtotal hysterectomy was reserved for cases where the PAS lesion was at the cervical trigonal area with extensive vesicouterine fibrosis.<sup>3</sup>

In the PAS cases, the excised specimen was inspected and a gentle digital dissection was attempted to identify the exact area of abnormal adherence for documentation and was marked for histopathologic analysis<sup>19</sup> (Figure 3). Histologic analysis of the specimen was performed and reported by a pathologist (G.A.) with experience in PAS. Histologic diagnosis of PAS was made based on the extent of placental villi invasion as follows: normal, placenta villi attached to an intervening decidua; accreta, the adherence of the villi directly to the myometrium without

**FIGURE 2**  
Shows the intraoperative appearances of the lower uterine segment

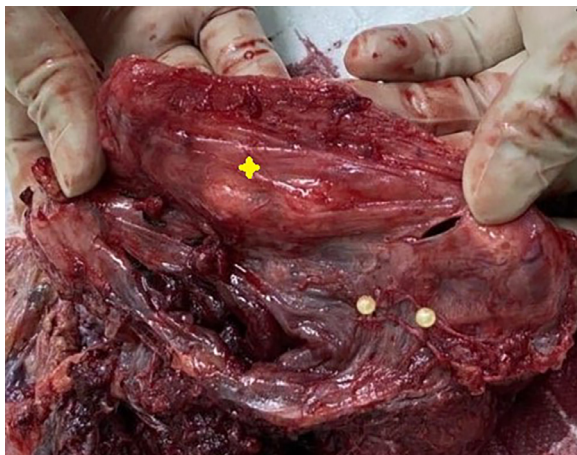

"A" represents grade 1; notice the absence of placental bulge or visualisation of placenta tissue underneath the serosa. "B" represents grade 2; notice the purple discoloration and massive neovascularization on the serosa surface. "C" represents grade 3a; notice the obvious placental bulge with the placenta visible underneath and importantly, neovascularization on the serosa surface. "D" represents grade 3b; notice the obvious bulge, neovascularization with the urinary bladder (\*) adherent to this area. "E" represents scar dehiscence with the placenta underneath; notice the obvious placenta bulge but the absence of neovascularity on the serosa surface and normal appearing surrounding myometrial tissue.

Adu-Bredu. 3D volume rendering ultrasound for placenta accreta spectrum assessment. *Am J Obstet Gynecol MFM* 2024.

FIGURE 3

Shows the postoperative gentle dissection of the placenta from the myometrial tissue to determine the exact suspicious area (marked yellow circle) for histologic analysis



Notice thinned and transparent myometrium (yellow cross) and dissected off the area. Also, the yellow circle indicates the area of abnormal attachment.

Adu-Bredu. 3D volume rendering ultrasound for placenta accreta spectrum assessment. *Am J Obstet Gynecol MFM* 2024.

intervening decidua; increta, deep villous invasion into the myometrium; and percreta, invasion of the villi beyond in to the serosa or beyond.<sup>16</sup>

### Statistical analysis

Data were collected and organized using Microsoft Excel (manufacturer: Microsoft cooperation, Redmond, Washington, USA) and the analysis was done using IBM SPSS (manufacturer: IBM, Chicago, Illinois, USA) software version 29. The Shapiro-Wilk normality test<sup>20</sup> was used to determine whether to use parametric or nonparametric statistical tests/methods regarding the test of validity of the research hypothesis. Categorical variables were expressed as frequencies and percentages in the table. Continuous or numeric variables were expressed as mean with their standard deviation if they are normally distributed and in median with their interquartile ranges if they are not normally distributed. Chi-square and Fisher's exact tests were used to determine the relationship between categorical variables. The independent *t* test or Mann-Whitney *U* test was used to compare means and mean rank differences. A univariate and multivariable logistic

regression was performed to identify the important ultrasound predictors of scar dehiscence with the nonadherent placenta underneath and PAS, as well as bladder involvement in PAS. Diagnostic test of accuracy of the ultrasound signs was assessed using the receiver operator characteristic curves. A 95% confidence interval (CI) with a *P* value of .05 was accepted as statistical significance.

### Results

The study recruited 82 pregnant individuals with a history of at least 1 previous CD, who presented with an anterior low-lying placenta or placenta previa. An ultrasound examination was conducted, and participants were followed up until delivery. Histologic confirmation was required for cases of PAS, whereas the diagnosis of scar dehiscence with underlying nonadherent placenta was made at laparotomy. Among these, there were 57 confirmed cases of PAS, 14 cases of scar dehiscence with nonadherent placenta underneath, and 11 cases of uncomplicated placenta previa. One case of PAS was excluded from our analysis owing to poor-quality ultrasound 3D image. All the cases of uncomplicated

placenta previa suspected on ultrasound had normal looking lower uterine segment and spontaneous placental detachment on laparotomy and were excluded from further analysis in accordance with our eligibility criteria and study objectives. Comprehensive information regarding patient characteristics, 2D and 3D ultrasound findings, intraoperative and histologic findings of confirmed cases of PAS, and scar dehiscence are presented in [Table 1](#).

Among the PAS cases, 12 were categorized as FIGO grade 1, 22 cases of grade 2, and 22 cases of grade 3 comprising 10 cases of grade 3A, 11 cases of grade 3B, and 1 case of grade 3C. Histologic examination of the area of abnormal adherence revealed 8 cases (14.3%) diagnosed as accreta, whereas 47 cases (83.9%) were identified as placenta increta. Only a single case was described as placenta percreta, which presented as a medical emergency owing to spontaneous uterine rupture resulting in massive hemoperitoneum.

Details on the 3D VRU signs in scar dehiscence with underlying nonadherent placenta and various clinical grades of PAS are presented in [Table 2](#). Multivariate logistic regression of all ultrasound indicators revealed the 3D loss of retroplacental clear zone (adjusted odds ratio [OR], 46.8 [95% CI, 4.872–449.59; *P*<.001]) and the presence of bridging vessels on 2D ultrasound (adjusted OR, 30.98 [95% CI, 1.47–652.2; *P*=.027]) as highly predictive in distinguishing PAS from scar dehiscence with a nonadherent placenta underneath ([Supplemental Table 3](#)). The diagnostic accuracy test for the 3D loss of retroplacental clear zone in differentiating PAS from scar dehiscence demonstrated an excellent area under the curve (AUC) of 0.911 (95% CI, 0.81–1.002) along with a sensitivity of 89.3% (95% CI, 78.1–95.97), specificity of 92.9% (95% CI, 66.1–99.8), positive likelihood ratio (LR+) of 12.5 (95% CI, 1.89–82.82), and negative likelihood ratio (LR–) of 0.12 (95% CI, 0.05–0.25). Similarly, the presence of bridging vessels clearly differentiates PAS from scar dehiscence with an AUC of 0.848 (95% CI, 0.714–0.982) with a sensitivity of 91.1% (95% CI, 80.4–97.0)



**TABLE 1**  
**Patient characteristics, ultrasound, intraoperative, and histologic findings**

Patient demographics	Dehiscence group (N=14)	PAS group (n=56)	P value
Maternal age (y) <sup>a</sup>	34.14±4.912	32.71±4.00	.327
Gravida <sup>b</sup>	3 (2–5)	3 (2–6)	.867
Para <sup>b</sup>	2 (1–3)	2 (1–5)	.539
Number of previous CD <sup>b</sup>	2 (1–2)	1 (1–3)	.679
GA ultrasound (complete weeks of GA) <sup>c</sup>	35 (IQR, 33–37)	34 (IQR, 32–35)	.079
GA surgery (complete weeks of GA) <sup>a</sup>	36 (IQR, 36–38)	35 (IQR, 34–37)	.05
Blood loss (mL) <sup>a</sup>	1200 (IQR, 500–2000)	2550 (IQR, 1500–3900)	<.001
Clinical FIGO PAS grading <sup>d</sup>			
Grade 1	N/A	12 (21.4%)	N/A
Grade 2	N/A	22 (39.3%)	N/A
Grade 3a	N/A	10 (17.9%)	N/A
Grade 3b	N/A	11 (19.6%)	N/A
Grade 3c	N/A	1 (1.8%)	N/A
Histology <sup>d</sup>			
Accreta	N/A	8 (14.3%)	N/A
Increta	N/A	47 (83.9%)	N/A
Percreta	N/A	1 (1.8%) <sup>e</sup>	N/A
2D and Doppler Ultrasound signs <sup>d</sup>			
Loss of clear zone	12 (85.7%)	50 (89.3%)	.656
Myometrial thickness <1 mm	14 (100%)	46 (82.1%)	.194
Placental bulge	4 (28.6%)	33 (58.9%)	.042
Abnormal lacunae	2 (14.3%)	40 (71.4%)	<.001
Lacunae feeding vessel	1 (7.1%)	34 (60.7%)	<.001
Subplacental hypervascularity	8 (57.1%)	54 (96.4%)	<.001
Uterovesical hypervascularity	3 (21.4%)	44 (78.6%)	<.001
Bridging vessels	3 (21.4%)	51 (91.1%)	<.001
3D volume rendering ultrasound features <sup>d</sup>			
3D loss of retroplacental clear zone	1 (7.1%)	50 (89.3%)	<.001
3D tramline disruption sign	0 (0)	33 (58.9%)	<.001
3D distorted bladder wall with obliterated vesicouterine space	0 (0)	11 (19.6%)	0.105

CD, cesarean delivery; IQR, interquartile range; FIGO, International Federation of Gynecology and Obstetrics; GA, gestational age; N/A, not available; PAS, placenta accreta spectrum; SD, standard deviation; 3D, 3-dimensional; 2D, 2-dimensional.

<sup>a</sup> Mean±standard deviation; <sup>b</sup> Median (range); <sup>c</sup> Median (interquartile range); <sup>d</sup> Frequency (percentage); <sup>e</sup> Presented clinically as a uterine rupture with placenta protruding through the defect. Adu-Bredu. 3D volume rendering ultrasound for placenta accreta spectrum assessment. *Am J Obstet Gynecol MFM* 2024.

and specificity of 78.6% (95% CI, 49.2–95.3), LR+ of 4.25 (95% CI, 1.55–11.63), and LR– of 0.11 (95% CI, 0.05–0.27).

Furthermore, among all the ultrasound makers, the 3D disrupted urinary bladder wall with obliterated vesicouterine space was the only predictor for

vesicouterine involvement with an OR of 27 (95% CI, 3.8–191.7;  $P<.001$ ) (Figure 4).

## Discussion

### Principal findings

We demonstrated that the absence of the retroplacental clear zone on 3D

VRU and presence of bridging vessels in 2D ultrasound are reliable markers for predicting the presence of PAS regardless of the severity and can effectively differentiate it from scar dehiscence with excellent sensitivity and specificity. Vesicouterine involvement (Grade 3B) that is mostly associated

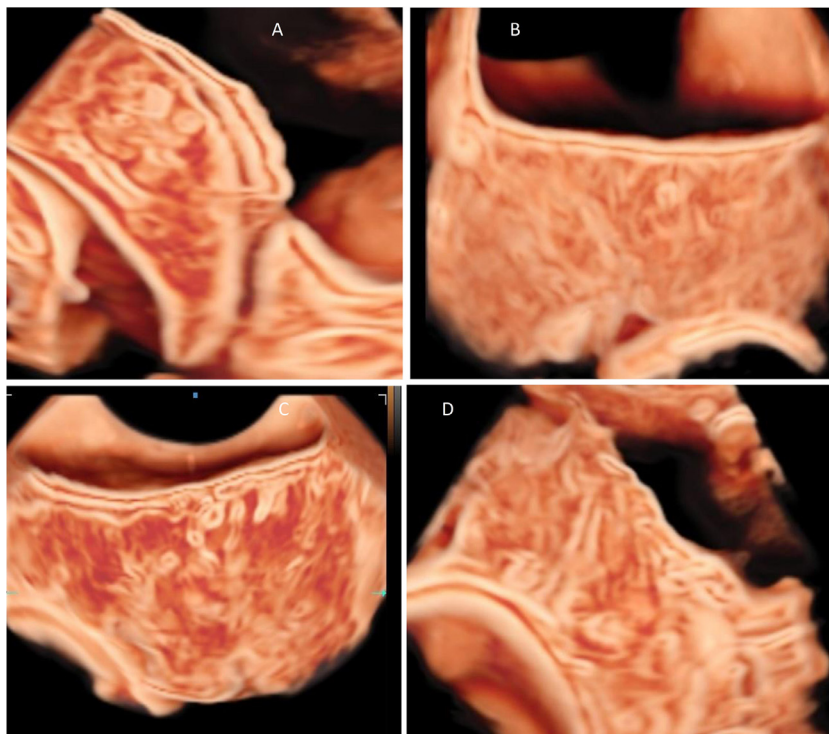
**TABLE 2**  
**3D VRU features of Scar dehiscence and various clinical grades of PAS**

3D VRU features	Dehiscence	Clinical classification of PAS group			P value for dehiscence vs grades 1 and 2	Grade 3 spectrum			P value of dehiscence vs grade 3
		Grade 1	Grade 2			3A	3B	3C	
3D loss of retroplacental clear zone	1 (7.1%)	11 (91.7%)	18 (81.8%)	<.001	9 (90%)	11 (100%)	1 (100%)	<.001	
3D disruption of “tramline sign”	0	2 (16.7%)	12 (54.5%)	.004	7 (70%)	11 (100%)	1 (100%)	<.001	
3D distorted bladder wall with obliterated vesicouterine space	0	0 (0)	1 (4.5%)	1.0	1 (10%)	8 (72.7%)	1 (100%)	.003	

PAS, placenta accreta spectrum; VRU, volume rendering ultrasound; 3D, 3-dimensional.

Adu-Bredu. 3D volume rendering ultrasound for placenta accreta spectrum assessment. *Am J Obstet Gynecol MFM* 2024.

**FIGURE 4**  
**Shows the various 3D VRU images**



“A” is a case of scar dehiscence; notice the presence of a retroplacental clear zone despite a thinned myometrium, a clear tramline sign, vesicouterine interface, and urinary bladder serosa. “B” is a case of low-grade PAS; notice the obliteration of the retroplacental clear zone but the preservation of the tramline sign, vesicouterine space, and smooth hyperechoic urinary bladder serosa. “C” is a case of grade 3a; notice the obliteration of the retroplacental clear zone and disruption of the tramline sign, but preservation of the vesicouterine space and smooth hyperechoic urinary bladder serosa. “D” is a case of grade 3b; notice the obliteration of the retroplacental clear zone, disruption of the tramline sign, and obliteration of the vesicouterine space and bladder serosa.

PAS, placenta accreta spectrum; VRU, volume rendering ultrasound; 3D, 3-dimensional.

Adu-Bredu. 3D volume rendering ultrasound for placenta accreta spectrum assessment. *Am J Obstet Gynecol MFM* 2024.

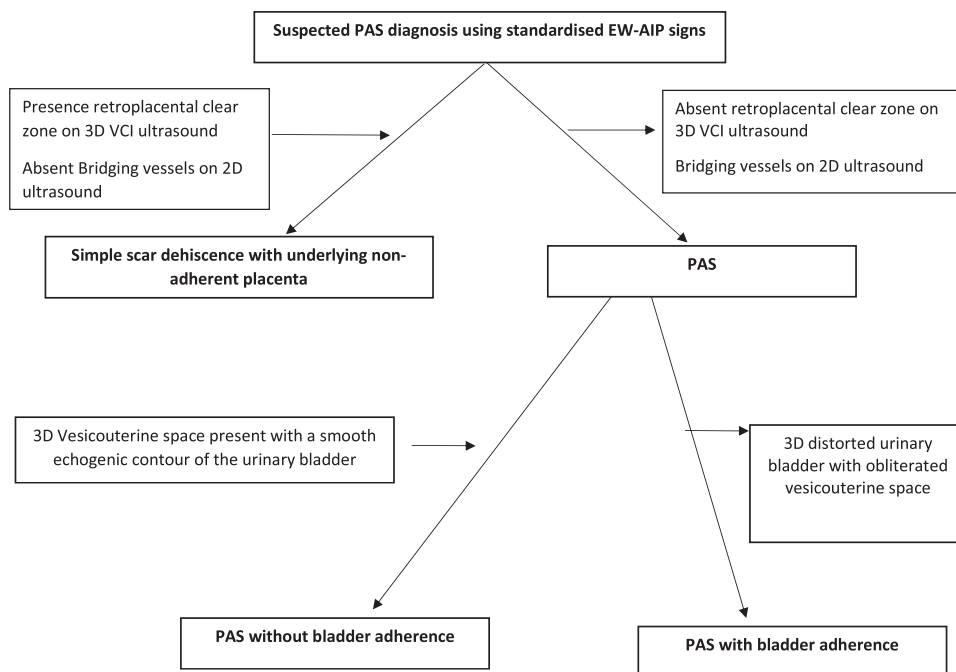
with varying degrees of urological injuries could be identified by the presence of 3D disrupted urinary bladder wall with obliterated vesicouterine space ( $P<.001$ ). A flowchart of ultrasound signs in assessing suspected cases of PAS is presented in [Figure 5](#).

### Results in the context of what is known and clinical implications

There is currently very little published literature on the prenatal ultrasound discrimination of scar dehiscence from PAS.<sup>1,21</sup> In PAS screening, the defining 2D imaging features in predicting abnormally invasive placentation are placenta bulge, presence of bridging vessels, abnormal placental lacunae and myometrial thinning.<sup>22,23</sup> However, owing to the comparable pathophysiology, 2 of these features are also seen in scar dehiscence with underlying nonadherent anterior placenta (see [Table 1](#)). In addition, the placenta by nature is a vascular organ and the presence of normal vasculature within or at the uteroplacental interface may be misdiagnosed as hypervascularity in high-risk cases.<sup>24</sup> Urinary bladder varicosities may also be mistaken as bridging vessels in nonaccreta previa.<sup>25,26</sup> Even though definitive diagnosis of PAS can only be made with the failure of placenta to separate after delivery, any attempt to manually remove the placenta could result in the rupture of uterus and neovasculature, which may cause massive, life-threatening hemorrhage.<sup>24</sup> This inevitably leads to

FIGURE 5

## Flowchart of ultrasound signs in scar dehiscence with nonadherent placenta underneath and PAS with or without bladder adherence



PAS, placenta accreta spectrum.

Adu-Bredu. 3D volume rendering ultrasound for placenta accreta spectrum assessment. *Am J Obstet Gynecol MFM* 2024.

anxiety in the accoucheur when scar dehiscence is mistakenly diagnosed as PAS on prenatal ultrasound imaging and may lead to aggressive management, which elevates the risks of iatrogenic morbidity.<sup>27</sup>

The presence of the retroplacental clear zone is often considered by experts to be the most direct and crucial indicator of normal placental separation.<sup>24,28,29</sup> This zone is believed to represent decidual glands and a convoluted network of basal arteries and terminal branches of the spiral arteries.<sup>30</sup> The absence of this sign in PAS cases has been attributed to the loss or deficiency of the Nitabuch's layer and probable fusion of the placenta and myometrium.<sup>19</sup> Despite the high sensitivity of this sign, its specificity on 2D ultrasound imaging has been questioned owing to its reliance on the resolution of the ultrasound equipment, operator-dependent image optimization techniques, and its susceptibility to the compressive effect of the probe.<sup>24,31</sup> In our study, the retroplacental clear zone was not visible in most cases of scar

dehiscence on 2D greyscale imaging despite the presence of a nonadherent placenta underneath (Table 1). This finding aligns with previous research.<sup>21,27</sup> However, leveraging the state-of-the-art advanced 3D volume rendering and contrast enhancement techniques, our study demonstrated clear visualisation of the retroplacental clear zone in scar dehiscence cases (Table 1). This capability enables accurate differentiation from PAS, regardless of its severity (Table 2).

During the assessment of the 3D uteroplacental interface in the PAS cases, the clear zone was evident in some areas whereas some areas showed the obliteration of this zone despite the noticeable thinning of the lower segment and extensive hypervascularity. This finding correlated with the evaluation of the gross specimen, where a careful digital dissection of the placenta revealed certain regions exhibiting clear separation, with overlaying thin uterine tissue, whereas other regions showed adherence (Figure 3). Our findings support the theory of the combination of PAS and scar

dehiscence in the same uterine bed.<sup>21,32</sup> Therefore, we hypothesize that the overlap of several 2D imaging features of PAS and scar dehiscence is not a coincidence. We believe that the currently recognized imaging descriptors for PAS<sup>15,23</sup> in literature may stem from the concurrent presence of dehiscence in most PAS cases involving the lower uterine segment. This may explain the lack of classical PAS features in reported upper uterine segment cases<sup>28,33,34</sup> and the incongruence between clinical and histologic correlation.

The predominant complication associated with PAS is the involvement of the urinary bladder wall to the abnormal area in the lower uterine segment, accompanied by significant neovascularization. Dealing with extensive bladder involvement can be challenging, even for skilled surgeons and an experienced MDT, which can result in various degrees of lower urinary tract damage.<sup>35–38</sup> Currently, 2D and Doppler ultrasound, as well as MRI, have not been proven to be reliable in identifying cases of urinary

bladder involvement.<sup>39,40</sup> Consequently, effective presurgical planning is not optimal. Findings of this study demonstrate the utility of 3D VRU in identifying vesicouterine adherence by examining the vesicouterine space and the urinary bladder serosa.

A notable finding from our study was the lack of correlation between the histologic and clinical PAS grading. Even in the most severe complication of PAS with extensive urinary bladder involvement, significant surgical difficulty, and higher blood loss, histologic findings were reported as either accreta or increta. The only case of percreta reported histologically in our series was a case of spontaneous uterine rupture. When considering this disparity, we believe that the most important factor for managing PAS is the clinical presentation at laparotomy. There have been several controversies about the underlying pathophysiology of PAS in recent years, with authors questioning the definition of percreta.<sup>32,41–43</sup> We believe the prediction of the topography of the lesion and surgical risk is of considerable benefit to the clinician and, ultimately, the wellbeing of the patient. This is particularly important given that postoperative histologic findings do not offer insights for subsequent management or contribute to patient care. This opinion is also shared by other experts on the topic.<sup>44,45</sup>

With the rapid increase in the caesarean delivery rate and subsequent rate of complications arising from them, improved antenatal diagnosis is vital. 3D VRU seems to be a promising tool for evaluating the uteroplacental bed and uterovesical fold where 2D ultrasound findings are uncertain. The flowchart presented in Figure 5 provides a simplified algorithm that could aid the fetal imaging expert in assessing suspected cases of PAS and predicting the surgical morbidity, which could be very valuable for adequate multidisciplinary preparation and appropriate management.

### Research implications

Given that this study was conducted in a single center, validation studies in the

form of large multicentre studies are recommended to establish the clinical utility of 3D VRU in routine obstetrical practice. In addition, further studies are recommended to assess the interoperator reliability of these 3D volume rendering techniques and image interpretation.

### Strengths and limitations

Since the claim of primacy has been removed, this statement is only a repetition of what has already been stated in the manuscript. Hence, it has been crossed out. A strength of this study is the incorporation of different ultrasound systems (Samsung Hera W10, GE Voluson Expert 22) during our evaluation, a crucial aspect that was not explored in previous studies on this topic. Hence, we envisage that this technique may be reproducible in similar ultrasound systems with advanced 3D contrast technology. Although our study has yielded promising results, we acknowledge that it is not without limitations. The study was conducted in a tertiary institution with a high PAS rate. Ultrasound examinations were performed by a single operator and corroborated by a second operator, possessing both substantial expertise in PAS imaging and proficiency in 3D volume rendering, manipulation, and interpretation. Consequently, the lack of assessment of interoperator reliability of this technique hinders our ability to generalize results.

### Conclusion

Accurate prenatal discrimination between scar dehiscence with an underlying nonadherent placenta and PAS can be achieved using 3D VRU. This imaging technique holds significant potential to improve diagnostic accuracy thereby facilitating improved preoperative planning. ■

### CRedit authorship contribution statement

**Theophilus K. Adu-Bredu:** Writing – review & editing, Writing – original draft, Formal analysis, Data curation, Conceptualization. **Robert Ridwan:** Writing – review & editing,

Investigation. **Adiawarman Aditiawarman:** Writing – review & editing, Methodology. **Grace Ariani:** Writing – review & editing, Investigation. **Sally L. Collins:** Writing – review & editing, Validation, Supervision. **Rozi A. Aryananda:** Writing – review & editing, Methodology, Investigation, Data curation, Conceptualization. ■

### Supplementary materials

Supplementary material associated with this article can be found in the online version at [doi:10.1016/j.ajogmf.2024.101321](https://doi.org/10.1016/j.ajogmf.2024.101321).

### References

1. Adu-Bredu TK, Owusu-Bempah A, Collins S. Accurate prenatal discrimination of placenta accreta spectrum from uterine dehiscence is necessary to ensure optimal management. *BMJ Case Rep* 2021;14:e244286.
2. Hussein AM, Fox K, Bhide A, et al. The impact of preoperative ultrasound and intraoperative findings on surgical outcomes in patients at high risk of placenta accreta spectrum. *BJOG* 2023;130:42–50.
3. Palacios-Jaraquemada JM, Nieto-Calvache AJ, Aryananda RA, Basanta N, Campos CI, Ariani G. Placenta accreta spectrum with severe morbidity: fibrosis associated with cervical-trigonal invasion. *J Matern Fetal Neonatal Med* 2023;36:2183741.
4. Palacios-Jaraquemada JM, Nieto-Calvache AJ, Aryananda RA, Basanta N. Placenta accreta spectrum into the parametrium, morbidity differences between upper and lower location. *J Matern Fetal Neonatal Med* 2023;36:2183764.
5. Palacios-Jaraquemada JM, Nieto-Calvache AJ, Aryananda RA, Basanta N. Advantages of individualizing the placenta accreta spectrum management. *Front Reprod Health* 2022;4:1096175.
6. Young H, Ehrig JC, Hammonds K, Hofkamp MP. Effect of a placenta accreta spectrum multidisciplinary team and checklist on maternal outcomes for planned hysterectomy at time of cesarean delivery. *Proc (Bayl Univ Med Cent)* 2022;35:755–8.
7. Einerson BD, Silver RM. Multidisciplinary teams in the management of placenta accreta spectrum disorders. *Curr Obstet Gynecol Rep* 2019;8:80–5.
8. Benavides-Calvache JP, Adu-Bredu T, Nieto-Calvache AJ. Prenatal placenta accreta spectrum diagnosis must go beyond confirming or ruling out the disease. *Am J Obstet Gynecol MFM* 2023;5:101079.
9. Santana EFM, Araujo Júnior E. Realistic view: a new three-dimensional surface rendering approach for the in utero visualization of embryos and fetuses. *Radiol Bras* 2019;52:172–3.



- 10.** Dall'Asta A, Paramasivam G, Lees CC. Crystal Vue technique for imaging fetal spine and ribs. *Ultrasound Obstet Gynecol* 2016;47:383–4.
- 11.** Dall'Asta A, Paramasivam G, Lees CC. Qualitative evaluation of Crystal Vue rendering technology in assessment of fetal lip and palate. *Ultrasound Obstet Gynecol* 2017;49:549–52.
- 12.** Aryananda RA, Akbar A, Wardhana MP, et al. New three-dimensional/four-dimensional volume rendering imaging software for detecting the abnormally invasive placenta. *J Clin Ultrasound* 2019;47:9–13.
- 13.** Dall'Asta A, Forlani F, Shah H, et al. Evaluation of the tramline sign in the prediction of placenta accreta spectrum and perioperative outcomes in anterior placenta previa. *Ultraschall Med* 2022;43:e118–24.
- 14.** Chen S, Chen Q, Du X, Chen S, Li W, Chen S. Value of Crystal Vue technique in detecting the placenta accreta spectrum located in C-section scar area. *Med Ultrason* 2020;22:438–44.
- 15.** Collins SL, Ashcroft A, Braun T, et al. Proposal for standardized ultrasound descriptors of abnormally invasive placenta (AIP). *Ultrasound Obstet Gynecol* 2016;47:271–5.
- 16.** Jauniaux E, Ayres-de-Campos D, Langhoff-Roos J, Fox KA, Collins S. FIGO Placenta Accreta Diagnosis and Management Expert Consensus Panel. FIGO classification for the clinical diagnosis of placenta accreta spectrum disorders. *Int J Gynaecol Obstet* 2019;146:20–4.
- 17.** Collins SL, Alemdar B, van Beekhuizen HJ, et al. Evidence-based guidelines for the management of abnormally invasive placenta: recommendations from the International Society for Abnormally Invasive Placenta. *Am J Obstet Gynecol* 2019;220:511–26.
- 18.** Nieto-Calvache AJ, Palacios-Jaraquemada JM, Aryananda R, et al. How to perform the one-step conservative surgery for placenta accreta spectrum move by move. *Am J Obstet Gynecol MFM* 2023;5:100802.
- 19.** Jauniaux E, Hussein AM, Zosmer N, et al. A new methodologic approach for clinico-pathologic correlations in invasive placenta previa accreta. *Am J Obstet Gynecol* 2020;222:379.. e1–11.
- 20.** Shapiro SS, Wilk MB. An analysis of variance test for normality (complete samples). *Biometrika* 1965;52:591–611.
- 21.** Hussein AM, Elbarmelgy RA, Elbarmelgy RM, Thabet MM, Jauniaux E. Prospective evaluation of the impact of post-cesarean section uterine scarification in the perinatal diagnosis of placenta accreta spectrum disorder. *Ultrasound Obstet Gynecol* 2022;59:474–82.
- 22.** Sargent W, Gerry S, Collins SL. A risk-prediction model for placenta accreta spectrum severity from standardized ultrasound markers. *Ultrasound Med Biol* 2023;49:512–9.
- 23.** Jauniaux E, D'Antonio F, Bhide A, et al. Modified Delphi study of ultrasound signs associated with placenta accreta spectrum. *Ultrasound Obstet Gynecol* 2023;61:518–25.
- 24.** Adu-Bredu TK, Rijken MJ, Nieto-Calvache AJ, et al. A simple guide to ultrasound screening for placenta accreta spectrum for improving detection and optimizing management in resource limited settings. *Int J Gynaecol Obstet* 2023;160:732–41.
- 25.** Adu-Bredu TK, Collins SL, Nieto-Calvache AJ. Ultrasound discrimination between placenta accreta spectrum and urinary bladder varices. *Aust N Z J Obstet Gynaecol* 2023;63:725–7.
- 26.** Warshafsky C, Corran B, Willner I, Warren J, Singh SS. Placenta previa and bladder varicosities—a clinical conundrum. *Am J Obstet Gynecol* 2022;227:533–4.
- 27.** Adu-Bredu TK, Owusu YG, Owusu-Bempah A, Collins SL. Absence of abnormal vascular changes on prenatal imaging aids in differentiating simple uterine scar dehiscence from placenta accreta spectrum: a case series. *Front Reprod Health* 2023;5:1068377.
- 28.** Adu-Bredu TK, Owusu YG. Prenatal diagnosis of focal placental invasion in upper uterine segment: is novel 'separation sign' key? *Ultrasound Obstet Gynecol* 2023;62:442–4.
- 29.** Allwood RX, Self A, Collins SL. Separation sign: novel ultrasound sign for ruling out diagnosis of placenta accreta spectrum. *Ultrasound Obstet Gynecol* 2022;60:390–5.
- 30.** Jauniaux E, Collins S, Burton GJ. Placenta accreta spectrum: pathophysiology and evidence-based anatomy for prenatal ultrasound imaging. *Am J Obstet Gynecol* 2018;218:75–87.
- 31.** Kennedy A, Griffith A, Einerson B, Woodward PJ. Pitfalls in sonographic evaluation of placenta accreta spectrum. *WFUMB Ultrasound Open* 2023;1:100016.
- 32.** Jauniaux E, Hecht JL, Elbarmelgy RA, Elbarmelgy RM, Thabet MM, Hussein AM. Searching for placenta percreta: a prospective cohort and systematic review of case reports. *Am J Obstet Gynecol* 2022;226:837. e1–13.
- 33.** Lo TK, Lam CHL, Cheung KW, Ng GHT, Wu AKP. Scaloping of placenta–myometrium interface on ultrasound in case with myomectomy scar. *Ultrasound Obstet Gynecol* 2016;47:518–22.
- 34.** Al-Serehi A, Mhoyan A, Brown M, Benirschke K, Hull A, Pretorius DH. Placenta accreta: an association with fibroids and Asherman syndrome. *J Ultrasound Med* 2008;27:1623–8.
- 35.** Friedrich L, Mor N, Weissmann-Brenner A, et al. Risk factors for bladder injury during placenta accreta spectrum surgery. *Int J Gynaecol Obstet* 2023;161:911–9.
- 36.** Abbas F, Talati J, Wasti S, Akram S, Ghafar S, Qureshi R. Placenta percreta with bladder invasion as a cause of life threatening hemorrhage. *J Urol* 2000;164:1270–4.
- 37.** Lucidi A, Jauniaux E, Hussein AM, et al. Urological complications in women undergoing cesarean section for placenta accreta spectrum disorders: systematic review and meta-analysis. *Ultrasound Obstet Gynecol* 2023;62:633–43.
- 38.** Jain N, Patwardhan S, Jain H, Patil B. Surgical strategies for placenta percreta invading the bladder and review of literature. *Afr J Urol* 2020;26:57.
- 39.** Familiari A, Liberati M, Lim P, et al. Diagnostic accuracy of magnetic resonance imaging in detecting the severity of abnormal invasive placenta: a systematic review and meta-analysis. *Acta Obstet Gynecol Scand* 2018;97:507–20.
- 40.** D'Antonio F, Iacovella C, Bhide A. Prenatal identification of invasive placentation using ultrasound: systematic review and meta-analysis. *Ultrasound Obstet Gynecol* 2013;42:509–17.
- 41.** Einerson BD, Comstock J, Silver RM, Branch DW, Woodward PJ, Kennedy A. Placenta accreta spectrum disorder: uterine dehiscence, not placental invasion. *Obstet Gynecol* 2020;135:1104–11.
- 42.** Jauniaux E, Hussein AM, Einerson BD, Silver RM. Debunking 20th century myths and legends about the diagnosis of placenta accreta spectrum. *Ultrasound Obstet Gynecol* 2022;59:417–23.
- 43.** Einerson BD, Kennedy A, Silver RM, Branch DW, Comstock J, Woodward PJ. Ultrasonography of the explanted uterus in placenta accreta spectrum: correlation with intraoperative findings and gross pathology. *Obstet Gynecol* 2023;141:544–54.
- 44.** Nieto-Calvache AJ, Palacios-Jaraquemada JM, Basanta N, Aryananda RA. How to differentiate intraoperatively between placenta accreta spectrum and uterine dehiscence? *BJOG* 2023;130:1288–90.
- 45.** Hussein AM, Fox K, Bhide A, Jauniaux E. Confirming the diagnosis of placenta accreta at birth: intraoperative and macroscopic findings are essential but not histology. *BJOG* 2023;130:1290–2.

## Author and article information

From the Nuffield Department of Women's and Reproductive Health, University of Oxford, United Kingdom (Mr Adu-Bredu and Prof Collins); Maternal Fetal Medicine, Obstetrics and Gynecology Department, Dr Soetomo Academic General Hospital, Universitas Airlangga, Surabaya, Indonesia (Dr Ridwan, Dr Aditiawarman, and Dr Aryananda); Anatomical Pathology Department, Dr Soetomo Academic General Hospital, Universitas Airlangga, Surabaya, Indonesia (Dr Ariani); Department of Obstetrics and Gynaecology, Erasmus, University Medical Center, Rotterdam, The Netherlands (Dr Aryananda).

Received Nov. 7, 2023; revised Feb. 17, 2024; accepted Feb. 25, 2024.

The authors report no conflict of interest.

Corresponding author: Rozi A. Aryananda, MD. rozi.odi@gmail.com