

Navigating Complex Cardiovascular Pathologies

by Yan Efrata Sembiring

Submission date: 11-May-2024 06:30AM (UTC+0800)

Submission ID: 2376376338

File name: Navigating_Complex_Cardiovascular_Pathologies.pdf (763.23K)

Word count: 3522

Character count: 19785



Case Report

Navigating Complex Cardiovascular Pathologies: A Case Report on Aortic Arch Replacement in a Middle-Aged Male with Stanford A De Bakery I Aortic Dissection

Muhammad Firdaus^{1*}, Saskia Dyah Handari^{2,4}, Yan Efrata Sembiring^{3,4}

¹Brawijaya Cardiovascular Research Center, Department of Cardiology and Vascular Medicine, Faculty of Medicine, Universitas Brawijaya, Malang, Indonesia.

²Department of Cardiology and Vascular Medicine, Faculty of Medicine, Universitas Brawijaya, Malang, Indonesia.

³Department of Thoracic Cardiac and Vascular Surgery, Faculty of Medicine, Airlangga University, Surabaya, Indonesia.

⁴Premier Hospital, Surabaya Indonesia.

ARTICLE INFO

ABSTRACT

Keyword :

Aortic Dissection;
Dissection Flap;
Total Aortic Arch Replacement.

Background: Aorta dissection is characterized by the presence of an intimal tear, which permits the passage of blood through the tear and into the aorta media. This process leads to the separation of the intimal and the formation of a dissection flap, representing the true lumen and a newly formed false lumens. The incidence of aortic dissection varies between 0.2% and 0.8%. Management of acute aortic standford A aortic dissection primarily involves invasive surgical procedures.

Case presentation: A middle-aged male patient, aged 40, who possesses risk factors including uncontrolled hypertension and obesity, arrived to the emergency room with symptoms of chest pain. He described the pain as tearing in nature and said that it radiated towards the abdominal. The examination findings included a blood pressure reading of 255/143, a widened mediastinum and cardiomegaly observed on the chest X-ray, a slight elevation in Hs-Troponin levels, and the presence of sinus rhythm with left ventricular hypertrophy. He underwent CT scan, which demonstrated the presence of an aortic dissection extending from the ascending to descending aorta, with no associated damage to the aortic valve from echocardiography. He was diagnosed with Standford A DeBakey I Aortic dissection and underwent preference replacement of the aortic arch and elephant trunk implantation instead of Bentall procedure.

Conclusion: The surgical and perioperative methods employed may differ based on the specific clinical presentation and the nature of the aortic disease. Because there was no involvement of the aortic valve, we performed total aortic arch replacement and elephant trunk procedure over the Bentall procedure.

1. Introduction

Acute aortic dissection is a rare and extremely dangerous condition that affects the aorta, resulting in significant morbidity and mortality. Acute type A aortic dissection (ATAAD) is commonly acknowledged as the most lethal variant of dissection, predominantly impacting the ascending aorta. Aortic dissection is distinguished by the existence of an intimal tear, which allows blood to flow past the tear and into the media layer of the aorta. This phenomenon induces the detachment of the intima layer and the subsequent creation of a dissection flap, leading to the separation of the genuine lumen from a recently developed pseudo lumen. Aortic dissection has been associated with a range of underlying medical conditions that increase the risk, including genetic disorders, inflammatory vasculitides, as well as other risks such as pregnancy, trauma, history of cardiac surgery, stimulant misuse, and infection.¹⁻³

ATAAD accounts for roughly 58-62% of the total occurrences of aortic dissections. The case-fatality rate of acute type A aortic dissection ATAAD is reported to be 73%, with over half of

all deaths happening prior to arrival at a healthcare facility. Historical records indicate that the prevalence of ATAAD has been shown to range from 2.5 to 6 occurrences per 100,000 patient years. Approximately two-thirds of instances involving aortic dissections are observed in males.^{1,3}

Aortic dissection presents with a wide range of symptoms, which are dependent on the underlying pathophysiological disruption. The primary presentation of an aortic dissection is characterized by the notable development of severe and sudden pain centered in the thorax, dorsal region, or abdominal region. Imaging modalities are of paramount importance in the diagnostic evaluation of aortic diseases, as they provide valuable information regarding the precise anatomical location, size, shape, and extent of pathological abnormalities affecting the aorta. The categorization of aortic dissection management is determined on the precise anatomical location of the condition. Type A necessitates surgical intervention, whereas type B, despite its intricate nature, can be efficiently addressed with pharmacological therapy.³

Total Aortic Arch Replacement is a surgical intervention that entails the complete substitution of the aortic arch, which refers to the

* Corresponding author at: Brawijaya Cardiovascular Research Center, Department of Cardiology and Vascular Medicine, Faculty of Medicine, Universitas Brawijaya, Malang, Indonesia.
E-mail address: muhfirdaus.dr@gmail.com (M. Firdaus).

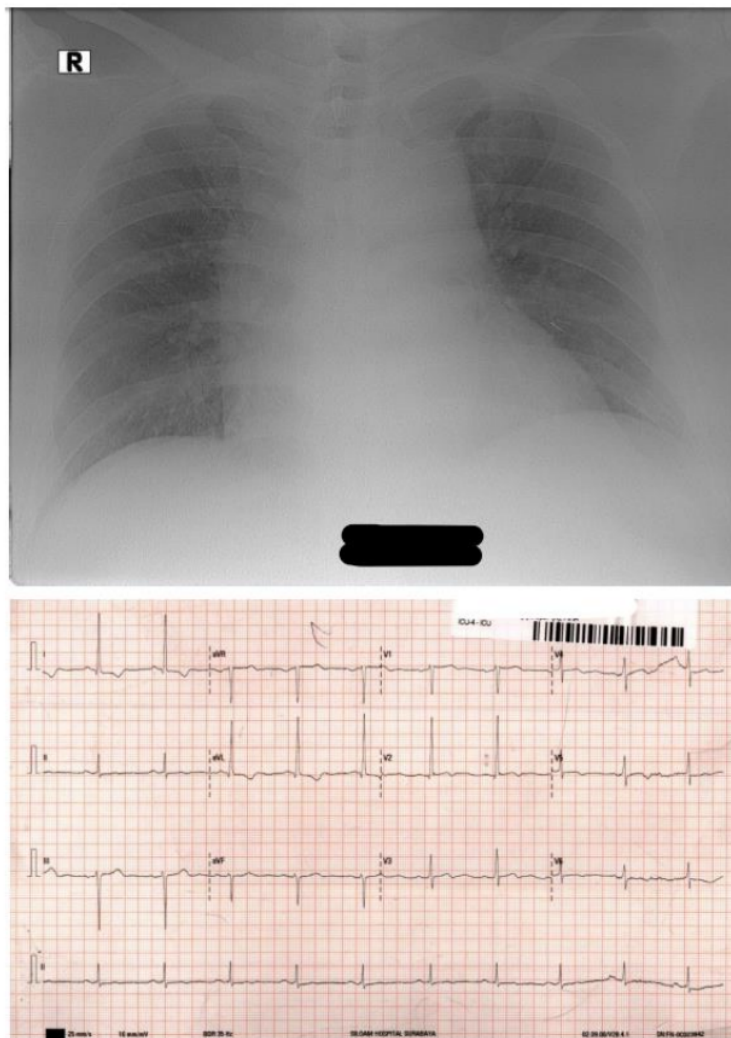


Figure 1. ECG and chest X-ray at initial presentation. Cardiomegaly and mediastinum enlargement were seen on the CXR. The ST-T wave on the ECG was non-specific.

curved segment of the aorta extending from the heart. This operation is commonly conducted to address various diseases, including aneurysms, dissections, and other anomalies affecting the aorta.⁴ This case report aims to elucidate the decision-making process for managing cases of aortic dissection.

2. Case Presentation

A middle-aged male, aged 40, who possesses risk factors including uncontrolled hypertension for a duration exceeding 10 years and obesity classified as class III with a body mass index (BMI) of 50.8 kg/m², arrived at the emergency department with symptoms of abrupt chest pain. The pain was characterized as tearing in nature and extended to the abdominal region. The patient's physical findings included a blood pressure reading of 255/143, a widened mediastinum and cardiomegaly observed on chest X-ray, a small

elevation in Hs-Troponin levels, and an electrocardiogram showing sinus rhythm with left ventricular hypertrophy. Based on the findings obtained from the anamnesis, physical examination, and supportive examination, medical professionals maintain a degree of uncertainty regarding the diagnosis of ACS. Consequently, they proceed to conduct CT scans as a triple rule out procedure on the aforementioned patient. The CT scans revealed a series of aortic dissections extending from the ascending to the descending aorta, with no apparent impact on the aortic valve from echocardiography. The individual received a medical diagnosis of Stanford A DeBakey I aortic dissection. Subsequently, the patient has a surgical intervention involving open heart surgery, resulting in a successful replacement of the entire aortic arch and conventional elephant trunk.

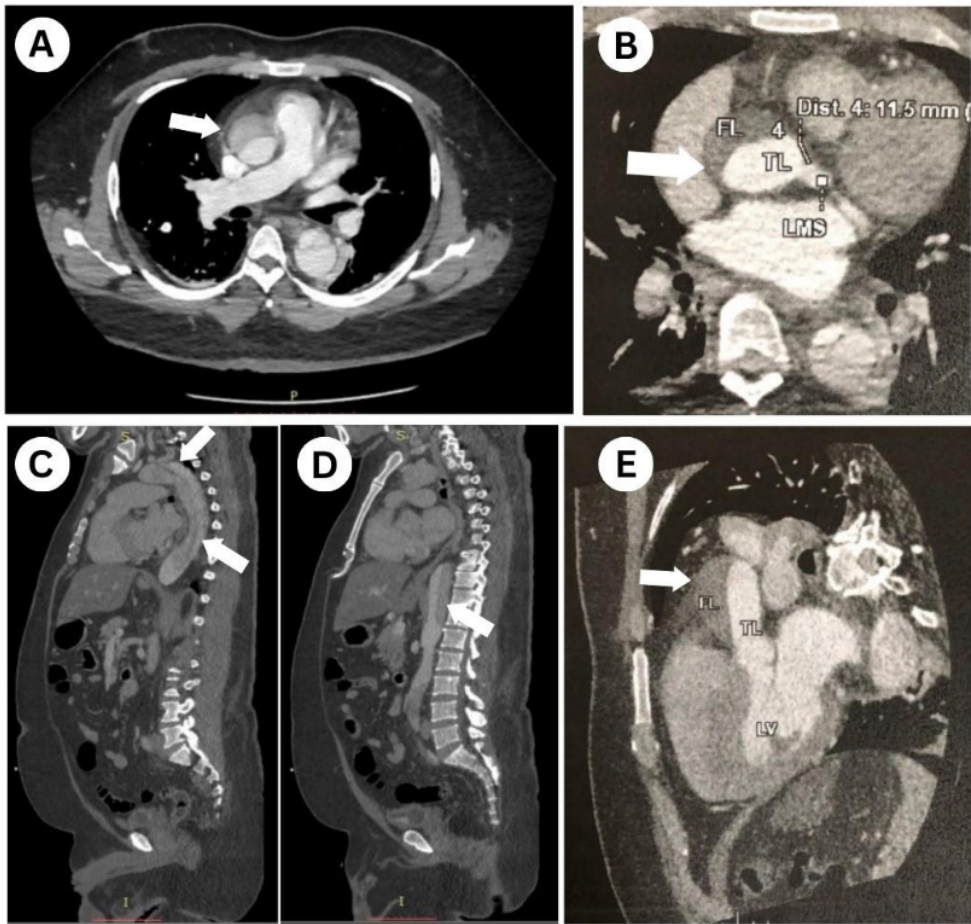


Figure 2. Image A and B (axial view CT scan) depict an intimal flap inside the ascending aorta, causing a division of the lumen into two separate spaces: the true lumen and the false lumen. The true lumen appears with a more intense coloration. Image C (sagittal view) revealed an intimal tear located at the arcus aorta, specifically following the left subclavia artery sinistra. Image D (sagittal view CT scan) clearly depicts the intimal flap at the descending aorta level and the artificial lumen. Image E (coronal view) displays an intimal flap located at the ascending aorta, which separates the inner space into two sections: a true lumen and a false lumen. However, the aortic root remains unaffected by this condition. These CT scan results indicate that the patient has a Stanford A DeBakey I aortic dissection.

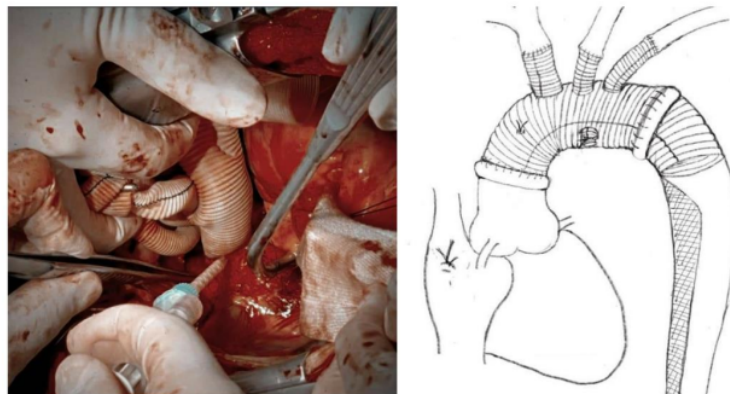


Figure 3. Total arch aortic replacement with elephant trunk procedure to manage patient with aortic dissection standford A DeBakey I

3. Discussion

Aorta dissection is characterized by the presence of an intimal tear, which permits the passage of blood through the tear and into the aorta media. This results in the longitudinal splitting of the intima, leading to the formation of a dissection flap that separates the genuine lumen from a newly formed false lumen. The dissection flap has the potential to propagate either in an antegrade or retrograde manner, giving rise to several severe consequences that can endanger the patient's life. These problems encompass acute aortic regurgitation, myocardial ischemia, cardiac tamponade, acute stroke, and malperfusion syndromes.⁵ In this case, CT scan showed intimal tears and false lumen at level aortic ascending and descending without aortic regurgitation finding from physical examination and echocardiography.

Establishing the incidence of aortic dissection is difficult as many patients (18% to 49%) die before the condition is recognized. Population studies estimate the incidence of acute aortic syndrome to range from 2.6 to 7.7 cases per 100,000 person-years, with 15 cases per 100,000 in the middle-aged. Acute aortic dissection has a very high early mortality, with up to a 1% per hour death rate in the first hours after acute type A dissection. Type A aortic dissection occurs most commonly in individuals between 50 and 60 years of age, and type B dissection at a peak of 60 to 70 years of age. The occurrence of aortic dissections in men accounts for around two-thirds of cases.^{1,3} In accordance with existing epidemiological data, this case occurs in men with a greater prevalence than women and happened in a younger age than usual.

The most commonly reported symptom of acute aortic dissection is chest discomfort. The most characteristic presentation is the sudden onset of intense chest and/or back pain. The pain experienced in this context has characteristics such as sharpness, ripping, tearing, and knife-like sensations, which distinguish it from other forms of chest pain. Notably, the suddenness with which it manifests is the most distinctive feature. The chest is the predominant location of pain, reported by almost 80% of individuals, but back discomfort and stomach pain are encountered by 40% and 25% of patients, respectively. The sensation of pain has the potential to relocate from its initial location to various other areas, tracing the course of dissection as it progresses along the aorta. In the study conducted on IRAD, it was noted that 15% of patients diagnosed with acute Type A AD had migrating pain, while around 20% of patients with acute Type B AD experienced the same symptom.⁶ In accordance with existing theory, the clinical presentation of this patient that made him come to the emergency room was abrupt tearing chest pain radiating to abdominal.

The use of chest x-ray is customary in individuals who exhibit symptoms of chest pain. The radiographic features commonly observed in acute type A aortic dissection (ATAAD) often involve the enlargement of the mediastinum or aortic knob. Interestingly, it has been shown that more than 20% of patients diagnosed with AAD do not exhibit any abnormalities in the mediastinum or aortic contour. This phenomenon is more prone to manifest in people who have a dissection involving a nondilated aorta. The observation of a pleural effusion, which lacked specificity, was notably observed in individuals with prolonged durations till diagnosis.⁷

The electrocardiogram (ECG) is a standard diagnostic procedure that is commonly conducted when individuals exhibit symptoms of chest pain. The data indicates that 30% of individuals exhibit aberrant findings when an ECG displays irregularities, which can be attributed to hypertensive alterations, compromised coronary ostia, or underlying coronary artery disease. Within the IRAD series, it was observed that 42% of individuals with ATAAD displayed nonspecific ST and T-wave alterations on their ECG of patients exhibited ischemia changes, while evidence of an acute myocardial infarction was found in 5% of cases. The occurrence of diagnostic delays can be anticipated when an ECG displays abnormalities, as doctors frequently prioritize the investigation of coronary illness as a first diagnosis due to its higher prevalence.⁷

Effective imaging plays a crucial role in the diagnosis and management of this condition due to the high frequency of missed dissections, unusual presentations, and the potential for time-dependent morbidity and mortality. In the context of the Investigational Research and Development (IRAD), the primary diagnostic modality employed was CT (Computed Tomography) in around 69% of instances. Echocardiography was utilized in 25% of cases, MRI was employed in 4% of cases. Aortography, on the other hand, was utilized in 2% to 3% of cases. The growing utilization of computed tomography can potentially be attributed to the increased accessibility and improved scanning speed. CT demonstrates a notable degree of sensitivity and specificity in the diagnosis of acute aortic syndromes and traumatic aortic damage. Additionally, CT has the capability to detect simultaneous coronary involvement, involvement of all four branch vessels, and the presence of blood in the pericardial sac (hemopericardium). Furthermore, CT imaging can assist in the identification of entrance rips in cases of dissection.^{5,7}

The patient underwent a surgical procedure involving comprehensive replacement of the aortic arch, including all three supra-aortic branches. Aortic valve replacement was not performed due to the absence of aortic regurgitation from echocardiography as a consequence of aortic dissection. The preferred therapeutic intervention for type A aortic dissection is surgical intervention. The death rate associated with unoperated acute type A aortic dissection is observed to be 1% per hour. Furthermore, the timing of symptom onset, diagnosis, and subsequent surgery has a crucial role in determining patient outcomes. Notably, individuals who undergo surgery within 8 to 12 hours following diagnosis exhibit the highest fatality rate. Previous studies have documented the superiority of surgical interventions compared to conservative treatment, especially in cases when patients come with unfavorable conditions and/or significant comorbidities. The study examined a cohort of 936 individuals diagnosed with ATAAD who were registered in the IRAD database. The analysis focused on patients up to 80 years of age. The findings revealed that the rate of mortality during hospitalization was significantly lower among those who underwent surgical intervention compared to those who received medicinal treatment. The study observed a decreased in-hospital death rate among octogenarians who underwent surgery compared to those who received conservative care (37.9% vs 55.2%).^{5,6}

The incidence of aortic arch dissection is observed in over 70% of cases classified as type A dissections, with arch vascular involvement reported in a range of 28% to 73% of cases. The procedure of arch replacement is conducted in cases where there is a significant intimal tear present throughout the arch and its associated vessels, which cannot be effectively addressed through primary resection. Additionally, arch replacement is performed when the aortic arch is either aneurysmal or has experienced a rupture. Furthermore, if a primary tear in the arch is identified during surgery or if the patient has heritable aneurysm disease, arch replacement may also be considered as a treatment option. The utilization of branched graft procedures is commonly favored in the management of arch vessels that are affected.¹

Drug treatment alone should be the initial approach for managing dissections limited to the descending aorta. It is advisable to suggest prompt interventional therapy just for instances involving problems associated with dissection, such as unyielding discomfort or hypertension, fast aortic expansion, bleeding or controlled rupture, and ischemia of distal organs. Therefore, it is imperative to promptly administer endovascular or surgical intervention to individuals who exhibit the aforementioned problems. The utilization of endovascular repair as a substitute for traditional open surgery in the management of descending aorta has gained considerable popularity due to its notable reduction in morbidity and mortality rates compared to conventional surgical interventions.⁸

The technique of total arch replacement with the elephant trunk surgery has been devised and has shown encouraging outcomes in the treatment of DeBakey type I aortic dissection. Nevertheless, there are numerous issues that might significantly impact the long-

term result, including the continuous perfusion of the distal false lumen and the adverse remodeling of the distal aorta following the surgical procedure. The utilization of thoracic endovascular aortic repair (TEVAR), which is a less invasive method, has demonstrated notable efficacy in the management of type B aortic dissection (TBAD) as well as in cases requiring re-intervention subsequent to the frozen elephant trunk operation. It is believed that open surgery has the potential to transform type I aortic dissection into TEVAR. The utilization of a total arch aortic replacement with an elephant trunk surgery is employed as a therapeutic approach for patients presenting with Stanford type A aortic dissection DeBakey I.^{5,9,10}

The endovascular technique can be performed either concurrently (concomitant) with the initial surgery or at a separate time (staged, either earlier or later) than the initial open operation. A randomized controlled trial was conducted across multiple centers, with a total of 154 patients enrolled. The objective of the study was to evaluate the impact of early minimally invasive endovascular repair on distal aortic remodeling and long-term clinical outcomes in patients who had dominant false lumen and residual tears in the descending thoracic aorta following total arch replacement and frozen elephant trunk procedure. In this study, it is recommended that TEVAR operation be conducted no earlier than 30 days following the elephant trunk treatment, but no later than 90 days after its initiation. This timing is intended to facilitate collateral revascularization of the intercostal arteries and minimize the impact of the inflexible thick intimal flap on aortic remodeling. The recommendation for immediate interventional treatment utilizing an endoprosthesis should be limited to instances when complications arising from dissection are present. These complications may include refractory pain or hypertension, fast expansion of the aorta, bleeding or controlled rupture, as well as distal organ ischemia.¹⁰ According to previous study, we did not perform TEVAR procedure for descending aorta at acute onset and planned to perform TEVAR procedure next time because there was no related complication.

4. Conclusion

Type-A aortic dissection (ATAAD) is a cardiovascular emergency with a significant mortality rate. The utilization of imaging and diagnostic technologies has significantly influenced the approach to managing cases with suspected conditions. Acute surgical intervention is recommended for all patients, with the exception of individuals who are in a moribund state or have significant comorbidities. The surgical and perioperative methods employed may differ based on the specific clinical presentation and the nature of the aortic disease. This patient performed a total aortic arch replacement with elephant trunk procedure successfully with is currently scheduled for a planned thoracic endovascular aortic repair (TEVAR) treatment to address the descending aorta.

5. Declaration

5.1 Ethics Approval and Consent to participate

Patient has provided written informed consent prior to involvement in the study.

5.2. Consent for publication

Not applicable.

5.3 Availability of data and materials

Data used in our study were presented in the main text.

5.4 Competing interests

Not applicable.

5.5 Funding Source

Not applicable.

5.6 Authors contributions

Idea/concept: MF. Design: MF. Control/supervision: SDH, YES. Data collection/processing: MF. Analysis/interpretation: MF, SDH. Literature review: MF. Writing the article: MF. Critical review: SDH, YES. All authors have critically reviewed and approved the final draft and are possible for the content and similarity index of the manuscript.

5.7 Acknowledgements

We thank to Brawijaya Cardiovascular Research Center

References

- Bonow Mann L, Bhatt T, Elsevier S. *Heart disease a textbook of cardiovascular medicine*.
- Gudbjartsson T, Ahlsson A, Geirsson A, et al. Acute type A aortic dissection—a review. *Scandinavian Cardiovascular Journal*. 2020;54(1):1-13. doi:10.1080/14017431.2019.1660401
- Sayed A, Munir M, Bahbah EI. Aortic Dissection: A Review of the Pathophysiology, Management and Prospective Advances. *Curr Cardiol Rev*. 2020;17(4). doi:10.2174/1573403x16666201014142930
- Czerny M, Schmidli J, Adler S, et al. Editor's Choice – Current Options and Recommendations for the Treatment of Thoracic Aortic Pathologies Involving the Aortic Arch: An Expert Consensus Document of the European Association for Cardio-Thoracic Surgery (EACTS) & the European Society for Vascular Surgery (ESVS). *European Journal of Vascular and Endovascular Surgery*. 2019;57(2):165-198. doi:10.1016/j.ejvs.2018.09.016
- Isselbacher EM, Preventza O, Black JH, et al. 2022 ACC/AHA Guideline for the Diagnosis and Management of Aortic Disease: A Report of the American Heart Association/American College of Cardiology Joint Committee on Clinical Practice Guidelines. *Circulation*. 2022;146(24):E334-E482. doi:10.1161/CIR.0000000000001106
- Erbel R, Aboyans V, Boileau C, et al. 2014 ESC guidelines on the diagnosis and treatment of aortic diseases. *Eur Heart J*. 2014;35(41):2873-2926. doi:10.1093/eurheartj/ehu281
- Evangelista A, Isselbacher EM, Bossone E, et al. Insights from the international registry of acute aortic dissection: A 20-year experience of collaborative clinical research. *Circulation*. 2018;137(17):1846-1860. doi:10.1161/CIRCULATIONAHA.117.031264
- Dinato FJ, Ribeiro Dias R, Abrahão Hajjar L. DISSECÇÃO DA AORTA: MANEJO CLÍNICO E CIRÚRGICO. *Revista da Sociedade de Cardiologia do Estado de São Paulo*. 2018;28(3):260-266. doi:10.29381/0103-8559/20182803260-6
- Juraszek A, Czerny M, Rylski B. Update in aortic dissection. *Trends Cardiovasc Med*. 2022;32(7):456-461. doi:10.1016/j.tcm.2021.08.008
- Liu Y, Li L, Xiao Z, et al. Early endovascular intervention for unfavorable remodeling of the thoracic aorta after open surgery for acute DeBakey type I aortic dissection: study protocol for a multicenter, randomized, controlled trial. *Trials*. 2023;24(1). doi:10.1186/s13063-023-07548-x

Navigating Complex Cardiovascular Pathologies

ORIGINALITY REPORT

16%

SIMILARITY INDEX

10%

INTERNET SOURCES

14%

PUBLICATIONS

%

STUDENT PAPERS

PRIMARY SOURCES

- 1** Ahmed Sayed, Malak Munir, Eshak I. Bahbah. "Aortic Dissection: A Review of the Pathophysiology, Management and Prospective Advances", *Current Cardiology Reviews*, 2021 **1** %

Publication
- 2** Seprian Widasmara, Indra Jabbar Aziz, Mohammad Saifur Rohman. "75. MORE FREQUENT REHOSPITALIZATION IN HEART FAILURE PATIENTS WITH HYPERTENSION", *Journal of Hypertension*, 2021 **1** %

Publication
- 3** Erbel, R., V. Aboyans, C. Boileau, E. Bossone, R. Di Bartolomeo, H. Eggebrecht, A. Evangelista, V. Falk, H. Frank, O. Gaemperli, M. Grabenwoger, A. Haverich, B. Iung, A. J. Manolis, F. Meijboom, C. A. Nienaber, M. Roffi, H. Rousseau, U. Sechtem, P. A. Sirnes, R. S. von Allmen, C. J. M. Vrints, ESC Committee for Practice Guidelines (CPG), J. L. Zamorano, S. Achenbach, H. Baumgartner, J. J. Bax, H. Bueno, V. Dean, C. Deaton, C. Erol, R.

1 %

Fagard, R. Ferrari, D. Hasdai, A. Hoes, P. Kirchhof, J. Knuuti, P. Kolh, P. Lancellotti, A. Linhart, P. Nihoyannopoulos, M. F. Piepoli, P. Ponikowski, P. A. Sirnes, J. L. Tamargo, M. Tendera, A. Torbicki, W. Wijns, S. Windecker, Document reviewers, P. Nihoyannopoulos, M. Tendera, M. Czerny, J. Deanfield, C. D. Mario, M. Pepi, M. J. S. Taboada, M. R. v. Sambeek, C. Vlachopoulos, and J. L. Zamorano. "2014 ESC Guidelines on the diagnosis and treatment of aortic diseases: Document covering acute and chronic aortic diseases of the thoracic and abdominal aorta of the adult * The Task Force for the Diagnosis and Treatment of Aortic Diseases of the European Society of Cardiology (ESC)", European Heart Journal, 2014.

Publication

4

www.tandfonline.com

Internet Source

1 %

5

f1000research.com

Internet Source

1 %

6

Kirsch, M.. "Fate of the distal aorta after surgical repair of acute DeBakey type I aortic dissection: A review", Archives of Cardiovascular Diseases, 201102

Publication

1 %

www-thelancet-com.autorpa.ntunhs.edu.tw

7	Internet Source	1 %
8	www.frontiersin.org Internet Source	1 %
9	www.science.gov Internet Source	1 %
10	pubmed.ncbi.nlm.nih.gov Internet Source	1 %
11	link.springer.com Internet Source	1 %
12	www.spandidos-publications.com Internet Source	<1 %
13	Divaldo Pereira de Lyra, Thaciana dos Santos Alcântara, Fernando Castro de Araújo Neto, Helena Ferreira Lima et al. "Medication Discrepancies Involving Hospitalized Children At A High-Complexity Public Hospital", Research Square, 2019 Publication	<1 %
14	Tomas Gudbjartsson, Anders Ahlsson, Arnar Geirsson, Jarmo Gunn et al. "Acute type A aortic dissection – a review", Scandinavian Cardiovascular Journal, 2019 Publication	<1 %
15	vbn.aau.dk Internet Source	<1 %

16	jamanetwork.com Internet Source	<1 %
17	www.dovepress.com Internet Source	<1 %
18	Takuya Ogami, George J. Arnaoutakis, Eric M. Isselbacher, Guillaume S.C. Geuzebroek et al. "Long-term outcomes after recurrent acute thoracic aortic dissection: Insights from the International Registry of Aortic Dissection", <i>The Journal of Thoracic and Cardiovascular Surgery</i> , 2024 Publication	<1 %
19	Changcun Fang, Chen Wang, Kai Liu, Xinyan Pang. "Early Outcomes of Left Subclavian Artery Revascularization Using Castor Single-Branched Stent-Graft in the Treatment of Type B Aortic Dissection or Intramural Hematoma", <i>Annals of Thoracic and Cardiovascular Surgery</i> , 2020 Publication	<1 %
20	Martin Czerny, Jürg Schmidli, Luca Bertoglio, Thierry Carrel et al. "Clinical Cases Referring to Diagnosis and Management of Patients With Thoracic Aortic Pathologies Involving the Aortic Arch: A Companion Document of the 2018 European Association for Cardio-Thoracic Surgery (EACTS) and the European Society for Vascular Surgery (ESVS) Expert	<1 %

Consensus Document Addressing Current Options and Recommendations for the Treatment of Thoracic Aortic Pathologies Involving the Aortic Arch", European Journal of Vascular and Endovascular Surgery, 2019

Publication

21

Yutaka Okita. "Some Comments from the East on the European Association for Cardio-Thoracic Surgery (EACTS) & the European Society for Vascular Surgery (ESVS) Consensus Document for Treatment of Aortic Arch Pathologies", European Journal of Vascular and Endovascular Surgery, 2019

Publication

<1 %

22

academic.oup.com

Internet Source

<1 %

23

journals.lww.com

Internet Source

<1 %

24

www.researchsquare.com

Internet Source

<1 %

25

www.thieme-connect.de

Internet Source

<1 %

26

F Nisi, L Carengo, N Ruggieri, A Reda, MG Pascucci, A Pignataro, E Civilini, F Piccioni, E Giustiniano. "The anesthesiologist's perspective on emergency aortic surgery: preoperative optimization, intra-operative

<1 %

management, and post-operative surveillance", Seminars in Vascular Surgery, 2023

Publication

27

Januar, M.. "Left ventricle diastolic function in patients undergoing chemotherapy with doxorubicin", Heart, Lung and Circulation, 2008

Publication

<1 %

28

Leopoldo Fernández-Alonso, Sebastián Fernández Alonso, Esther Martínez Aguilar, Estéfana Santamarta Fariña et al.

"Fenestrated and Scalloped Endovascular Grafts in Zone 0 and Zone 1 for aortic arch disease", Annals of Vascular Surgery, 2020

Publication

<1 %

29

Rohesh J. Fernando, Scott R. Coleman, Fares Alghanem, Joseph Sanders et al. "The Year in Aortic Surgery: Selected Highlights from 2023", Journal of Cardiothoracic and Vascular Anesthesia, 2024

Publication

<1 %

30

Wahaj Munir, Amer Harky, Mohamad Bashir, Benjamin Adams. "Does adding a root replacement in type A aortic dissection repair provide better outcomes?", Journal of Cardiac Surgery, 2020

Publication

<1 %

31 Yongting Luo, Junjie Luo, Peng An, Yuanfei Zhao et al. "The activator protein-1 complex governs a vascular degenerative transcriptional programme in smooth muscle cells to trigger aortic dissection and rupture", European Heart Journal, 2023
Publication

32 opus4.kobv.de
Internet Source

33 www.thieme-connect.com
Internet Source

34 www.wjgnet.com
Internet Source

35 www.worldwidejournals.com
Internet Source

36 Lin Li, Wenxian Wu, Na Xu, Qing Zhao, Wanpeng Guo. "Treatment and referral experiences of patients with type A aortic dissection and their families: a qualitative study", BMJ Open, 2023
Publication

37 "Cases", Journal of Arrhythmia, 2023
Publication

38 Diagnosis and Management of Marfan Syndrome, 2016.
Publication

39

E. Sebastian Debus, Reinhart T. Grundmann.
"Evidence-based Therapy in Vascular
Surgery", Springer Science and Business
Media LLC, 2017

Publication

<1 %

Exclude quotes On

Exclude matches Off

Exclude bibliography On