

# EFFICACY, SAFETY, AND CLINICAL OUTCOMES

*by Yan Efrata Sembiring*

---

**Submission date:** 08-May-2024 05:09PM (UTC+0800)

**Submission ID:** 2374084999

**File name:** EFFICACY,\_SAFETY,\_AND\_CLINICAL\_OUTCOMES.pdf (298.92K)

**Word count:** 5970

**Character count:** 36289

## Systematic Review

### EFFICACY, SAFETY, AND CLINICAL OUTCOMES OF SPLENORENAL SHUNT SURGERY AS A THERAPEUTIC INTERVENTION FOR PORTAL HYPERTENSION PATIENTS

Yan Efrata Sembiring<sup>1\*</sup>, Heroe Soebroto<sup>1</sup>, Ito Puruhito<sup>1</sup>, Dhihintia Jiwangga Suta Winarno<sup>1</sup>, I Gusti Agung Made Adnyanya Putra<sup>2</sup>, Sri Pramesti Wisnu Bowo Negoro<sup>3</sup>, Ketut Putu Yasa<sup>4</sup>, Jeffrey Jeswant Dillon<sup>4</sup>

<sup>1</sup>Department of Thoracic, Cardiac, and Vascular Surgery, Faculty of Medicine, Universitas Airlangga; Dr. Soetomo General Academic Hospital, Surabaya, Indonesia

<sup>2</sup>Thoracic, Cardiac, and Vascular Surgery Residency Program, Faculty of Medicine, Universitas Airlangga, Surabaya, Indonesia

<sup>3</sup>Department of Thoracic, Cardiac, and Vascular Surgery, Faculty of Medicine, Universitas Udayana; Prof. Dr. IGNG Ngoerah Central General Hospital, Denpasar, Indonesia

<sup>4</sup>Department of Cardiothoracic Surgery, Institut Jantung Negara, Kuala Lumpur, Malaysia

#### 5 ABSTRACT

Portal hypertension is the second most common gastrointestinal bleeding in cirrhosis and non-cirrhosis patients. The splenorenal shunt surgery is a potential intervention that may be considered for portal hypertension patients with clinical symptoms such as upper gastrointestinal bleeding caused by the rupture of gastro-esophageal varices. The objective of the procedure is to prevent long-term complications of portal hypertension, such as biliopathy. In this study, the researchers aimed to analyze the efficacy, clinical outcomes, and safety of splenorenal shunt surgery in portal hypertension patients. This study used a qualitative methodology with a systematic review framework. The sources were obtained from electronic search databases, i.e., PubMed, Google Scholar, and ScienceDirect, using "Efficacy," "Safety," and "Clinical Outcomes" as keywords that are related to splenorenal shunt surgery in portal hypertension patients. The researchers set specific criteria for the inclusion and exclusion of articles. The inclusion criteria were articles that met the following requirements: (1) retrospective case studies, retrospective cohort studies, or prospective cohort studies published from 2018 to 2023; (2) the topic of splenorenal shunt surgery in hepatic portal vein hypertension, with a specific evaluation of their efficacy, safety, and clinical outcomes that were established through clinical data validation. Ten studies were selected according to the inclusion criteria. This systematic review revealed the efficacy of the splenorenal shunt procedure with favorable outcomes. The success rate of splenorenal shunt surgery in reducing the clinical symptoms of portal hypertension varied between 66% and 100%. The prevailing complications observed in this study were shunt thrombosis, rebleeding, and thrombocytopenia. However, notable improvements could be achieved with general treatment. In terms of short- and long-term clinical outcomes, the splenorenal shunt procedure demonstrated favorable results. It can be concluded that splenorenal shunt surgery provides excellent clinical outcomes and should be considered a viable treatment option for patients with both cirrhotic and non-cirrhotic portal hypertension.

**Keywords:** Portal hypertension; splenorenal shunt surgery; efficacy; clinical outcomes; human and health

**\*Correspondence:** Yan Efrata Sembiring, Department of Thoracic, Cardiac, and Vascular Surgery, Faculty of Medicine, Universitas Airlangga; Dr. Soetomo General Academic Hospital, Surabaya, Indonesia. Email: yan-e-s@fk.unair.ac.id

#### Article history

• Submitted 9/6/2023 • Revised 3/8/2023 • Accepted 30/8/2023 • Published 10/9/2023

**How to cite:** Sembiring YE, Soebroto H, Puruhito I, et al (2023). Efficacy, Safety, and Clinical Outcomes of Splenorenal Shunt Surgery as a Therapeutic Intervention for Portal Hypertension Patients. *Folia Medica Indonesiana* 59 (3), 302-312, <https://doi.org/10.20473/fmi.v59i3.48843>



Copyright: © 2023 Folia Medica Indonesiana.

This is an open-access article distributed under the terms of the Creative Commons Attribution

License as stated in <https://creativecommons.org/licenses/by-nc-sa/4.0/deed.id>.

pISSN:2355-8393, eISSN: 2599-056x

#### Highlights:

1. This study systematically reviewed the efficacy, clinical outcomes, and safety of the splenorenal shunt procedure with a comprehensive and meticulous approach.
2. The splenorenal shunt procedure is an innovative surgical intervention that offers a viable option for the management of portal hypertension.
3. The findings of this study may improve clinical decision-making by helping healthcare professionals more effectively evaluate portal hypertension management strategies.

## INTRODUCTION

Hepatic portal vein hypertension is a medical disorder that is characterized by an increase in pressure inside the hepatic portal venous system. The examination of this condition can be conducted through the measurement of the elevated portal pressure gradient, which represents the difference between the pressures observed in the portal vein and those in the inferior vena cava or hepatic vein (Gunarathe et al. 2020, Oliver et al. 2023). Normally, the difference in portal pressure gradient is  $\leq 5$  mmHg. If the pressure gradient is  $\geq 6$  mmHg, it can be inferred that portal hypertension is present. Additionally, if the pressure is greater than 10 mmHg, clinical symptoms of portal hypertension typically appear. Meanwhile, if the pressure is 5–9 mmHg, it is usually indicative of a subclinical condition. Although the exact cause of this condition remains uncertain, it is classified into prehepatic, intrahepatic, or post hepatic causes (Gunarathe et al. 2020, Gioia et al. 2020). From an epidemiological standpoint, the most common cause is cirrhosis of the liver. However, schistosomiasis is the predominant factor in portal hypertension cases in Africa.

Typical features of portal hypertension are varices or variceal bleeding. The veins in the oesophagus normally carry blood into the hepatic portal vein. However, in cases of hypertension, these veins enlarge and carry blood away from the portal vein, which is commonly referred to as an oesophageal varices (Rockey 2017). These blood vessels may burst, resulting in the occurrence of hematemesis. In addition, the features of cirrhotic patients with portal hypertension can trigger ascites. Varicose or ascitic bleeding in cirrhotic patients is called decompensation. The most effective investigation method, albeit invasive, is the measurement of the hepatic vein pressure gradient. Clinically, if left untreated, portal hypertension can result in ascites, bleeding from varicose veins, and hepatic encephalopathy because the liver cannot remove ammonia due to collateral circulation, which causes the patient to lose consciousness. The treatment of portal hypertension depends on its underlying cause (Kibrit et al. 2018). Various therapies may be used, such as anticoagulants in confirmed thrombosis cases, non-selective  $\beta$ -blockers, endoscopic ligation of varices in cirrhotic patients with large varicose veins or a risk of stigmata, implantation of a transjugular intrahepatic portosystemic shunt (TIPS) for acute variceal bleeding, antibiotics for peritonitis prevention, and other symptomatic treatments. The novel surgical-based therapy that has currently been developed is splenorenal shunt surgery (Gao et al. 2020, Iwakiri & Trebicka 2021).

A splenorenal shunt surgery is a surgical procedure

that attaches the splenic vein to the left renal vein. This surgical procedure is typically performed to treat hepatic portal hypertension and its common complications. The procedure consisted of two types, i.e., proximal splenorenal shunt (PSRS) and distal splenorenal shunt (DSRS) (Papandria et al. 2019, Yao et al. 2021). Portal hypertension patients with clinical symptoms, such as upper gastrointestinal bleeding due to rupture of esophago-gastric varices, may consider the option of undergoing splenorenal shunt surgery. This surgery can prevent severe complications, such as biliopathy. In addition, this surgical procedure can also restore hepatic portal vein pressure to its normal levels and reduce postoperative morbidity and mortality (Dasanayake et al. 2020). Previous studies have demonstrated excellent outcomes, safety, and effectiveness of PSRS and DSRS, albeit with some reported side effects of little significance. However, it is imperative to conduct a systematic review to provide a comprehensive overview regarding the safety, efficacy, and clinical outcomes of splenorenal shunt surgery. Therefore, this research aimed to present a comprehensive review that investigated the safety, clinical outcomes, and efficacy of splenorenal shunt surgery in portal hypertension patients.

## MATERIALS AND METHODS

As recommended by Moher et al. (2015), this study was conducted with a review protocol that adhered to the Preferred Reporting Items for Systematic Reviews (PRISMA) guidelines. The reviewers of this research undertook the study selection and data extraction independently. All data were recorded electronically and organized in tabular format. The researchers assessed the feasibility of the literature. All of the researchers examined the titles, abstracts, and entire contents of the acquired articles.

The initial search of literature was conducted using a keyword extraction algorithm. The search started by querying indexed databases, including Google Scholar, ScienceDirect, and PubMed, using the specified keywords "Efficacy," "Safety," and "Clinical Outcomes" in relation to splenorenal shunt surgery in portal hypertension patients. The search was limited to publications within the last five years without any data discrimination. The researchers weed out duplicate articles after compiling results from the initial search. After getting rid of articles that were not related to the keywords, the researchers thoroughly selected articles that had the potential to be a source of data according to the inclusion and exclusion criteria. In addition to the PRISMA guidelines, this study adhered to the Cochrane Handbook for Systematic Reviews of Interventions (Page et al. 2021). The articles that

met the inclusion criteria comprised retrospective case studies, retrospective cohort studies, and prospective cohort studies that were published between 2018 and 2023. The primary focus of the studies must be centered around splenorenal shunt surgery in hepatic portal vein hypertension, with a detailed analysis of its efficacy, safety, and clinical outcomes, which were established through clinical data validation. The exclusion criteria consisted of the following: article duplicates; articles that were not compatible with the specified keywords; articles that did not provide information on efficacy, safety, and clinical outcomes of splenorenal shunt surgery; letters, review articles, or commentaries; and articles in languages other than English.

The data were extracted from the selected journal articles according to the aforementioned inclusion criteria. The researchers synthesized and arranged the data in tabular format by categorizing them by numerous variables, including study design, year of publication, country of origin, and clinical characteristics (i.e., age, sex, etiology of portal hypertension, complications, and medical indications for splenorenal shunt procedure). When a particular data point was absent from the selected literature, it was denoted as "NA" (an abbreviation for "not available") within the tables (Espinós et al. 2018).

## RESULTS

The researchers discovered a total of 150 publications that were published throughout the period of 2018–2023. These articles were retrieved from three different search engines, i.e., PubMed (n=100), ScienceDirect (n=25), and Google Scholar (n=25). A total of 140 records were excluded from the study due to various reasons, including duplicate articles (n=50), non-English articles, failure to be consistent with the abstract (n=10), the absence of full text (n=50), and articles that did not address the specific subject matter as defined by the researchers (n=30). Thus, a total of ten articles were deemed relevant to our topic and met the inclusion criteria. The flowchart of the article selection process can be seen in Figure 1.

The characteristics of the publications that were selected are presented in Table 1. Of the 150 articles, there were ten studies that reported the safety, efficacy, and clinical outcomes of splenorenal shunt surgery. In the ten selected articles that were identified and screened, it was found that the majority of the studies came from the United States. The remaining studies were from Germany, India, South Africa, Pakistan, and

France. The studies reported splenorenal shunt surgery in a total of 238 portal hypertension patients. All of the selected studies were retrospective cohort studies. The data exhibited a prevalent representation of male patients. The age of onset upon diagnosis was 5.5–27 years. The causes of hepatic portal vein hypertension in the studies included schistosomiasis, cystic fibrosis, portal vein thrombosis, and splenic vein ligation during pancreaticoduodenectomy. The most common complications related to portal hypertension were varices bleeding, hypersplenism, pancytopenia resulting from hypersplenism, and advanced decompensated liver cirrhosis. The literature revealed that the indications most frequently reported for splenorenal shunt surgery included unsuccessful transjugular intrahepatic porto-systemic shunt insertion, hepatic portal venous thrombosis, cystic fibrosis, decompensated liver cirrhosis, recurrent gastrointestinal bleeding, and hypersplenism.

The efficacy and safety of splenorenal shunt surgery were reported in the ten selected articles included in this systematic review. Several studies presented both the efficacy and safety of splenorenal shunt surgery, whereas other studies solely focused on either efficacy or safety. Table 2 summarizes the findings regarding the safety and efficacy of splenorenal shunt surgery as a surgical intervention for portal hypertension.

The findings of this systematic review indicated that splenorenal shunt surgery exhibited efficacy, as evidenced by the favorable results seen in the selected studies. The success rates of the splenorenal shunt procedure in reducing clinical symptoms of portal hypertension ranged from 66% to 100%. The studies conducted by Nordmann et al. (2021) and van Praet et al. (2021) yielded success rates of 100%. The later study further revealed a complete shunt patency rate of 100%, with no instances of shunt thrombosis, re-intervention for variceal bleeding, or mortality. According to the study by Gupta et al. (2022), a success rate of 88% was seen over the follow-up period, with no reported cases of thrombosis development. Comparable results were also documented in another study that was reviewed in this research. The study reported that the primary patency rates of splenorenal shunts at one-year and five-year intervals were observed to be 71% and 66%, respectively (Cortez et al. 2019).

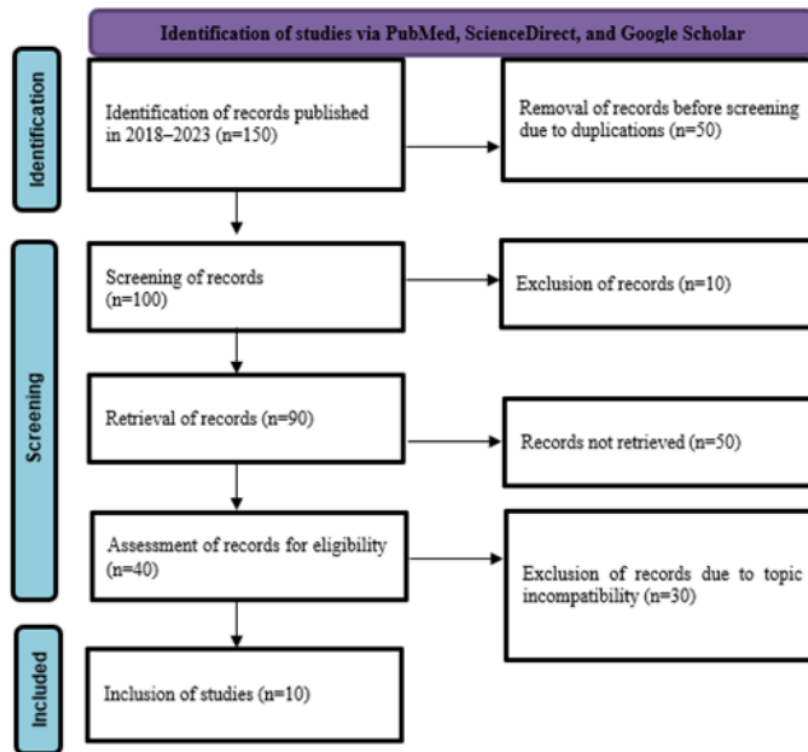


Figure 1. PRISMA flowchart of the article selection process.

The ten selected studies provided substantial evidence on the safety of splenorenal shunts in the treatment of portal hypertension. Several studies mentioned a number of complications that arose during the surgical procedures, including transient thrombocytosis, shunt and portal vein thrombosis, rebleeding, and thrombocytopenia. Some of the studies also reported increased risks of mortality due to complications such as arterial rupture, pulmonary embolism, and multiorgan failure after hemorrhagic shock. However, it is important to consider that the splenorenal shunt procedure in patients with portal hypertension demonstrated no long-term complications such as thrombosis or stenosis. Additionally, this procedure showed improvements in various aspects, including variceal bleeding, hypersplenism, hemoglobin and leukocyte levels, ascites, spontaneous bacterial peritonitis, jaundice, hepatorenal syndrome, hepatopulmonary syndrome, and portoencephalopathy. The improvements were also observed in the laboratory test results of liver functions, including total bilirubin, serum glutamic-oxaloacetic transaminase (SGOT), serum glutamic-pyruvic transaminase (SGPT), and alkaline

phosphatase. The occurrence of postoperative rebleeding was observed, albeit with limited reported cases in the selected studies.

Table 3 presents a comprehensive overview of the outcomes of splenorenal shunt surgery in the management of portal hypertension, as reported in the selected studies. The findings of this systematic review indicated that several studies demonstrated favorable clinical outcomes. The clinical outcomes of splenorenal shunt surgery were categorized into three distinct phases: preoperative, perioperative, and postoperative. The majority of the studies revealed similar preoperative outcomes, which included various conditions such as hypersplenism, Child-Pugh scores of 5 (class A), MELD scores of 3-28, pancytopenia, esophageal varices of grade II-IV according to Paquet's classification, advanced decompensated liver cirrhosis, ascites, spontaneous bacterial peritonitis, portal hypertensive biliopathy, hepatorenal syndrome, hepatopulmonary syndrome, and portosystemic encephalopathy. The procedures reported by the studies were proximal and distal splenorenal shunts.

Table 1. Characteristics of the selected studies.

Authors (Year)	Country	Study Design	n	Gender (Male)	Age (median / mean)	Etiologies	Complications	Indications
Nordmann et al. (2021)	United States	Retrospective case study	2	1	27	Hepatosplenic schistosomiasis	Variceal bleeding	Unsuccessful TIPS insertion, hepatic portal venous thrombosis
Lemoine et al. (2019)	United States	Retrospective cohort	5	3	6.9	Cystic fibrosis	Hypersplenism, variceal bleeding, thrombocytopenia	Portal hypertension related to cystic fibrosis
			9	8	10.7 ±4.2	Cystic fibrosis and liver disease	Advanced decompensated liver cirrhosis, hypersplenism, variceal bleeding	Decompensated liver cirrhosis
van Praet et al. (2021)	Germany	Retrospective Cohort	14	7	15	Portal vein thrombosis	Variceal bleeding	Portal vein thrombosis
Anand et al. (2020)	India	Prospective Cohort	25	19	18.6	Extrahepatic portal vein obstruction, non-cirrhotic portal fibrosis	Variceal bleeding	Recurrent GI bleeding and hypersplenism
Khamag et al. (2023)	South Africa	Retrospective Cohort	23	5	12	Extrahepatic portal vein obstruction	Hypersplenism, variceal bleeding	Recurrent GI bleeding and hypersplenism
Gupta et al. (2022)	India	Retrospective cohort	47	23	22	Extrahepatic portal vein obstruction, non-cirrhotic portal fibrosis	Variceal bleeding	Recurrent GI bleeding and hypersplenism
Rehman & Nazir (2019)	Pakistan	Retrospective Cohort	9	11	6	Extrahepatic portal hypertension	Variceal bleeding	Recurrent GI bleeding and hypersplenism
Addeo et al. (2020)	France	Retrospective Cohort	78	NA	63±8.1	Splenic vein ligation during pancreaticoduodenectomy	NA	Carcinoma of pancreas
Cortez et al. (2019)	United States	Retrospective Cohort	10	5	8.1	Extrahepatic portal vein thrombosis, chronic liver disease	NA	Recurrent GI bleeding
Woerner et al. (2018)	United States	Retrospective Cohort	16	NA	5.5	NA	NA	NA

Short-term complications during surgery were rarely reported. However, the study by Cortez et al. (2019) found perioperative outcomes with a median operating time of 390.5 minutes, estimated blood loss of 125 mL, portocaval gradient, pre-shunt mesenteric pressure of 28.7 mmHg, post-shunt mesenteric pressure of 22.8 mmHg, and a mesenteric pressure of 5.1 mmHg. The postoperative outcomes showed a hepato-encephalopathy grade of 0, a constant Child-Pugh score of 5 (class A), and improvements in esophageal varicose and thrombocytopenia. The life expectancy rate was found to be 80% with improved liver functions, as shown by the levels of bilirubin, SGOT, SGPT, and alkaline phosphatase. There was no occurrence of variceal bleeding after shunt, decreased spleen size, ascites, spontaneous bacterial peritonitis, jaundice, or hepatorenal syndrome.

The duration of follow-up ranged from 14 to 18.2 months. During the follow-up, variceal regression (100%), total regression (40%), and thrombosis (20%) were found in the patients who underwent splenorenal shunt surgery. The classification of clinical outcomes following shunt surgery in the study conducted by Cortez et al. (2019) included two categories, i.e., short-term outcomes and long-term outcomes. The short-term outcomes were the length of stay (9.5 days), postoperative transfusion (30%), wound complications (0%), early shunt thrombosis (20%), and unplanned reoperation (10%). Meanwhile, the long-term complications were recurrent bleeding within 60 days postoperatively (10%), readmission (30%), mortality (0%), appropriate growth development in terms of length (70%) and weight (90%), shunt complications (20%), and postoperative liver transplantation (30%).

Table 2. Efficacy and safety of splenorenal shunt surgery for portal hypertension.

Authors (Year)	Country	Efficacy	Safety
Nordmann et al. (2021)	United States	Success rate: 100%	Post-surgery complications: <ul style="list-style-type: none"> <li>• Transient thrombocytosis</li> <li>• Shunt and portal vein thrombosis</li> </ul>
Lemoine et al. (2019)	United States	Effective improvement of pulmonary hypertension and hypersplenism in CFLD patients	<ul style="list-style-type: none"> <li>• No long-term shunt complication; no shunt stenosis or thrombosis</li> <li>• No clinical finding of hepatic encephalopathy, although levels of ammonia were not consistently measured</li> </ul>
van Praet et al. (2021)	Germany	<ul style="list-style-type: none"> <li>• Median duration of follow-up: 3 years</li> <li>• Survival rate in the last follow-up: 100%</li> <li>• Shunt thrombosis: 0%</li> <li>• Maximum flow velocity: 46 cm/s</li> <li>• Shunt patency rate: 100%</li> <li>• Re-intervention due to variceal bleeding: 0%</li> </ul>	<ul style="list-style-type: none"> <li>• No perioperative complication</li> <li>• Improvement of esophageal variceal bleeding, hypersplenism, and the counts of hemoglobin, thrombocytes, and leukocytes</li> <li>• No ascites, spontaneous bacterial peritonitis, jaundice, hepatorenal syndrome, or portoencephalopathy</li> <li>• Improvement of liver functions, as shown by the examination of bilirubin, SGOT, SGPT, and alkaline phosphatase</li> </ul>
Anand et al. (2020)	India	Success rate: 80%	<ul style="list-style-type: none"> <li>• Rebleeding rate 48 hours post-surgery: 8%</li> <li>• Thrombosis of the splenic vein and superior mesenteric: 4%</li> </ul>
Khamag et al. (2023)	South Africa	Success rate: 73%	<ul style="list-style-type: none"> <li>• No complication post-surgery</li> <li>• Complications found during follow-up: GI bleeding and thrombosis</li> </ul>
Gupta et al. (2022)	India	Success rate: 88% No development of thrombosis after follow-up	<ul style="list-style-type: none"> <li>• Shunt thrombosis</li> <li>• Thrombocytopenia</li> </ul>
Rehman & Nazir (2019)	Pakistan	Success rate: 88.8%	Rebleeding
Addeo et al. (2020)	France	Success rate: 69.2%	Mortality due to grade C pancreatic fistula with arterial rupture, pulmonary embolism, and multiorgan failure after hemorrhagic shock due to arterial bleeding
Cortez et al. (2019)	United States	One-year primary patency rate: 71% Five-year primary patency rate: 66%	Complications: thrombosis and shunt stenosis
Woerner et al. (2018)	United States	Success rate: 95.2%	Complication: shunt stenosis

Table 3. Outcomes of splenorenal shunt surgery for portal hypertension

Author	Country	Outcomes		
		Preoperative	Perioperative	Postoperative
Nordmann et al. (2021)	United States	<ul style="list-style-type: none"> <li>Follow-up period: 17–23 months</li> <li>Spleen length: 211–213 mm</li> <li>Child-Pugh score: 5 (A)</li> <li>PELD: 9-12</li> <li>Initial platelet counts: 43-53 n/L</li> <li>Esophageal varicose and rectal varicose with red spots, and</li> <li>Paquet's classification grade: II-III</li> </ul>	Proximal splenorenal shunt with splenectomy	<ul style="list-style-type: none"> <li>Hepatic Encephalopathy grade: none</li> <li>Child-Pugh score: 5 (A)</li> <li>Gastroesophageal varicose: none</li> <li>Rectal varicosis regredient</li> <li>Paquet's classification grade: I</li> <li>Reduction of Paquet's classification grade: 2</li> <li>Latest platelet count: 200-518 n/L</li> </ul>
Lemoine et al. (2019)	United States	<p>Cystic fibrosis patients:</p> <ul style="list-style-type: none"> <li>Hypersplenism</li> <li>Thrombocytopenia</li> <li>Well-preserved liver function (albumin, INR, and total bilirubin)</li> <li>MELD/PELD score: 3±6</li> <li>Esophageal varicose</li> <li>Paquet's classification grade: III-IV</li> </ul> <p>CFLD patients:</p> <ul style="list-style-type: none"> <li>Advanced decompensated liver cirrhosis</li> <li>Hypersplenism</li> <li>Variceal bleeding</li> <li>PELD/MELD score: 28±4</li> </ul>	Distal splenorenal shunt without any immediate or early perioperative surgical complications	<ul style="list-style-type: none"> <li>Survival rate: 80%</li> <li>One mortality case due to pulmonary complication of cystic fibrosis</li> <li>No postoperative rebleeding</li> <li>Improvement of splenism</li> <li>No difference between preoperative and postoperative platelet counts, with spontaneous improvement at the last follow-up</li> <li>Compression of left renal vein, impaired drainage to the IVC, and pressure gradient of 5-6 mmHg that can not be improved with angioplasty</li> </ul>
van Praet et al. (2021)	Germany	<ul style="list-style-type: none"> <li>Esophageal variceal bleeding</li> <li>Hypersplenism</li> <li>Anemia, thrombocytopenia, and leukopenia</li> <li>Ascites</li> <li>Spontaneous bacterial peritonitis</li> <li>Portal hypertensive biliopathy (abnormal liver function test result)</li> <li>Hepatorenal syndrome</li> <li>Portosystemic encephalopathy</li> </ul>	Distal splenorenal shunt without reported immediate or short-term perioperative surgical complications	<ul style="list-style-type: none"> <li>Improvement of esophageal variceal bleeding, hypersplenism, and the counts of hemoglobin, thrombocytes, and leukocytes</li> <li>No ascites, spontaneous bacterial peritonitis, jaundice, hepatorenal syndrome, or portoencephalopathy</li> <li>Improvement of liver function laboratory test results (alkaline phosphatase, SGPT, SGOT, and bilirubin)</li> </ul>
Anand et al. (2020)	India	Esophageal variceal bleeding	Proximal splenorenal shunt without immediate or short-term perioperative surgical complications	<p>Follow-up (n=20)</p> <ul style="list-style-type: none"> <li>Variceal regression: 100%</li> <li>Complete variceal regression: 40%</li> <li>Shunt thrombosis: 20%</li> <li>Rebleeding: 10%</li> <li>Hepatic encephalopathy: 0%</li> </ul>
Khamag et al. (2023)	South Africa		Distal splenorenal shunt without immediate or short-term perioperative surgical complications	<p>Follow-up (n=21):</p> <ul style="list-style-type: none"> <li>Improvement of platelet counts and liver functions</li> <li>Median period of follow-up: 129 months</li> </ul>
Gupta et al. (2022)	India	<ul style="list-style-type: none"> <li>Esophageal variceal bleeding</li> <li>Hypersplenism</li> <li>Pancytopenia</li> </ul>	Proximal splenorenal shunt, with intraoperative blood loss of 500 cc	<ul style="list-style-type: none"> <li>Follow-up period: 3 years</li> <li>Shunt thrombosis: 37.2%</li> <li>Complete variceal regression: 59.7%</li> </ul>



Rehman & Nazir (2019)	Pakistan	<ul style="list-style-type: none"> <li>Bleeding episodes: 100%</li> <li>Platelet counts: 57.4±22.2</li> <li>Spleen size: 15.6±2.4</li> </ul>	Distal splenorenal shunt without operative complications, such as bleeding, injury to the surrounding tissue, wound infection, or encephalopathy	<ul style="list-style-type: none"> <li>Bleeding episodes: 11.1%</li> <li>Platelet counts: 94.4±34.4</li> <li>Spleen size: 15.1±2.5</li> </ul>
Addeo et al. (2020)	France		Left splenorenal shunt with a perioperative transfusion rate of 66%	<ul style="list-style-type: none"> <li>Survival rate: 18.2 months</li> <li>Mortality rate: 1.28%</li> <li>Morbidity rate: 30%</li> </ul>
				Median period of follow-up: 14 months
				Short-term outcomes: <ul style="list-style-type: none"> <li>Length of stay: 9.5 days</li> <li>Red blood cell transfusion: 30%</li> <li>Wound complication: 0</li> <li>Early shunt thrombosis: 20%</li> <li>Unplanned reoperation: 10%</li> <li>Other complications: 20%</li> </ul>
Cortez et al. (2019)	United States	<ul style="list-style-type: none"> <li>Esophageal varices</li> <li>Gastrointestinal bleeding</li> <li>Refractory ascites</li> <li>hepatopulmonary syndrome</li> <li>Hepatorenal syndrome</li> <li>Hepatic encephalopathy</li> </ul>	Distal splenorenal shunt, with the following perioperative outcomes: <ul style="list-style-type: none"> <li>Median operative time: 390.5 minutes</li> <li>Estimated blood loss: 125 mL</li> <li>Portocaval gradient: mesenteric pressures of 28.7 mmHg (pre-operative), 22.8 mmHg (post-operative), and 5.1 mmHg</li> </ul>	Long-term outcomes: <ul style="list-style-type: none"> <li>Recurrent GI bleeding within 60 days post-surgery: 10%</li> <li>Readmission within 60 days post-surgery: 30%</li> <li>Mortality within 60 days post-surgery: 0%</li> <li>Appropriate growth development (length, weight): 70%, 90%</li> <li>Shunt complication: 20%</li> <li>Liver transplantation: 30%</li> </ul>
Woerner et al. (2018)	United States	NA	NA	<ul style="list-style-type: none"> <li>Stenosis: 83.33%</li> <li>Platelet count of &lt;50,000/mm<sup>3</sup>: 12.5%</li> <li>Platelet count of &lt;100,000/mm<sup>3</sup>: 83.33%</li> <li>Spleen diameter increase of &gt;10%: 91.66%</li> <li>Recurrent variceal bleeding: 20.83%</li> </ul>

Notes: NA=Not available; PELD=Pediatric end stage liver disease model; MELD=Model for end stage liver disease; INR=International normalized ratio; DSRS=Distal splenorenal shunt; IVC=Inferior vena cava; SGOT=Serum glutamic oxaloacetic transaminase; SGPT=Serum glutamic pyruvic transaminase; GI=Gastrointestinal.

**DISCUSSION**

This systematic review examined the data of 238 patients obtained from the selected articles published in 2018–2023. The collected data represented the clinical outcomes, efficacy, and safety of splenorenal shunt surgery as the treatment of portal hypertension. As previously stated, the majority of the studies consistently indicated that bleeding and rebleeding were the predominant severe complications associated with hepatic portal vein hypertension resulting from either cirrhosis or non-cirrhosis. These complications had a significant impact on the prognosis and clinical outcomes of splenorenal shunt surgery. A broad range of therapeutic options were widely used, spanning from pharmacological to non-pharmacological interventions (Gairing et al. 2021, Yao et al. 2021). The pharmacological intervention exhibits favourable effectiveness in the short-term management of portal hypertension. However, this method does not change the overall portal vein blood flow or pressure, hence leading to the

potential recurrence of varicose veins. There are ongoing developments in the field of surgical interventions, including the development of various procedures such as splenorenal shunt surgery (both proximal and distal) and transjugular intrahepatic portosystemic shunts. These interventions have been reported to have the potential to reduce mortality and morbidity rates in the specific case being discussed (Terwagne et al. 2022).

The findings of this systematic review indicated that the entire literature confirmed the excellent efficacy, safety, and clinical outcomes of splenorenal shunt surgery in patients with portal hypertension. The aforementioned results are consistent with the meta-analysis conducted by Yao et al. (2021), who revealed that transjugular intrahepatic portosystemic shunts and distal splenorenal shunts exhibited a greater capacity to decrease rebleeding rates when compared to other therapeutic approaches. Several other studies have indicated that the use of mixed treatments may

yield more favourable outcomes. The suggested surgical interventions for hepatic portal vein hypertension in the presence of portal vein thrombosis are laparoscopic splenectomy and proximal splenorenal shunts (Gómez et al. 2021). A combination of a modified surgical technique with proximal splenorenal shunts has also been discovered as an advantageous therapeutic approach for managing portal vein thrombosis in patients with non-cirrhotic portal hypertension. This treatment strategy has demonstrated efficacy in preventing rebleeding, as supported by studies conducted by Gupta et al. (2019), Irawan & Mulyawan (2019), and Terwagne et al. (2022).

According to a study conducted by Malviya et al. (2022), splenorenal shunt surgery falls within the category of unconventional shunts, which can be used effectively and safely with favourable outcomes. This argument is supported by the results of various additional investigations. In the study by Biju et al. (2019), splenorenal shunt surgery was proven to be effective in lowering the risks of mortality and morbidity associated with portal hypertension. Moreover, the presence of abnormalities in the renal veins did not prevent the implementation of proximal splenorenal shunt surgery, even with different modifications. End-to-end interposition of proximal splenorenal shunt grafts is the ideal option, as it provides advantages in terms of shunt patency and clinical outcomes. In contrast, the study conducted by Yi et al. (2021) found that spontaneous splenorenal shunts as a surgical intervention for managing hepatic portal vein hypertension in cirrhosis had a detrimental effect on hepatic function and resulted in an increased mortality rate. Nevertheless, splenorenal shunt surgical intervention remains significant in the prevention of spontaneous splenorenal shunts in patients with cirrhosis. According to the results of the study conducted by Ravindranath et al. (2020), the intervention technique implemented in patients with comorbid cholangiopathy was effective in managing portal hypertension. However, it should be noted that this intervention did not lead to improvements in cholangiopathy or peribiliary collateral.

#### Strength and limitations

One notable aspect of this study is its pioneering nature, as it is the first-ever comprehensive analysis of splenorenal shunt surgery in the management of portal hypertension as far as the author is concerned. However, the scarcity of literature limited the information available regarding the splenorenal shunt procedure as a surgical intervention for portal hypertension.

#### CONCLUSION

This systematic review provides evidence supporting the efficacy, safety, and clinical results of splenorenal shunt surgery for treating portal hypertension. Patients diagnosed with either cirrhotic or non-cirrhotic portal hypertension may consider this surgical strategy to manage their condition.

#### Acknowledgment

The authors would like to express their sincere appreciation to the Faculty of Medicine, Universitas Airlangga, Surabaya, as well as to all those who have offered exceptional support since the initial stages of this study.

#### Conflict of interest

None.

#### Funding disclosure

None.

#### Author contribution

YES contributed to the conception, design, and final approval of the article. HS contributed to the analysis and interpretation of the data. DJSW contributed to the drafting of the article. IP and JJD contributed to the critical revision of the article for important intellectual content. SPWBN and IGAMAP contributed to the provision of administrative, technical, and logistic support. KPY contributed to the collection and assembly of data.

#### REFERENCES

- Addeo P, De Mathelin P, Averous G, et al (2020). The left splenorenal venous shunt decreases clinical signs of sinistral portal hypertension associated with splenic vein ligation during pancreaticoduodenectomy with venous resection. *Surgery* 168, 267–273. doi: 10.1016/j.surg.2020.04.033.
- Anand U, Kumar R, Priyadarshi RN, et al (2020). Proximal splenorenal shunt surgery for bleeding gastric varices in non-cirrhotic portal hypertension. *Cureus*. doi: 10.7759/cureus.10464.
- Biju P, Midha K, Gupta S, et al (2019). Proximal splenorenal shunt in a rare renal vein anomaly: A case report. *Cureus*. doi: 10.7759/cureus.4754.
- Cortez AR, Kassam A-F, Jenkins TM, et al (2019). The role of surgical shunts in the treatment of pediatric portal hypertension. *Surgery* 166, 907–913. doi: 10.1016/j.surg.2019.05.009.

- Dasanayake B, P Kanchana W, Darmapala A, et al. (2020). Left adrenalectomy and proximal splenorenal shunt. *Kerala Surgical Journal* 26, 212. doi: 10.4103/ksj.ksj\_27\_20.
- Espinós EL-, Hernández V, Domínguez-Escrig JL, et al (2018). Metodología de una revisión sistemática. *Actas Urológicas Españolas* 42, 499–506. doi: 10.1016/j.acuro.2018.01.010.
- Gairing SJ, Kloeckner R, Pitton MB, et al (2021). Multidisciplinary approach to the complex treatment for non-cirrhotic portal hypertension – case-report-based discussion. *Zeitschrift für Gastroenterologie* 59, 43–49. doi: 10.1055/a-1330-9827.
- Gao Z-Q, Han Y, Li L, et al (2020). Pharmacological management of portal hypertension: current status and future. *Chinese Medical Journal (Engl)* 133, 2362–2364. doi: 10.1097/CM9.0000000000001004.
- Gioia S, Nardelli S, Ridola L, et al (2020). Causes and management of non-cirrhotic portal hypertension. *Current Gastroenterology Reports* 22, 56. doi: 10.1007/s11894-020-00792-0.
- Gómez CA, Romani Pozo D, Herrera Chávez G, et al (2021). Laparoscopic splenectomy and proximal splenorenal shunt for portal hypertension due to portal vein thrombosis in a patient with protein S deficiency. *Revista de gastroenterología del Peru : organo oficial de la Sociedad de Gastroenterología del Peru* 41, 48–51. Available at: <http://www.ncbi.nlm.nih.gov/pubmed/34347772>.
- Gunarathne LS, Rajapaksha H, Shackel N, et al. (2020). Cirrhotic portal hypertension: From pathophysiology to novel therapeutics. *World Journal of Gastroenterology* 26, 6111–6140. doi: 10.3748/wjg.v26.i40.6111.
- Gupta S, Pottakkat B, Kalayarasan R, et al (2022). Use of caudal pancreatectomy as a novel adjunct procedure to proximal splenorenal shunt in patients with noncirrhotic portal hypertension: A retrospective cohort study. *Annals of Hepato-Biliary-Pancreatic Surgery* 26, 178–183. doi: 10.14701/ahbps.21-106.
- Gupta S, Venkata Srinivas G, Chandrasekar AS, et al (2019). Splenoarenal shunt for noncirrhotic portal hypertension. *Indian Journal of Surgery* 81, 28–31. doi: 10.1007/s12262-017-1706-z.
- Irawan H, Mulyawan IM (2019). Combination of modified Sugiura technique and proximal splenorenal shunt for the management of portal vein thrombosis in noncirrhotic portal hypertension. *Clinical and Experimental Gastroenterology* 12, 149–156. doi: 10.2147/CEG.S188200.
- Iwakiri Y, Trebicka J (2021). Portal hypertension in cirrhosis: Pathophysiological mechanisms and therapy. *JHEP Reports* 3, 100316. doi: 10.1016/j.jhepr.2021.100316.
- Khamag O, Numanoglu A, Rode H, et al (2023). Surgical management of extrahepatic portal vein obstruction in children: advantages of MesoRex shunt compared with distal splenorenal shunt. *Pediatric Surgery International* 39, 128. doi: 10.1007/s00383-023-05411-3.
- Kibrit J, Khan R, Jung BH, et al (2018). Clinical assessment and management of portal hypertension. *Seminars in Interventional Radiology* 35, 153–159. doi: 10.1055/s-0038-1660793.
- Lemoine C, Lokar J, McColley SA, et al (2019). Cystic fibrosis and portal hypertension: Distal splenorenal shunt can prevent the need for future liver transplant. *Journal of Pediatric Surgery* 54, 1076–1082. doi: 10.1016/j.jpedsurg.2019.01.035.
- Malviya NK, Behari A, Kumar A, et al (2022). Unconventional shunts in extrahepatic portal venous obstruction—A retrospective review. *Journal of Clinical and Experimental Hepatology* 12, 503–509. doi: 10.1016/j.jceh.2021.05.007.
- Moher D, Shamseer L, Clarke M, et al (2015). Preferred reporting items for systematic review and meta-analysis protocols (PRISMA-P) 2015 statement. *Systematic Reviews* 4, 1. doi: 10.1186/2046-4053-4-1.
- Nordmann T, Schlabe S, Feldt T, et al (2021). TIPS and splenorenal shunt for complications of portal hypertension in chronic hepatosplenic schistosomiasis—A case series and review of the literature ed. Fairfax KC. *PLOS Neglected Tropical Diseases* 15, e0010065. doi: 10.1371/journal.pntd.0010065.
- Oliver TI, Sharma B, John S (2023). Portal hypertension. Available at: <http://www.ncbi.nlm.nih.gov/pubmed/23363263>.
- Page MJ, McKenzie JE, Bossuyt PM, et al (2021). The PRISMA 2020 statement: an updated guideline for reporting systematic reviews. *Systematic Reviews* 10, 89. doi: 10.1186/s13643-021-01626-4.
- Papandria DJ, Besner GE, Moss RL, et al (2019). Operative dictations in pediatric surgery. Papandria DJ, Besner GE, Moss RL & Diefenbach KA. Springer International Publishing, Cham. Available at: <http://link.springer.com/10.1007/978-3-030-24212-1>.
- van Praet KM, Ceulemans LJ, Monbaliu D, et al (2021). An analysis on the use of Warren’s distal splenorenal shunt surgery for the treatment of portal hypertension at the University Hospitals Leuven. *Acta Chirurgica Belgica* 121, 254–260. doi: 10.1080/00015458.2020.1726099.
- Ravindranath A, Sen Sarma M, Yachha SK, et al (2020). Outcome of portosystemic shunt surgery on pre-existing cholangiopathy in children with extrahepatic portal vein obstruction. *Journal of Hepato-Biliary-Pancreatic Sciences* 27, 141–148. doi: 10.1002/jhbp.692.
- Rehman Z, Nazir Z (2019). Distal Splenorenal Shunt (DSRS) in children with extrahepatic portal

- hypertension. *Journal of the College of Physicians and Surgeons Pakistan* 29, 1228–1229. doi: [10.29271/jcsp.2019.12.1228](https://doi.org/10.29271/jcsp.2019.12.1228).
- Rockey DC (2017). Advances in hepatology. *Current Opinion in Gastroenterology* 33, 113–114. doi: [10.1097/MOG.0000000000000357](https://doi.org/10.1097/MOG.0000000000000357).
- Terwagne N, Marique L, Dieu A, et al (2022). The use of autologous peritoneum in surgery of portal hypertension: H-shape splenorenal shunt using simple layer peritoneal tube. *Acta Gastro Enterologica Belgica* 85, 643–645. doi: [10.51821/85.4.9665](https://doi.org/10.51821/85.4.9665).
- Woerner A, Shivaram G, Koo KSH, et al (2018). Clinical and imaging predictors of surgical splenorenal shunt dysfunction in pediatric patients. *Journal of Pediatric Gastroenterology & Nutrition* 66, e139–145. doi: [10.1097/MPG.0000000000001931](https://doi.org/10.1097/MPG.0000000000001931).
- Yao Q, Chen W, Yan C, et al (2021). Efficacy and safety of treatments for patients with portal hypertension and cirrhosis: A systematic review and bayesian network meta-analysis. *Frontiers in Medicine*. doi: [10.3389/fmed.2021.712918](https://doi.org/10.3389/fmed.2021.712918).
- Yi F, Guo X, Wang L, et al (2021). Impact of spontaneous splenorenal shunt on liver volume and long-term survival of liver cirrhosis. *Journal of Gastroenterology and Hepatology* 36, 1694–1702. doi: [10.1111/jgh.15386](https://doi.org/10.1111/jgh.15386).



# EFFICACY, SAFETY, AND CLINICAL OUTCOMES

---

## ORIGINALITY REPORT

---

15%

SIMILARITY INDEX

9%

INTERNET SOURCES

12%

PUBLICATIONS

%

STUDENT PAPERS

---

## PRIMARY SOURCES

---

- 1** Karel M. Van Praet, Laurens J. Ceulemans, Diethard Monbaliu, Raymond Aerts, Ina Jochmans, Jacques Pirenne. "An analysis on the use of Warren's distal splenorenal shunt surgery for the treatment of portal hypertension at the University Hospitals Leuven", Acta Chirurgica Belgica, 2020  
Publication 1%

---
- 2** [www.cureus.com](http://www.cureus.com)  
Internet Source 1%

---
- 3** Manggala Pasca Wardhana, Kuntaman Kuntaman, Budi Utomo, Rozi Aditya Aryananda et al. "Evidence of Placental Villous Inflammation and Apoptosis in Third-Trimester Symptomatic SARS-CoV-2 Maternal Infection", Yonsei Medical Journal, 2024  
Publication 1%

---
- 4** Sanchez, Elizabeth. "Anxiety in Hispanic Freshman College Students", California Southern University, 2021  
Publication 1%

---

5	<a href="#">Variceal Hemorrhage, 2014.</a> Publication	1 %
6	<a href="#">c.coek.info</a> Internet Source	1 %
7	<a href="#">www.tridhascholars.org</a> Internet Source	1 %
8	Pietro Addeo, Pierre De Mathelin, Gerlinde Averous, Marlene Tambou-Nguipi et al. "The left splenorenal venous shunt decreases clinical signs of sinistral portal hypertension associated with splenic vein ligation during pancreaticoduodenectomy with venous resection", Surgery, 2020 Publication	<1 %
9	<a href="#">w.balimedicaljournal.org</a> Internet Source	<1 %
10	<a href="#">Medical Radiology, 2000.</a> Publication	<1 %
11	<a href="#">repositorium.sdum.uminho.pt</a> Internet Source	<1 %
12	<a href="#">ejmcm.com</a> Internet Source	<1 %
13	<a href="#">rcastoragev2.blob.core.windows.net</a> Internet Source	<1 %
14	<a href="#">www.asianinstituteofresearch.org</a>	

Internet Source

<1 %

15

Kulkarni, P.S.. "Immunogenicity of a new, low-cost recombinant hepatitis B vaccine derived from *Hansenula polymorpha* in adults", *Vaccine*, 20060424

Publication

<1 %

16

[www.annalsmedres.org](http://www.annalsmedres.org)

Internet Source

<1 %

17

[iridescentlearning.org](http://iridescentlearning.org)

Internet Source

<1 %

18

[arxiv.org](http://arxiv.org)

Internet Source

<1 %

19

Mozzochi, Kathryn. "Acupuncture for Knee Pain in Pediatric Patients: A Retrospective Chart Review Over the Last 10 Years", Boston University, 2023

Publication

<1 %

20

Caroline Lemoine, Joan Lokar, Susanna A. McColley, Estella M. Alonso, Riccardo Superina. "Cystic Fibrosis and Portal Hypertension: Distal Splenorenal Shunt Can Prevent the Need for Future Liver Transplant", *Journal of Pediatric Surgery*, 2019

Publication

<1 %

21

Henk R van Buuren, Marijke C Rasch, Piet L Batenburg, Clemens JM Bolwerk et al.

"Endoscopic sclerotherapy compared with no specific treatment for the primary prevention of bleeding from esophageal varices. A randomized controlled multicentre trial [ISRCTN03215899]", BMC Gastroenterology, 2003

Publication

---

<1 %

22

Kimo C Stine, Bryce A Warren, Robert L Saylor, David L Becton. "KRN5500 induces apoptosis (PCD) of myeloid leukemia cell lines and patient blasts", Leukemia Research, 2000

Publication

---

<1 %

23

Lethogonolo J. Diseko, Ana M. Tsoetsi-Khambule, ThankGod E. Onyiche, Tsepo Ramatla, Oriel Thekiso, Nomakorinte Gcebe. "Coxiella burnetii infections from animals and ticks in South Africa: a systematic review", Veterinary Research Communications, 2023

Publication

---

<1 %

24

Moinak Sen Sarma, Jayendra Seetharaman. "Pediatric non-cirrhotic portal hypertension: Endoscopic outcome and perspectives from developing nations", World Journal of Hepatology, 2021

Publication

---

<1 %



25

Internet Source

<1 %

26

[sbir.upct.es](http://sbir.upct.es)

Internet Source

<1 %

27

[www.researchgate.net](http://www.researchgate.net)

Internet Source

<1 %

28

[www.scielo.br](http://www.scielo.br)

Internet Source

<1 %

29

Alfian Nur Rosyid, Daniel Maranatha.  
"Methacholin Provocation Test in COPD and  
Healthy Smokers", Current Respiratory  
Medicine Reviews, 2018

Publication

<1 %

30

Pierre Mayer, Aina Venkatasamy, Thomas F.  
Baumert, François Habersetzer, Patrick  
Pessaux, Antonio Saviano, Emanuele Felli.  
"Left-sided portal hypertension: Update and  
proposition of management algorithm",  
Journal of Visceral Surgery, 2023

Publication

<1 %

31

Shahana Gupta, Biju Pottakkat, Raja  
Kalayarasan, Gnanasekaran Senthil, Pagadala  
Naga Balaji Nitesh. "Use of caudal  
pancreatectomy as a novel adjunct procedure  
to proximal splenorenal shunt in patients with  
noncirrhotic portal hypertension: A

<1 %

retrospective cohort study", Annals of  
Hepato-Biliary-Pancreatic Surgery, 2022

Publication

32

[ecommons.aku.edu](https://ecommons.aku.edu)

Internet Source

<1 %

33

[fmsscicom.fm.vse.cz](https://fmsscicom.fm.vse.cz)

Internet Source

<1 %

34

[www.clinicaltrials.gov](https://www.clinicaltrials.gov)

Internet Source

<1 %

35

[www.science.gov](https://www.science.gov)

Internet Source

<1 %

36

"Abstracts of "The 38th Annual Scientific Meeting of Indonesian Urological Association"", BJU International, 2015.

Publication

<1 %

37

Jay H. Shah, Harun Krndzija, C. Matthew Hawkins. "Pediatric Portal Hypertension: Etiology and Management", Digestive Disease Interventions, 2022

Publication

<1 %

38

M. K. Mohapatra, A. K. Mohapatra, S. K. Achary, P. Sahni, S. Nundy. "Encephalopathy in patients with extrahepatic obstruction after lienorenal shunts", British Journal of Surgery, 1992

Publication

<1 %

39 Michael Okello, Sanjanaa Srikant, Dave Darshit, Ponsiano Ocama. "Outcomes of Proximal Spleno-Renal Shunt Operations for Idiopathic Portal Hypertension in Tertiary Hospital in the Sub-Sahara", International Medical Case Reports Journal, 2024  
Publication

---

40 Nishant K. Malviya, Anu Behari, Ashok Kumar, Vinay K. Kapoor, Rajan Saxena. "Unconventional Shunts in Extrahepatic Portal Venous Obstruction—A Retrospective Review", Journal of Clinical and Experimental Hepatology, 2021  
Publication

---

41 Stefania Gioia, Silvia Nardelli, Lorenzo Ridola, Oliviero Riggio. "Causes and Management of Non-cirrhotic Portal Hypertension", Current Gastroenterology Reports, 2020  
Publication

---

42 [journals.plos.org](https://journals.plos.org)  
Internet Source

---

43 [neuro.unboundmedicine.com](https://neuro.unboundmedicine.com)  
Internet Source

---

44 [pubmed.ncbi.nlm.nih.gov](https://pubmed.ncbi.nlm.nih.gov)  
Internet Source

---

45 [www.discover-journal.ru](https://www.discover-journal.ru)  
Internet Source

---

46	<a href="http://www.hindawi.com">www.hindawi.com</a> Internet Source	<1 %
47	<a href="http://www.medrxiv.org">www.medrxiv.org</a> Internet Source	<1 %
48	<a href="http://www.ncbi.nlm.nih.gov">www.ncbi.nlm.nih.gov</a> Internet Source	<1 %
49	<a href="http://www.revistagastroperu.com">www.revistagastroperu.com</a> Internet Source	<1 %
50	"Abstracts", Journal of Gastroenterology and Hepatology, 2016 Publication	<1 %
51	Seung Hyuk Im, Dam Hyeok Im, Su Jeong Park, Youngmee Jung, Dong-Hwee Kim, Soo Hyun Kim. "Current status and future direction of metallic and polymeric materials for advanced vascular stents", Progress in Materials Science, 2022 Publication	<1 %
52	Mullen, Amanda. "A Systematic Review of the Best Practices in Blended Learning Classrooms that Increase Elementary Students' Engagement, Motivation, and Reading Proficiency", Trevecca Nazarene University, 2023 Publication	<1 %

---

Exclude quotes      On

Exclude matches      Off

Exclude bibliography      On

# EFFICACY, SAFETY, AND CLINICAL OUTCOMES

---

## GRADEMARK REPORT

---

FINAL GRADE

GENERAL COMMENTS

**/100**

---

PAGE 1

---

PAGE 2

---

PAGE 3

---

PAGE 4

---

PAGE 5

---

PAGE 6

---

PAGE 7

---

PAGE 8

---

PAGE 9

---

PAGE 10

---

PAGE 11

---