





## SYSTEMATIC REVIEW

## Effect of Modic Change on Clinical Outcome of Cervical Disc Herniation Patients Undergoing Anterior Cervical Discectomy and Fusion

Caesaroy Afif Wibowo<sup>1\*</sup>, Muhammad Faris<sup>2,3\*</sup>, Sri Andreani Utomo<sup>4,5</sup>, Tsabita Hadid<sup>1</sup>

<sup>1</sup>Faculty of Medicine Universitas Airlangga, Surabaya, Indonesia

<sup>2</sup>Department of Neurosurgery, Faculty of Medicine, Universitas Airlangga;

Dr. Soetomo General Academic Hospital, Surabaya, Indonesia

<sup>3</sup>Department of Neurosurgery, RS Adi Husada Undaan Wetan Surabaya

<sup>4</sup>Department of Radiology, Faculty of Medicine Universitas Airlangga;

Dr. Soetomo General Academic Hospital Surabaya, Indonesia

<sup>5</sup>Asian Musculoskeletal Society

### Article Info

#### Article history:

Received 21-12-2022

Revised 04-05-2023

Accepted 10-06-2023

Published 10-07-2023

#### Keywords:

Modic change

Patient's clinical outcome

Anterior cervical

discectomy and fusion

Cervical disc herniation

Health disease

#### \*Corresponding author:

Muhammad Faris

mfarisns@fk.unair.ac.id

### ABSTRACT

**Background:** Modic Change (MC) is a phenomenon that can be found in Magnetic Resonance Imaging (MRI) of patients with degenerative spinal diseases and in the cervical region. The effect of Modic change on the clinical outcome of postoperative patients has not been fully established. Anterior Cervical Discectomy and Fusion (ACDF) is a procedure that has become the gold standard in treating cervical disc herniation because it is able to eliminate pathological lesions and prevent the recurrence of nerve compression. **Objective:** This study aimed to determine the effect of MC on the clinical outcome of patients undergoing ACDF therapy due to degenerative disc pathology, including cervical disc herniation. **Material and Method:** This was a systematic review using filtered literature based on PICO. The variables examined in this study were "modic change", "ACDF", and "clinical outcome". Data were collected from three databases, which were then screened based on eligibility criteria, assessed for study quality, and reviewed using a qualitative descriptive method. **Result:** A total of six articles published between 2017 and 2021 were included in this study. This study was an observational study with a retrospective cohort method. Preoperative Modic changes tend not to affect clinical outcomes after ACDF. **Conclusion:** The presence of preoperative Modic changes tends not to affect clinical outcomes after ACDF due to degenerative disc pathology, including disc herniation, but remains a risk factor for postoperative disability and provides a worse preoperative picture.

#### How to cite:

Wibowo, C.A., Utomo, S.A. 2023. Effect of Modic Change on Clinical Outcome of Cervical Disc Herniated Patients Undergoing Anterior Cervical Discectomy and Fusion. *Majalah Biomorfologi*, 33(2):100-108

*Majalah Biomorfologi (Biomorphology Journal)* p.ISSN:0215-8833, e.ISSN: 2716-0920

doi: [10.20473/mbiom.v33i2.2023.100-108](https://doi.org/10.20473/mbiom.v33i2.2023.100-108)



Copyright: © 2023 by the authors. Open access publication under the terms and condition of the Creative Commons Attribution 4.0 International license (CC.BY 4.0).

### Highlights

1. The presence of preoperative Modic changes tends not to affect clinical outcomes after ACDF due to degenerative pathology, including disc herniation.
2. Preoperative Modic changes are correlated with a worse preoperative picture.

## BACKGROUND

Intervertebral disc herniation is a condition when the disc material, the nucleus pulposus, prolapses due to a lesion in the annulus fibrosus tissue. The disc material that protrudes into the vertebral canal often results in radiating pain in some patients with disc herniation due to pressure on the spinal nerve roots and spinal cord. Disc herniation can occur in any region of the spine but is most commonly found in the lumbar and cervical regions due to biomechanical forces on the flexible side of the spine, which cause these regions to support relatively more body weight (Dydyk, et al., 2023).

Cervical disc herniation is a condition in which the prolapse of the disc material occurs in the cervical region. The prolapse of disc material in cervical disc herniation is most often directed posterolaterally, where the annulus fibrosus tissue is neither too thick nor supported by the posterior longitudinal ligament. This herniation will then lead to compression of the spinal nerve roots and the release of inflammatory mediators so that the patient will experience symptoms in the form of axial neck pain and ipsilateral arm pain, sometimes accompanied by paresthesias according to the dermatome of the nerve roots that are experiencing compression (Sharrak & Al Khalili, 2023).

Disc herniation is known to occur in 1-3% of the world's population. The majority of disc herniations, both lumbar and cervical, occur at the age of 30-50 years, and the incidence of these herniations increases with age (Kim, et al., 2018; de Ciccio & Willhuber, 2023). In the cervical region, herniation most commonly occurs at the C5-C6 and C6-C7 intervertebral discs. This results in nerve lesions often found in the C6 and C7 nerves. Cervical disc herniation is also known to occur most often in women, with a percentage of more than 60% of total cases (Kim, et al., 2018; Sharrak & Al Khalili, 2023).

In patients with disc herniation, operative treatment is sometimes required in patients with severe neurologic deficits or in patients who do not respond to non-operative treatment. The surgical technique that has become the gold standard in dealing with cervical disc herniation is Anterior Cervical Discectomy and Fusion (ACDF). This procedure is the first choice because apart from getting rid of these pathological conditions, it also prevents the recurrence of nerve compression by performing fusion (Sharrak and Al Khalili, 2023). Based on meta-analytic studies, ACDF is able to provide a good prognosis for patients by significantly reducing axial neck pain as well as providing more stable results over time (Oitment, et al., 2020).

Modic Change (MC) is a phenomenon that can be found in Magnetic Resonance Imaging (MRI) of patients with degenerative spinal diseases and is known to have a close relationship with the incidence of low back pain. There are three types of signal changes in the vertebral body, which are classified as Modic change types 1, 2, and 3 (Laustsen & Bech-Azeddine, 2016; Applebaum, et al., 2022).

In lumbar disc herniation, Modic change is one of the factors that determines the postoperative patient's prognosis. Based on a meta-analytic study, Modic change is a factor that is closely related to the recurrence of lumbar disc herniation after lumbar discectomy (Brooks, et al., 2021). In addition, the presence of Modic change and disc inflammation is also known to cause a decrease in the clinical improvement of postoperative patients with lumbar disc herniation (Djuric, et al., 2019; Papanastasiou, et al., 2020; Kumarasamy, et al., 2022). In cervical disc herniation, Modic change is associated with lower repair in the patients undergoing therapy, both conservatively and operatively, namely through the ACDF procedure (Kressig, et al., 2016; Zhou, et al., 2018; Baker, et al., 2022).

## OBJECTIVE

This study aimed to determine the effect of MC on the clinical outcome of patients undergoing ACDF therapy due to degenerative disc pathology, including cervical disc herniation.

## MATERIAL AND METHOD

### Literature search

We conducted a literature search using the key concepts of "modic change", "ACDF", and "clinical outcome". The literature search was carried out comprehensively by using three databases (Pubmed, ScienceDirect, and Proquest). The process of this literature search was documented in the PRISMA

flow diagram. MC was defined by changes in signal intensity in the vertebral body as seen by T1WI and/or T2WI MRI spinal imaging, which were then classified as types 1, 2, and 3. Type 1 is characterized by hypointensity on T1WI and hyperintensity on T2WI, type 2 is characterized by hyperintensity on T1WI and isointensity or hyperintensity on T2WI, and type 3 is characterized by hypointensity on T1WI and T2WI.

### **Study selection**

The selection of studies was done by two independent reviewers regarding the inclusion and exclusion criteria. Any differences in opinion between reviewers were discussed until an agreement was reached. The Rayyan application was used to remove any duplicated studies.

### **Eligibility criteria**

Articles were included if they were published within 2017–2022, using English or Indonesian, and contained keywords related to “modic change”, “clinical outcome”, and “anterior cervical discectomy and fusion” or “ACDF”. Articles were excluded if they could not be accessed in full text and if the articles had a systematic review and experimental design. The population was patients undergoing ACDF for degenerative disc pathologies, including disc herniation. The intervention or exposure in this review was any type of Modic change. The control or comparison was patients without Modic change, and the clinical outcome was assessed by any tools for clinical outcome.

### **Data extraction**

Data extraction from the literature included in this study was carried out by the first author with the following data: first author, publication year, country, study design, number of samples, mean duration of follow-up, the mean age of the population, tools for assessing clinical outcome, and results.

### **Study quality assessment**

Articles included in this study were examined using the [Newcastle Ottawa Scale \(NOS\)](#) for cohort studies to assess the quality of the study by giving each study a score regarding some criteria. The main components of the assessment using NOS included selection, comparability, and outcome. Two authors (CAW and TH) assessed the quality of the studies, and any discrepancy was discussed until an agreement was reached.

## **RESULT**

### **Selection process**

On October 4, 2022, a literature search was carried out on the Pubmed, ScienceDirect, and Proquest databases using the advanced search on the Pubmed database and the boolean operator on the ScienceDirect and Proquest databases with the same keywords, namely (anterior cervical discectomy and fusion OR ACDF OR cervical discectomy and fusion) AND (modic change OR modic vertebral endplate change OR vertebral signal intensity change) AND (clinical outcome OR visual analog scale OR neck disability index). Searches using the keywords above were limited to 2017–2021 (the last 5 years), and there were 13 articles from Pubmed, 231 articles from ScienceDirect, and 109 articles from Proquest, so a total of 353 articles were obtained from the three databases.

From the search results, the deduplication process was then carried out. Four articles that were identified as the same were removed, leaving 349 articles. A total of 6 articles met the requirements for qualitative synthesis and were continued in the next process. The following is the PRISMA flowchart made in this study.

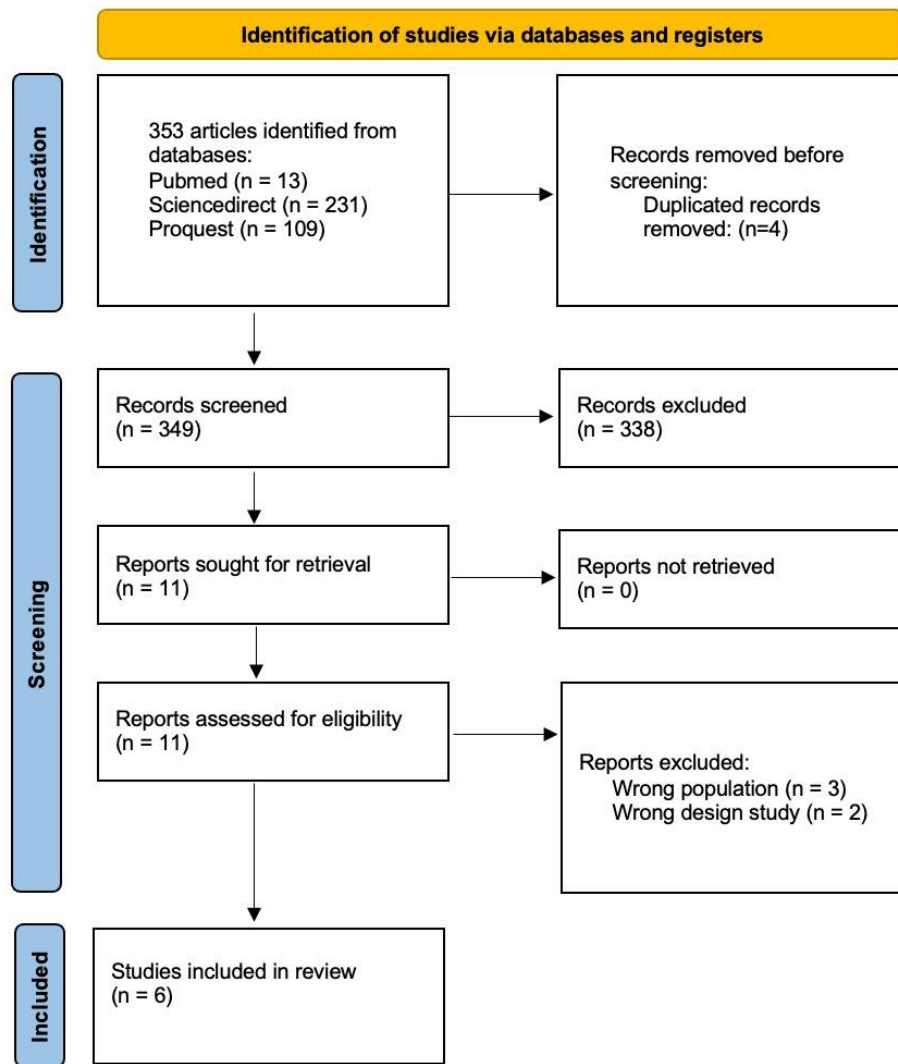


Figure 1. Study selection flowchart.

### Study quality

Based on the types of study articles that were included, it was found that six articles used the retrospective cohort method. Assessment of study quality was carried out using the Newcastle-Ottawa Scale (NOS). The Newcastle-Ottawa Scale is a tool for assessing the quality of observational studies, including cohort and case-control studies. Assessment using NOS produces a value in the form of a score with a maximum score of 9. The determination of the strength of the study is not carried out on NOS, so the quality of the study is only written in the form of a score. Assessment points on the NOS consist of selection, comparability, and outcome (Gierisch, et al., 2014). The quality assessment for the included studies resulted in one study receiving a total score of 5, one study receiving 6, two studies receiving 7, and two studies receiving 8.

Table 1. Quality assessment.

First author / year	Selection			Demonstration that the outcome of interest was not present at the start of the study (maximum: 1)	Comparability		Outcome		Total Score (maximum: 9)
	Representativeness of the exposed cohort (maximum: 1)	Selection of the non exposed cohort (maximum: 1)	Ascertainment of exposure (maximum: 1)		Comparability of cohorts on the basis of the design or analysis (maximum: 2)	Assessment of outcome (maximum: 1)	Was follow-up long enough for outcomes to occur (maximum: 1)	Adequacy of follow-up of cohorts (maximum: 1)	
Li, J/ 2017	0	0	1	1	0	1	1	1	5
Huang, K/ 2020	0	1	1	1	1	1	1	1	7
Baker, J/ 2020	1	1	1	1	1	1	1	1	8
Baker, J/ 2021	1	1	1	1	1	1	1	1	8
Harada, G/ 2021	1	0	1	1	0	1	1	1	6
Zhou, J/2018	0	1	1	1	1	1	1	1	7

### Study characteristics

A total of 6 studies that had been included were published between 2017–2021. The six literatures use English, and the full text of the six retrospective cohort studies can be accessed by reviewers. The total population obtained from the six studies amounted to 2655 patients, with a sample size varying from 72 to 861 patients. Although all studies contained keywords in the form of Anterior Cervical Discectomy and Fusion or ACDF, modic change, and clinical outcomes, several included observational studies did not specifically discuss this matter. However, all studies still had points that researchers are looking for, which will be presented in the next section.

All patients included in this study underwent ACDF. ACDF is performed in a population with indications of degenerative disc lesions, including cervical disc herniation. The majority of clinical outcomes were measured using VAS (neck and arm), the Japanese Orthopedic Association (JOA), and the Neck Disability Index (NDI). In addition to these three measurements, there is also a study that measures clinical outcomes using the Short Form 12-item, the Veteran's Rand 12-item, and Range of Motion (ROM). The majority of the literature measures pre and post-operative clinical outcomes, and only one article measures postoperative clinical outcomes.

### Data extraction

Table 2. Data extraction of study design, number of samples, mean duration of follow-up, and mean age.

First author/ year/ country	Study design	Number of samples	The mean duration of follow-up (month)	Mean age (year)
<a href="#">Harada, et al., (2021)</a> / N/A	Retrospective cohort	Total: 861	21.20	53.06
<a href="#">Zhou, et al., (2018)</a> / China	Retrospective cohort	Total: 117	23.28	AS: 57.02; without AS: 55.76
<a href="#">Baker et al., (2020)</a> / USA	Retrospective cohort	Total: 861; no MC: 505; overall MC: 356; MC type I: 70; MC	no MC: 26.38; overall MC: 27.86; MC type I: 30.32; MC type II: 26.87; MC type III: 28.84	no MC: 51.39; overall MC: 55.5; MC type I: 54.8; MC type II: 56.25, MC type III: 54.42

		type II: 218; MC type III: 68		
<a href="#">Baker et al., (2022)</a> / N/A	Retrospective cohort	Total: 628; no MC: 191; MC only: 84; endplate only: 166; MEC: 187	No MC: 28.2; MC only: 29.6; endplate only: 23.7; MEC: 26.6	control: 49; MC only: 50.6; endplate only: 53.2; MEC: 57.2
<a href="#">Huang, et al., (2020)</a> / China	Retrospective cohort	Total: 116; no MC: 92; MC type II: 24	no MC: 34; MC type II: 30	no MC=51.38; MC type II= 46.79
<a href="#">Li, et al., (2017)</a> / N/A	Retrospective cohort	Total (MC type II): 72	60	55.8 (TDR=53.6; ACDF=58.5)

Table 3. Data extraction of tools for assess clinical outcomes and results.

First author/ year/ country	Tools for assess the clinical outcome	Results
<a href="#">Harada, et al., (2021)</a> / N/A	NDI, VAS neck, VAS arm, ASDeg, ASDz	Type I and III MCs were associated with improved NDI, VAS arm, and VAS neck scores, whereas type II MCs were associated with a reduced incidence of ASDeg (OR: 0.79; 95% CI: 0.64-0.97; P=.026). CPI is a significant predictor of pain, disability, and the incidence of post-ACDF ASDeg/ASDz.
<a href="#">Zhou, et al., (2018)</a> / China	JOA score, JOA recovery rate, VAS	The risk of AS increased 3.2-fold in patients with preoperative MC (OR=3.268; 1.255 – 8.511).
<a href="#">Baker et al., (2020)</a> / USA	VAS-neck, VAS-arm, NDI, Short Form 12-item, the Veterans' Rand 12-item	MC had no significant effect (P>0.05) on postoperative clinical outcomes. MCs overall, including type II MCs, are associated with a longer duration of symptoms. There was no difference in operative output for either the MCs inside or outside the fusion segment. Overall, MCs, type II MCs, and type III MCs are associated with more fused levels. MC, including MC types I, II, and III, are associated with older age. Modic change has no significant effect on postoperative clinical or operative outcomes, but Modic change is associated with older age, longer duration of symptoms, and more levels of fused segments so that it may be able to indicate more debilitating and degenerative conditions preoperatively.
<a href="#">Baker et al., (2022)</a> / N/A	NDI and Veterans' Rand 12-item	The MC-only group within the segment and at the adjacent segment level was associated with higher postoperative disability compared to the control group. The MEC group also showed higher postoperative disability, especially when found within the fusion segment. MC and endplate abnormalities correlated independently of each other and the endplate only group was also found to correlate overall with poorer clinical outcome.
<a href="#">Huang, et al., (2020)</a> / China	JOA and VAS	MC type II does not affect clinical outcome but affects slower bone fusion rates in ACDF patients with Zero-P implants.
<a href="#">Li, et al., (2017)</a> / N/A	JOA, NDI, ROM, VAS arm and neck	Both groups had good clinical improvement (P<0.05).

## DISCUSSION

Based on the review, there is one literature that states MC is correlated with postoperative disability relative to controls. [Baker, et al., \(2022\)](#) found that the presence of MC is associated with postoperative disability as measured using the NDI. Based on its location, the presence of MCs within the segment and at the level of adjacent segments was related to the patient's perceived health status (P<0.05). In that study, MC was also found to be associated with the presence of another degenerative lesion, the endplate abnormalities ([Baker, et al., 2022](#)). This is similar to the results of other studies on the lumbar vertebrae, which also state that MC is associated with endplate abnormalities ([Määttä, et al., 2015](#)). In addition, the MEC group, which was the group with both MC and endplate abnormalities, also showed higher postoperative disability relative to controls. [Baker, et al., \(2022\)](#) concluded that the presence of MC correlated with the presence of endplate abnormalities, and the relationship between several degenerative lesion (MEC) phenotypes on post-ACDF clinical outcome was more significant than the relationship between each phenotype on post-ACDF clinical outcome ([Baker, et al., 2022](#)).

Another study by Zhou, et al., (2018) states that the presence of MC is a risk factor for Axial Symptom (AS) up to 3.2 times. AS is a condition that exacerbates the patient's symptoms because it can have an impact on the patient's work and social lives. Nonetheless, the study that divided the population into groups with and without AS stated that both groups experienced a significant clinical improvement in the JOA score and the rate of healing of JOA after one year. This shows that the presence or absence of AS is not related to neural repair after ACDF (Zhou, et al., 2018).

Then there are two studies supporting the hypothesis that Modic change has no significant effect on the clinical outcome of post-ACDF patients. A research by Huang, et al., (2020) states that MC type II does not affect postoperative clinical outcome ( $P>0.05$ ), but MC is associated with a slowdown in the rate of bone fusion after ACDF. The slowing of the rate of bone fusion can be affected by the use of Zero-P implants that are placed in surgical samples. The beta-tricalcium phosphate content contained in Zero-P implants may be more sensitive to changes in the microenvironment caused by local inflammation of the MC (Huang, et al., 2020). Even though the slowdown in the rate of bone fusion was present in the third and sixth months postoperatively and caused the patient to have to be collared longer to prevent complications of implant failure, bone fusion results were good and not associated with MC at the end of follow-up (Huang, et al., 2020).

Another study by Baker et al. (2020) also stated that overall MC, both types I, II, and III, did not significantly correlate with clinical outcomes after ACDF ( $P>0.05$ ). There was actually a relationship between MC and post-ACDF clinical outcome, but this relationship was only found in MC at vertebrae C7–T1, whereas the population of patients with MC at C7–T1 was only 1.2% of the population, so these results were most likely due to sample size bias. In addition to the rare prevalence of MC at C7–T1, the absence of other degenerative lesions investigated was a potential bias for the association of clinical outcomes with lesions at this level (Baker, et al., 2020). This was also supported by Baker's statement in his next study, which found that the presence of several degenerative lesion phenotypes (MC and endplate abnormalities at the same time) was more significant in determining the clinical outcome of post-ACDF patients than calculations of each phenotype (Baker, et al., 2022).

In addition to these two studies, we also obtained two other studies which stated that the presence of MC was correlated with significant clinical improvement after ACDF. Research by Li, et al., (2017) states that MC type II gets good clinical improvement, both through ACDF and TDR surgery ( $P<0.05$ ) (20). Another study by Harada, et al., (2021) also stated that MC types I and III correlated with improved NDI and VAS scores of the hands and neck. In addition, type II MC also correlates with a reduced incidence of ASDeg, which is one of the clinical deteriorations in patients (Harada, et al., 2021). In ACDF, the majority of the inflamed disc is removed, thereby reducing the pain caused by inflammation and reducing further endplate abrasion. In addition, bone fusion creates stability so that further endplate damage can be prevented (Li, et al., 2017). MC studies in the lumbar spine show that MC can regress and progress based on pre- and postoperative bone biomechanics. This is something that cannot be overlooked in relation to clinical outcomes (Portella and Acioly, 2017). Nonetheless, this significant clinical improvement could also be due to the patient's preoperative condition, which was worse due to MC or other degenerative lesions. Various studies state that the presence of MC is associated with high preoperative disability in the patients. Baker, et al., (2020) stated that MC is associated with older age, a longer duration of symptoms, and more fused segments. This can affect the assessment of clinical improvement after ACDF, lead to bias in the assessment by patients, and generate further questions about whether MC is related to clinical improvement or simply does not affect clinical improvement after ACDF because improvement is generally obtained from the loss of existing preoperative disability (Baker, et al., 2020).

### Strength and limitations

Research on the effect of Modic change is still very rare, and there is no systematic review that specifically discusses the effect of Modic change on the clinical outcome of patients undergoing operative therapy, especially ACDF. Therefore, this study was conducted to determine whether the variable of Modic change in patients undergoing ACDF therapy had an effect on the patient's clinical outcome or not.

Although further research is needed with more studies regarding Modic change variables and clinical outcomes after ACDF, based on the results of the review of the six studies that have been conducted, the researchers concluded that the presence of Modic changes in preoperative MRI images tends to have no effect on postoperative clinical outcomes. Nonetheless, the presence of preoperative Modic changes

remains a risk factor for postoperative disabling conditions, including axial symptoms, and is associated with a worse preoperative clinical condition.

## CONCLUSION

The presence of preoperative Modic changes tends not to affect clinical outcomes after ACDF due to degenerative pathology, including disc herniation but remains a risk factor for postoperative disability and correlates with a worse preoperative picture. ACDF can be performed on patients with cervical disc herniation with Modic change on MRI because ACDF can significantly treat preoperative symptoms without being affected by Modic change. A systematic review or meta-analysis on the same topic using a larger sample of articles could be carried out in the future to provide a more extensive explanation of the effect of Modic change on ACDF.

## Acknowledgment

Special thanks to the supervisor of this research and all of the team that has been working in this paper together.

## Conflict of Interest

All authors have no conflict of interest.

## Funding

This research was not funded by any funding agencies, commercials, nor non-profit sectors.

## Author Contribution

CAW contributes to conception and design, analysis and interpretation of the data, drafting of the article, critical revision of the article for important intellectual content, and final approval of the article. SAU contributes to conception and design, critical revision of the article for important intellectual content, and final approval of the article.

## REFERENCES

- Applebaum, A., Nessim, A., Cho, W. 2022. Modic Change. *Clinical Spine Surgery: A Spine Publication*, 35(1): 12–17. doi: [10.1097/BSD.0000000000001168](https://doi.org/10.1097/BSD.0000000000001168).
- Baker, J.D., Harada, G.K., Tao, Y., Louie, P.K., Basques, B.A., et al. (2020) The impact of Modic Changes on preoperative symptoms and clinical outcomes in anterior cervical discectomy and fusion patients. *Neurospine*, 17(1): 190–203. doi: [10.14245/ns.2040062.031](https://doi.org/10.14245/ns.2040062.031).
- Baker, J.D., Sayari, A.J., Harada, G.K., Tao, Y., Louie, P.K., et al. 2022. The modic-endplate-complex phenotype in cervical spine patients: Association with symptoms and outcomes. *Journal of Orthopaedic Research*, 40(2): 449–459. doi: [10.1002/jor.25042](https://doi.org/10.1002/jor.25042).
- Brooks, M., Dower, A., Jalil, M.F.A., Kohan, S. 2021. Radiological predictors of recurrent lumbar disc herniation: a systematic review and meta-analysis. *Journal of Neurosurgery: Spine*, 34(3): 481–491. doi: [10.3171/2020.6.SPINE20598](https://doi.org/10.3171/2020.6.SPINE20598).
- de Ciccio, F.L., Willhuber, G.O.C. 2023. Nucleus pulposus herniation, StatPearls. Available at: <http://www.ncbi.nlm.nih.gov/pubmed/17268274>.
- Djuric, N., Yang, X., Ostelo, R.W.J.G., van Duinen, S.G., Nijeholt, G.J., et al. 2019. Disc inflammation and Modic changes show an interaction effect on recovery after surgery for lumbar disc herniation', *European Spine Journal*, 28(11): 2579–2587. doi: [10.1007/s00586-019-06108-9](https://doi.org/10.1007/s00586-019-06108-9).
- Dydyk, A.M., Massa, R.N., Mesfin, F.B. 2023. Disc herniation, StatPearls. Available at: <http://www.ncbi.nlm.nih.gov/pubmed/30943704>.
- Gierisch, J. M., Beadles, C., Shapiro, A., McDuffie, J. R., Cunningham, N., et al. 2014. Health disparities in quality indicators of healthcare among adults with mental illness [Internet]. Washington (DC): Department of Veterans Affairs (US). Available at: <https://pubmed.ncbi.nlm.nih.gov/26065051/>
- Harada, G.K., Tao, Y., Louie, P.K., Basques, B.A., Galbusera, F., et al. 2021. Cervical spine MRI phenotypes and prediction of pain, disability and adjacent segment degeneration/disease after ACDF.



- Journal of Orthopaedic Research, 39(3): 657–670. doi: [10.1002/jor.24658](https://doi.org/10.1002/jor.24658).
- Huang, K., Hong, Y., Liu, H., Duan, Y., Wang, B., et al. 2020. Is the bone fusion affected by Modic-2 changes in single-level anterior cervical discectomy and fusion?. *Medicine*, 99(1): e18597. doi: [10.1097/MD.00000000000018597](https://doi.org/10.1097/MD.00000000000018597).
- Kim, Y.K., Kang, D., Lee, I., Kim, S.Y. 2018. Differences in the incidence of symptomatic cervical and lumbar disc herniation according to age, sex and national health insurance eligibility: A pilot study on the disease's association with work. *International Journal of Environmental Research and Public Health*, 15(10): 2094. doi: [10.3390/ijerph15102094](https://doi.org/10.3390/ijerph15102094).
- Kressig, M., Peterson, C.K., McChurch, K., Schmid, C., Leemann, S., et al. 2016. Relationship of modic changes, disk herniation morphology, and axial location to outcomes in symptomatic cervical disk herniation patients treated with high-velocity, low-amplitude spinal Manipulation: A Prospective Study. *Journal of Manipulative and Physiological Therapeutics*, 39(8): 565–575. doi: [10.1016/j.jmpt.2016.08.004](https://doi.org/10.1016/j.jmpt.2016.08.004).
- Kumarasamy, D., Rajasekaran, S., Anand, S.V., Soundararajan, D.C., Shetty, A.P., et al. 2022. Lumbar disc herniation and preoperative modic changes: A prospective analysis of the clinical outcomes after microdiscectomy', *Global Spine Journal*, 12(5): 940–951. doi: [10.1177/2192568220976089](https://doi.org/10.1177/2192568220976089).
- Laustsen, A.F., Bech-Azeddine, R. 2016. Do modic changes have an impact on clinical outcome in lumbar spine surgery? A systematic literature review. *European Spine Journal*, 25(11): 3735–3745. doi: [10.1007/s00586-016-4609-y](https://doi.org/10.1007/s00586-016-4609-y).
- Li, J., Zhang, D., Ding, W., Zhang, Y., Shen, Y. 2017. Comparison of clinical outcomes after anterior cervical discectomy and fusion versus cervical total disk replacement in patients with modic-2 changes on MRI', *Clinical Spine Surgery: A Spine Publication*, 30(8): E1088–E1092. doi: [10.1097/BSJ.0000000000000226](https://doi.org/10.1097/BSJ.0000000000000226).
- Määttä, J.H., Karppinen, J.I., Luk, K.D.K., Cheung, K.M.C., Samartzis, D. 2015. Phenotype profiling of Modic changes of the lumbar spine and its association with other MRI phenotypes: a large-scale population-based study. *The Spine Journal*, 15(9): 1933–1942. doi: [10.1016/j.spinee.2015.06.056](https://doi.org/10.1016/j.spinee.2015.06.056).
- Oitment, C., Watson, T., Lam, V., Aref, M., Koziarz, A., et al. 2020. The role of anterior cervical discectomy and fusion on relieving axial neck pain in patients with single-level disease: A systematic review and meta-analysis. *Global Spine Journal*, 10(3): 312–323. doi: [10.1177/2192568219837923](https://doi.org/10.1177/2192568219837923).
- Papanastasiou, E.I., Theodorou, D.J., Theodorou, S.J., Pakos, E.E., Ploumis, A., et al. 2020. Association between MRI findings and clinical outcomes in a period of 5 years after lumbar spine microdiscectomy. *European Journal of Orthopaedic Surgery & Traumatology*, 30(3): 441–446. doi: [10.1007/s00590-019-02588-z](https://doi.org/10.1007/s00590-019-02588-z).
- Portella, S.T., Acioly, M.A. 2017. The course of Modic vertebral body changes after posterolateral lumbar fusion on fused and adjacent levels: A systematic review of the literature. *Journal of Clinical Neuroscience*, 41: 6–10. doi: [10.1016/j.jocn.2017.04.007](https://doi.org/10.1016/j.jocn.2017.04.007).
- Sharrak, S., Al Khalili, Y. 2023. Cervical disc herniation, StatPearls. Available at: <http://www.ncbi.nlm.nih.gov/pubmed/0>.
- Zhou, J., Li, L., Li, T., Xue, Y. 2018. Preoperative Modic changes are related to axial symptoms after anterior cervical discectomy and fusion. *Journal of Pain Research*. 11: 2617–2623. doi: [10.2147/JPR.S172953](https://doi.org/10.2147/JPR.S172953).