



A Systematic Review: Early Simultaneous Vomer Flap with Primary Cleft Lip Repair, Does it Bring More Benefits?

The Cleft Palate Craniofacial Journal
1-11© 2023, American Cleft Palate
Craniofacial Association
Article reuse guidelines:
sagepub.com/journals-permissions
DOI: 10.1177/10556656231192295
journals.sagepub.com/home/cpc

Indri Lakshmi Putri, MD, PhD^{1,2} , Evan Savero Widiono, MD³ ,
Stephanie Liana, MD⁴, Sandro Ruberto, MD⁴,
and Citrawati Dyah Kencono Wungu, MD, PhD⁵

Abstract

Introduction: Vomer flap is a technique to close cleft lip and palate. This technique is a simple procedure that has many benefits. However, the vomer flap's application together with primary lip closure is still questionable.

Objective: To find out whether the vomer flap's application in primary cleft lip repair can provide significant benefits

Design: A systematic review was conducted using the PRISMA methodology has been licensed in PROSPERO databases (CRD42023399487).

Setting: A comprehensive search was set out, utilizing eight data sources up to March 2023.

Participants: Both cohort studies and randomized control trials regarding the use of vomer flaps performed concurrently with cleft lip repair in children up to six months old.

Results: This article involved 8 studies involving 542 patients who met the inclusion criteria, consisting of 6 retrospective cohort studies, 1 RCT study, and 1 prospective cohort study. Vomer flaps provide a reduction in palatal cleft distance of 3–5 mm, a relatively small number of fistulas (0–4%), improvement of velopharyngeal function (nasal tone and nasal emission), maximal development of the maxilla although it is still controversial.

Conclusion: The vomer flap's application in primary cleft lip repair provides many advantages, such as reduced palatal and alveolar clefts, decreased risk of oronasal fistula, increased velopharyngeal function, and increased maxillary growth. It is reliable for the management of cleft lip and palate.

Keywords

cleft lip palate, vomer flap, palatoplasty, cleft lip repair, medical care

Introduction

Cleft lip and palate (CLP) is a congenital dysmorphology commonly found within the craniofacial region.^{1,2} According to WHO, the prevalence of CLP is around 1: 700 live births, the highest being of Asian descent with 14: 10000 live births.^{3,4} Indonesia is recorded to have a prevalence of CLP of around 0.2%.⁵ There have been many procedures introduced to treat CLP, all with the same goal in mind: an aesthetically pleasing appearance, adequate speech outcome and minimal impact on craniofacial growth. Several complications most commonly found are surgical wound dehiscence, partial or total necrosis of the flap, floating palate, and oronasal fistula, in which the latest studies reported variation in oronasal fistula incidence between 0% and 77.8%, making it the most frequent complication in palatal repair.^{6–8} The most common

¹ Department of Plastic Reconstructive and Aesthetic Surgery, Faculty of Medicine, Airlangga University, Surabaya, Indonesia

² Plastic Reconstructive and Aesthetic Surgery Unit, Airlangga University Hospital, Surabaya, Indonesia

³ General Practitioner, Bendan General Hospital, Pekalongan, Indonesia

⁴ Medical Student, Faculty of Medicine, Diponegoro University, Semarang, Indonesia

⁵ Department of Physiology and Medical Biochemistry, Faculty of Medicine, Airlangga University, Surabaya, Indonesia

Corresponding Author:

Indri Lakshmi Putri, Department of Plastic Reconstructive and Aesthetic Surgery, Faculty of Medicine, Airlangga University, Plastic Reconstructive and Aesthetic Surgery Unit, Airlangga University Hospital, Surabaya, Jl. Mayjend Moestopo 6-8, 60131, East Java, Indonesia.

Emails: indrilakshmi Putri@fk.unair.ac.id, indrilakshmi Putri@gmail.com

signs of oronasal fistula are nasal regurgitation and hypernasality of speech. In terms of surgery techniques and experiences, the major reason is thought to be the restoration of cleft palate under stress, while vascular injuries, poor hygiene, and infection may also constitute contributing factors. However, certain cleft palates are somewhat large, and having enough tissue to rebuild the palate appears insufficient.⁹

Pichler, in 1934, explained a palatal closure method that involves tucking a single cranial-based flap of the vomerine's mucoperiosteum and the nasal septum's mucoperichondrium under the raised margin of oral mucoperiosteum on the opposite side of the cleft, exposing the raw surface of the nasal septum exposed and allowing it to heal with epithelialization.^{10,11}

This technique uses a soft tissue flap from the vomer or nasal septum to close a defect in the hard palate region. The tissue is delicate but highly vascular, and if properly manipulated, will develop as the free-floating flap. The procedure is relatively simple but with satisfying results.¹² Several studies showed no reports of maxillary growth stunts. The dental arch grew as it should, providing sufficient space for dental accommodation. The facial growth was reported to be adequate with no sub malar depression and no disorders of the maxillo-facial growth. Therefore, this procedure was frequently employed, albeit with modest modifications to meet each circumstance.^{13,14}

However, there are investigations reporting contradictory results, demonstrating that the vomer's flap application causes scarring at the vomero-premaxillary suture, which means slowing anterior midface development.¹⁵ Despite patients having final palatoplasty using the "push back" method, Friede and Johanson's cohort study discovered poor craniofacial growth in complete bilateral and unilateral vomer flaps performed between 1964 and 1970.¹⁶

Deshpande et al. initiated a retrospective analysis on 101 non-syndromic CLP, calling into doubt the efficacy of simultaneous hard palate and cleft lip repair employing a vomer flap. The findings found that almost 100% flap successes were seen in about half of the cases, whereas 50% flap successes occurred in nearly a quarter of the cases. Vomer flap's failure is linked with a greater probability of fistula and wound dehiscence even after palatal cleft closure.^{17,18} Even though vomer flaps succeeded, the palate failed to be closed without releasing the incision, limiting subsequent palatal repair.^{14,18,19}

Considering the multiple contradictory reports on the efficacy and complications of early vomer flaps, this research examines the utilization of vomer flaps performed concurrently during labioplasty up to the age of six months.

Method

This research has been licensed in PROSPERO databases (CRD42023399487) and was completed in line with the Preferred Reporting Items for Systematic Review and Meta-Analyses (PRISMA) statement.²⁰

Eligibility Criteria

For our study's inclusion criteria, we specifically considered published papers that met certain parameters. These parameters included both cohort studies and randomized control trials that showed data on any outcome related to palate repair using a vomer flap along with cleft lip repair in children up to six months old. Additionally, we included controlled studies focused solely on cleft lip repair in children up to six months old. To ensure consistency, we limited our analysis to articles available in full text, written in English, and conducted on human subjects.

Conversely, we excluded articles featuring samples that underwent surgery either with or without vomer flaps, whether performed simultaneously with cleft lip repair or not, but at an age exceeding six months. This decision was based on our study's goal of evaluating early vomer flap repair, which was performed at the initial stage of CLP surgery, namely cleft lip repair, when children were up to six months old. By implementing these inclusion and exclusion criteria, we aimed to ensure the relevance and validity of the data included in our study.

Search Strategy and Selection Studies

To identify studies related to the use of vomer flaps in cleft palate and cleft lip closure, we systematically searched the PubMed, Scopus, Science Direct, Cochrane, EBSCO, Web of Science, Clinicaltrials.gov, and Proquest databases that were published through March 2023, apart from that we also looked for gray literature using Pre-print and Medrxiv. The term the search is as follows: vomer flap, early vomer flap, cleft lip repair, early cleft lip repair, primary cleft lip repair, labioplasty, cheilorrhaphy, early hard palate repair, early palatoplasty, and early palatorrhaphy. This term is used in combination with "AND" or "OR", depending on the search engine utilized (see the Appendix). Two investigators conducted the literature review autonomously, with a third reviewer settling any disagreements as required.

Quality Assessment

Two authors autonomously selected necessary data, including author, year of publication, article title, country of origin, type of study, and variable measured, then determined the size of the sample, sex characteristics, and average age when treated in the study. Then we will extract the results of the variables measured in each study found.

To assess the quality of the included studies, we employed specific evaluation tools. We used a quality assessment tool for the cohort study using a modified New Castle Ottawa (NOS) scale,²¹ with maximum score of nine points. The NOS assesses three domains: study group selection (four points), group comparability (two points); and ascertainment of exposure and outcome (three points). In accordance with the overall score, we sorted the studies as having a low risk of bias (≥ 7

points), a moderate risk of bias (5–6 points), or a high risk of bias (≤ 4 points). Meanwhile, for the randomized controlled trial study, we used the JADAD score consisting of three items: randomization (0–2 points), blinding (0–2 points), and dropout and withdrawal (0–1 points).²² The response to each item is “Yes” (1 point) or “No” (0 points). Final points range from 0 to 5 points, with higher points signifying better-quality reporting. JADAD scores of 2 points or less indicate low quality, whereas JADAD scores of 3 points or above indicate excellent quality. All authors discussed and settled any disputes.

Statistical Analysis

Due to significant variations in the comparisons made among research articles and the diversity of outcome measures, conducting a meta-analysis was not feasible for our study. Instead, we will employ a narrative synthesis approach to analyze each piece of evidence individually. This process will involve dividing the outcomes into relevant subsections using appropriate subtitles. Subsequently, we will compare the treatment group to the control group in a descriptive manner, providing a comprehensive narrative analysis of the available evidence. This method will allow us to synthesize the findings effectively, despite the inability to perform a meta-analysis due to the aforementioned differences in study designs and outcome measures.

Result

Study Selection

Based on screening strategies, 2568 pertinent investigations were retrieved from sources. We used the Mendeley Reference Manager to remove 558 duplicate studies, meta-analyses, systematic reviews, case reports, case series, and reviews. Subsequently, 986 pertinent investigations were omitted based on the title and abstract, and 328 papers were eliminated after reviewing the whole article. In the gray literature we found 6 related studies, but then we excluded all studies. Moreover, this systematic review comprised a total of eight studies. Figure 1 depicts the PRISMA flowcharts of the included investigations.²⁰

General Characteristic

Three studies were from Continental Europe (England, Netherlands, Finland), four studies were from Continent Asia (China, Taiwan, Japan, and India), and 1 study was from the African continent (Egypt). The total number of samples from the eight articles that we used was 542, and each article had a sample size ranging from 40 to 140. The number of male patients ranged from 12 to 76, while the number of female patients ranged from 11 to 41. The average age of patients undergoing surgery in the vomer flap and lip repair treatment group was 4.1 months, while the mean age of patients

undergoing surgery in the control group was 4.2 months. Seven articles on lip repair use a modified Millard technique, while 1 article uses a modified Mohler technique. Six studies were retrospective cohort studies, 1 prospective cohort study, and 1 RCT study. Table 1 shows the overall features of the eight selected studies.

Quality Assessment

The study assessment used the New Castle Ottawa score for the cohort study, where in 7 studies scores ranged from 7–9 which were included in high-quality studies, while the RCT study assessment used the JADAD score and obtained a score of 5, which was included in good research. The detailed results of the study quality assessments are listed in Table 2 and Table 3.

Gap Reduction

The use of a vomer flap provides an advantage in terms of reducing the gap between the alveolar gap and the gap itself. Two published research articles showed that the vomer flap's application resulting a substantial reduction in gap distance (3–5 mm) compared to the control group using vomer flaps (0.8–1.5 mm) ($p < 0.005$).^{23,24} See Table 1.

Incidence of Fistula

Fistula is one of the complications that often occur in flap closure. Closing the cleft palate using the vomer flap method provides advantages by reducing the incidence of fistulas. Two studies have shown that the incidence of fistulas in patients who use vomer flaps is only around 0–4% compared to patients who do not receive vomer flaps 4–14%. This study also shows an evaluation of the occurrence of fistulas at the age of 18 months, where at the age of 18 months a definitive cleft palatal closure is usually done, so that the use of this vomer flap can also facilitate the second stage of surgery.^{23,25} See Table 1.

Velopharyngeal Function

The use of vomer flaps also provides benefits in terms of velopharyngeal function, a study shows that vomer flaps provide good output on nasal tone and nasal emission so that patients can provide better sound output. Two subsequent studies showed that the vomer flap group provided better outcomes in terms of velopharyngeal function than the non-vomer flap group, although two did not provide statistically significant differences.^{25,26} See Table 1.

Maxillary Growth

The 4 studies presented in this article present the pros and cons of using the Vomer Flap, respectively. Xu et al. and Alam et al. noticed that the Vomer flap had adverse consequences for maxillary growth. However, Xu et al. conclude that the vomer

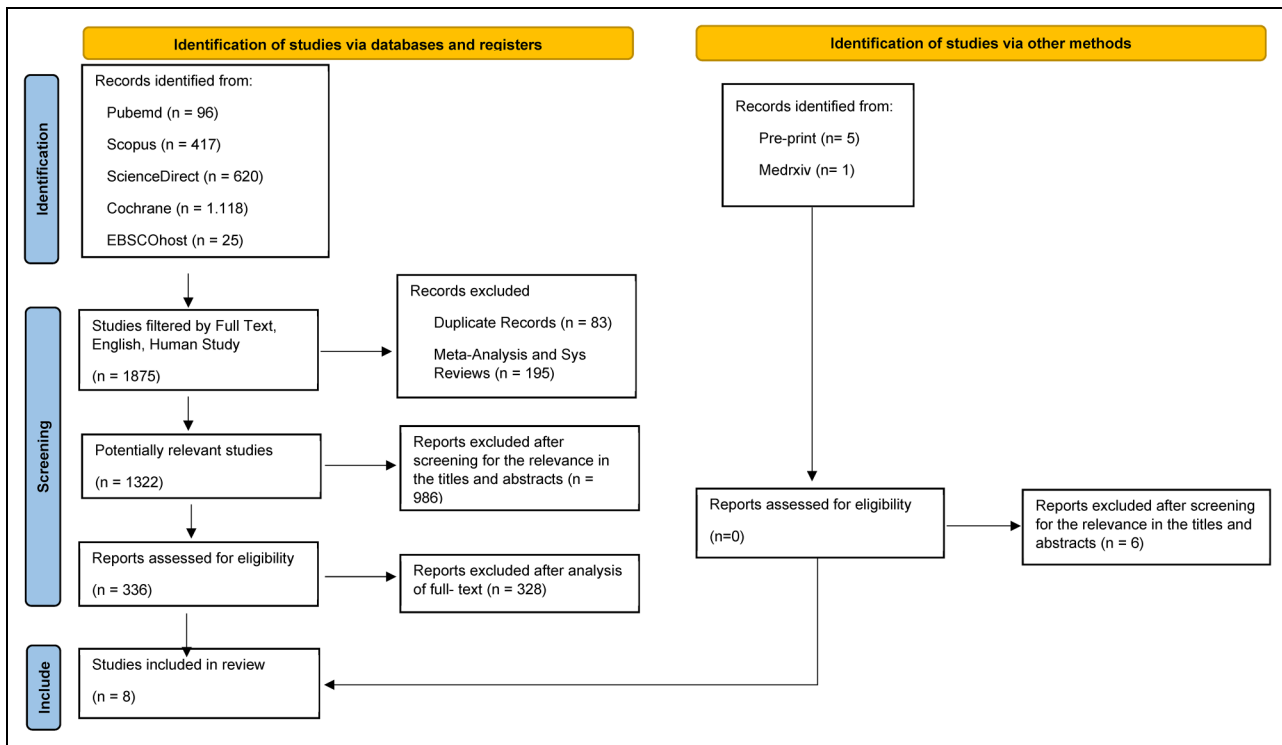


Figure 1. PRISMA flowchart.

flap's application is favorable in terms of offering efficiency for palatal closure in the next steps. In contrast to the two previous studies, Ganesh et al. and Wong et al. observed that the vomer flap had a positive effect on the growth of the facial bones, particularly the maxillary bone.²⁷⁻³⁰ See Table 1.

Discussion

Treatment for unilateral CLP has evolved significantly over the previous few decades, and surgical procedures are continually advancing. To protect the nasal lining during palatal closure, the Vomer flap employed mucoperichondrial and mucoperiosteal flaps, which are still questioned in terms of risks and benefits.³¹ However, the study analysis presented in this publication reveals that the vomer flap's application together with primary lip repair up to 6 months of age can be exceptionally trustworthy, although risks can still arise.²⁴

In numerous investigations, the ages of patients with CLP employing the vomer flap ranged from 4 months to 9 years.³² It is predicted that by sealing the hard palate, the space left in the soft palate would close spontaneously as well. However, there is limited evidence that using a vomer flap has any significant advantage in reducing the cleft, particularly in children under the age of six months.²⁴ Therefore, we gathered some literature that can offer data on the usage of vomer flaps in children under the age of six months.

In several articles, it has been shown that the use of vomer flaps can reduce the distance between clefts, the distance between palatal slits, the distance between alveolar slits, and

the distance between clefts of the uvula.²⁴ De Jong et al.²³ showed a significant reduction in the distance ($p < 0.05$), so it was hoped that narrowing the clefts would be of benefit in reducing complications such as fistula occurrence and facilitating surgery for definitive closure of the hard palate. This reduction in cleft spacing may be due solely to the new tissue creation from the vomer flap used for anterior palate closure during labioplasty. In addition, many studies also state that the greater the reduction in the distance between the gaps, the lower the number of fistulas.

There are differences between 4 studies regarding early vomer flap and maxillary growth. In this maxillary development, the average study provides follow-up after 7–10 years. Ganesh et al.²⁹ and Wong et al.³⁰ concluded that vomer flap technique is favorable in terms of maxillary growth. Meanwhile, Xu et al.²⁷ and Alam et al.²⁸ concluded that vomer flap technique is unfavorable in terms of maxillary growth. Alam et al. believed that scarring slows maxillary growth, a later age for hard palate closure will result in less growth disruption and better maxilla final growth. However, the number of patients in the study conducted by Ganesh et al.²⁹ and Wong et al.³⁰ was greater than the study conducted by Xu et al.²⁷ and Alam et al.,²⁸ so this could provide insight that the vomer flaps technique is favorable in terms of maxillary growth. Moreover, the research conducted by Ganesh et al.²⁹ is a randomized controlled trial, whereas the other studies are retrospective analyses. Xu et al.²⁷ later emphasized the importance of deferring the final evaluation until the facial bone is completely mature. This is also consistent with Ganesh

Table 1. Study Characteristics.

No	Author, Year of publish	Country	Study type	Measured variable	Treatment; N	Control; N	Characteristic	Result	Information
1	Maggiulli F, et al.; 2014 ²³	England	Retrospective study	Alveolar cleft width between 3 months and 6 months after surgery	Lip repair (modified Millard technique) + vomer flap; 18	Lip Repair (modified Millard technique); 22	Gender N/A; Mean age from study and treatment group: 3 months	Study: -3.76 (3.57); Control: -0.82 (1.48); p 0.004	The VF group provided a significant reduction in the alveolar gap distance compared to the non-VF group
2	Johanna P. de Jong, et al.; 2013 ²²	Netherland	Retrospective analysis	Differences in cleft width at 7 and 11 months of age	Lip repair + vomer flap; 25	Lip repair; 22	Gender: Male 34 (72%), female 13 (28%); Mean age: treatment 4 months, control 4.4 months	Study: 5.0 ± 1.9; Control: 1.5 ± 2.2; p < 0.01 *	The VF group provided a significant reduction in the cleft width the slits compared to the control group
3	Veera Ahti, et al.; 2020 ²⁴	Finland	Retrospective analysis	Differences in fistula incidence at 18 months of age	Lip repair + vomer flap; 25	Lip repair; 22	Gender: Male 34 (72%), female 13 (28%); Mean age: treatment 4 months, control 4.4 months	Study: 0; Control 14%; p 0.095	The control group gave a greater incidence of fistulas than the study group, although there was no significant difference
3	Veera Ahti, et al.; 2020 ²⁴	Finland	Retrospective analysis	Fistula incidence at 5 years old	Lip repair (modified Millard method) + vomer flap; 67	Lip repair (modified Millard method); 50	Gender: Male 76 (65%), female 41 (35%); Median age, control: 4,2 months, Study: 4,1 months.	Control: 2 patients (4%); study: 3 patients (4%); (P = 0.635).	There is no significant difference existed in the prevalence of fistulas between the study group the and control group
4	Xue Xu, et al.; 2019 ²⁶	China	Retrospective analysis	Velopharyngeal Function at 3 and 5 years old	Lip repair (modified Millard method) + vomer flap; 67	Lip repair (modified Millard method); 50	Gender: Male 76 (65%), female 41 (35%); Median age, control: 4,2 months, Study: 4,1 months.	Normal or borderline competent velopharyngeal function in 74% of patients in control, and 72% of patients in study at 3 years of age before palatal reoperations (VF at 3 years p 0.805); 5 years of age, the corresponding figures were controlled 82%, and study 92% (VF at 5 years p 0.409)	There is no significant differences emerged in velopharyngeal competence at ages 3 and 5 years between the study and the group
4	Xue Xu, et al.; 2019 ²⁶	China	Retrospective analysis	Anterior facial height, Posterior facial height	Lip repair + vomer flap; 23	Lip repair; 17	Gender: study group 12 male 11 female, Control group 6	(Anterior nasal spine-nasion, anterior nasal spine-menton, nasion-menton; p	Vomer flap repair with denuded bone inhibited maxillary vertical

(continued)

Table 1. (continued)

No	Author, Year of publish	Country	Study type	Measured variable	Treatment; N	Control; N	Characteristic	Result	Information
5	Praveen Ganesh, et al.; 2015 ²⁸	India	RCT	(Measured at the age of 7-8 years) GOSLON SCORE at the mean age of 7.8 years for the VF procedure and 8.1 years for the TF procedure	Lip repair (Millard technique + nose correction) + Vomer flap: 40	Lip repair (Millard technique); 45	Gender: 24 male patients and 16 female patients; mean age study group 5.22 months, control group 6.3 months	<0.05) and posterior facial height (registration point-posterior maxillary point; $p < 0.05$) than groups 3 and 4. In the VF group, 70% of the patients demonstrated good growth and 30% revealed adequate growth. In the TF group, 54% of the patients displayed good growth, 37.7% had the adequate growth category, and 8.8% had poor growth. Hypernasality ($p = 0.05$) and weak oral pressure consonants at the level of words and sentences ($p =$ 0.014), with better outcomes in the TF group	growth, although it reduced the difficulties with and need for lateral releasing incisions at palate repair. Patients in the VF group showed slightly better growth potential than those in the TF;
6	Ali Abde Elfatah M., et al.; 2014 ²⁵	Egypt	Prospective Study	Speech assessment using Universal parameters for reporting speech at the mean age of 7.8 years The grade of nasality, the nasal emission of air, and the grade of closure of VPV at 13 months, 18 months, and 2 years of age	Lip repair (Millard technique + nose correction) + Vomer flap: 40	Lip repair (Millard technique); 45	Gender: 24 male patients and 16 female patients; mean age study group 5.22 months, control group 6.3 months Gender: 19 male (63.3%) and 11 female (36.7%); Mean age of study and control group 3-4 month	Results at 13 months of age: grade of nasality $p < 0.05$; audible nasal air emissions $p < 0.05$; velopharyngeal valve $p > 0.05$; Results at 1.5 years postoperatively: smoothness level $p < 0.05$; audible nasal air emissions $p < 0.05$; velopharyngeal valve $p < 0.05$; Results at 2 years of age: grade of nasality $p < 0.05$; audible nasal air emissions $p <$ 0.005; velopharyngeal valve $p < 0.05$	The patients in the TF group showed better speech outcomes than the CF group The early closure of the hard palate prepares for better results of later soft palate closure, which in turn improves nasal tone and nasal emission of air during speech and crying.
7	M.K. Alam,	Japan	Retrospective analysis	Knowing the maxillofacial morphology as seen by	Lip repair (Millard	Lip Repair (Millard	Gender: male 76 female 64; Mean	The treatment effect on sella-nasion-point A in the	The maxillofacial morphology was better

(continued)

Table 1. (continued)

Author; Year of No publish	Country	Study type	Measured variable	Treatment; N	Control; N	Characteristic	Result	Information
et al.; 2012 ²⁷			sella-nasion-point A, nasion-point A-pogonion, upper incisor-sella nasion	procedure) + vomer flap; 80	procedure); 60	age from study and treatment group: 5 months	control and study groups was not significant (p = 0.06), the treatment effect on the nasion-point A-pogonion in the control and study groups was significant (p = 0.04), the treatment effect on the upper incisor-sella nasion control group and study not significant (p = 0.70)	in the control group than in the study group
8 Ling Siew Wong, et al., 2020 ²⁹	Taiwan	Retrospective analysis	To compare 10-year facial growth of 2 surgical protocols in the treatment of patients with unilateral cleft lip and palate (UCLP).	Lip repair (modified Mohler technique) + vomer flap; 20	Lip Repair (modified Mohler technique); 23	Gender: male 26, female 17; mean age: study group 3.50 months, control group 42.6 months	At the ages of 5 and 7, there was no significant difference of maxillary and mandibular growth in both groups. At the age of 9 years, all the angular measurements revealed statistical significance with SNA (P = 0.02), SNB (P = 0.05), ANB (P < 0.01), and SNPg (P = 0.05).	This study has shown that vomer flap repair at 3 months of age results in better maxillary growth and less mandibular prognathism.

Table 2. Quality Assessment (Modified New Castle Ottawa Scale).

Modified New-Castle Ottawa Scale										
Selection			Comparability			Outcome				
Study ID	Representativeness of exposed cohort (1)	Selection of non-exposed cohort (1)	Ascertainment of exposure (1)	Outcome of interest not present at the start of the study (1)	Comparability of cohorts based on the design or analysis (2)	Assessment of outcome (1)	Sufficient follow-up time (1)	Adequacy of follow-up of cohort (1)	Total score (out of 9)	Power
Maggiulli F; 2014					2				8	High Quality
Johanna P. de Jong; 2013					2				7	High Quality
Veera Ahti; 2020					2				9	High Quality
Xue Xu; 2019					2				8	High Quality
Ali Abde Elfatah M; 2014					2				8	High Quality
Wong; 2020					2				9	High Quality
Alam; 2012					2				9	High Quality

Table 3. Quality Assessment (JADAD Scale).

JADAD Scale	
Item Assesed	Praveen Ganesh; 2015
Was the study described as randomized?	Yes
Was the method of randomization appropriate?	Not described
Was the study described as blinded?	Yes
Was the method of blinding appropriate?	Not described
Was there a description of withdrawals and dropouts?	Yes
Was there a clear description of the inclusion/exclusion criteria?	Yes
Was the method used to assess adverse effects described?	Not described
Was the method of statistical analysis described?	Yes
Scores	5

et al.²⁹ and Alam et al.,²⁸ suggesting further follow-up once maxillary growth is complete at puberty. Genetic and/or environmental factors influence the growth of the maxilla and mandible.

Fistula incidence is an important factor to be assessed since it has a negative impact on articulation.^{17,19} Numerous investigations have shown that hard palate closure with a vomer flap correlates with a reduced number of fistulas. Which may be the consequence of significant cleft narrowing. However, a study from Ahti et al.²⁵ found that labioplasty and hard palate closure with a vomer flap at 4 months of age followed by soft palate closure at 10 months of age versus labioplasty at 4 months of age followed by complete palate closure at 12 months of age did not differ (4% versus 4%). Another study by de Jong et al.²³ also revealed no significant fistula incidence between patients receiving lip repair and vomer flap and patients receiving only lip repair on their first surgery. Though it is important to note, that smaller residual clefts make way for a simpler follow-up repair regardless of the fistula incidence.

The patient's speech quality frequently serves as a barometer for the success or failure of cleft surgery results. However, it is not a simple measurement due to the fact that it is subjective, depending on the examiner. Several reports have stated different outcomes in the quality of speech of patients. In 2015, Ganesh et al.²⁹ employed a universal metric for reporting speech and discovered that the Two Flap approach is superior to the Vomer Flap in terms of hypernasality and weak oral pressure in patients aged 4 to 6 years. Another study, Ahti et al.²⁵ found no statistically significant variance between the vomer flap and non-vomer flap groups at 3 and 5 years of age. However, Ali et al.²⁶ demonstrated conflicting results, in which they documented the audio recordings of the patients and had three judges score them, as well as tracked the velum's movement and lateral pharyngeal walls using video nasoendoscopy. At 13 months, 18 months, and 24 months, they reported substantial changes in favor of the vomer flap

group. Among these studies, the study by Ali et al.²⁶ seems to be more advantageous since they include an objective measure from the nasoendoscopy. Another difficulty in speech assessment is determining when the right time is for its evaluation. One study argues speech assessment right after surgery, or at least one month after surgery, has a risk of being misinterpreted as edema secondary to surgery.²⁶ Another study stated that evaluations are warranted after speech development is completed and highlighted the importance of assessments done at 3 years of age.²⁵

This article provides the strength that the use of vomer flaps can be one of the techniques used in repairing palatal clefts, but we are still aware of several limitations in writing this article, including the relatively small number of studies, small number of samples in each study, single-center study, and the assessment parameters are not uniform. We hope that future studies will provide uniform assessment parameters with a larger sample size in a multicenter study.

Conclusion

The vomer flap's application in primary cleft lip repair provides many benefits, including reduction of palatal and alveolar clefts, reduced risk of oronasal fistula, improved velopharyngeal function, and improved maxillary growth, although this is still controversial. Overall, this is a reliable technique for CLP.

Acknowledgment

We thank the authors of articles included in this systematic review for the advancement of science.

Authors Contributions

Conceptualization, ILP, CDK; Data Collection, ESW, SL, SR; Methodology, ILP, CDK; Writing-Original Draft Preparation, ESW, SL, SR; Writing-Review & Editing, ILP, CDK. All authors have critically reviewed and approved the final draft and are responsible for the content and similarity index of the manuscript.

Declaration of Conflicting Interests

The authors declared no potential conflicts of interest with respect to the research, authorship, and/or publication of this article.



Ethical Approval

No ethical approval was required since the study is a systematic review.

Funding

The authors received no financial support for the research, authorship, and/or publication of this article.

ORCID iDs

Indri Lakhsmi Putri  <https://orcid.org/0000-0001-6668-6496>
Evan Savero Widiono  <https://orcid.org/0000-0002-0938-8123>

Reference

- Onah I, Okoye C, Bala E. Early cleft lip and palate repair: Experience of the National Orthopedic Hospital Enugu, Southeast Nigeria. *J Cleft Lip Palate Craniofacial Anomalies*. 2019;6(2):99. doi:10.4103/jclpca.jclpca_26_18
- Grollemund B, Galliani E, Soupre V, Vazquez MP, Guedeny A, Danion A. L'impact des fentes labiopalatines sur les relations parents-enfant. *Arch Pédiatrie*. 2010;17(9):1380-1385. doi:10.1016/j.arcped.2010.06.026
- Richard B, Russell J, McMahon S, Pigott R. Results of randomized controlled trial of soft palate first versus hard palate first repair in unilateral complete cleft lip and palate. *Cleft Palate Craniofac J*. 2006;43(3):329-338. doi:10.1597/05-065.1
- Borah GL, Rankin MK. Appearance is a function of the face. *Plast Reconstr Surg*. 2010;125(3):873-878. doi:10.1097/PRS.0b013e3181cb613d
- Kristiantini NKP, Hamid ARRH, Sanjaya IGPH, Adnyana IMS. Epidemiologi penderita celah bibir dan langit-langit di rumah sakit umum pusat sanglah Denpasar tahun 2016-2019. *J Med udayana*. 2021;10(12):96-99.
- Sert G, Calis M, Suslu AE, Ozgur F. Effect of cleft palate repair with vomer flap on incidence and severity of obstructive sleep apnea. *Eur J Plast Surg*. 2021;44(6):779-784. doi:10.1007/s00238-021-01818-0
- Willadsen E. Influence of timing of hard palate repair in a two-stage procedure on early speech development in Danish children with cleft palate. *Cleft Palate-Craniofacial J*. 2012;49(5):574-595. doi:10.1597/09-120
- Lohmander A, Friede H, Lilja J. Long-term, longitudinal follow-up of individuals with unilateral cleft lip and palate after the Gothenburg primary early veloplasty and delayed hard palate closure protocol: Speech outcome. *Cleft Palate-Craniofacial J*. 2012;49(6):657-671. doi:10.1597/11-085
- Sadhu P. Oronasal fistula in cleft palate surgery. *Indian J Plast Surg Off Publ Assoc Plast Surg India*. 2009;42(Suppl):S123-S128. doi:10.4103/0970-0358.57203
- Kobus K. Extended vomer flap in the early repair of a cleft palate. *Scand J Plast Reconstr Surg Hand Surg*. 1987;21(1):95-102. doi:10.3109/02844318709083586
- Cuzalina A, Jung C. Rhinoplasty for the cleft lip and palate patient. *Oral Maxillofac Surg Clin North Am*. 2016;28(2):189-202. doi:10.1016/j.coms.2015.12.002
- Liao YF, Lee YH, Wang R, et al. Vomer flap for hard palate repair is related to favorable maxillary growth in unilateral cleft lip and palate. *Clin Oral Investig*. 2014;18(4):1269-1276. doi:10.1007/s00784-013-1084-2
- Lee YH, Liao YF. Hard palate-repair technique and facial growth in patients with cleft lip and palate: A systematic review. *Br J Oral Maxillofac Surg*. 2013;51(8):851-857. doi:10.1016/J.BJOMS.2013.08.012
- Deshpande G, Wendby L, Jagtap R, Schönmeier B. The efficacy of vomer flap for closure of hard palate during primary lip repair. *J Plast Reconstr Aesthetic Surg*. 2015;68(7):940-945. doi:10.1016/j.bjps.2015.03.034
- Yang IY, Liao YF. The effect of 1-stage versus 2-stage palate repair on facial growth in patients with cleft lip and palate: A review. *Int J Oral Maxillofac Surg*. 2010;39(10):945-950. doi:10.1016/j.ijom.2010.04.053
- Martin-Smith JD, Fitzgerald L, Orr DJA. How reliable is the vomer flap in early hard palate repair? *J Plast Reconstr Aesthetic Surg*. 2017;70(6):828-832. doi:10.1016/J.BJPS.2017.02.026
- Becker M, Hansson E. Low rate of fistula formation after Sommerlad palatoplasty with or without lateral incisions: An analysis of risk factors for formation of fistulas after palatoplasty. *J Plast Reconstr Aesthetic Surg*. 2013;66(5):697-703. doi:10.1016/j.bjps.2013.01.031
- Russell K, Long RE, Hathaway R, et al. The americleft study: An inter-center study of treatment outcomes for patients with unilateral cleft lip and palate part 5. General discussion and conclusions. *Cleft Palate-Craniofacial J*. 2011;48(3):265-270. doi:10.1597/09-187.1
- Phua YS, de Chalain T. Incidence of oronasal fistulae and velopharyngeal insufficiency after cleft palate repair: An audit of 211 children born between 1990 and 2004. *Cleft Palate-Craniofacial J*. 2008;45(2):172-178. doi:10.1597/06-205.1
- Page MJ, McKenzie JE, Bossuyt PM, et al. The PRISMA 2020 statement: An updated guideline for reporting systematic reviews. *Br Med J*. 2021 Mar;372:n71. doi:10.1136/bmj.n71
- Wells G, Shea B, Peterson J, et al. The Newcastle-Ottawa Scale (NOS) for assessing the quality of nonrandomised studies in meta-analyses. http://www.ohri.ca/programs/clinical_epidemiology/oxford.asp, Published online 2013.
- Zhang Y, Zhou L, Liu X, et al. The modified Jadad scale. <https://doi.org/10.1371/journal.pone0120884.t001>. Published online 2015.
- de Jong JP, Breugem CC. Early hard palate closure using a vomer flap in unilateral cleft lip and palate: Effects on cleft width. *Clin Oral Investig*. 2014;18(4):1285-1290. doi:10.1007/s00784-013-1091-3
- Maggiulli F, Hay N, Mars M, Worrell E, Green J, Sommerlad B. Early effect of vomerine flap closure of the hard palate at the time of lip repair on the alveolar gap and other maxillary dimensions. *Cleft Palate-Craniofacial J*. 2014;51(1):43-48. doi:10.1597/11-297
- Ahti V, Alaluusua S, Rautio J, Leikola J, Hukki J, Saarikko A. Speech of patients with unilateral complete cleft lip and palate. *J Craniofac Surg*. 2020;31(3):e291-e296. doi:10.1097/SCS.00000000000006242
- Elfatah MKAA, El-Anwar MW, Quriba AS. Early functional outcome of two surgical protocols used in the repair of complete unilateral cleft lip palate. *Ann Pediatr Surg*. 2014;10(4):99-106. doi:10.1097/01.XPS.0000452062.30697.91
- Xu X, Cao C, Zheng Q, Shi B. The influence of four different treatment protocols on maxillofacial growth in patients with unilateral complete cleft lip, palate, and alveolus. *Plast Reconstr Surg*. 2019;144(1):180-186. doi:10.1097/PRS.00000000000005711
- Alam MK, Iida J, Sato Y, Kajii TS. Postnatal treatment factors affecting craniofacial morphology of unilateral cleft lip and palate (UCLP) patients in a Japanese population. *Br J Oral Maxillofac Surg*. 2013;51(8):e205-e210. doi:10.1016/j.bjoms.2012.10.001
- Ganesh P, Murthy J, Ulaghanathan N, Savitha VH. A randomized controlled trial comparing two techniques for unilateral cleft lip and palate: Growth and speech outcomes during mixed dentition. *J Cranio-Maxillofacial Surg*. 2015;43(6):790-795. doi:10.1016/j.jcms.2015.03.033
- Wong LS, Lu TC, Hang DTD, Chen PKT. The impact of facial growth in unilateral cleft lip and palate treated with 2 different

- protocols. *Ann Plast Surg.* 2020;84(5):541-544. doi:10.1097/SAP.0000000000002232
31. Agrawal K, Panda KN. Use of vomer flap in palatoplasty: Revisited. *Cleft Palate Craniofac J.* 2006;43(1):30-37. doi:10.1597/04-034.1
32. Ferdous KMN, Salek AJM, Islam MK, Das BK, Khan AR, Karim MS. Repair of cleft lip and simultaneous repair of cleft hard palate with vomer flap in unilateral complete cleft lip and palate: A comparative study. *Pediatr Surg Int.* 2010;26(10):995-1000. doi:10.1007/s00383-010-2643-0

Appendix

Searching Strategy

PUBMED

- #1 "Cleft lips" OR "Lips cleft" OR "Lip cleft" OR "cleft palate" OR "palate cleft" OR "palates cleft" OR "Cleft lip*" OR "cleft palate*" OR "cleft lip palate*"
- #2 "vomer flap" OR "early vomer flap" OR "cleft lip repair" OR "early cleft lip repair" OR "primary cleft lip repair" OR "labioplasty" OR "cheilorrhaphy" OR "early hard palate repair" OR "early palatoplasty" OR "early palatorrhaphy"
- #3 #1 AND #2

SCOPUS

- #1 "unilateral cleft lip" OR "bilateral cleft lip" OR "cleft lip" OR "complete cleft lip" OR "incomplete cleft lip" OR "unilateral cleft palate" OR "bilateral cleft palate" OR "complete cleft palate" OR "incomplete cleft palate" OR "cleft palate" OR "unilateral cleft lip and palate" OR "bilateral cleft lip and palate" OR "complete cleft lip and palate" OR "incomplete cleft lip and palate" OR "cleft lip and palate" OR "unilateral labioschizis" OR "bilateral labioschizis" OR "complete labioschizis" OR "incomplete labioschizis" OR "labioschizis" OR "unilateral palatoschizis" OR "bilateral palatoschizis" OR "complete palatoschizis" OR "incomplete palatoschizis" OR "palatoschizis" OR "unilateral labiopalatoschizis" OR "bilateral labiopalatoschizis" OR "complete labiopalatoschizis" OR "incomplete labiopalatoschizis" OR "labiopalatoschizis"
- #2 "vomer flap" OR "vomerplasty" OR "early vomer flap" OR "cleft lip repair" OR "early cleft lip repair" OR "labioplasty" OR "cheilorrhaphy" OR "early hard palate repair" OR "early palatoplasty" OR "early palatorrhaphy"
- #3 #1 AND #2

CLINICALTRIAL.GOV

- #1 (vomer flap) OR (early vomer flap) OR (cleft lip repair) OR (early cleft lip repair) OR (primary cleft lip repair) OR (labioplasty) OR (cheilorrhaphy) OR (early hard palate repair) OR (early palatoplasty) OR (early palatorrhaphy)

PROQUEST

- #1 ((Cleft lip) OR (Lips cleft) OR (Lip cleft) OR (cleft palate) OR (palate cleft) OR (palates cleft) OR (Cleft lip*) OR (cleft palate*) OR (cleft lip palate*)) AND ((vomer flap) OR (early vomer flap))

EBSCO

- #1 ((Cleft lip) OR (Lips cleft) OR (Lip cleft) OR (cleft palate) OR (palate cleft) OR (palates cleft) OR (Cleft lip*) OR (cleft palate*) OR (cleft lip palate*)) AND ((vomer flap) OR (early vomer flap))

COCHRANE

- #1 (cleft lip) OR (cleft palate) OR (cleft lip palate) AND (vomer flap) OR (vomerplasty) OR (early hard palate repair)

WEB OF SCIENCE

- #1 ALL = (((Cleft lip) OR (Cleft palate) OR (Cleft lip palate)) AND ((Vomer Flap) OR (Early hard palate repair) OR (Vomerplasty)))

SCIENCE DIRECT

- #1 ((cleft lip) OR (cleft palate) OR (cleft lip palate)) AND ((Vomer flap) OR (vomerplasty))
-

