

The effect of combined *Moringa oleifera* and demineralized freeze-dried bovine bone xenograft on the amount of osteoblast and osteoclast in the healing of tooth extraction socket of *Cavia cobaya*

by Rostiny Rostiny

Submission date: 17-Jun-2019 10:19AM (UTC+0800)

Submission ID: 1144348649

File name: 1580-8013-2-PB.pdf (570.98K)

Word count: 4413

Character count: 24170

The effect of combined *Moringa oleifera* and demineralized freeze-dried bovine bone xenograft on the amount of osteoblast and osteoclast in the healing of tooth extraction socket of *Cavia cobaya*

Rostiny, Eha Djulaeha, Nike Hendrijantini, and Agus Pudijanto

Department of Prosthodontic
Faculty of Dental Medicine, Universitas Airlangga
Surabaya - Indonesia

ABSTRACT

Background: Alveolar bone has an important role in providing support to teeth and dentures. Loss of support caused by alveolar resorption will cause functional and aesthetic problems. Preservation socket using bone graft is one way to maintain the dimensions of the alveolar bone. *Moringa oleifera* leaf can increase the activity of bone graft in the formation of new bone. **Purpose:** This study was aimed to evaluate the effect of combined *Moringa oleifera* leaf extract and demineralized freeze-dried bovine bone xenograft (DFDBBX) towards the formation of osteoblasts and osteoclasts in the tooth extraction sockets of *cavia cobaya*. **Method:** This study used 28 *cavia cobayas* divided into four groups. The combination of *Moringa oleifera* leaf extract and DFDBBX was inducted into the sockets of lower incisor tooth with certain dose in each group, ointment 1 containing PEG (a mixture of PEG 400 and PEG 4000) for control group, ointment 2 containing *Moringa oleifera* leaf extract and DFDBBX and PEG (at active substance concentration of 0.5%) for group 1, ointment 3 containing *Moringa oleifera* leaf extract and DFDBBX and PEG (at active substance concentration of 1%) for group 2, and Ointment 4 containing *Moringa oleifera* leaf extract and DFDBBX and PEG (at active substance concentration of 2%) for group 3. paraffin block preparations were made for histopathology examination using hematoxylin eosin staining. **Result:** The results showed that there were significant differences of the number of osteoblasts and osteoclasts in each treatment group ($p < 0.05$). **Conclusion:** It can be concluded that the combination of *Moringa oleifera* leaf extract and DFDBBX at 2% cocentration can increase the number of osteoblasts and decrease osteoclasts in the healing of tooth extraction sockets of *cavia cobaya*.

Keywords: demineralized freeze-dried bovine bone xenograft; *Moringa oleifera* leaf; osteoblast; osteoclast

Correspondence: Rostiny, Department of Prosthodontics, Faculty of Dental Medicine, Universitas Airlangga, Jl. Mayjend. Prof. Dr. Moestopo 47 Surabaya 60132, Indonesia. E-mail: rostiny54@gmail.com

INTRODUCTION

Alveolar bone has an important role in providing support to teeth and dentures.¹ Making dentures require sufficient structure and volume of alveolar bone as a buffer for removable dentures, fixed dentures and implant placement. Loss of the structure and volume of alveolar bone will affect stability, retention and comfort in the use of dentures in patients. This condition is usually caused by resorption

process of alveolar bone due to mechanical factors, pathological processes, trauma on face and resorption process triggered by tooth extraction.² Therefore, it is essential to maintain alveolar ridge after tooth extraction. One of techniques aimed to maintain alveolar ridge after tooth extractions by using graft materials either with or without membrane.^{3,4}

Graft materials are natural or synthetic substances used to correct defect or deficiency in tissue by providing extra cellular matrix in the form of scaffold during bone regeneration process.^{5,6} However, the use of graft materials in post-extraction sockets is still questionable because it can interfere with healing process in the socket when the socket will be used for the placement of implant.^{3,4} The formation of new bone derived from graft materials moreover also depends on time, therefore a substance that can simulate the activity of the graft materials is needed to accelerate new bone formation process.^{7,8}

Moringa oleifera, is a plant that has many benefits because it contains many nutrients, including vitamin C, α and β tocoferol, α and β -carotene, and 12 kinds of flavonoids including kaempferol and quercetin with high concentration.⁹ Flavanoid compound serves as an anti-inflammatory, anti oxidants and osteoprotection.¹⁰⁻¹² Several other researchers even claim that Moringa oleifera plant can inhibit cyclooxygenase enzyme, prostaglandin synthesis and nitrous oxide production in macrophages cells induced by lipopolysaccharide (LPS).^{12,13}

Tooth extraction can cause trauma triggering inflammation. Inflammatory reaction is a sign of first activated defense cells.¹⁴ This process occurs as a result of prostaglandin synthesis. This prostaglandin synthesis then will increase prostaglandin E2 (PGE2). PGE2 will directly lead to the increasing of osteoclast activity. In addition, macrophages infiltration as protection against infection will also be increased in the area of trauma and will induce nuclear factor kappa β (NF- κ B). Consequently, NF- κ B will trigger the secretion of pro-inflammatory mediators, namely interleukin-1 (IL-1), interleukin 6 (IL-6) and tumor necrosis factor α (TNF α) to strength immune response and also accelerate metabolic process. Those pro-inflammatory mediators then can regulate the receptor activators of nuclear kappa β ligand (RANKL) to bind to the receptor activators of nuclear kappa (RANK) causing the increasing of the differentiation of pre-osteoclasts into osteoclasts, later accelerating bone resorption process.¹⁵ In the healing process of the sockets after tooth extraction, osteoblast cells have been formed, derived from pluri-potential cells of periodontal ligament. This process indicates osteogenic function occurred in the third week. In this week, cortical bone in the sockets will also remodel, and the crest of the alveolar bone will be rounded by the activity of osteoclastic resorption.^{16,17} Based on the description above, therefore, this research is aimed to evaluate the effect of combine bonegraft and moringa leaf extract on the formation of osteoblasts and osteoclasts in the tooth extraction.

MATERIALS AND METHOD

This was an experimental laboratory research using experimental animals with true experimental design (Post only control group design). Subjects in this research were healthy male *Cavia cobaya*s weighed 300-350 grams, aged

3-3.5 months obtained from Biochemistry Laboratory unit of experimental animal, Faculty of Medicine, Universitas Airlangga. PEG is a compound serves as carrier for extract of Moringa oleifera leaf and DFDBBX, making them readily absorbed by human's body.

Twenty-eight *Cavia cobaya* were divided into four groups, each consisting of seven samples. Mixture of Moringa oleifera leaf extract, DFDBBX and PEG were made. Ointment 1 containing 25 grams of PEG (a mixture of PEG 400 and PEG 4000), ointment 2 containing 0.5 grams of Moringa oleifera leaf extract, 0.5 grams of DFDBBX and 99 grams of PEG (at active substance concentration of 0.5%), ointment 3 containing 0.5 grams of Moringa oleifera leaf extract 0.5 grams of DFDBBX and 49 grams of PEG (at active substance concentration of 1%), and ointment 4 containing with 0.5 grams of Moringa oleifera leaf extract, 0.5 grams DFDBBX and 24 grams of PEG (at active substance concentration of 2%).¹⁸ Those ointments were applied on the tooth extraction sockets of lower left incisors of *Cavia cobaya*s previously got anesthesia injection with ketamine. Ointment 1 was applied on the sockets in the control group, ointment 2, 3 and 4 were applied to the sockets in group 1, 2 and 3. On day 28th, all of those animals were killed and mandibular were taken and decalcified with EDTA solution for 30 days. Then, paraffin blocks were made and cut with rotary microtomes at 4 microns of thickness. Deparaffination was conducted by dissolving them in xylol for 2 x 3 minutes. Residual xylol was washed with absolute alcohol 99%, 95%, 90%, 80%, and 70%, respectively for 2 x 1 minutes. The residual alcohol was washed with running water. HE staining was conducted for 30 seconds and then rinsed with water. Eosin staining was conducted for 1-2 minutes, and then washed with absolute alcohol 70%, 80%, 90%, 95%, and 99% for 2 x 3 minutes and with xylol for 2 x 2 minutes. Each preparation was closed with a cover glass previously dropped with Canadian balsam. Histology examination of osteoblasts and osteoclasts were done by using a light microscope at 400x magnification.^{18,19} The data collected from the observation was analysed statistically. Kolmogorov Smirnov test, Levene test and one way Anova were done, followed with multifactorial comparison test using Tukey-HSD.

RESULTS

It can be seen that the highest mean number of osteoblast cells was in the group treated with the active substance concentration of 2%, while the lowest in the control group. Furthermore, the highest mean number of osteoclasts was in the control group, while the lowest was in group 3 treated with the active substance concentration of 2% (Figure 1). The increased number of osteoblasts and the decreased of osteoclasts in the control group and the treatment groups can be seen in Figure 2 and 3.

In addition, the results of normality test showed that the

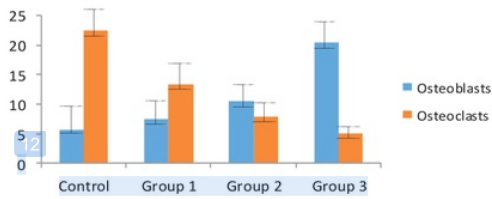


Figure 1. Graph of the mean and standard deviation of the number of osteoblasts and osteoclasts.

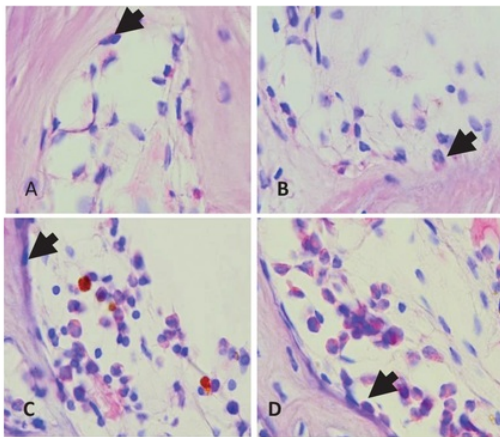


Figure 2. Description of osteoblast cells as a result of HE examination with a light microscope at 400x magnification. A) control group; B) group 1; C) group 2; and D) group 3. The number of osteoblasts was different among the groups, getting increased from control group to group 3. (Arrow heads indicate osteoblast).

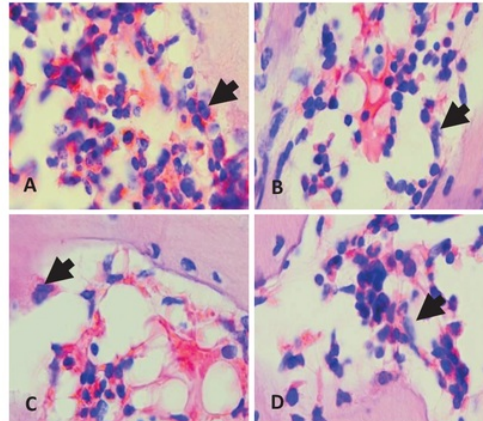


Figure 3. Description of osteoclast cells as a result of HE examination with a light microscope at 400x magnification. A) control group; B) group 1; C) group 2; and D) group 3. The number of osteoclasts was different among the groups, getting decreased from control group to group 3. (Arrow heads indicate osteoclast).

distribution of data in all groups of osteoblasts was normal ($p = 0.160$). Based on the results of homogeneity test, it is also known that the variance of data obtained from those groups was homogeneous ($p = 0.975$). It was shown that all data in the groups of osteoclasts was normally distributed ($p = 0.395$) with homogeneous variance ($p = 0.083$). The results of Anova test showed that there were significant differences among the treatment groups ($p < 0.05$). The results of multiple comparison using Tukey HSD test (Table 1).

Shown that there was no significant difference of the

Table 1. Results of Tukey HSD test on the number of osteoblasts and osteoclasts in each treatment group

		Control	Group 1	Group 2	Group 3
Osteoblasts	Control	-	-	*	*
	Group 1	-	-	*	*
	Group 2	*	*	-	*
	Group 3	*	*	*	-
Osteoclasts	Control	-	*	*	*
	Group 1	*	-	*	*
	Group 2	*	*	-	-
	Group 3	*	*	-	-

* = No significant difference ($p < 0.05$)

Note: Control: Control group; group 1: at active substance concentration of 0.5%; group 2: at active substance concentration of 1%; Group 3: at active substance concentration of 2%.

number of osteoblasts between control group and group 1. While there were significant differences in the number of osteoblasts between control group and both group 2 and group 3. There were also significant differences of the number of osteoblasts between group 1 and both group 2 and group 3. Similarly, there were significant differences in the number of osteoblasts between group 2 and control group, and also between group 1 and group 3. There were significant differences of the number of osteoblasts between group 3 and the other treatment groups.

The result of Tukey HSD showed that there was a significant difference in the number of osteoclasts between the control group and all of those treatment groups. There were significant differences of the number of osteoclasts between group 1 and the control group, and also between group 2 and group 3. It is also known, furthermore, that there were significant differences between group 2 and both the control group and group 1. Nevertheless, there was no significant difference between group 2 and group 3. It also shows that there were significant differences between group 3 and both the control group and group 1. There was no significant difference between group 3 and group 2.

DISCUSSION

Based on data analysis, the mean number of osteoblast cells was getting increased from the control group to group 3. It is also known that based on the results of one way Anova test, there was a significant difference of the number of osteoblast cells among the treatment groups. It indicates that the combination of *Moringa oleifera* leaf extract and both PEG and DFDBBX can influence the formation of osteoblasts in the tooth extraction sockets. Similarly, a previous research also claims that *Moringa oleifera* leaf extract has osteogenic effects.^{20,21} A compound playing a role in this condition is flavonoid, especially kaempferol and quercetin. Osteogenic effects derived from flavonoid can be detected from the increasing of alkaline phosphatase (ALP) enzyme in cultured osteoblast cells. In addition to the increasing of ALP, ethanol derived from *Moringa oleifera* leaf extract can also improve other remodelling bone markers, namely calcium serum and phosphorus serum.²² ALP playing a role in mineralization process is aimed to create alkaline atmosphere in osteoid tissue formed, as a result, calcium can be easily deposited in the tissue.²³ Meanwhile, specific ALP plays a role to make bone synthesized into osteoblasts and reflects osteoblast cell activities during bone formation.²⁴ In addition to osteogenic effects, kaempferol also has estrogenic effects. Kaempferol can bind to estrogen receptors in osteoblasts. Kaempferol through the estrogen receptors then can increase biomarkers of osteoblast differentiation, such as ALP and osteoblastic genes transcription, namely collagen type I, osteocalcin and osteonectin.²⁰

Another cause of the condition is by the participation of a graft material combined with *Moringa oleifera* leaf

extract. A graft material used in this study is DFDBBX, a kind of xenograft produced by Batan. Xenograft is useful to stimulate the proliferation of osteoblasts, fibroblasts and endothelial cells.²⁵ Xenograft also has an ability to regenerate tissue osteoconductively because it has inner surface properties, porosity, calcium ratio, and mineral factors, such as hydroxyapatite owned by bovine similar to human bone minerals.²⁶ DFDBBX plays a role as osteoconductor in osteoinduction.²⁷ But, inorganic materials derived from this graft can make the attachment and proliferation of osteoblast cells as the first step for the formation of osteoblasts to form bone.¹⁵

Unlike the number of osteoblast cells, the highest number of osteoclasts in this research was in the control group treated with only the administration of PEG on the tooth extraction sockets. Meanwhile, the lowest number of osteoclasts was in Group 3 treated with the administration of the active substance concentration of 2%. The decreasing of the number of osteoclasts is caused by kaempferol and quercetin contained in *Moringa oleifera* leaf extracts playing an important role as anti-inflammation. In inflammatory reaction triggered by tooth extraction, pro inflammatory mediators are released from macrophages in the form of cytokines, including IL-1, IL-6, TNF α and prostaglandin E2 (PGE2). These components then will stimulate the formation of osteoclasts either directly or indirectly. PGE2 can directly induce vascular changes in inflammation process, and also induce bone resorption in the absence of inflammatory cells with a few of multinucleated osteoclasts when attached directly to the surface of bone.²⁸ Cytokine then is produced by macrophages as a process of bone destruction, namely IL-1 that can improve the regulation of RANKL in osteoblasts. RANKL binds to RANK as the initial process of bone destruction. The increasing of osteoclast differentiation process is influenced by the increasing of RANK fusion on the precursor of the surface of osteoclasts, resulting in bone resorption.²⁹

Moringa oleifera leaf, contains the large amount of flavonoids, namely kaempferol and quercetin.³⁰ Flavonoids can be used in all inflammatory conditions because they can inhibit cyclooxygenase2 enzyme playing a role in the formation of inflammatory mediators derived from arachidonic acid. It can also inhibit the release of histamine by mast cells in basophils that have anti-inflammatory effects.^{31,32} The effects of this enzyme then will reduce a number of pro-inflammatory mediators, such as IL-1, IL-6 and TNF α . Kaempferol and quercetin activities can also directly inhibit TNF α activity and RANKL expression.³³ Both of these flavonoids have a tendency to bind atoms or act as scavenging for free radical atoms, so reactive oxygen species (ROS) can not be formed redundantly. ROS can stimulate phosphorylation process of inhibitor kappa β (IK β), which serves to bind NF κ β , so it can be inactive in cytoplasm. If IK β is phosphorylated, the bond of the bond IK β and NF κ β will be separated, so NF κ β becomes active and moves to cell nucleus. This process is called activation process of NF κ β . Therefore, with the barriers of

flavonoids in forming ROS, the activation of NF κ B will also be inhibited.³⁴ NF κ B is known as gene transcription that will induce the formation of pro-inflammatory cytokines, such as TNF α . As mentioned before, TNF α and RANKL are precursors of osteoclast cell maturation playing a role in bone resorption. In addition, quercetin is also able to inhibit differentiation and activation as well as to induce apoptosis of osteoclast cells.^{35,36} Thus, in this research, it is known that *Moringa oleifera* leaf extract can reduce the number of osteoclasts, but on the other hand it can increase the number of osteoblasts. This is caused by the suppression phase of differentiation terminal of osteoclasts, so the formation of pre-osteoblast cells become more accelerated.

The combination extract of *Moringa* and DFDBBX accelerates bone formation due to its good compatibility and osteoconductivity. Acceleration of bone regeneration mechanically might be caused by combination substance which acts as scaffold, stabilizing blood clot and preventing epithelia from growing inward the socket, while biologically the substances provide extra minerals.³⁷ Combination of substances could be caused resorption and gradation in formation of new bone so that enabling osteocompetent penetration and endothelial cells and vascularization in order to accelerate new bone formation.³⁸ It can be concluded that the combination of *Moringa oleifera* leaf extract and DFDBBX at 2% concentration can increase the number of osteoblasts and decrease osteoclasts in the healing of tooth extraction sockets of cavia cobaya

REFERENCES

- Allegrini S Jr, Koenig B Jr, Allegrini MR, Yoshimoto M, Gedrange T, Fanghaenel J, Lipski M. Alveolar ridge sockets preservation with bone grafting—Review. *Ann Acad Med Sterin* 2008; 54(1): 70–81.
- Irinakis T. Rationale for socket preservation after extraction of a single-rooted tooth when planning for future implant placement. *J Can Dent Assoc* 2007; 72(10): 917–22.
- Nevins M, Camelo M, De Paoli S, Friedland B, Schenk RK, Parma-Benfenati S, Simion M, Tinti C, Wagenberg B. A study of the buccal wall of extraction socket of teeth with prominent roots. *Int J Periodontics Restorative Dent* 2006; 26(1): 19–20.
- Oghli AA, Steveling. Ridge preservation following tooth extraction: A comparison between a traumatic extraction and socket seal surgery. *Quint Int* 2010; 4(7): 605–9.
- Gark K, Lynch SE, Robert G, Robert EM. Tissue engineering applications in maxillofacial surgery and periodontics. Illinois: Quintessence Public Inc; 1999. p. 83–9.
- Weiss CM, Weis A. Principle and practice of implant dentistry. 1st ed. United State of America: Mosby Inc; 2001. p. 659.
- Baharuddin NA, Kamin S, Samsuddin AR. The use of demineralized freeze-dried bovine bone xenograft in reducing post surgical periodontal pocket depth. *Annals of Dentistry, University of Malaya* 2003; 10: 33–6.
- Nevins M, Camelo M, De Angelis N, Hanratty JJ, Khang WG, Kwon JJ, Rasperini G, Rocchietta I, Schupbach P, Kim DM. The clinical and histological efficacy of xenograft granules for maxillary sinus floor augmentation. *Int J Periodontics Restorative Dent* 2011; 31(3): 227–35.
- Copin JA. Study of the nutritional and medicinal values of *Moringa oleifera* leaves from sub-saharan Africa: Ghana, Rwanda Senegal and Zambia. Thesis. The State University of New Jersey: Graduate School-New Brunswick Rutgers; 2008. p. 5–99.
- Kasolo JN, Bimenya GS, Ojok L, Ochieng J, Ognel JW. Phytochemical and uses of *Moringa oleifera* leaves in Ugandan rural communities. *Journal of Medicinal Plants Research* 2010; 4(9): 753–7.
- Patel C, Rangrez A, Parikh P. The anti-osteoporotic effect of *Moringa oleifera* on osteoblastic cells: SaOS2. *Journal of Pharmacy and Biological Sciences* 2013; 5(2): 10–7.
- Coppin JW, Xu Y, Chen H, Pan MH, Ho CT, Juliani R, Simon JE, Wu. Determination of flavonoid by LC/MS anti inflammatory activity in *Moringa oleifera*. *Journal of Functional Foods* 2013; 5: 1892–9.
- Araújo LC, Aguiar JS, Napoleão TH, Mota FV, Barros AL, Moura MC, Coriolano MC, Coelho LC, Silva TG, Paiva PM. Evaluation of cytotoxic and anti-inflammatory activities of extracts and lectins of *Moringa oleifera* seeds. *PLoS One* 2013; 8(12): e81973.
- Weijen FV, Actqua D, Slot DE. Alveolar bone dimensional changes of post-extraction sockets in humans: a systematic review. *J Clin Periodontol* 2009; 36(12): 1048–58.
- Yustina AR, Suardita K, Agustin D. Peningkatan jumlah osteoklas pada keradangan periapikal akibat induksi lipopolisakarida porphyromonas gingivalis (Suatu penelitian laboratories menggunakan tikus). *Jurnal Biosains* 2012; 14(3): 140–4.
- Ghom A, Mhaske S. Textbook of oral pathology. 1st ed. New Delhi, India: Jaypee Brothers Medical Publisher Ltd; 2009. p. 86–7.
- Rajendran S. Textbook of oral pathology. 6th ed. India: Elsevier; 2010. p. 599–60.
- Kresnoadi U, Rahayu RP. The influence of Aloe vera BNP 2 expression and amount of osteoblast of alveolar bone induced into tooth extraction socket (Cavia Cobaya). *Journal of Biological Researches* 2014; 19(2): 2–10.
- Vindani D. Efektivitas kombinasi ekstrak Jinten Hitam (*Nigella Sativa*) dan Graft terhadap peningkatan osteoblas tulang alveol pada Cavia Cobaya. Thesis. Surabaya: Pendidikan Dokter Gigi Spesialis Universitas Airlangga; 2013. p. 24–35.
- Jiang Yang Guo, Chiyun Choi, Yuzhong Zheng, Ping Chen, Tingxia Dong, Zheng-Tao Wang, Günter Vollmer, Taiwan Lau, Wali-keung Tsim. Kaempferol as a flavonoid induces osteoblastic differentiation via estrogen receptor signaling. *Chinese Medicine* 2012; 7(10): 1–7.
- Yamaguchi M. The osteogenic effect of bioactive flavonoid p-hydroxycinnamic acid: development in osteoporosis treatment. *OA Biotechnology* 2013; 01: 2(2): 15.
- Jiaying G. Mechanistic studies on the osteogenic effects of dietary flavonoids in cultured osteoblasts: potential drug development against osteoporosis. Thesis. Hong Kong: Hong Kong University of Science and Technology; 2011. p. 146–50.
- Thomas SDC. Bone turnover markers. *Aust Prescr* 2012; 35: 156–8.
- Yudaniyanti IS. Aktifitas alkaline phosphatase pada proses kesembuhan patah tulang femur dengan terapi CaCO₃ dosis tinggi pada tikus jantan. *Media Kedokteran Hewan* 2008; 21(1): 15–8.
- Gupta R, Pandit N, Malik R, Sood S. Clinical and radiological evaluation of an osseous xenograft for the treatment of infrabony defects. *J Can Dent Assoc* 2007; 73(6): 513.
- Baharuddin NA, Kamin S, Samsuddin AR. The original article use of demineralized freeze-dried bovine bone xenograft in reducing post-surgical periodontal recession. *Annals of Dentistry, University of Malaya* 2005; 12: 37–40.
- Pumomo A, Adji D. Ekspresi bone morphogenetic protein-2 untuk mengukur efektivitas biomaterial freeze dried bovine bone xenograft (FDBBX) sebagai bahan penyambung tulang. *Jurnal Sain Veteriner* 2012; 30(1): 1–6.
- Khan SN, Cammisa FP Jr, Sandhu HS, Diwan AD, Girardi FP, Lane JM. The biology of bone grafting. *J Am Acad Orthop Surg* 2005; 13(1): 77–86.
- Takanyangi. Ostoimmunology: Share mechanism and crosstalk between the immunes and bone system. 7th ed. Tokyo: Nature Publishing Group; 2007. p. 292–302.
- Sreelatha S, Jeyachitra A, Padma PR. Antiproliferation and induction of apoptosis by *Moringa oleifera* leaf extract on human cancer cells. *Food Chem Toxicol* 2011; 49(6): 1270–5.

31. Thorne research. 2000. Alternative medicine review. Vol.3(2). Available from: www.thorne.com/altmedrev/fulltex/3/2/140.pdf. Accessed on 10 may 2015.
32. Della L. Anti inflammatory activity of benzopyrones that are inhibitors of cyclo and lipo-oxygenase. *Pharmacological Research Communications* 2001; 20: 91-4.
33. Amijaya APP, Murwani S, Wardhana AW. 2012. Efek ekstrak air daun kelor (*Moringa Oleifera*) terhadap kadar tumor necrosis factor Alpha (TNF α) dan gambaran histopatologi sel endotel arteri coronaria pada tikus putih (*Rattus Norvegicus*) yang diberi diet Aterogenik. Program Studi Pendidikan Dokter Hewan. Program Kedokteran Hewan. Universitas Brawijaya. 1-12. Available from: <http://pkh.ub.ac.id/wp-content/uploads/2012/10/0911310033-AriPumamasariP.pdf>. Accessed on 9 may 2015.
34. Wihastuti TA, Sargowo D, Rohman MS. Efek ekstrak daun kelor (*Moringaoleifera*) dalam menghambat aktivasi Nfkb, ekspresi TNF α dan ICAM-1 pada HUVECS yang dipapar LDL teroksidasi. *Jurnal Kardiologi Indonesia* 2007; 28: 181-8.
35. Wattel A, Kamel S, Mentaverri R, Lorget F, Prouillet C, Petit JP, Fardelone P, Brazier M. Potent inhibitory effect of naturally occurring flavonoids quercetin and kaempferol on in vitro osteoclastic bone resorption. *Biochem Pharmacol* 2003; 65: 35-42.
36. Woo JT, Nakagawa H, Notoya M, Yonezawa T, Udagawa N, Lee IS, Ohnishi M, Hagiwara H, Nagai K. Quercetin suppresses bone resorption by inhibiting the differentiation and activation of osteoclast. *Biol Pharm Bull* 2004; 27(4): 504-9.
37. De Risi V, Clementini M, Vittorini G, Mannocci A, De Sanctis M. Alveolar ridge preservation techniques. A systematic review and meta-analysis of histological and histomorphometrical data. *Clin Oral Implants Res* 2015; 26(1): 50-68.
38. Logeart-Avramoglou D, Anagnostou F, Bizios R, Petite H. Engineering bone challenges and obstacles. *J Cell Mol Med* 2005; 9(1): 72-84.

The effect of combined *Moringa oleifera* and demineralized freeze-dried bovine bone xenograft on the amount of osteoblast and osteoclast in the healing of tooth extraction socket of *Cavia cobaya*

ORIGINALITY REPORT

22%

SIMILARITY INDEX

19%

INTERNET SOURCES

10%

PUBLICATIONS

7%

STUDENT PAPERS

PRIMARY SOURCES

1

journal.unair.ac.id

Internet Source

5%

2

mafiadoc.com

Internet Source

3%

3

A Brahmanta, D Mulawarmanti, F Z Ramadhani, W Widowati. "The Differences of Effectiveness HBO 2,4 ATA Between 7 and 10 Days In Bone Remodelling of Tension Area of Orthodontic Tooth Movement", IOP Conference Series: Earth and Environmental Science, 2019

Publication

2%

4

journalseeker.researchbib.com

Internet Source

1%

5

jcdr.net

Internet Source

1%

6

hangtuah.ac.id

Internet Source

1%

7	www.kokuhoken.or.jp Internet Source	1%
8	Alejandro Iglesias-Linares, Rosa-María Yáñez-Vico, Enrique Solano-Reina, Daniel Torres-Lagares et al. "Influence of bisphosphonates in orthodontic therapy: Systematic review", Journal of Dentistry, 2010 Publication	1%
9	Hüseyin Can Tükel, Ertan Delilbaşı. "Effects of metabolic syndrome on jawbones and bone metabolic markers in sucrose-fed rats", Odontology, 2019 Publication	1%
10	link.springer.com Internet Source	<1%
11	www.scribd.com Internet Source	<1%
12	www.aitvm.org Internet Source	<1%
13	www.dovepress.com Internet Source	<1%
14	www.jomb.org Internet Source	<1%
15	Vanhoutte, Vanessa, Eric Rompen, Geoffrey Lecloux, Stefan Rues, Marc Schmitter, and	<1%

France Lambert. "A methodological approach to assessing alveolar ridge preservation procedures in humans: soft tissue profile", *Clinical Oral Implants Research*, 2013.

Publication

16

repositorio.pucrs.br

Internet Source

<1%

17

Submitted to University of Birmingham

Student Paper

<1%

18

www.saddleback.edu

Internet Source

<1%

19

repository.hyogo-u.ac.jp

Internet Source

<1%

20

jtrolis.ub.ac.id

Internet Source

<1%

21

Nayak, G., A. Vadinkar, S. Nair, S. G. Kalthur, A. S. D'Souza, P. K. Shetty, S. Mutalik, M. M. Shetty, G. Kalthur, and S. K. Adiga. "Sperm abnormalities induced by pre-pubertal exposure to cyclophosphamide are effectively mitigated by *Moringa oleifera* leaf extract", *Andrologia*, 2015.

Publication

<1%

22

sta.uwi.edu

Internet Source

<1%

23

emjreviews.com

Internet Source

<1%

24	journals.sagepub.com Internet Source	<1%
25	www.blog.calesmart.com Internet Source	<1%
26	bmccomplementaltemed.biomedcentral.com Internet Source	<1%
27	www.jkimsu.com Internet Source	<1%
28	"Interface Oral Health Science 2007", Springer Nature, 2007 Publication	<1%
29	www.alkalifewater.com.my Internet Source	<1%
30	www.gulfmedicaljournal.com Internet Source	<1%
31	jimd.in Internet Source	<1%
32	Berkovich, Liron, Gideon Earon, Ilan Ron, Adam Rimmon, Akiva Vexler, and Shahar Lev-Ari. "Moringa Oleifera aqueous leaf extract down-regulates nuclear factor-kappaB and increases cytotoxic effect of chemotherapy in pancreatic cancer cells", BMC Complementary and Alternative Medicine, 2013. Publication	<1%

33

Submitted to Centre for Nutrition Education & Lifestyle Management (CNELM)

Student Paper

<1%

Exclude quotes On

Exclude matches < 5 words

Exclude bibliography On

The effect of combined Moringa oleifera and demineralized freeze-dried bovine bone xenograft on the amount of osteoblast and osteoclast in the healing of tooth extraction socket of Cavia cobaya

GRADEMARK REPORT

FINAL GRADE

/0

GENERAL COMMENTS

Instructor

PAGE 1

PAGE 2

PAGE 3

PAGE 4

PAGE 5

PAGE 6
