

pISSN: 1411-8327
eISSN: 2477-5665

Jurnal Veteriner

INDONESIAN VETERINARY JOURNAL

Vol. 19 No. 1, Maret 2018

- Karakteristik tipe diabetes akibat induksi deksametasone ●
- Gambaran patologi mencit tripanosomiasis pascaterapi ●
ekstrak daun kipahit
- Ekstrak kulit buah naga menurunkan induksi tumor mammae ●
- Salep daun sirih merah untuk terapi luka miasis ●
- Ekstrak terung asam & temu kunci atau terung asam & lempuyang, ●
menekan *A. hydrophila* dan *Pseudomonas*
- Ekstrak bakau api-api putih hambat mikrob patogen ●
pada larva udang windu
- Senyawa antibakteri pada katak papua ●
- Morfometri limpa codot krawar (*Cynopterus brachyotis*) ●
- Ekspresi hyaluronan pascavitrifikasi oosit matang dan belum matang ●
- Anak-anak babi turunan induk yang disuntik gonadotropin ●
- The comparison of various technique for diagnosis of demodectosis ●
- Prevalensi paramphistomosis pada sapi bali di Papua Barat ●
- Peningkatan kadar lemak tidak jenuh susu sapi setelah ransum ●
diimbui minyak jagung
- Bius tetes infus gravimetrik ketapol pada babi ●
- Karakteristik Gen Sitokrom Lebah Liar Apis cerena ●
Asal Pulau Hoga Sulawesi Tenggara
- Limfosit, Monosit, dan Basofil Sapi Bali yang Digembalakan ●
di Tempat Sampah Kota
- Penanganan obstruksi duodenum pada anjing ●
Urolith surgical removal in green iguana ●



AFP Foto/Muhammad Agus Salim

Ketika musim duren memuncak di bulan Februari-Maret, bukan hanya manusia yang suka duren, harimau sumatra pun menyukai duren. Memanfaatkan cakarinya, harimau dengan mudah membelah duren runtuh. Mungkin duren itu yang membuatnya masuk kampung di Mandailing Natal Sumut atau karena habitatnya telah dirusak. Sempat dijuluki harimau jadi-jadian, sang raja rimba pun diuber masuk hutan sampai masyarakat menemukan goa persembunyiannya. Tak berapa lama, harimau masuk kampung lagi tanpa menyadari masyarakat telah mempersenjatai dirinya dengan tombak. Masyarakat Desa Hatupangan, Kecamatan Batang Natal, Mandailing Natal, Sumatra Utara menombak sang raja rimba hingga tewas Minggu 4 maret 2018. Jasadnya digantung dan dipertontonkan. Petugas yang sempat mau membantu warga menghalau harimau dilarang masuk desa dan bahkan disandera dan diintimidasi. Diduga ada ilegal logging dibalik itu semua sehingga masyarakat begitu tega menghabisi satwa yang terancam punah dan dilindungi.

PEMIMPIN UMUM : I WAYAN BATAN **DEWAN REDAKSI :** NYOMAN MANTIK ASTAWA (KETUA), IDA BAGUS ARKA, NYOMAN SADRA DHARMAWAN, IWAN H. UTAMA, I GUSTI NGURAH KADE MAHARDIKA, I KETUT PUJA, I KETUT SUATHA, TJOK GDE OKA PEMAYUN, ROOSTITA L. BALIA, I KETUT BERATA, AIDALOUISE TENDEN ROMPIS, GUSTIAYU YUNIATI KENCANA **REDAKTUR PELAKSANA :** I NYOMAN SUARTHA & I G M KRISNA ERAWAN, **SEKRETARIS REDAKSI :** I NYOMAN SUARSANA. **STAF REDAKSI :** I WAYAN SUARDANA, I GUSTI NGURAH SUDISMA, NI GUSTI AGUNG AYU SUARTINI, I MADE SUKADA, ANAK AGUNG SAGUNG KENDRAN, ANAKAGUNG AYU MIRAH ADI, I MADE KARDENA, YANA QOMARIANA. **TATA USAHA :** WERDI SUSARI, PUTU AYU SISYAWATI PUTRI NINGSIH. **KANTOR REDAKSI & ALAMAT SURAT :** KLINIK HEWAN FKH UNUD, Jl. Raya Sesetan Gg. Markisa 6 Banjar Gaduh, Denpasar - Bali. **PENERBIT :** FAKULTAS KEDOKTERAN HEWAN, UNIVERSITAS UDAYANA BEKERJA SAMA DENGAN PERHIMPUNAN DOKTER HEWAN INDONESIA. **REKENING :** NOMOR 0118628705 A/N dth. I NYOMAN SUARTHA, M.Si BNI CABANG DENPASAR **DICETAK OLEH:** PERCETAKAN PELAWA SARI, JL. ANTOSURA 33 DENPASAR

Setiap naskah yang dikirim ke redaksi untuk dipublikasikan dalam Jurnal Veteriner dipandang sebagai karya asli penulis dan bila diterima, naskah tersebut tidak diperkenankan dipublikasikan lagi secara keseluruhan ataupun sebagian tanpa seijin Jurnal Veteriner.

DAFTAR ISI

Vol 19, No 1 Maret 2018
Terakreditasi Dirjen Penguatan
Riset dan Pengembangan,
Kemenristek Dikti RI
S.K. No. 36a/E/KPT/2016

Jurnal Veteriner

Jurnal Kedokteran Hewan Indonesia
Indonesian Veterinary Journal

pISSN: 1411-8327; eISSN: 2477-5665
Website : ojs.unud.ac.id
Terbit sejak 18 Desember 2000

Naskah Asli
Original Article

- RAHMANIA HANIM, HUDA SHALAHUDIN DARUSMAN, MIN RAHMINI WATI**
Studi Karakteristik Tipe Diabetes pada Tikus
(*Rattus novergicus*) yang Diinduksi Deksametason
(CHARACTERISTIC STUDY OF THE TYPE OF DIABETES IN RAT (*RATTUS NOVERGICUS*)
MODEL INDUCED BY DEXAMETHASONE) 1-10
- SUTIASTUTI WAHYUWARDANI, APRIL H WARDHANA,
DIDIK T SUBEKTI, DHARWIN SISWANTORO**
Gambaran Patologi Infeksi *Trypanosoma evansi* pada Mencit Pascapengobatan
dengan Ekstrak Ethanol Daun Kipahit (*Tithonia diversifolia*)
(PATHOLOGIC FEATURES OF *TRYPANOSOMA EVANSI* INFECTION AFTER BEING TREATED
WITH ETHANOLIC EXTRACT OF KIPAHIT LEAVES (*TITHONIA DIVERSIFOLIA*) 11-22
- MUHAMMAD THOHAWI ELZIYAD PURNAMA, RAGIL ANGGA PRASTIYA,
FAISAL FIKRI, AMUNG LOGAM SAPUTRO, BODHI AGUSTONO**
Ekstrak Etanol Kulit Buah Naga Menurunkan Indikasi Neoplasia Mammar
Tikus Putih Berdasarkan Histopatologi dan *Inhibitor Siklooksigenase-2*
(DRAGON FRUIT ETHANOL EXTRACT REDUCES INDICATIONS OF WHITE RAT
NEOPLASIA BASED ON HISTOPATHOLOGY AND CYCLOOXYGENASE-2 INHIBITORS) 23-29
- SUS DERTHI WIDHYARI, IETJE WIENTARSIH, AULIA ANDI MUSTIKA,
APRIL HARI WARDHANA, DODI DARMAKUSUMA, LINA NOVIYANTI SUTARDI,
MUHAMMAD BINTANG**
Potensi Salep Ekstrak Daun Sirih Merah Terhadap Profil Eritrogram
Sebagai Terapi pada Luka Miasis
(THE EFFECT OF RED BETEL LEAF EXTRACT OINTMENT IN ERYTHROGRAM
PROFILES AS THERAPY IN MYIASIS WOUND) 30-34
- ESTI HANDAYANI HARDI, GINA SAPTIANI, NURKADINA,
IRAWAN WIJAYA KUSUMA, WIWIN SUWINARTI**
Uji In Vitro Gabungan Ekstrak *Boesenbergia pandurata*, *Solanum ferox*,
Zingiber zerumbet terhadap Bakteri Patogen pada Ikan Nila
(IN VITRO TEST OF CONCOCTION PLANT EXTRACTS OF *BOESENBERGIA PANDURATA*,
SOLANUM FEROX, *ZINGIBER ZERUMBET* AGAINST PATHOGENIC
BACTERIA IN TILAPIA) 35-44
- GINA SAPTIANI, ANDI NOOR ASIKIN, FIKRI ARDHANI, ESTI HANDAYANI HARDI**
Tanaman Bakau Api-api Putih (*Avicennia marina*) Berpotensi Menghambat
Mikrob Patogen dan Melindungi Post Larva Udang Windu
(THE POTENTIAL OF *AVICENNIA MARINA* TO INHIBITS PATHOGEN MICROBES
AND PROTECTS THE POST LARVA OF TIGER PRAWN) 45-54
- MARIA MASSORA, ELDA IRMA J. J. KAWULUR*, HERMAWATY ABUBAKAR**
Uji Aktivitas Senyawa Antibakteri Katak Papua
(ANTIBACTERIAL ACTIVITY TEST OF PAPUAN FROGS) 55-61
- DESRAYNI HANADHITA, ANDHIKA YUDHA PRAWIRA, ANISA RAHMA,
ARYANI SISMIN SATYANINGTIJAS, SRIHADI AGUNGPRIYONO**
Morfometri Limpa Berkaitan dengan Produksi Radikal Bebas dan Antioksidan
pada Kelelawar Pemakan Buah Codot Krawar (*Cynopterus brachyotis*)
(MORPHOMETRIC STUDY OF SPLEEN ASSOCIATED WITH FREE RADICAL PRODUCTION
AND ANTIOXIDANT DEFENSE IN THE LESSER SHORT-NOSED FRUIT BATS
(*Cynopterus brachyotis*)) 62-70
- ZAKIYATUL FAIZAH, R. HARYANTO ASWIN, HAMDANI LUNARDHI, WIDJIATI**
Hyaluronan Expression on Vitrified Oocytes Before and After In Vitro Maturation
(EKSPRESI HYALURONAN PADA OOSIT YANG DIVITRIFIKASI
SEBELUM DAN SESUDAH MATURASI IN VITRO) 71-75

DAFTAR ISI (Lanjutan)

Vol 19, No 1 Maret 2018
Terakreditasi Dirjen Penguatan
Riset dan Pengembangan,
Kemenristek Dikti RI
S.K. No. 36a/E/KPT/2016

Jurnal Veteriner

Jurnal Kedokteran Hewan Indonesia
Indonesian Veterinary Journal

pISSN: 1411-8327; eISSN: 2477-5665
Website : ojs.unud.ac.id
Terbit sejak 18 Desember 2000

- FRISKA MONTOLALU, ANITA ESFANDIARI, DAMIANA RITA EKASTUTI, WASMEN MANALU
Kondisi Neonatus Anak Babi yang Dilahirkan oleh Induk yang Disuntik Gonadotropin
Sebelum Pengawinan
(THE NEONATE CONDITIONS OF PIGLETS BORN FROM SOW
INJECTED WITH GONADOTROPIN PRIOR TO MATING)..... 76-84
- I NYOMAN SUARTHA, WILLY MORIS NAINGGOLAN,
YEKHONYA REHUEL SIDJABAT, NI MADE RESTIATI
The Comparison of Scraping, Trichogram, and Taping Techniques for Diagnosis
of Demodicosis in Dog
(PERBANDINGAN TEKNIK SCRAPING, TRICHOGRAM, DAN TAPING
DALAM MENDIAGNOSIS DEMODEKSOSIS PADA ANJING)..... 85-90
- PURWANINGSIH, NOVIYANTI, RIZKI PRATAMA PUTRA
Prevalensi dan Faktor Risiko Paramphistomiasis
pada Sapi Bali di Distrik Prafi, Kabupaten Manokwari, Provinsi Papua Barat
(PREVALENCE AND RISK FACTORS OF PARAMPHISTOMIASISIN BALI CATTLE IN PRAFI
DISTRICT, MANOKWARI REGENCY, WEST PAPUA PROVINCE) 91-99
- DANES SUHENDRA, SUDJATMOGO, WIDIYANTO
Pengimbuhan Minyak Jagung Terproteksi dengan Berbagai Level Protein Ransum Sapi
Friesian Holstein Meningkatkan Kadar Asam Lemak Tidak Jenuh Susu
(CORN OIL PROTECTED SUPPLEMENTATION WITH VARIOUS OF PROTEIN LEVEL
ON FRIESIAN HOLSTEIN COW DIET FOR MILK UNSATURATED FATTY ACID LEVEL) 100-108
- I NYOMAN TIRTA ARIANA, ANAK AGUNG OKA, I GEDE SURANJAYA, I KETUT BERATA
Peningkatan Limfosit, Monosit, dan Basofil pada Sapi Bali yang Digembalakan
di Tempat Pembuangan Akhir Sampah Kota Denpasar
(THE ELEVATION LEVEL OF LIMPHOCYTE, MONOCYTE, AND BASOPHIL
ON BALI CATTLE GRAZING AT WASTE DISPOSAL CITY OF DENPASAR)..... 109-115
- SURIANA, JAMILI, PARAKKASI
Karakteristik Gen Sitokrom C Oksidase Sub Unit I (CO1) Lebah Liar *Apis cerena*
(Hymenoptera: apidae) Asal Pulau Hoga Sulawesi Tenggara
(CHARACTERISTICS OF GEN CYTOCHROME C OXIDASE SUBUNIT I (CO1) WILD BEES
Apis cerena (Hymenoptera: Apidae) FROM THE HOGA ISLAND OF SOUTH EAST SULAWESI) .. 116-125
- I GUSTI AGUNG GDE PUTRA PEMAYUN, I GUSTI NGURAH SUDISMA
Anestesi Tetes Infus Gravimetrik Ketapol sebagai Alternatif Bius Umum Secara
Inhalasi Guna Menjaga Status Teranestesi pada Babi
(THE GRAVIMETRIC INFUSION ANAESTHESIA WITH KETAPOL AS AN ALTERNATIVE
GENERAL INHALATION ANESTHESIA TO MAINTANACE
ANESTHESIA STATUS ON PIGS) 126-136
- ERWIN, RUSLI, AMIRUDDIN, DENI NOVIANA, RADEN RORO SOESATYORATIH,
ARNI DIANA FITRI¹, SITARIA FRANSISKA SIALLAGAN
Penanganan Obstruksi Duodenum pada Anjing: Laporan Kasus
(TREATMENT OF DUODENUM OBSTRUCTION IN DOGS: CASE REPORTS) 137-142
- PUVEANTHAN NAGAPPAN GOVENDAN, I GUSTI MADE ANANTHAWIJAYA,
ANAK AGUNG GEDE JAYAWARDITHA
Case Report : Urolith Surgical Removal in a Green Iguana (*Iguana iguana*)
(LAPORAN KASUS : BEDAH PENGELUARAN BATU KANTUNG KEMIH
PADA SEEKOR IGUANA HIJAU (IGUANA IGUANA)) 143-147
- PEDOMAN BAGI PENULIS i

Editor :

Jurnal Veteriner, Indonesian Veterinary Journal

Animal Hospital, Faculty of Veterinary Medicine Building, Udayana
University,

2nd Floor, Jalan Raya Sesetan, Gang Markisa No 6, Banjar Gaduh,

Sesetan, Denpasar, Bali, Indonesia

Email: bobbatan@yahoo.com

Publisher : Faculty of Veterinary Medicine, Udayana University

Alamat web: <https://ojs.unud.ac.id/index.php/jvet/article/view/40259>

DOI: <https://doi.org/10.19087/jveteriner.2018.19.1.71>

Volume No. : 19

Issue No : 1

Year : **2018**

ISSN Print: 1411-8327

ISSN Online :: 2477-5665

Hyaluronan Expression on Vitrified Oocytes Before and After In Vitro Maturation

(EKSPRESI HYALURONAN PADA OOSIT YANG DIVITRIFIKASI
SEBELUM DAN SESUDAH MATURASI IN VITRO)

Zakiyatul Faizah^{1*}, R. Haryanto Aswin¹,
Hamdani Lunardhi¹, Widjiati²

¹Faculty of Medicine, ²Faculty of Veterinary Medicine, University of Airlangga,
Jl. Prof. Dr. Moestopo 47, Surabaya, Jawa Timur, Indonesia
Telp. 031-5020125 Ext. 1137; Email: faizbiomed@yahoo.com

ABSTRACT

Oocyte vitrification is a major challenge in assisted reproductive technology. Oocyte vitrification with cumulus cells provide benefits in the process of maturation and fertilization. Vitrification leads to rapid temperature changes, therefore the decreasing in temperature could damage the cells even when the morphology was normal. Vitrification of mature oocytes is common because of its low sensitiveness towards low temperatures than immature oocytes. The aim of the research was to compare the effect of vitrification before and after *in vitro* maturation to the expression of hyaluronan. Maturation was operated in medium TC 50 µL in CO₂ incubators for 24 hours. Vitrification started with washing oocyte in PBS basic medium supplemented with 20% serum for 1-2 minutes, then in equilibration medium PBS + 20% serum + 10% ethylene glycol for 10-14 minutes, then transferred to 20% serum + PBS + 0.5 M sucrose + 15% ethylene glycol + PROH 15% for 25-30 seconds. Thawing was processed by submerging the oocytes in the media: 1). PBS + 20% serum + 0.5 M sucrose (K1); 2) PBS + 20% serum + 0.25 M sucrose (K2); and 3). PBS + 20% serum + 0.1 M sucrose (K3). Immunocytochemical stain was performed to evaluate the hyaluronan expression. Remmele scale index (Immunoreactive score, IRS) was used to read the result. There was no differences of hyaluronan expression in oocyte and cumulus group of K1, K2 and K3 at $p < 0.05$, statistically. We concluded that there was no difference of hyaluronan expression on oocyte and cumulus between vitrified oocyte of pre and post *in vitro* maturation which indicated that oocyte could be vitrified in the immature and mature state.

Keywords: vitrification; *in vitro* maturation; hyaluronan expression

ABSTRAK

Vitrifikasi oosit merupakan tantangan yang besar dalam teknologi reproduksi berbantu. Vitrifikasi oosit dengan sel kumulusnya memberikan keuntungan pada proses maturasi dan fertilisasi. Penelitian ini bertujuan membandingkan pengaruh vitrifikasi oosit sebelum dan sesudah maturasi *in vitro* terhadap ekspresi hyaluronan pada oosit dan sel kumulus. Oosit diaspirasi dari folikel berukuran 3-5 mm. Maturasi dilakukan dalam medium TCM 50 µl dalam inkubator CO₂ selama 24 jam. Vitrifikasi diawali dengan pencucian oosit dalam medium PBS yang disuplementasi serum 20% selama 1-2 menit, dilanjutkan dalam medium PBS + serum 20% + etilen glikol 10% selama 10-14 menit. Oosit kemudian dipindahkan dalam medium vitrifikasi PBS + serum 20% + sukrosa 0,5M + etilen glikol 15% + PROH 15% selama 25-30 detik. Thawing dilakukan dengan cara oosit direndam secara berturut dalam media : 1). PBS + 20% serum + sukrosa 0,5M, 2). PBS + 20% serum + sukrosa 0,25M, dan 3). PBS + 20% serum + sukrosa 0,1M. Dilakukan pemeriksaan imunositokimia untuk melihat ekspresi hyaluronan. Hasil pewarnaan dibaca dengan Indeks skala remmele (IRS). Ekspresi hyaluroan pada oosit dan kumulus K1, K2 da K0 tidak berbeda bermakna pada $p < 0,05$ Tidak ada perbedaan ekspresi hyaluronan pada oosit dan sel kumulus antara kelompok kontrol dan perlakuan, hal ini menunjukkan oosit dapat divitrifikasi dalam keadaan matur dan immatur.

Kata-kata kunci: vitrifikasi; maturasi in vitro; ekspresi hyaluronan

INTRODUCTION

Vitrification of oocytes has become a promising technology and has evolved in assisted reproductive technology as it could prevent the formation ice crystals. The use of high concentrations of cryoprotectants and extremely rapid cooling will result in a change of shape from liquid to solid without the formation of ice crystals (Chang, 2008). The development of frozen oocyte stores was longer due to the typical physical properties of the oocyte. First, human oocytes have a typical critical size where the volume and surface ratios are low, causing limited penetration of water and cryoprotectants to penetrate the plasma membrane, then it will be difficult to protect the oocytes from the formation of intracellular ice crystals (Cotichio, 2004). Second, the mature oocyte contains spindle yarns that were particularly susceptible to a decrease in temperature (Chen, 2003).

Vitrification of mature oocytes was more commonly performed because it was more resistant to a decrease of temperature than immature oocytes (Otoi *et al.*, 1995). Vitrification was expected to give the same results both on immature and mature oocytes in order to give hope for storing oocytes in immature state.

Vitrification leads to very rapid temperature changes, if there was a decrease in temperature it will cause damage in the cell, although there was no morphological changes. Complex cutaneous oocytes that have been vitrified in mature and immature states show improved survival, cell division ability, and lower blastocyst ability compared to non vitrified oocytes (Zhou *et al.*, 2010). Cumulus cells have the ability to support oocyte maturation during the maturation process (Yuan *et al.*, 2005). In vitro maturation of oocytes immature that have been removed from cumulus cells indicates a mismatch of nucleus and cytoplasm maturity (Combelles *et al.*, 2002). The function of cumulus cells in mature oocytes was to increase sperm penetration and improve fertilization rates in conventional IVF (Tanghe *et al.*, 2003).

Granulosa cell damage especially in the immature oocytes would disrupt hyaluronan synthesis that the oocyte needs to achieve its maturation. Hyaluronan synthesis performed by complex cumulus oocytes was influenced by FSH and paracrine signals from oocytes (Spicer and McDonald, 1998).

Research on the effect of vitrification on hyaluronan expressions that affect oocyte

maturation has not been widely done at this time. This study aims was to study the hyaluronan expression in cumulus cells and cytoplasm of oocytes that were vitrified before and after in vitro maturation.

RESEARCH METHODS

The sheep oocytes samples were used in this study, collected from 3-5 mm follicles. The comparative experimental laboratory study with post test only control group design was used in this study. The oocyte was divided into three groups. IVM was performed in the control group. Group 1 was going through in vitro maturation before it was vitrified meanwhile; Group 2 was vitrified before going through in vitro maturation. In vitro maturation was performed in 38°C incubators, 5% CO₂ with 95% humidity for 24 hours. Vitrification was initiated by the washing of oocytes in a PBS-supplemented basal medium for up to 1-2 minutes, followed by equilibration of the oocyte in PBS + serum 20% + ethylene glycol 10% for 10-14 minutes. The oocyte was then transferred in vitrified medium of PBS + serum 20% + sucrose 0.5 m + ethylene glycol 15% + PROH 15% for 25-30 seconds. Thawing is done by dipping the hemistraw into thawing media. Oocytes were soaked sequentially into media consisting of: 1). PBS + 20% serum + sucrose 0.5M, 2).PBS + 20% serum + sucrose 0.25M, and 3).PBS + 20% serum + sucrose 0.1M. Immunocytochemical stain was performed by washing the preparations with PBS for 2x5 minutes, then protolithic digestion was performed with trypsin 0.025% in incubator with temperature of 37°C for 15 minutes, followed by H₂O₂ for 10 minutes, given the primary antibody for 60 minutes, the next step was biotinylated link for 30 minutes, followed by giving streptavidin for 30 minutes, then given diaminobenzidine (DAB) chromagen 2% diluted with DAB plus substrate for 6-10 minutes. Washing was performed by PBS for 2x5 minute each change of the phase in order to clean up the remaining substance. Counterstain was done with methyl green 3 for 5-10 minutes at room temperature then it was examined under light microscope. The coloring result was read by Remmele scale index (IRS) which was the result of multiplication between immunoreactive cell percentage score and color intensity score on the immunoreactive cells. Data analysis was done by using one-way analysis of variance.

RESULTS AND DISCUSSION

Immunocytochemical examination was used to find out hyaluronan expression in oocytes and cumulus cells. The positive expression was characterized by brownish color on oocytes and granulosa cells. Hyaluronan expression in oocytes and cumulus cells is summarized in Table 1.

Table 1 showed no significant difference in hyaluronan expression in oocyte and cumulus between control group and treatment group with $p < 0,05$.

Oocytes and cumulus cells need each other in their developmental processes, cumulus cells have a major role in vitro maturation and oocyte development (Shirazi *et al.*, 2007), at least three compact cumulus cell layers were required to protect oocytes and in vitro maturation (Ebrahimi *et al.*, 2010). While the oocyte secretes factors that could protect the cumulus from apoptosis by maintaining the localization of gradient anti apoptotic factors in complex cumulus oocytes (Hussein *et al.*, 2005; Hussein *et al.*, 2006). Knowledge of Oocyte-Secreted Factors (OSFs) which regulate the function of granulosa and cumulus complex to this day is still growing, which has been widely known is the Growth Differentiation Factors 9 (GDF9) and Bone Morphogenetic Protein 15 (BMP15) (McNatty *et al.*, 2004). GDF 9 increases the expression of Hyaluronic Acid Synthetase (HAS2), Cyclooxygenase 2 and Gremlin (Pangas *et al.*, 2004). Hyaluronan (HA) is an important component of expanding cumulus complex oocytes, hyaluronan synthesized in cell membranes by HA synthases (HAS) (Weigel *et al.*, 2007).

In this study, hyaluronan expression was higher in oocytes and cumulus cells in both treatment groups with no significant differences. In the vitrified group prior to in vitro maturation, hyaluronan expression was higher than in the vitrified group after in vitro maturation, although not significantly different. It seems that

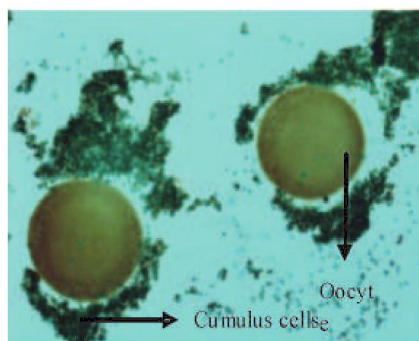


Figure 1. Hyaluronan expressions with immunocytochemical examination, cumulus cells and oocyte showed a score of 8(IRS)

the vitrification process does not affect in vitro maturation process.

The vitrification of the immature oocyte with its complex cumulus results in the death of the cumulus cells at the edges only, not on the inner part that close to the oocyte. Actin cytoskeleton on the surviving cumulus is also still well organized, as well as the gap junction between cumulus cells. Oocytes with complex cumulus images that experience death at multiple levels could still reach maturation (Tharasanit *et al.*, 2009). Oocytes protect the cumulus during culture, apoptotic COCs cultures occur in the outermost layer of the cumulus, whereas complex cumulus cultures with apoptotic oocyte cultures are found in the deepest cumulus layer (Hussein *et al.*, 2005). This was in accordance with the results of research that hyaluronan remains expressed in oocytes and cumulus was vitrified in the immature state that shows communication between oocyte and cumulus cell keep running, so that maturation could still be achieved.

Communication between cumulus cells and oocytes was instrumental in the process of oocyte maturation. The results of this study indicate

Table 1. Hyaluronan expression in oocytes and cumulus cells

Group	oocytes ± SD	cumulus ± SD
IVM (K0)	5,31 ± 1,62	3,01 ± 1,34
IVM+Vitrification (K1)	6,68 ± 2,80	5,75 ± 3,35
Vitrification+IVM (K2)	7,33 ± 4,75	6,67 ± 4,60

* = significant; IVM= in vitro maturation

that vitrification did not affect the oocyte maturation process, as the results obtained by Faizah *et al* (2014). That there was no difference in maturation of the vitrified oocytes before and after in vitro maturation.

This study used PROH as cryoprotectant, oosit viability after vitrification showed better results by using PROH, as well as embryonic development until blastocyst stage (Chian *et al.*, 2004).

Hyaluronan has the potential to improve the viability of embryos produced in vitro. Hyaluronan plays an important role in some cell functions including cell proliferation, cell migration, cell adhesion and cell signalling (Toole, 2001). The addition of hyaluronan to embryonic cattle culture could improve the development of embryos to the blastocyst stage (Jang *et al.*, 2003) and could improve the return of embryo expansion after vitrification (Block *et al.*, 2009) which has been shown in this study. The cumulus cells of Group K2 showed the highest hyaluronan expression compared to the other groups, so the oocytes also showed the highest hyaluronan expression compared to the other groups although not significantly different.

As the cumulus cell expands, cumulus cells secrete hyaluronan accumulated between cumulus cells. There were three types of genes in mammals encoding hyaluronan namely, Has 1, Has 2, Has 3 (Kimura *et al.*, 2002), but Has 1 was not detected in complex cytoplasm oocytes in cattle. In the culture for 12 hours and 24 hours, Has 2 was synthesized more than Has 3. The synthesis of Has 2 and Has 3 could be seen in the cross-sectional histologic images of complex cumulus oocytes that form composite and multilayered images of cumulus forming a sheath surrounding the oocyte. At the time of in vitro maturation, all cumulus cells attach strongly to one another, most of the cumulus cells scattered around the oocyte but still in the hyaluronan massive sheath. Only a layer of corona cells was still attached to the oocyte (Schoenfelder and Einspanier, 2003).

CONCLUSION

Based on this research, it was found that there was no difference of hyaluronan expression in oocytes and cumulus cells that were vitrified before and after in vitro maturation.

SUGGESTION

This study suggests that oocytes might be vitrified in immature and mature states.

ACKNOWLEDGMENT

Thanks to the Medical Faculty of Airlangga University who has funded this research from BOPTN sources.

REFERENCES

- Chian RC, Kuwayama M, Tan L, Tan J, Kato O, Nagai T. 2004. High survival rate of bovine matured oocyte in vitro following vitrification. *Journal of Reproduction and Development* 50(6): 685-695
- Chang CC, Saphiro DB, Bernal DP, Wright G, Kort HI, Nagy ZP. 2008. Two successful pregnancies obtaining following oocyte vitrification and embryo re-vitrification. *Reproductive Biomedicine online* 16(3): 346-349
- Combelles CM, Cekleniak NA, Racowsky C, Albertini DF. 2002. Assessment of nuclear and cytoplasmic maturation in in vitro. *Hum Reprod* 7(4): 1006-1016.
- Ebrahimi B, Valojerdi MR, Yazdi PE, Baharvand B. 2010. In vitro maturation, apoptotic gene expression and incidence of numerical chromosoma abnormalities following cryotopvitrification of sheep cumulus-oocyte complexes. *J Assist Reprod Genet* 27: 239-246
- Faizah Z, Hinting A, Darsini N, Widjiati. 2014. Perbandingan matures antar oosit sapi yang divitrifikasi pra dan pasca matures in vitro. *Veterinaria Medika* 7(3): 232-239.
- Gordon I. 2003. *Laboratory production of cattle embryo*. 2nded. CIBA Publishing. P122
- Hussein TS, David AF, Amato F, Jeremy GT, Gilchrist RB. 2005. Oocyte prevent cumulus cell apoptosis by maintaining a morphogenic paracrine gradient of bone morphogenetic protein. *J of Cell Sci* 118: 5257-5268

- Hussein TS, Thompson JG, Gilchrist RB. 2006. Oocyte secreted factors enhance oocyte developmental competence. *Develop Biol* 296: 514-521
- Jang G, Lee BC, Kang KC, Hwang WS. 2003. Effect of glycosaminoglycans on the pre implantation development of embryos derived from in vitro fertilization and somatic cell nuclear transfer. *Reprod Fertil Dev* 15: 179-185
- Kimura N, Konno Y, Miyoshi K, Matsumoto H, Sato E. 2002. Expression of hyaluronan synthases and CD44 messenger RNAs in porcine cumulus-oocyte complexes during in vitro maturation. *Biol Reprod* 66: 707-701
- Pangas SA, Jorgez CJ, Matzuk M. 2004. Growth differentiation factor 9 regulates expression of the bone morphogenetic protein antagonist gremlin. *J Biol Chem* 279: 32281-32286
- Otoi T, Yamamoto K, Koyama N, Suzuki T. 1995. In vitro fertilization and development of immature and mature bovine oocytes cryopreserved by ethylene glycol with sucrose. *Cryobiology* 32: 455-460
- Rall WF, Fahy GM. 1985. Ice-free cryopreservation of mouse embryos at -196°C by vitrification. *Nature* 313: 573-575
- Schoenfelder M, Einspanier R. 2003. Expression of hyaluronan synthases and corresponding hyaluronan receptors is differentially regulated during oocyte maturation in cattle. *Biology of Reproduction* 69: 269-277
- Shirazi A, Shams-Esfandabadi N, Hosseni SM, Karimi I. 2007. The presence of cumulus cells on nuclear maturation of sheeps oocyte during in vitro maturation. *Small Rumin Res* 68: 291-295
- Spicer AP, McDonald JA. 1998. Characterization and molecular evolution of a vertebrate hyaluronan synthase gene family *J Biol Chem* 276: 1923-1932
- Tanghe S, Van Soom A, Mehrzad J, Maes D, Duchateau L, de Kruif A. 2003. Cumulus contribution during bovine fertilization in vitro. *Theriogenology* 60: 135-149
- Tharasanit T, Colleoni S, Galli C, Colenbrander B, Stout TAE. 2009. Protective effects of the cumulus-corona radiata complex during vitrification of horse oocyte. *Reproduction* 137: 391-401
- Toole BP. 2001. Hyaluronan in Morphogenesis. *Semin Cell Dev Biol* 12: 79-87
- Weigel PH, Hasscall VC, Tammi M. 1997. Hyaluronan synthases. *J Biol Chem* 272: 22945-22948
- Yuan YQ, Van Soom A, Leroy JLMR, Dewulf J, Van Zeveren A, Kruif A, Peelman LJ. 2005. Apoptosis in cumulus cells, but not in oocytes, may influence bovine embryonic developmental competence. *Theriogenology* 63: 2147-2163.
- Zhou XL, Al Naib A, Sun DW, Lonerga P. 2010. Bovine oocyte vitrification using the Cryotop method: Effect of cumulus cells and vitrification protocol on survival and subsequent development. *Cryobiology* 61: 66-72.