

ORIGINAL ARTICLE

Effect of Vitamin D during Orthodontic Tooth Movement on Receptor Activator of Nuclear Factor Kappa- Ligand Expression and Osteoclast Number in Pregnant Wistar Rat (*Rattus norvegicus*)

Ida Bagus Narmada¹, Kinanthi Rizka Dewi Husodo¹, I Gusti Aju Wahyu Ardani¹, Dwi Rahmawati^{1*},
Alexander Patera Nugraha¹, Regina Purnama Dewi Iskandar¹

¹Orthodontics Department, Faculty of Dental Medicine, Universitas Airlangga, Surabaya, Indonesia

Abstract:

Background: Female patients have the possibility to become pregnant during orthodontic treatment. Vitamin D usually consumed by pregnant women. Estrogen and Vitamin D could affect bone metabolism. **Aim and Objectives:** The aim of this study was to analyze the effect of vitamin D during orthodontic movement in pregnant rats by Receptor Activator of Nuclear Factor Kappa- Ligand (RANKL) expression and osteoclast number. **Material and Methods:** The experimental observational analytic study with post-test only control group design and simple random sampling method was conducted. 24-healthy-female Wistar rats were divided into 4 groups; K1: pregnant rats with orthodontic tooth movement and vitamin D on Day 7; K2: pregnant rats with orthodontic tooth movement and vitamin D on Day 14; K3: pregnant rats with orthodontic tooth movement without vitamin D on Day 7 and; K4: pregnant rats with orthodontic tooth movement without vitamin D on Day 14. Nickle-Titanium coil spring with 10 g/mm² force was placed between the incisors and the maxillary molars. The RANKL expression and osteoclasts number were analyzed using Analysis of Variance (ANOVA) ($p < 0.05$). **Results:** The highest osteoclasts number (8.494 ± 1.194), and RANKL expression (7.967 ± 2.185) found in K1 group with significant between groups ($p < 0.05$). **Conclusions:** Vitamin D increase osteoclast number and RANKL expression during orthodontic tooth movement in pregnant rats.

Keywords: Pregnant, Vitamin D, Receptor Activator of Nuclear Factor Kappa-B Ligand, Osteoclast, Orthodontic Tooth Movement

Introduction:

Orthodontic treatment is the treatment that aligns the teeth to achieve good aesthetic and occlusion function. The teeth can move in the alveolar bone due to orthodontic force, there is cellular and biochemical activity, accompanied by increased remodelling of the periodontal ligaments and alveolar bone, allowing tooth movement. Cytokines, especially interleukins, also play an important role in the Receptor Activator of Nuclear Factor-Kb/ Ligand (RANK/RANKL) system that controls bone remodelling [1]. RANKL is a protein expressed by osteoblasts that regulates osteoclastogenesis in which binding to receptors on the pre-osteoclast surface (RANK) stimulates differentiation and activation into mature osteoclasts resulting in bone resorption [2]. Adolescents and adult women patients were the most patients with orthodontic treatment [3]. Orthodontic treatment was dominated by women with prevalence of 3:1 as compared with men. This proportion showed that women do more orthodontic treatment, because of aesthetic and appearance considerations [4]. Women are associated with various hormones, one of them is estrogen [5]. Female patients have a possibility of pregnancy during orthodontic treatment; previous research has shown that sex hormones have a physiological effect on bone metabolism, skeletal

bone formation, and maintaining bone balance in adults [6]. Estrogen also plays an important role in bone metabolism, including bone remodelling during orthodontic treatment [7].

In pregnancy, women consume various nutritional supplements for the mother and fetus, such as vitamin D. Previous research on tooth movement showed Vitamin D administration during orthodontic tooth movement can induce osteoclast formation thus leading to bone resorption, so the movement of teeth occurs faster than without vitamin D [8]. Although the functions and mechanisms of sex hormones in bone remodelling and vitamin D increase in bone remodelling are well-known, but the effects of vitamin D on pregnancy during orthodontic tooth movement are still unknown. Hence further research is needed in this direction. The aim of this study was to analyze the efficacy of vitamin D on orthodontic movement in pregnant rats by RANKL expression and osteoclast number.

Material and Methods

This study achieved Research Ethical Clearance from Faculty of Dental Medicine, Universitas Airlangga with number: 229/HRECC.FODM/X/2017. This study was experimental observational analytic study with post-test only control group design and simple random sampling method. The sample was 24-healthy-female Wistar rats (*Rattus norvegicus*), 16-20 weeks-old with weight 200-250 g selected blind-randomly into controls and treatment groups. K1: A group of pregnant rats with orthodontic tooth movement and vitamin D on Day 7; K2: A group of pregnant rats with orthodontic tooth movement and vitamin D on Day 14; K3: A group of pregnant rats with orthodontic tooth movement without vitamin D

on Day 7 and; K4: A group of pregnant rats with orthodontic tooth movement without vitamin D on Day 14. Vitamin D administration with dose of 2.5 mg Intramuscular (IM) once every 3 days for 7 days or 14 days. The orthodontic tooth movement was done by 8.0 mm-long Nickle-titanium coil spring (Ortho technology, China) which was placed between the maxillary central incisors to move the molar towards the mesial and was fixed using 0.07 stainless steel ligature wire around the maxillary incisor with 10 g/mm² force measured using a tension gauge daily [9].

All sample groups synchronized their mating cycles. The pregnancy is assisted by the injection of hormones Pegan Mare Serum Gonadotrophin (PMSG) and Human Chorionic Gonadotrophin (HCG), then collected with each male, to achieve the same gestation period, with treatment less than 21 days after being declared pregnant [9]. Determination of pregnancy is done with vaginal smear, with clinical examination and the presence of abdominal expansion, then confirmed by dissection and observation of the fetus in the womb after the rats were sacrificed [10].

All samples were sacrificed by rodent anaesthesia (60 mg/ b w of ketamine and xylazine 3 mg/ b w). Rat's premaxillae were dissected and placed in 10% formalin for four days. After fixation, the springs were removed, and the premaxillae were decalcified with 5% nitric acid for two days. The decalcified premaxillae were fixed again in the same manner for another three days. The sample was then dehydrated in a graded series of ethanol and embedded in paraffin (passage process). Clearing and impregnation were carried out. The paraffin blocks were sectioned serially using a microtome [11].

Samples were then examined by immunohistochemical staining by indirect technique using a 3.3'-diaminobenzidine stain kit (DAB) (Pierce™ DAB Substrate Paint Kit 34002, Thermofisher™, Waltham, Massachusetts, US) and monoclonal antibodies (Santa Cruz Biotechnology™, US) anti-RANKL sc-7628) cell was ready for microscopy analysis. The examination was carried out by 2 observers (Joko Legowo and Kinanthi Husodo) in 5 different visual fields and using Nikon H600L light microscope (Japan) at 400x magnification with a 300 megapixels Fi2 DS digital camera and image processing software Nikon Image System (Nikon, Japan) [12].

The data were analysed by Statistical Package for the Social Sciences 14.0 software (SPSS for

Windows, SPSS, Chicago, USA). Descriptive statistics are given as means ± Standard Deviation (SD). One-way Analysis of Variance (ANOVA), and Tukey-test for post hoc ($p < 0.05$) performed based on Shapiro-Wilk and Levene's test ($p > 0.05$) to compare the osteoclast number and RANKL expression between groups.

Results:

The highest number of osteoclasts was found in K1 group (Fig. 1) with significant difference between group ($p = 0.001$, $p < 0.05$) (Table 1). K1 has the highest expression of RANKL (Fig. 2), with significant difference between groups ($p = 0.001$, $p < 0.05$) (Table 2).

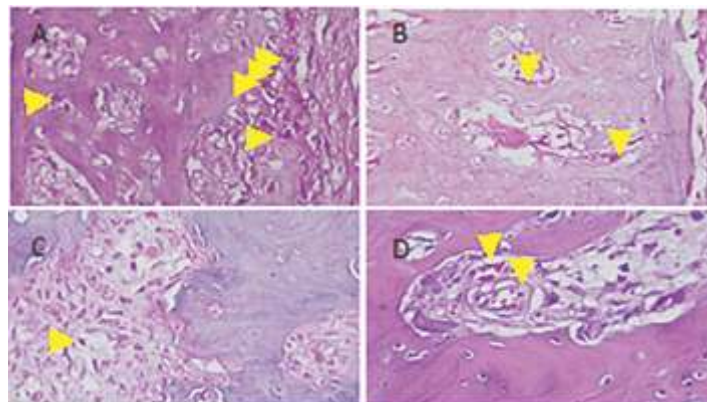


Fig. 1: Osteoclast Number (yellow arrow) was Detected in the Alveolar Bone on K1 (A), K2 (B), K3 (C), K4 (D) (HE Staining, Nikon Eclipse Ci 400x Magnification)

Table 1: Result of ANOVA Test in Osteoclast Number between Groups

Group	Mean ± SE	p-value
K1	8.493 ± 1.193	0.001*
K2	2.039 ± 1.268	
K3	2.090 ± 0.392	
K4	1.578 ± 0.640	

*significant differences between group ($p < 0.01$)

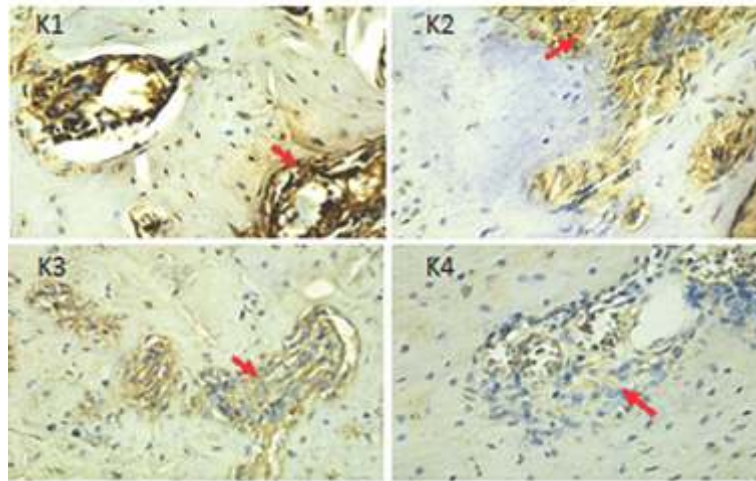


Fig. 2: RANKL Expression in Osteoblast in Each Group showed Positively (Brown Color) (Red Arrow) (Nikon H600L Microscope, DS Fi2 300-Megapixel Camera with 400x Magnification)

Table 2: Result of ANOVA Test in RANKL Expression between Groups

Group	Mean ± SE	p-value
K1	7.967 ± 2.185	0.001*
K2	6.167 ± 2.181	
K3	4.800 ± 1.080	
K4	4.167 ± 2.138	

**significant differences between group (p<0.01)*

Discussion

This study indicated that during pregnancy without vitamin D administration, the number of osteoclasts and RANKL expression was lower than groups with vitamin D. There was significant difference in osteoclast number and RANKL expression between groups. The estrogen level fluctuation during pregnancy can affect the tooth movement. Estrogen levels increase during pregnancy, thus tooth movement was decreased. The result of this study is in accordance with previous research which revealed that estrogen

deficiency can increase orthodontic tooth movement. Estrogen levels are inversely proportional to orthodontic tooth movement [10].

Estrogen is a hormone that inhibits osteoclast activity directly or indirectly. Estrogen directly inhibits bone remodeling by reducing osteogenesis. Estrogen works indirectly on osteoclasts by increasing calcitonin production. Increased secretion of calcitonin by estrogen will inhibit osteoclast action in bone resorption [11].

This is in accordance with previous studies comparing the osteoclast number after various orthodontic forces in pregnant and non-pregnant rats that showed the decreased number of osteoclasts in the pregnant rats group than in the non-pregnant rats group. The highest number of osteoclasts was found in K1 group, then decreased in K2 group. The decreased number of osteoclast is due to increased estrogen and progesterone level gradually in the early phase of pregnancy. The number of osteoclast was significantly decreased on the Day 7 after orthodontic treatment [11]. The administration of vitamin D in pregnant rats had significant effect on osteoclasts number and RANKL expression. The results showed that the highest number of osteoclasts was in K1. This is consistent with previous study which showed that after vitamin D administration, bone resorption occurred. Vitamin D stimulates osteoclast activity, thus providing a balance between resorption and bone tissue apposition [13].

The osteoclasts number in the group with vitamin D administration on Day 7 was higher than in the group with vitamin D administration on Day 14. In this case, the osteoclast number was higher between Day 7 and declined by Day 14. The result is in accordance with Matsunaga which stated that the tooth movement reaches a maximum limit on the Day 8 after coil spring insertion [13]. The number of osteoclasts increased dramatically in

the compression side of the periodontal ligament with a maximum increase on Day 8. RANKL expression on Day 7 treatment group increased with significant difference between groups. This result is in line with that of Li *et al.*, which stated that RANKL expression increases significantly after seven days [3].

The osteoclast number and RANKL expression were lower than the treatment group with vitamin D. In this case, fluctuations in estrogen levels in pregnancy can affect the tooth movement due to orthodontic forces. RANKL expression increased significantly between groups, according to a previous study of Li *et al.*, mentioned that RANKL expression increased significantly after 7 days of orthodontic tooth movement and subsequently tended to decline [3]. The results were consistent with previous study that vitamin D administration increased the tooth movement on the Day 9 compared with the control group [11, 14].

Conclusion

The result of osteoclast and RANKL expression in the group with vitamin D administration was higher than in the group without vitamin D, there was a significant effect of vitamin D on the tooth movement in pregnant rats. Vitamin D can accelerate orthodontic tooth movement by stimulating alveolar bone remodelling during pregnancy.

References

1. Krishnan V, Davidovitch Z. Cellular, molecular, and tissue-level reactions to orthodontic force. *Am J Orthod Dentofac Orthop* 2006; 129(4):1-32.
2. Kumamoto H, Ooya K. Expression of parathyroid hormone related protein (PTHrP), osteoclast differentiation factor (ODF) / receptor activator of nuclear factor-kappaB ligand (RANKL) and osteoclastogenesis inhibitory factor (OCIF)/ osteoprotegerin (OPG) in ameloblastoma. *J Oral Pathol Med* 2004; 33(1):46-52.
3. Li X, Yang Y, Zhang D, *et al.* Age effect on OPG expression in periodontal ligament cells during orthodontic tooth movement. *Chin J Orthod* 2003; 10:164-67.
4. De Souza RA, de Oliveira AF, Pinheiro SM, Cardoso JP, Magnani MB. Expectations of orthodontic treatment in adults: the conduct in orthodontist/patient relationship. *Dental Pres Orthod* 2013; 18(2):88-94.

5. Bao AM, Liu RY, van Someren EJ, Hofman MA, Cao YX, Zhou JN. Diurnal rhythm of free estradiol during the menstrual cycle. *Eur J Endocrinol* 2003; 148(2):227-32.
6. Proffit W, Henry F. The biologic basic of orthodontic therapy. In: contemporary Orthodontics. 4th Ed. St. Louis: Mosby Elsevier. 2007, 200-205
7. Kitaura H, Kimura K, Ishida M, Sugisawa H, Kohara H, Yoshimatsu M, et al. Effect of cytokines on osteoclast formation and bone resorption during mechanical force loading of the periodontal membrane. *Scientific World J* 2014; 617032.
8. Agoreyo FO, Okeke OG. Estrogen levels in the three trimesters of pregnancy in albino rat. *Jos J Med* 2014; 8:1.
9. Sonya GS, Rahmi A, Boedi OR, Joko K. The differences of orthodontic tooth movement on menstrual and ovulation cycle. *Dent. J. (Maj. Ked. Gigi)* 2014; 47(4):177-80.
10. Derek S. Osteoclast function in Bone Remodelling. *BIK Biomed* 2007; 3: 97-107.
11. Al-Hasani NR, Ali IA, Mowafaq G, Saad H. Clinical efficacy of locally injected calcitriol in orthodontic tooth movement. *Int J Pharm Pharm Sci* 2011; 3 (5):139-43.
12. Dolle C, Bindoff LA, Tzolis C. 3, 3'-Diaminobenzidine staining interferes with PCR-based DNA analysis. *Sci Rep* 2018; 8:1272.
13. Matsunaga SA, Ono T, Hayashi M, Takayanagi H, Moriyama K, Nakashima T. Osteocyte regulation of orthodontic force-mediated tooth movement via RANKL expression. *Sci Rep* 2017; 7(1):8753.
14. Kavos G, Pooya O, Behnam M, Loghman G, Alireza G, Esmaeil D, et al. The effect of pregnancy on orthodontic tooth movement in rats. *Med Oral Patol Cir Bucal* 2013; 18(2):e351-5.

***Author for Correspondence:** Dwi Rahmawati, Orthodontics Department, Faculty of Dental Medicine, Universitas Airlangga, Surabaya, Indonesia-60132 Email: dwi.rahma039@gmail.com Tel: +62315030255