

**Expression of TGF- β 1 During Fracture Repair in
Ovariectomized Rats with Therapy of *Cissus Quadrangularis*
Extract**

Lukiswanto B. S., Arifin M. Z. and Yudaniayanti I. S.

J Phys Pharm Adv 2015, 5(11): 779-786

DOI: 10.5455/jppa.20151118113714



Expression of TGF- β 1 During Fracture Repair in Ovariectomized Rats with Therapy of *Cissus Quadrangularis* Extract

Lukiswanto B. S., Arifin M. Z. and *Yudaniayanti I. S.

*Department of Veterinary Clinic, Faculty of Veterinary Medicine, University of Airlangga.

Abstract

This study aims to determine the osteogenic potential of *Cissus quadrangularis* extract based on its ability to increase the expression of TGF beta-1 in the case of osteoporotic fractures. This study used forty female rats weighing 200–250 g. The rats were acclimatized for ten days, before they were randomly assigned to the sham-operated (SX, n = 10) or ovariectomized (n = 30) groups. The treatment started to be given the next day after osteotomy for six weeks. Rats in P0(NOV) and P1(OV) group received 1.5 ml 0.5% NaCMC per-oral as placebo. P2 group was treated using Raloxifene 5,4 mg/kg of body weight and P3 group was treated using *Cissus quadrangularis* extract 750 mg/kg of body weight. Examination of expression of TGF- β 1 in this study performed twice. The first examination was done two weeks after osteotomy and the second examination was done six weeks after osteotomy. Based on the statistical test of the TGF β -1 expression at the 2nd week, the highest score belongs to the P0 group (NOV) that have significant difference (p<0.05) with other groups of treatments, while the lowest score belongs to group P1 (OV) that have significant difference (p<0.05) with other groups of treatments. There are no significant difference at the P2 and P3 groups (p>0.05). From the expression of TGF β -1 at the 6th weeks, the same pattern occurs to the 2nd week, the highest expression belongs to the P0 groups (NOV), and the lowest belongs to the P1 (OV) that have significant different with the other groups. The comparison of TGF β -1 expression between the 2nd and the 6th weeks at almost all of the groups shows no significant different (p>0.05). The concluded that the extract of *Cissus quadrangularis* has the potential osteogenic that is able to stimulate the proliferation and differentiation of osteoblasts from mesenchymal stem cells, but it also is able to increase the activity of osteoblasts in bone formation because it can increase the expression of Transforming Growth Factor β 1 (TGF- β 1).

Keywords: Osteoporosis, TGF β -1, ovariectomized, osteotomized, *cissus quadrangularis*.

* Corresponding author: Department of Veterinary Clinic, Faculty of Veterinary Medicine, University of Airlangga.

Received on: 26 Oct 2015

Revised on: 04 Nov 2015

Accepted on: 18 Nov 2015

Online Published on: 30 Nov 2015

Introduction

The increasing incidence of postmenopausal osteoporosis and its related fractures have become global health issues in the recent days. Postmenopausal osteoporosis is a systemic skeletal disorder characterised by reduced bone mineral density (BMD), micro architectural deterioration of bone tissue resulting in fragility and susceptibility to fractures and uncoupling of osteoblast-mediated bone formation and osteoclast (OC)-mediated bone resorption. Fragility fractures can cause significant morbidity and mortality in patients with osteoporosis and inflict a considerable medical and socioeconomic burden.

The treatment of osteoporotic fractures is a challenge because of the unpredictable outcome as a result of increased bone fragility, which predisposes to a high rate of implant fixation failure and a less than optimal environment for bone formation, leading to prolonged healing time and increased risk of non-union (Namkung-Matthai, 2001; Lill *et al.*, 2003; Nikolaou, 2009). Clinical observations indicate that fragility fractures heal despite the abnormality of bone remodelling in osteoporosis. There is no clear evidence yet as to whether complications during the course of healing are attributable to implant anchorage problems in osteoporotic bone or to possibly delayed healing in elderly patients. In animal models of fracture, fracture healing takes longer in older animals (Meyer *et al.*, 2001; Lill *et al.*, 2003). There is conflicting evidence as to whether ovariectomy adds an additional impediment to healing. Some animal studies show deficient healing, especially in the early response (Meyer *et al.*, 2006; Namkung-Matthai *et al.*, 2001), and some do not (Melhus *et al.*, 2007).

Many synthetic agents such as estrogens in hormone replacement therapy, selective estrogen receptor modulators like raloxifen and droloxifen, bisphosphonates and calcitonin have been developed to treat osteoporosis but each one of them is associated with side effects such as hypercalcemia, hypercalciurea, increased risk of endometrial and breast cancer, breast tenderness, menstruation, thromboembolic events, vaginal

bleeding and hot flushes (Genant *et al.*, 1998; Bennet *et al.*, 1984; Canalis *et al.*, 1998).

Traditional medicine has been widely used for thousands of years to treat bone disorders. Although these herbal medicines are seen as cost-effective alternatives by their traditional users, their international acceptance as a major regimen for prevention and treatment of osteoporosis would require extensive research using modern science (Potu *et al.*, 2009). *Cissus quadrangularis* is one such medicinal plant possessing osteogenic activity and is attaining increasing interest as a potential therapeutic agent for enhancing bone healing. The pharmacological and therapeutic ability of *Cissus quadrangularis* is well studied (Garima *et al.*, 2010; Jakikasem *et al.*, 2000). This plant has been customarily used in the bone fracture healing and also known as bonesetter for its ability to join bones (Potu *et al.*, 2009). Moreover, the extracts of this plant are reported to contain phytoestrogenic steroids, ascorbic acid, carotene, calcium and anabolic steroids (Mehta *et al.*, 2001). The effects of *Cissus quadrangularis* on the bone marrow mesenchymal stem cell proliferation and osteogenic differentiation were also studied (Boissesson *et al.*, 2004; Potu *et al.*, 2009). Several previous *in vivo* experiments have demonstrated that CQ promotes ALP activity and enhances collagen synthesis in the fracture-healing process (Shirwaiker *et al.*, 2003). In addition, there was a positive correlation value of serum ALP activity with the process of fracture healing in rat with therapy *Cissus quadrangularis* extract (Yudaniayanti, 2014)

It is expected that anabolic agents used to treat osteoporosis would have a beneficial effect on fracture healing. However, most patients who need treatment for osteoporosis will currently receive anticatabolic agents, and it is important to know whether this may have any disadvantage for the healing of incident fractures. The development of agents that possess osteogenic activity will enhance the above process. In the perspective of utilization of biologically active natural osteogenic agents, the plant species possessing medicinal properties that are being used in the ancient medicines are gaining much scrutiny of researchers. The osteogenic cells derived from mesenchymal or stromal stem cells uniquely elaborate the matrix of bone. These cells

differentiate into mature osteoblasts, which then actively synthesize and mineralize bone matrix (Harada & Rodan, 2003).

Based on the statement above, it is necessary to do further research to find out efektifitas extract *Cissus quadrangularis* / CQ as osteogenic agents capable bone destruction, especially in the incidence of fractures in patients with osteoporosis. The current study aimed to determine the effects of the administration of *Cissus quadrangularis* on the expression of TGF- β 1 during fracture healing in ovariectomized rats.

Materials and Methods

Animals

Fourty female rats (*Rattus Norvegicus*) weighing 200–250 g were purchased from the Laboratory Animal Resource Unit, Faculty of Veterinary Medicine, Universitas Airlangga. The rats were housed individually in clean cages at room temperature with a normal 12-hour light-dark cycle and free access to water and food. The rats were acclimatized for ten days, before they were randomly assigned to the sham-operated (SX, n = 10) or ovariectomized (n = 30) groups. Following a previously described protocol, the rats in the SX group underwent a sham operation, whereas the rats in the ovariectomized group underwent a bilateral ovariectomy at the beginning of the study (Adam *et al.*, 2009). This study was approved by the Animal Ethics Committee of Faculty of Veterinary Medicine Universitas Airlangga.

Experimental Protocol

The ovariectomy was performed at the tenth day of adaptation, except the P0 (-) which is the negative control group. Osteoporosis was allowed to develop in the animals for eight weeks after the ovariectomy. After the rats were confirmed by radiological examination as having osteoporosis, rats from all groups were osteotomized in the diaphysis of the femur with the installation of intramedullary pin. The length of the pin that would be needed was measured with Vernier caliper, based on the length of the femur from radiograph result to determine the length needed. Osteotomy was conducted under anesthesia using a combination of

ketamine (50 mg/kg of body weight) and xylazine (10 mg/kg of body weight) (Flecknell, 2009).

To approach the anterior intercondylar notch, a transverse incision was made on the right knee, and the patella was displaced laterally. A Kirschner wire (K-wire, 1.0 mm) (Jorgensen Lab, USA) was inserted into the anterior intercondylar notch toward the femoral medullary canal as a fixator. X-ray images were immediately obtained post-fracture to confirm both the intramedullary placement of the K-wire and the fracture. To prevent infection, 5% Enrofloxacin was given at a dose of 10 mg/kg I.M. (Bayer, Thailand) daily for 2 days with the daily dressing.

The treatment started to be given the next day after osteotomy for six weeks. Rats in P0 (NOV + osteotomy) and P1 (OV + osteotomy) group received 1.5 ml 0.5% NaCMC per-oral as placebo. P2 (OV + osteotomy) group was treated using Raloxifene 5, 4 mg/kg of body weight and P3 (OV + osteotomy) group was treated using *Cissus quadrangularis* extract 750 mg/kg of body weight. Raloxifene and *Cissus quadrangularis* extract doses were based on previous research of ¹Potu *et al.*, (2009) which studied the effect of *Cissus quadrangularis* to osteoporotic rats.

Treatment was given daily for six weeks via oral gavage immediately after fracture of the right femur. Examination of expression of TGF- β 1 in this study performed twice. The first examination was done two weeks after osteotomy and the second examination was done six weeks after osteotomy.

Examination results in six weeks are in addition to be compared among treatment groups with the two week post osteotomy. Five rats were taken from each treatment groups and anesthetized. After euthanasia, the right femur was dissected, and the K-wires were removed, and the tissue blocks of the fracture areas were fixed in 10% formalin for 24 h, decalcified in EDTA, and embedded into paraffin. The block was then cut into 4- μ m slices along the sagittal plane passing through the longitudinal axis of the femur. For immunohistochemistry, the sections were incubated in 3% H₂O₂ for 15 min to inhibit endogenous peroxidase activity after undergoing deparaffinization and rehydration. Following washing with distilled water, the sections were incubated in TBS with polyclonal antibodies

against TGF- β 1 diluted at 1:200 for 30 min. After 10-min washing with TBS, the sections were incubated with Envision TM for another 30 min. After washing with TBS for 10 min, the sections were incubated with diaminobenzidine (DAB) as a substrate and counterstained. The results were evaluated by microscopy. All samples were classified according to the percentage of TGF- β 1 positive cells (brown colour reaction).

Statistical Analysis

The results were expressed as mean value \pm standard deviation (SD). Data analysis for this study using one-way Anova for each treatment, then continued Duncan test to determine differences between treatment groups by using SPSS for Windows version 20.0 (Ghozali, 2006).

Results and Discussion

Radiological Examination to Process of Osteoporosis

Radiological interpretation of the analysis results showed significant differences in bone density were found between groups (Figure 5.1). Based on Figure 1 is visible radiological picture ovariectomized rats (OV) level of density lower than rat that were not ovariectomized (NOV) with the bones picture in NOV group more white and it also lines the cortical diaphysis clearer than the mice OV. Based on the analysis using the Mann Whitney test there is a significant difference ($p < 0.05$) radiographs of the femur bone density in rat. Femur bone density of the lowest found in the treatment group OV. These results suggest that bone density in the lower OV group.

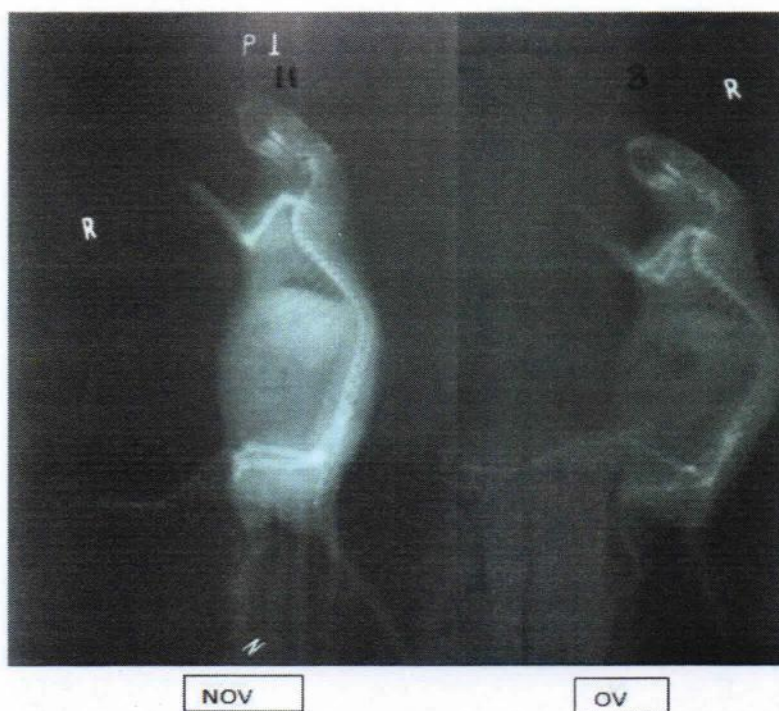

Fig. 5.1: Gambaran Radiologi densitas tulang antara tikus yang tidak diovariectomi (NOV) dengan tikus yang diovariectomi (OV).

Examination of Expression of TGF β -1

The examination of TGF β -1 expression was done in the 2nd week and the 6th week after osteotomy through the immunohistochemistry. This examination was intended to assess TGF β -1 expression at the beginning and the end of the fracture healing process. The table 5.1 shows

statistical analysis of TGF β -1 expression at the 2nd and the 6th week after osteotomy.

Based on the statistical test of the TGF β -1 expression at the 2nd week, the highest score belongs to the P0 group (NOV) that have significant difference ($p < 0.05$) with other groups of treatments, while the lowest score belongs to group P1 (OV)

that have significant difference ($p < 0.05$) with other groups of treatments. There are no significant

difference at the P2 and P3 groups ($p > 0.05$).

Table 1: Mean rate and deviation standard expression of the TGF β -1 on the fracture healing process of rats (*Rattus norvegicus*) on each groups of treatments.

No.	Groups of treatment	TGF β -1 (2 nd weeks)	TGF β -1 (6 th week)
1.	P0 (NOV + Osteotomy + CMC Na)	16,4 \pm 1,95 ^{ac}	18,2 \pm 1,64 ^a
2.	P1 (OV + Osteotomy + CMC Na)	4,4 \pm 1,14 ^b	7,4 \pm 1,52 ^d
3.	P2 (OV + Osteotomy + RLX)	11,6 \pm 1,52 ^c	14 \pm 1,41 ^{ce}
4.	P3 (OV + Osteotomy + CQ)	13,2 \pm 1,09 ^c	15,4 \pm 2,07 ^e

a, b, c, d, e; Different superscripts indicate significant differences ($p < 0.05$).

From the expression of TGF β -1 at the 6th weeks, the same pattern occurs to the 2nd week, the highest expression belongs to the P0 groups (NOV), and the lowest belongs to the P1 (OV) that have significant different with the other groups. The comparison of TGF β -1 expression between the 2nd and the 6th weeks at almost all of the groups shows no significant different ($p > 0.05$), only P1 groups shows significant difference between the 2nd and the 6th groups ($p < 0.05$). Based on the graphic of TGF β -1 expression, the 6th week is higher than the 2nd

week (Figure 5.2). This result shows that the expression of TGF β -1 is slightly higher at the remodeling phase (6th week) when the endochondral ossification occurs, this condition occurs because both cells, chondrocytes and osteoblast contain a lot of TGF β -1 receptors. Based on these, the TGF β -1 roles in all phase of bone healing process (Joyce *et al.*, 1990; Ishidou *et al.*, 1995; Kaspar *et al.*, 2003). The result of immunohistochemistry TGF β -1 could be seen at the Figure 5.3 and 5.4.

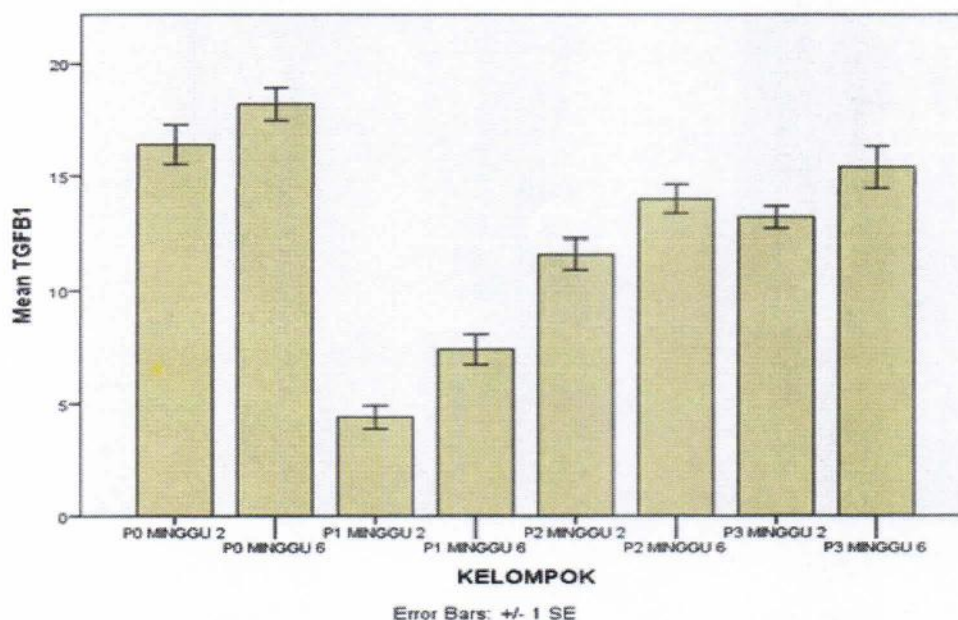


Fig. 5.2: Graphic of TGF β -1 expression at the 2nd week and the 6th week at all groups of treatments.

EXPRESSION OF TGF-B1 DURING FRACTURE REPAIR IN ...

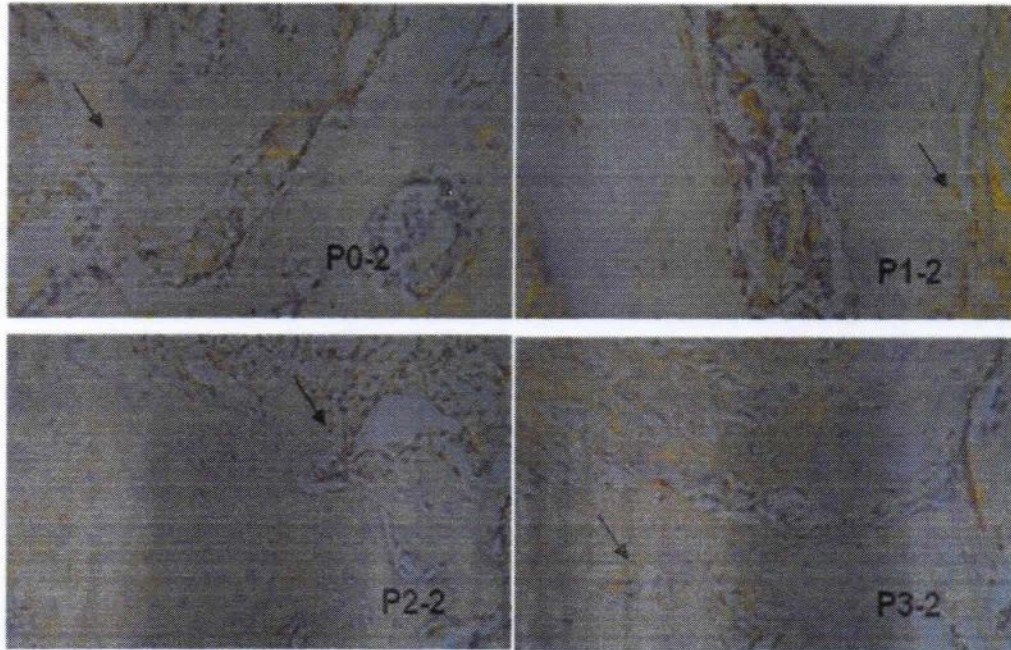


Fig. 5.3: The examination result of immunohistochemistry expression of TGFβ-1 at the 2nd weeks at all group of treatments, the arrows indicate cells expressing TGFβ-1 (brown).

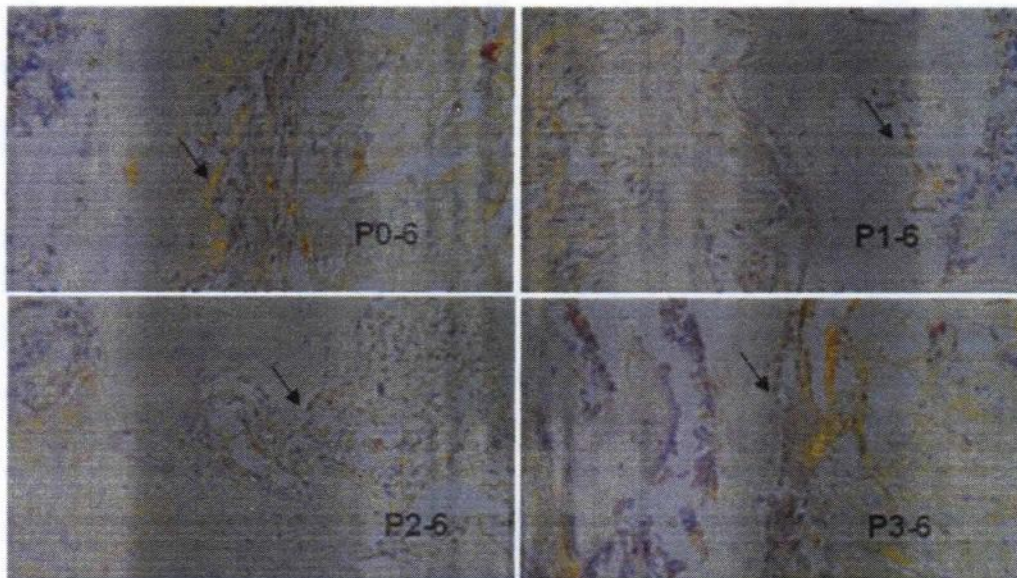


Fig. 5.4: The results from immunohistochemistry examination of TGFβ-1 at the 6th week at all group of treatments, the arrows indicate cells expressing TGFβ-1 (brown).

This condition shows that at the fracture healing process of normal bone healing of rats (without ovariectomized) the expression of TGFβ-1 is quite high, this condition occurs because the estrogen production is still normal, so it could stimulates the TGFβ-1 expression by the osteoblast

cell and stroma cell that continues to hold up the bone resorption and accelerate the apoptosis of osteoclast. Zimmermann *et al.*, (2005) states that on the 2nd week, the fracture healing process entering the phase where it starts to form granulation and soft callus, the osteoblast, chondroblast and the

young progenitor cells (soft callus) was also increasing. This phase marked by the increasing of TGF β -1 serum, thus related to the proliferation of periosteum tissue. TGF β -1 found at almost all kind of tissue, but it mostly found at the bone tissue, platelets and cartilage, so TGF β -1 have an important role in the bone healing process.

Zimmermann *et al.*, (2005) in his research proved that in the delayed union case, occurs a decreasing of TGF β -1 compared to the union fracture case. This condition caused by TGF β -1 is the only growth factor that work as mediator to attract osteoblast to the place of bone hole that had been absorbed by the osteoclast. This condition also occurs at the P1 group which was ovariectomized without given any therapy, where the expression of TGF β -1 shows the lowest score at the 2nd weeks and the 6th weeks. This caused by the deficiency of estrogen as the impact of ovariectomy induce the production of IL-1, IL-6, dan TNF-a produced by M-CSF and RANK-L. Then, the RANK-L induce the activity of JNK1 and osteoclastogenic activator protein-1, transcription factor of c-Fos and c-Jun, resulting in the increasing of osteoclast activity and decreasing of osteoblast activity (Bell and Normal, 2003). The decreasing of osteoblast activity also will give an impact to TGF β -1 receptors, so the expression is decreasing. The same result also shown at the research of Liu *et al.*, (2008) and Estai *et al.*, (2011), there are decreasing of TGF β -1 on the ovariectomized rats. The decreasing of TGF β -1 by the osteoblast will give a negative impact to the fracture healing process on the ovariectomized rats.

Different result obtained from the P2 and P3 groups. The expression of TGF β -1 in this group is higher than the P1 group, although the rats from this group was also ovariectomized, but it treated with Raloxifene (P2) and extract of *Cissus quadrangularis* (P3). Raloxifene effect in fixing the bone damage is decreasing the activity of osteoblast so the TGF β -1 rate is higher than P1.

Phytoestrogen contains in the *Cissus quadrangularis* are isoflavon, ligni, coumestan, triterpan, glycoside, and acyclic are able to bind with the beta receptor of estrogen in osteoblast and could stimulate the proliferation of osteoblast (Yamaguchi 2002). Besides, isoflavon also induce the differentiation of osteoblast through activation

of transforming-growth factor β (TGF- β) (Kim 1998). Based on these results it can be concluded that the extract of *Cissus quadrangularis* has the potential osteogenic that is able to stimulate the proliferation and differentiation of osteoblasts from mesenchymal stem cells, but it also is able to increase the activity of osteoblasts in bone formation because it can increase the expression of Transforming Growth Factor β 1 (TGF- β 1), which acts as an agent to stimulate the formation of bone fracture healing. The development of agents that possess osteogenic activity will enhance the above process. In the perspective of utilization of biologically active natural osteogenic agents, so that extract of *Cissus quadrangularis* can promote healing process in case osteoporotic fractures.

References

- Adam SK, Das S, Othman F, Jaarin K (2009). Fresh soy oil protects against vascular changes in an estrogen-deficient rat model: an electron microscopy study. *Clin.*, 64: 1113-9. DOI: 10.1590/S1807-59322009001100012.
- Bell Norman H (2003). RANK ligand and the regulation of skeletal remodeling. *J. Clin. Invest.*, (111): 1120-22.
- Bennet AE, Wahner HW, Riggs BL (1984). Soya-a dietary source of the non-steroidal oestrogen equal in man and animals. *J. Endocrinol.*, 102: 49-56.
- Boissesson MR, Leonard M, Hubert P, Marchal P, Stequert A, Castel C, *et al.*, (2004). Physical alginate hydrogels based on hydrophobic or dual hydrophobic/ionic interactions: Bead formation, structure, and stability. *J. Colloid Inter. Sci.*, 273: 131-139.
- Canalis H, McCarthy T, Centrella M (1998). Growth factors and the regulation on bone remodeling. *J. Clin. Invest.*, 81: 277-281.
- Estai MA, Suhaimi F, Das S, Shuid AN, Mohamed Z, Soelaiman IN (2011). Expression of TGF- β 1 in the Bood during Fracture Repair in an Estrogen-deficient Rat Model. *Clinics. Basic Res.*, 66(12): 2113-2119.
- Flecknell P (2009). *Laboratory Animal Anesthesia* 3rd Ed. Elsevier Inc., London. 183-186.
- Garima M, Saurabh S, Nagori BP (2010). Pharmacological and therapeutic activity of *Cissus quadrangularis*: An overview. *Int. J. Pharm. Tech. Res.*, 2: 1298-1310.
- Genant HK, Bay link DJ, Gallagher JC (1998). Estrogens in the prevention of osteoporosis in post-menopausal women. *Am. J. Obstet. Gynaecol.*, 161: 1842-1846.
- Ghozali I (2006). *Statistik Non-Parametrik Teori dan Aplikasinya dengan Program SPSS*. Badan Penerbit Universitas Diponegoro. Semarang.
- Harada S, Rodan GA (2003). Control of osteoblast function and regulation of bone mass. *Nat.*, 423: 349-355.

EXPRESSION OF TGF- β 1 DURING FRACTURE REPAIR IN ...

- Ishidou Y, Kitajima I, Obama H, Maruyama I, Murata F, Imamura T (1995). Enhanced expression of type I receptors for bone morphogenetic proteins during bone formation. *J. Bone Miner Res.*, 10: 1651-9.
- Jakikasem S, Limsiriwong P, Kajsongkarm T, Sontorntanasart T (2000). Phytochemical study of *Cissus quadrangularis*. *Thai J. Pharm. Sci.*, 24: 5.
- Joyce ME, Jingushi S, Bolander ME (1990). Transforming growth factor-beta in the regulation of fracture repair. *Orthop. Clin. North Am.*, 21: 199-209.
- Kaspar D, Neidlinger-Wilke C, Holbein O, Claes L, Ignatius A (2003). Mitogens are increased in the systemic circulation during bone callus healing. *J. Orthop. Res.*, 21: 320-325.
- Kim H, Peterson TG, Barnes S (1998). Mechanisms of action of the soy isoflavone genistein: emerging role for its effects via transforming growth factor β signaling pathways. *Am. J. Clin. Nutr.*, 68(Suppl): 1418S-25S.
- Lill CA, Hessel J, Schlegel U, Eckhardt C, Goldhahn J, Schneider E (2003). Biomechanical evaluation of healing in a non-critical defect in a large animal model of osteoporosis. *J. Orthop. Res.*, 21: 836-42.
- Liu H, Xu K, Qiao L (2008). Effects of estrogen on the expression of TGF- β in early fracture healing of ovariectomized rats. *Bone.*, 43: S54-S55. DOI: 10.1016/j.bone.2008.08.048.
- Mehta M, Kaur N, Bhutani K (2001). Determination of marker constituents from *Cissus quadrangularis* Linn and their quantitation by HPTLC and HPLC. *Phytochemical Anal.*, 12: 91-105.
- Melhus G, Solberg LB, Dimmen S, Madsen JE, Nordsletten L, Reinholt FP (2007). Experimental osteoporosis induced by ovariectomy and vitamin D deficiency does not markedly affect fracture healing in rats. *Acta Orthop.*, 78-3: 393-403.
- Meyer Jr RA, Desai BR, Heiner DE, Fiechtl J, Porter S, Meyer MH (2006). Young, adult, and old rats have similar changes in mRNA expression of many skeletal genes after fracture despite delayed healing with age. *J. Orthop. Res.*, 24(10): 1933-44.
- Meyer Jr RA, Tsahakis PJ, Martin DF, Banks DM, Harrow ME, Kiebzak GM (2001). Age and ovariectomy impair both the normalization of mechanical properties and the accretion of mineral by the fracture callus in rats. *J. Orthop. Res.*, 19(3): 428-35.
- Namkung-Matthai H, Appleyard R, Jansen J, Hao Lin J, Maastricht S, Swain M (2001). Osteoporosis influences the early period of fracture healing in a rat osteoporotic model. *Bone.*, 28(1): 80-6.
- Nikolaou VS, Efsthopoulos N, Kontakis G, Kanakaris NK, Giannoudis PV (2009). The influence of osteoporosis in femoral fracture healing time. *Inj.*, 40: 663-8.
- Potu BK, Bhat KM, Rao MS, Nampurath GK, Chamallamudi MR, Nayak SR, Muttigi MS (2009). Evidence-based assessment of antiosteoporotic activity of petroleum ether extract of *Cissus quadrangularis* Linn. On ovariectomy-induced osteoporosis. *Upsala J. Med. Sci.*, 114: 140-148.
- Potu BK, Bhat KMR, Rao MS, Nampurath GK, Chamallamudi MR, Nayak SR, *et al.*, (2009). Petroleum ether extract of *Cissus quadrangularis* (Linn) enhances bone marrow mesenchymal stem cell proliferation and facilitates osteoblastogenesis. *Clin.*, 64: 993-998.
- Shirwaiker A, Khan S, Malini S (2003). Antiosteoporotic activity of ethanol extract of *Cissus quadrangularis* Linn on ovariectomized rat. *J. Ethnopharmacol.*, 89: 245-250.
- Xu SW, Yu R, Zhao GF, Wang JW (2003). Early period of fracture healing in ovariectomized rats. *Chin. J. Traumatol.*, 6(3): 160-6.
- Yamaguchi M (2002). Isoflavone and bone metabolism: its cellular mechanism prevention role in bone loss. *J. Health Sci.*, 48(3): 209-220.
- Yudaniyanti IS, Nangoi L, Soepraptini J (2014). Correlation of Serum ALP Activity with the Healing Process of Femoral Fractures in Rats Used *Cissus quadrangularis* Extract as Therapy. *J. Phys. Pharm. Adv.*, 4(1).
- Zimmerman G, Henle P, Kusswetter A, Moghaddam A, Wentzensen A, Richter W, Weiss S (2005). TGF- β 1 as Marker of Delayed Fracture.