

Total hip arthroplasty performed in a 13-year-old Girl with avascular necrosis (AVN) of the left hip: A Case Report

by Komang Agung Irianto

Submission date: 20-Sep-2018 06:26PM (UTC+0800)

Submission ID: 1005240284

File name: 3._Total_Hip_-_Dr_Komang_BMJ_2017_dr_Ian.pdf (1.19M)

Word count: 2564

Character count: 13392



Published by DiscoverSys

Total hip arthroplasty performed in a 13-year-old Girl with avascular necrosis (AVN) of the left hip: A case report



CrossMark

Komang Agung Irianto S,^{*} Adrianto P Perbawa

ABSTRACT

16 Total hip arthroplasty (THA) is a commonly performed procedure in adults but rarely resorted to as a surgical option in the case of children. It is not only technical challenging, but the real staple is how to reach the decision. Until now arthrodesis is the primary option in the treatment plan for severe hip destruction. We are reporting the case of a 13-year-old girl who suffered left hip pain caused by the unknown destruction of the joint. On physical examination, the girl presented a

limping gait that was caused by severe pain and discrepancy between the lengths of both legs and also adduction contracture. The imaging suspected AVN feature without showing evidence for clear causal factors like Legg-Calve-Perthes disease (LCP), infection, juvenile rheumatoid arthritis (JRA), or slipped capital femoral epiphysiolysis (SCFE). We report a rare case of THA in a girl who had had an unclear preoperative diagnostic.

Keywords: total hip replacement, children, hip pain

Cite This Article: Irianto, K.A.S., Perbawa, A.P. 2017. Total hip arthroplasty performed in a 13-year-old Girl with avascular necrosis (AVN) of the left hip: A case report. *Bali Medical Journal* 6(2): 432-435. DOI:10.15562/bmj.v6i2i.615

Department of Orthopedic and Traumatology Dr. Soetomo General Hospital Medical Faculty of Airlangga University Surabaya

INTRODUCTION

15 Avascular necrosis (AVN) of the hip is one of the most devastating and common complications of injuries or conditions such as SCFE (slipped capital femoral epiphysis), Legg-Calve-Perthes disease (LCPD), developmental dysplasia of the hip, sickle cell anemia, prolonged use of steroid in SLE cases, and arthritis in the child's hip¹⁻⁴ AVN has three patterns as described by Ratliff⁵ in 1962.

These patterns are as follows:

Type I (total AVN), which involves the entire capital femoral epiphysis and proximal femoral neck fragment;

Type II (metaphyseal AVN), which involves fracture extending up to the physis;

Type III is a partial epiphyseal AVN in which the AVN is confined to the femoral head (Fig. 1).^{3,5}

Incidences of LCPD were reported to be at 9.3 in Scandinavia;⁶ another study reviewed 25 articles on the LCPD incidence in relation to different ethnicities and found that there was a wide range of LCPD incidences, with the lowest level of incidence taking place in the Indo-Malay ethnicities.⁷ In the case of SCFE, a review on the incidence in the Asian region showed an average of 0.8.⁸ As for rheumatoid arthritis, one study in Indonesia found that the prevalence was 0.5%.⁹ For juvenile idiopathic arthritis, the prevalence of incidence ranged from 3–13.9%.

We present one case of AVN in an adolescent with no clear etiology because the patient did not seek medical treatment until several months since the complaint started. The patient presented with clinical and radiological features of AVN of the hip.

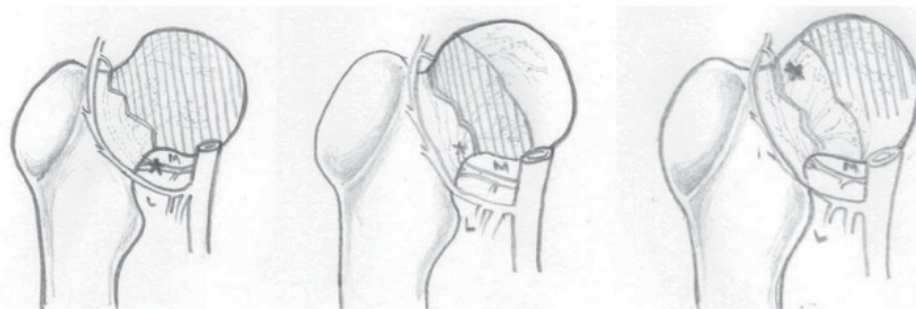


Figure 1 Three types of AVN⁵

^{*}Correspondence to: Komang Agung Irianto S, Department Orthopedic and Traumatology, Dr. Soetomo Hospital, Jalan Prof dr Moetopo 6-8 Surabaya, Indonesia
 komang168@yahoo.com

Received: 2017-05-07
 Accepted: 2017-06-2
 Published: 2017-06-9

Arthroplasty is a commonly used procedure in adults but seldom used in children. It is not only technically challenging but also poses a problem in preoperative diagnostics. Until now arthrodesis is still the primary option when it comes to treating the severe hip problem. Except for this case up until now, there has been no report in Indonesia about total hip replacement procedure carried out despite unclear diagnosis for THA in children. This work has been reported in line with the SCARE criteria.¹¹

Case Presentation

A 13-year-old girl complained of limping and pain in the left hip after trivial trauma about 8 months ago before she came for diagnosis. She felt pain in sitting position. After that accident, she walked with crutches. Physical examination of the gait showed short leg gait, Galeazzi sign was positive, Trendelenburg sign was positive, there was leg length discrepancy (LLD) of 4 cm. There was adduction contracture, but no other contractures were found. The girl was 158 cm tall, weighed 60 kg with a BMI of 24, which placed her in the overweight category. All of the laboratory results

were normal, and there was no sign of infection, inflammation, or other kinds of immune diseases. Radiology examination showed the collapse of the head and MRI revealed avascular necrosis of the head femur. She admitted that she was put in traction for 2 weeks, and still there is no improvement in LLD. Preoperative planning included arthrodesis of the left hip if possible. Unfortunately, total hip replacement of the left hip was already done. It is based on the condition during operation.

Preoperative preparation

Laboratory tests were done to evaluate the possibility of the presence of other diseases. All of the results that were obtained showed normal limits, including a chest x-ray.

Preoperative template pelvic x-ray (true size) was used to measure the right size of prosthesis.

Radiographic examination showed destruction and degeneration of the left femoral head associated with the destruction of the acetabular surface. Magnetic resonance imaging (MRI) confirmed deformity, subluxation, and impaction of the femoral head toward the superior and synovitis of the left hip enhanced by contrast administration.

Durante Operation

The patient was under general anesthesia and lateral decubitus position. The posterolateral approach was done. We opened layer by layer, found thickening of the capsule, synovial fluid serosanguineous, destruction of the head femur, and acetabulum. There is synovial tissue ingrowth to acetabulum surface partially. All of the synovium materials were sent for pathology examination. We used the same technique with THR in adults, but the difference is the anatomy was smaller; thus, a detailed preoperative preparation is key to minimize complications.

Post-operative follow-up treatment. Antibiotics and analgesics were given for two days, and a rehabilitation program was chalked out and implemented, and the program was carried out 6–12 hours after the operation and was continued for 24 hours. The program consisted of isometric and isotonic rehabilitation procedures, and the patient was subjected and familiarized to partial weight-bearing using the double crutch. After 2 days drain was removed, and the catheter was removed after 3 days. Patient's stay at the hospital lasted for 3 days, and during this period she underwent the weight-bearing procedure to get used to being mobile using the double crutch. Postoperatively the leg length discrepancy was reduced to 1 cm, and the patient had already started non-weight-bearing mobilization using a walker 3 days after the operation, and the patient was able to sit properly. The histopathology slides

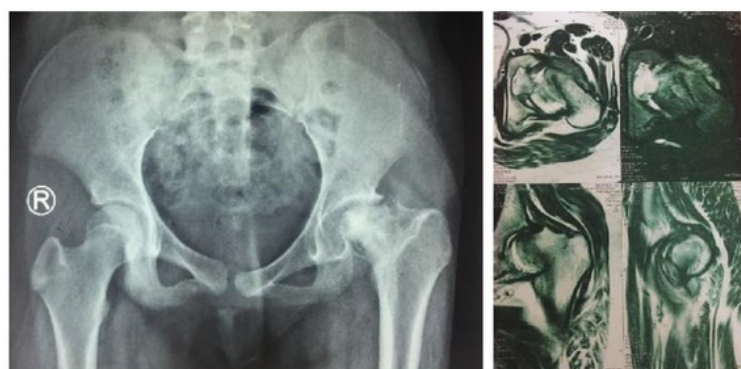

Figure 2 Right: (a) X-ray of pelvic view: migration proximally of the femur and collapse of the head of the femur; (b) left MRI deformity, subluxation, and impaction of the femoral head toward the superior and synovitis of left hip enhanced by contrast administration.

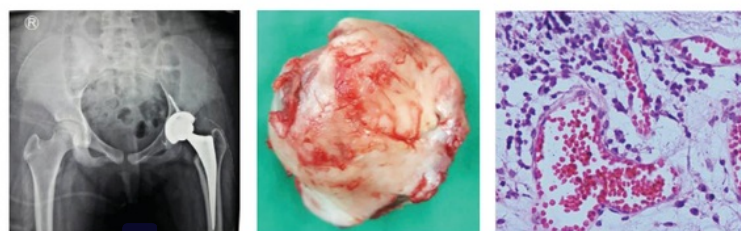


Figure 3 (a) Post-operation x-ray of the left hip after THR, (b) Gross specimen of the head femur, (c) histopathology result: hypervascular synovium, foci of vasculitis (precipitate inflammatory cells around vascular)(in the box); mostly of plasma cells.

show vasodilation, infiltration of lymphocytes, and interstitial edema. These conditions may also be found in cases of rheumatoid arthritis and chronic inflammation.^{10,12}

DISCUSSION

We were not able to determine the etiology of the AVN in this case because the patient did not have any radiological picture after the initial trauma or complaints. The patient presented with an already neglected case. Femoral neck fracture may be one of the causes of hip AVN in adolescents.³ Delbet,⁷ and later Colonna⁸ described four types of femoral neck fractures in pediatric patients (Fig. 6).^{3,9} Type I fractures had a higher rate of osteonecrosis/ avascular necrosis than other types of femoral neck fractures.⁹ Hip fractures in children are very rare and often caused by a high-energy trauma, in which associated injuries to the abdomen or pelvic are also common.^{3,5,9} Only in few cases, femoral neck fractures occur after trivial trauma, but in these cases, there was already a preexisting lesion which was unknown earlier. The most common conditions are a unicameral bone cyst, osteogenesis imperfecta, fibrous dysplasia, and meningomyelocele. This patient never had any high-energy trauma before, but we still could not determine whether there were any pathologic lesions earlier; thus, to confirm the presence of lesion we did a biopsy during surgery. However, we ruled out pure traumatic fracture of the femoral neck given the trivial trauma sustained by the patient.

Another condition that may cause hip AVN in children is slipped capital femoral epiphysis (SCFE).^{10–12} Usually, AVN caused by SCFE occurs after treatment with osteotomy or closed or open reduction of the hip, and any unstable acute displacement that has not been treated may also cause AVN of the hip.¹² Most cases occur in slips that have been treated and are caused by blood supply disturbance preoperatively or by the procedure carried out to treat slips. AVN in SCFE cases is different than in LCPD cases in which there is a single vascular insult and less remodeling capacity.¹³ An SCFE might still be the cause of AVN in this case because it fits the age group in which SCFE occurs, that is, adolescence.¹²

Legg-Calve-Perthes disease may also cause AVN in children.^{10,14} This is a poorly understood condition in which the proposed theory posits that there is a disruption in the blood supply to the growing femoral head.^{14,15} In LCPD, it has a characteristic sequence of epiphyseal growth retardation, followed by sclerosis, fragmentation, re-ossification, and healing stages. We rule out LCPD because the

radiological findings do not match the characteristics of LCPD but are more similar to total AVN.^{14,15}

Regardless of what might have caused AVN in this case, we still need to find the best choice of treatment to increase the quality of life of the patient and to preserve or restore as much joint motion as possible. Total hip arthroplasty (THA) is not the choice treatment in early stages of AVN conditions in children, and in such cases, conservative treatment is usually the best choice and surgery may be needed in unstable conditions.^{12–14} THA is now widely done not only for rheumatoid arthritis in young patients but also for other etiologies. THAs are done mainly because of AVN caused by complications rather than on account of degenerative changes.¹⁶ The author of the work above also prefers cementless fixation for both acetabular and femoral components. Cementless fixation combined with improved materials may provide long-term survivorship.¹⁶

Another choice treatment is HRA (hip resurfacing arthroplasty). To treat THA compared to HRA in AVN cases caused by LCPD or SCFE is easier because in these cases the femoral neck condition makes it difficult to achieve reliable fixation for the femoral component.¹⁵

One report from Norway stated that most patients with SCFE that underwent THA were females, and they suspected that the cause might be that in females the slip is usually more severe, and there is a likelihood of delay in diagnosis because physicians are more likely to suspect SCFE in males than in females.¹⁷

CONCLUSION

This case report suggests considering SCAFE, LCP, and rheumatoid arthritis of hip as one of differential diagnostics of its pain in children, in addition to considering THA as the other choice before doing arthrodesis as the last choice in the treatment plan.

CONFLICT OF INTEREST

The authors affirm no conflict of interests in this study.

REFERENCES

1. Adekile AD, Gupta R, Yacoub F, Sinan T, Al-Bloushi M, Haider MZ. Avascular Necrosis of the Hip in Children with Sickle Cell Disease and High Hb F: Magnetic Resonance Imaging Findings and Influence of --Thalassemia Trait. *Acta Haematol* 2001;105:27–31.
2. Aguilar CM, Neumayr LD, Eggleston BE, Earles AN, Robertson SM, Jergesen HE, et al. Clinical Evaluation of Avascular Necrosis in Patients With Sickle Cell Disease: Children's Hospital Oakland Hip Evaluation Scale—A

- Modification of the Harris Hip Score. *Arch Phys Med Rehabil* 2005;86:1369-1375.
3. Riccio AI, Wilson PL, Wimberly RL. Lower Extremity Injuries. In: Herring JA, ed. *Tachdjian's Pediatric Orthopaedics*. 5th ed. Philadelphia, PA: Elsevier Saunders, 2014.
 4. Bradley CS, Perry DC, Wedge JH, Murnaghan ML, Kelley SP. Avascular necrosis following closed reduction for treatment of developmental dysplasia of the hip: a systematic review. *J Child Orthop* 2016;10:627-632.
 5. Ratliff AHC. Fractures of the Neck of the Femur in Children. *The Journal of Bone & Joint Surgery* 1962;44B:528-542.
 6. Agha RA, Fowler AJ, Saeta A, Barai I, Rajmohan S, Orgill DP, et al. The SCARE Statement: Consensus-based surgical case report guidelines. *Int J Surg* 2016;34:180-186.
 7. Delbet MP. Fractures du col de femur. *Bull Mem Soc Chir* 1907;35:387-389.
 8. Colonna PC. Fracture of the Neck of the Femur in Childhood. *Ann Surg* 1928;88:902-907.
 9. Shrader MW, Jacofsky DJ, Stans AA, Shaughnessy WJ, Haidukewych GJ. Femoral neck fractures in pediatric patients: 30 years experience at a level 1 trauma center. *Clin Orthop Relat Res* 2007;454:169-173.
 10. Dudkiewicz I, Covo A, Salai M, Israeli A, Amit Y, Chechik A. Total hip arthroplasty after avascular necrosis of the femoral head: does etiology affect the results? *Arch Orthop Trauma Surg* 2004;124:82-85.
 11. Larson AN, McIntosh AL, Trousdale RT, Lewallen DG. Avascular Necrosis Most Common Indication for Hip Arthroplasty in Patients With Slipped Capital Femoral Epiphysis. *J Pediatr Orthop* 2010;30:767-773.
 12. Herring JA. Slipped Capital Femoral Epiphysis. In: Herring JA, ed. *Tachdjian's Pediatric Orthopaedics*. 5th ed. Philadelphia, PA: Elsevier Saunders, 2014:630-665.
 13. Parsons SJ, Barton C, Banerjee R, Kiely NT. Slipped upper femoral epiphysis. *Current Orthopaedics* 2007;21:215-228.
 14. Kim HKW, Herring JA. Legg-Calvé-Perthes Disease. In: Herring JA, ed. *Tachdjian's Pediatric Orthopaedics*. 5th ed. Philadelphia, PA: Elsevier Saunders, 2014:580-629.
 15. Shrader MW. Total hip arthroplasty and hip resurfacing arthroplasty in the very young patient. *Orthop Clin North Am* 2012;43:359-367.
 16. Prieto HA, Kamath AF, Lewallen DG. Total Hip Replacement in the Young Patient. In: Joseph C. McCarthy PCN, Richard N. Villar, ed. *Hip Joint Restoration: Worldwide Advances in Arthroscopy, Arthroplasty, Osteotomy and Joint Preservation Surgery*. 1 ed: Springer-Verlag New York, 2017:777-785.
 17. Lehmann TG, Engesaeter IO, Laborie LB, Lie SA, Rosendahl K, Engesaeter LB. Total hip arthroplasty in young adults, with focus on Perthes' disease and slipped capital femoral epiphysis: follow-up of 540 subjects reported to the Norwegian Arthroplasty Register during 1987-2007. *Acta Orthop* 2012;83:159-164.



This work is licensed under a Creative Commons Attribution

Total hip arthroplasty performed in a 13-year-old Girl with avascular necrosis (AVN) of the left hip: A Case Report

ORIGINALITY REPORT

12%

SIMILARITY INDEX

5%

INTERNET SOURCES

10%

PUBLICATIONS

0%

STUDENT PAPERS

PRIMARY SOURCES

1	"Hip Joint Restoration", Springer Nature, 2017 Publication	2%
2	www.balimedicaljournal.org Internet Source	2%
3	"Osteonecrosis of the Femoral Head", Springer Nature, 2017 Publication	1%
4	"Osteonecrosis", Springer Nature America, Inc, 2014 Publication	1%
5	Youssef A. Sleiman, Ziad A. Hassoun, Haydar A. Nasser, Leila Abs, Mustafa Allouch. "A late unusual complication after an open cholecystectomy: Amputation neuroma of the CBD causing obstructive jaundice", International Journal of Surgery Case Reports, 2017 Publication	1%
6	Pediatric Orthopedics in Practice, 2015. Publication	1%

- | | | |
|----|-------------------------------------------------------------------------------------------------------------------------------------------------------------------------------------------------------------------------------------------------------------------------------------------------------------------------|-----|
| 7 | Norton, Brian, Ryan Mulligan, Jeremy Rush, Derek M. Kelly, William C. Warner, and Jeffrey R. Sawyer. "Proximal femoral fractures in children and adolescents : an update", Current Orthopaedic Practice, 2012.
Publication | 1% |
| 8 | John C. Clohisy. "Function and Fixation of Total Hip Arthroplasty in Patients 25 Years of Age or Younger", Clinical Orthopaedics and Related Research®, 07/29/2010
Publication | 1% |
| 9 | dokteraaron.blogspot.com
Internet Source | 1% |
| 10 | www.medsci.org
Internet Source | <1% |
| 11 | Jesús Palencia, Saud Alfayez, Firas Serro, Jamal Alqahtani, Hani Alharbi, Hamed Alhinai. "A case report of the management and the outcome of a complete epiphyseal separation and dislocation with left anterior column fracture of the acetabulum", International Journal of Surgery Case Reports, 2016
Publication | <1% |
| 12 | Tetsunaga, Tomoko, Hirofumi Akazawa, and Tomonori Tetsunaga. "Intra-articular loose body caused by avascular necrosis of the femoral | <1% |

head in children :", Journal of Pediatric Orthopaedics B, 2014.

Publication

13

www.globalsciencejournals.com

Internet Source

<1%

14

"The Adult Hip - Master Case Series and Techniques", Springer Nature, 2018

Publication

<1%

15

www.amirfolio.com

Internet Source

<1%

16

www.wjgnet.com

Internet Source

<1%

Exclude quotes On

Exclude matches Off

Exclude bibliography On

Total hip arthroplasty performed in a 13-year-old Girl with avascular necrosis (AVN) of the left hip: A Case Report

GRADEMARK REPORT

FINAL GRADE

/100

GENERAL COMMENTS

Instructor

PAGE 1

PAGE 2

PAGE 3

PAGE 4
