

Effect of hematopoietic stem cell on tumor necrosis factor- α expression, spiral artery remodeling and placental apoptosis in lead-exposed pregnant mice

by Hendy Hendarto

Submission date: 01-Mar-2019 11:06AM (UTC+0800)

Submission ID: 1085750438

File name: 9_Effect_of_hematopoietic_stem_cell_on_tumor_necrosi.pdf (560.02K)

Word count: 3999

Character count: 20494



doi: 10.12980/apjr.6.20170403

©2017 by the Asian Pacific Journal of Reproduction. All rights reserved.

Effect of hematopoietic stem cell on tumor necrosis factor- α expression, spiral artery remodeling and placental apoptosis in lead-exposed pregnant mice

Widjiati¹, Suryo Kuncorojakti¹, HENDY Hendarto², Viski Fitri Hendrawan³, Aulanni'am Aulanni'am³

¹Faculty of Veterinary Medicine, Universitas Airlangga, Surabaya, Indonesia

²Faculty of Medicine, Universitas Airlangga, Surabaya, Indonesia

³Faculty of Veterinary Medicine, Universitas Brawijaya, Malang, Indonesia

ARTICLE INFO

Article history:

Received 4 March 2017

Revision 10 June 2017

Accepted 12 June 2017

Available online 1 July 2017

Keywords:

Pregnancy

Hematopoietic stem cell

Spiral artery remodeling

Apoptosis

ABSTRACT

Objective: To evaluate the effectiveness of hematopoietic stem cell (HSC) on TNF- α expression, spiral artery remodeling, and placental apoptosis. **Methods:** The study used pregnant mice divided to five groups of treatment: Group 1, without treatment; Group 2, 1/12 LD₅₀ of lead and Aquadest; Group 3, 1/16 LD₅₀ of lead and Aquadest, Group 4, 1/12 LD₅₀ of lead and 1×10^7 HSC; and group 5, 1/16 LD₅₀ of lead and 1×10^7 HSC. Histopathology examination was performed to identify spiral artery remodeling. Immunohistochemistry analysis was conducted to characterize TNF- α expression and the apoptosis index. The data from all five groups were compared using the ANOVA test. **Results:** TNF- α expression differed significantly among the groups that were not exposed to lead, exposed to lead and exposed to lead after HSC treatment ($P < 0.01$). There was also a significant difference of spiral artery remodeling between groups without lead-exposed, lead exposed and lead exposed followed HSC treatment ($P < 0.05$). In apoptosis index evaluation there was a significant difference between groups without lead-exposed, lead exposed and lead exposed followed HSC treatment, but not in the groups of 1/16 LD₅₀ of lead followed HSC ($P > 0.05$). **Conclusions:** In lead-exposed pregnant mice, the administration of hematopoietic stem cell may decrease TNF- α expression, spiral artery remodeling, and placental apoptosis index but in the group of 1/16 LD₅₀ of lead and HSC treatment, apoptosis index has no differences with those of control group.

1. Introduction

Lead, plumbum (Pb), one of the smoke's particle which causes various adverse effects as pollutant on human health through inhalation, also results in nucleus damage and cell apoptosis by its accumulation effect[1]. Pb toxicity can attack humans on various ages, however, young people, pregnant women, and workers in certain industries have a higher risk than other groups. Lead as pollutant source has negative effect on pregnancy by entering

placenta and plays a role in inflammation problem, spiral artery remodeling, and placental apoptosis. However, lead disturbs embryo cleavage and implantation as well[2–4].

Hematopoietic stem cell (HSC) is multipotent cell isolated from blood and bone marrow which can differentiate become variant of

This is an open access article distributed under the terms of the Creative Commons Attribution-Non Commercial-Share Alike 3.0 License, which allows others to remix, tweak and build upon the work non-commercially, as long as the author is credited and the new creations are licensed under the identical terms.

For reprints contact: reprints@medknow.com

©2017 Asian Pacific Journal of Reproduction Produced by Wolters Kluwer- Medknow

How to cite this article: Widjiati, Suryo Kuncorojakti, HENDY Hendarto, Viski Fitri Hendrawan, Aulanni'am Aulanni'am. Effect of hematopoietic stem cell on tumor necrosis factor- α expression, spiral artery remodeling and placental apoptosis in lead-exposed pregnant mice. Asian Pac J Reprod 2017; 6(4): 158-163.

[✉]Corresponding author: Widjiati, Faculty of Veterinary Medicine, Universitas Airlangga, Surabaya, Indonesia
E-mail: widjiati1962@gmail.com

the cell. Nowadays the utilization of hematopoietic stem cell for therapy is widely used. It is used for treatment due to its ability to express gene or certain cells in the body[5,6].

In the present study, a pregnant mice model was established to determine the effect of lead and hematopoietic stem cell treatment. The objectives of the study were to evaluate the effectiveness of hematopoietic stem cell on TNF- α expression, spiral artery remodeling and placental apoptosis of Pb-exposed pregnant mice.

2. Materials and methods

This study was an experimental laboratory study using 35 pregnant mice with complete random sampling design. Female mice (*Mus musculus*) were injected using pregnant mare serum gonadotropin (PMSG) (Foligon) with the dose of 5 IU and human chorionic gonadotropin (hCG) (Chorulon) 48 h after PMSG. After injection, they were monogamously mated to fertile male mice, and the examination of vaginal plugged was carried out 17 h after mated. Pregnancy age and vaginal plugged were counted from day 0 of pregnancy.

2.1. Lead and hematopoietic stem cell treatment

Thirty-five pregnant mice were divided into five groups. Group 1: without treatment. Group 2: lead with a dose of 1/12 50% lethal dose (LD₅₀) was injected from day 9 to day 15 and aquadest orally was given on day 16. Group 3: lead with a dose of 1/16 LD₅₀ was injected from day 9 to 15 and aquadest orally was given on day 16. Group 4: lead with a dose of 1/12 LD₅₀ was injected from day 9 to 15 and 1 × 10⁷ hematopoietic stem cell was given on day 9 intravenous. Group 5: lead with a dose of 1/16 LD₅₀ was injected from day 9 to 15 and 1 × 10⁷ hematopoietic stem cell was given on day 9 intravenous.

2.2. Hematopoietic stem cell method

Intracardiac blood of female mice was taken and its peripheral blood mononuclear cells (PBMCs) was filled-in 15 mL tubes, followed by adding sterile phosphate buffer saline (PBS). A 0.177 density of isopaque ficol was prepared and poured on the tube containing the PBMCs and PBS, centrifuged at the temperature of 20 °C for 5 min with 1 600 r/min speed. Mononuclear cells were taken into 15 mL tube and sterile medium was added for centrifuging process. The supernatant was taken out, then slowly resuspended the pellet using growing medium without damaging the cell membrane. After that, the suspension was taken and entered into 10 mL sterile disposable Petri dish and evaluated under an inverted microscope for cell quantification. Furthermore, the cells obtained, incubated to develop into a monolayer and these cells will be injected in the animal model of lead intoxication. Before the injection, the cells were checked and labeled by CD 45 and CD 105 marker (Figure 1).

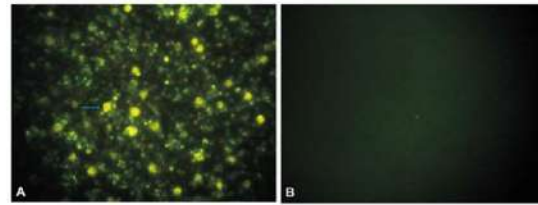


Figure 1. Characterisation of hematopoietic stem cell.

The HSC labelled by CD 45 marker as a positive control (A) and CD 105 marker as a negative control (B). The arrow showed the cells labelled by CD 45 marker.

2.3. Removal of placenta and uterus organs

The mice were decapitated on pregnancy day 17. The placenta and uterus microslices were prepared, and placenta sample was taken for TNF- α expression and apoptosis index examinations, then uterine sample was taken for spiral arteries remodeling evaluation.

2.4. Examination of tumor necrosis factor (TNF)- α expression

Placenta microslices made on the object glasses were dipped in xylol, alcohol and distilled water respectively. Then they were washed 3 times for 5 min each in PBS at pH 7.4. After that they were soaked in hydrogen peroxide (H₂O₂) 3% for 5-10 min, immersed in 1% BSA in PBS for 10-30 min at room temperature, followed by adding TNF- α antibody for 1 hour at room temperature. Then they were washed in PBS with pH 7.4 for 3 min × 5 min, added with SA-HRP (Strep Avidin-Horse Radish Peroxidase) for 30-60 min at room temperature, washed in PBS with pH 7.4 for 3 min × 5 min, added with Cromogen DAB (3,3-diaminbenzidine tetrahydrochloride) for 10-20 min, washed in distilled water for 3 min × 5 min at room temperature, then added with methyl green counterstain for 3 min. The examination was performed using a microscope at a magnification of 40, 100 and 400 times. TNF- α expression in placenta was determined by observing brownish discoloration on syncytiotrophoblast cells compared to the control.

2.5. Histopathology examination to assess spiral artery remodeling

Uterus was fixed with 10% buffered formalin, then histopathologically processed by dehydration, rehydration, embedding and uterine tissue cutting. Staining process was performed using hematoxylin-eosin. The microslices were evaluated under 400 times of microscope magnification.

2.6. Examination of apoptosis index

Stages TACS 2 TdT-DAB in situ Apoptosis Detection kit. Microslides were deparaffinized in xylol and alcohol series. Put PBS on the slide for 10 min, absorbed the liquid with a tissue. Covered the sample with 50 dsf mL proteinase K for 15-30 min, washed twice with deionized water (dH₂O) each for 2 min. Put drops on the samples with sequencing solution for 5 min, washed the slides by using PBS for 1 min. Put drops of TdT labeling buffer to the samples for 5 min, covered the sample with 50 mL of labeling reaction mix for 2 reactions: TdT dNTP Mix (Cat # 4828-30-04) 2 mL, TdT Enzyme (Cat # 4810-30-05) 2 mL, 50 × Cation Stock 2 mL, 1 × TdT labeling Buffer 100 mL, incubated for 60 min at 37 °C in a humid place. Washed slides with 1xTdT stop buffer for 5 min, washed slides every 5 min with dH₂O. Put drops on sample with 50 mL srep-HRP solution and incubated for 10 min at 37 °C in a humid place to prevent evaporation. Washed slides with PBS twice each for 2 min. Dropped with DAB solution for 2-7 min, washed slides with dH₂O each 2 min. Put drops of 1% methyl green on the slides for 30 s to 5 min, soaked and washed slides 10 times with dH₂O. Dried the microslides overnight and covered with entelan.

2.7. Assessing index apoptosis and expression TNF-α

Histopathological examination is intended to determine the index apoptosis and expression of TNF-α in the placenta. Data of each sample assessed semiquantitatively according to the modified method Remmele[7], where the index scale Remmele immuno reactive score (IRS) is the result of multiplying the cells percentage scores immunoreactive with the color intensity scores immunoreactive cells (Table 1). Data of each sample is the average value of IRS are observed in different 10 Field of view at 400 × magnification.

Table 1

Semiquantitative scale of IRS.

A	B
Score 0: No positive cells	Score 0: No reaction color
Score 1: Positive Cells less than 10%	Score 1: The color intensity mild
Score 2: Positive cells between from 11% - 50%	Score 2: The color intensity moderate
Score 3: Positive cells between from 51% - 80%	Score 3: The color intensity Strong
Score 4: Positive cells between from more than 80%	-

Positive cells (A) intensity of tubes Score color reaction (B), so the IRS=(A × B).

2.8. Data analysis

The data about the expression of TNF-α, the number of spiral artery remodeling and apoptosis index were analyzed using statistical SPSS program for windows. All five group data were compared using the ANOVA test. The differences were considered to be statistically significant if P<0.05.

3. Results

3.1. TNF-α expression

Immunohistochemistry examination of TNF-α expression was showed by the colors of light to dark brown in immunoreactive cells (Figure 2). There were significant differences between five groups above (P=0.00) (Figure 3).

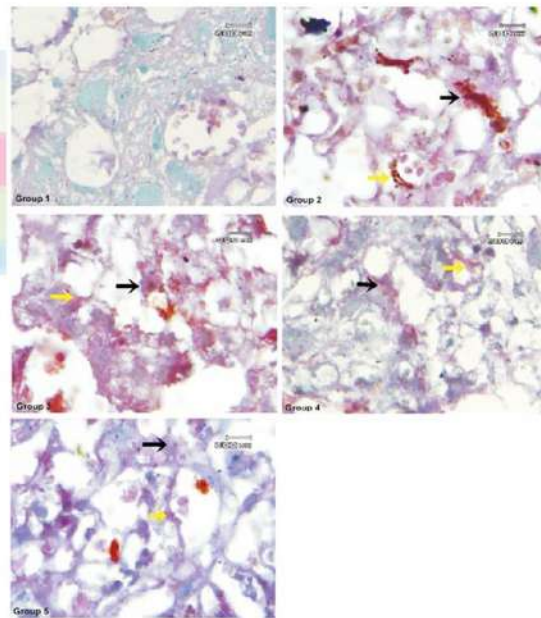


Figure 2. TNF-α expression shown by the colors of light to dark brown in immunoreactive cells.

Group 1 did not show the presence of immunoreactive cells. Group 2 group showed high intensity dark brown color of TNF-α immunoreactive cells than Group 3 on cytotrophoblast (black arrow) and endothel cells (yellow arrow). Group 4 and Group 5 showed TNF-α immunoreactive cells less than Group 2 and Group 3.

Coloring immunohistochemistry; magnification 1 000×; Olympus BX-50. Pentax optio 230; Digital Camera of 2.0 megapixel.

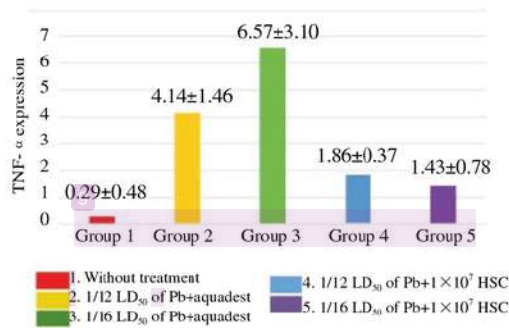


Figure 3. TNF-α expressions of pregnant mice group without treatment, with Pb treatment and Pb + hematopoietic stem cell treatment.

Thus TNF-α expression in normal pregnant mice without treatment, lead-exposed mice and mice exposed to lead after intravenous 1×10^7 HSC treatment were significantly different. By using Mann-Whitney test the difference of each groups were analyzed. There was no statistical difference of TNF-α expression between pregnant mice with of 1/12 LD₅₀ of lead exposed and those with 1/16 LD₅₀ of lead exposed, but significant difference was found between lead exposed treatment with and without 1×10^7 HSC treatment. There was no difference in TNF-α expression between pregnant mice with 1/12 LD₅₀ of lead followed 1×10^7 HSC and those with 1/16 LD₅₀ of lead exposed followed 1×10^7 HSC ($P=0.227$).

3.2. Spiral artery remodeling

Hematoxylin-eosin staining of spiral artery remodeling showed the difference of vascular response in the uterus (Figure 4).

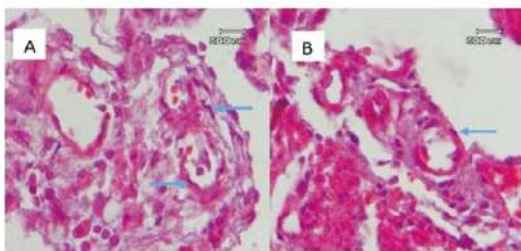


Figure 4. The difference of vascular response in uterus. Slide A showed gradual blood stream vasoconstriction (arrow) and slide B showed normal vasodilatation (arrow). Coloring haematoxylin eosin; magnification 1 000 ×; Olympus CX41; DP12 olympus micro digital camera 2 megapixel.

Spiral artery remodeling was analyzed by assessing the contraction status of blood vessel in endometrium and myometrium of pregnant mice uterine. There was a significant difference in the five groups above ($P=0.00$). It meant that spiral artery remodeling of normal pregnant mice group without treatment, lead exposed treatment and lead-exposed followed 1×10^7 HSC intravenous were significantly different (Figure 5).

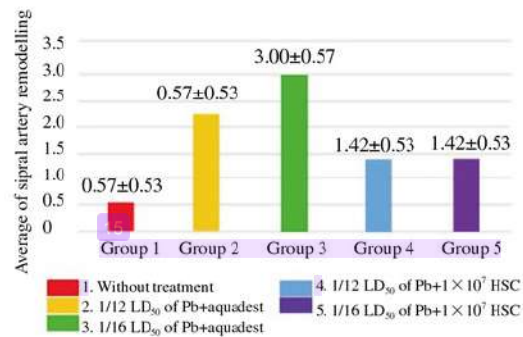


Figure 5. Spiral artery remodeling of pregnant mice group without treatment, with Pb treatment and Pb + hematopoietic stem cell treatment.

The difference between each group was analyzed using Mann-Whitney test. There was a significant difference of spiral artery remodeling between Group 2 (1/12 LD₅₀ of lead and Aquadest) and Group 3 (1/16 LD₅₀ of lead and Aquadest). There was also a significant difference of spiral artery remodeling between Group 2 and Group 4 (1/12 LD₅₀ of lead followed 1×10^7 HSC treatment) and Group 5 (1/16 LD₅₀ of lead followed 1×10^7 HSC treatment), but no difference was found between Group 4 and Group 5.

3.3. Apoptosis index

The immunohistochemistry examination of apoptosis involved light to dark brown staining of immunoreactive cells (Figure 6). There was a significant difference among the five groups above ($P=0.00$). It is meant that apoptosis index of normal pregnant mice group without treatment, lead-exposed treatment and lead-exposed followed 1×10^7 HSC intravenous were significantly different (Figure 7).

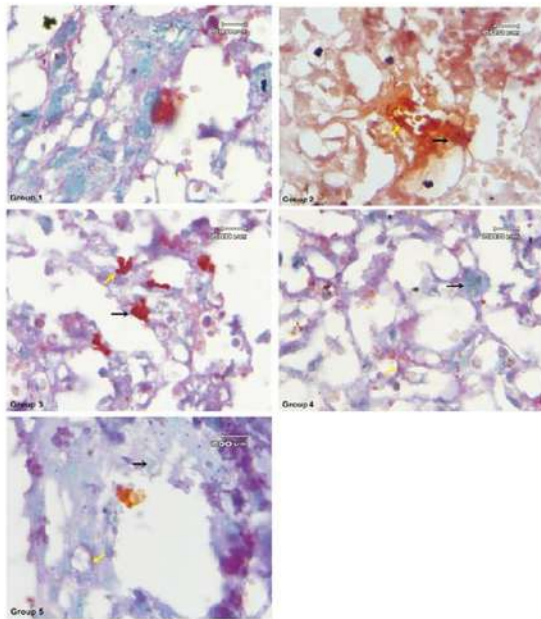


Figure 6. Apoptotic index was shown by colors of light brown to dark brown in immunoreactive cells.

Group 1 did not show the presence apoptotic cells in cytotrophoblast. Group 2 showed high intensity of dark Brown in apoptotic cells than Group 3, expressed in cytotrophoblast (black arrow) and endothelial cells (yellow arrow). Group 4 and group 5 showed apoptotic cells less than Group 2 and Group 3.

Coloring immunohistochemistry; magnification 1 000 ×; Olympus BX-50. Pentax optio 230; Digital Camera of 2.0.

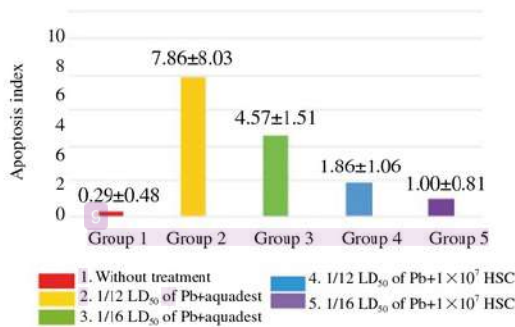


Figure 7. Apoptosis index of pregnant mice group without treatment, with Pb treatment and Pb + Hematopoietic stem cell treatment.

Differences among groups were assessed using the Mann-Whitney

test. The apoptosis index of pregnant mice group without lead-exposed treatment (Group 1) was significantly different between those groups with lead-exposed (Group 2 and 3) and HSC (Group 4), but no difference was found in Group 5. There was significant difference of apoptosis index between group of lead-exposed treatment (Group 2 and 3), and lead-exposed followed HSC treatment (Group 4 and 5) but no difference was found between Group 4 and 5 (Table 2).

Table 2

The significant comparison of apoptosis index in five groups.

Groups	Group 1	Group 2	Group 3	Group 4	Group 5
Group 1	-	0.001*	0.001*	0.004*	0.080
Group 2	-	-	0.013*	0.002*	0.001*
Group 3	-	-	-	0.007*	0.002*
Group 4	-	-	-	-	0.133
Group 5	-	-	-	-	-

Pregnant mice without treatment (Group 1), Pb treatment (Group 2 and 3) and Pb + Hematopoietic stem cell treatment (Group 4 and 5) (Mann-Whitney test). *P<0.05.

4. Discussion

Characterization was done to confirm the HSC growth by labeled with CD45 antibody. The HSC stained by FITC and CD 45 antibody and observed under fluorescent microscope. Our result showed that the cells labeled by CD 45 antibody have a light green color, so we can conclude that our culture is truly HSC. As a comparison the HSC also was labeled by CD 105 antibody as a negative control, after observed under fluorescent microscope our result showed no positive reaction. CD 105 is a specific marker to identify the mesenchymal stem cell.

Lead is a deleterious environmental pollutant and causes a range of physiological and biochemical dysfunctions. Repeated exposure of lead during organogenesis can cause teratogenicity, embryotoxicity, and abortion[8]. The amount of lead entering body will activate nuclear factor kappa beta and mitogen-protein kinase; both can change the function of mitochondria and increase cytokine proinflammation such as TNF-α [9]. Lead penetrating placenta and entering cells will lead to the formation of reactive oxygen species (ROS). ROS formed in trophoblast cells will cause mitochondrial damage, therefore it causes loose of cytochrome caught by apaf-1, then it will activate caspase-3 as the executor of apoptosis[10]. In this study TNF-α expression, spiral artery remodeling and apoptosis index in lead-exposed treatment group (Group 2 and 3) are higher than control group without treatment (Group 1). It is meant that

exposure of lead may cause negative effect on placenta and uterine of pregnant mice.

The administration of HSC intravenously through the coccygealis vein allowed cells to home to damaged placental tissues. Hematopoietic stem cell entering placental cells, proliferated and differentiated in order to change the damaged placental tissue because HSC was multipotent and can differentiate to all cell types including the formation of placenta and umbilical cords. The ability of stem cell for self-renewal enables it to replicate and form cells which have same characteristic with the parent cell, therefore, stem cell administration as therapy is aimed to replace damaged cells [11].

Hematopoietic stem cell therapy decreased trophoblast cells experiencing apoptosis and regenerate damaged trophoblast cells due to lead administration. In this study TNF- α expression, spiral artery remodeling and apoptosis index in group of lead-exposed followed HSC treatment (Group 4 and 5) is lower than those without HSC treatment. It is meant that HSC treatment has positive effect on placenta and uterine of pregnant mice.

HSC administration decreased the expression of TNF- α which is a factor initiating apoptosis, therefore, apoptosis index was also decrease. The decrease of TNF- α expression alleviated inflammation process, therefore it may decrease vasoconstriction of blood vessel in spiral artery as an explanation of the presence of spiral artery remodeling, and may suppressed uterus contraction as well.

Hematopoietic stem cells require time for homing in order to differentiate and regenerate damaged cells. In this study nine days administration of HSC was enough for homing which was seen by the decrease of TNF- α expression, spiral artery remodeling, and apoptosis index.

The conclusion of this study is in lead-exposed pregnant mice, the administration of hematopoietic stem cell may decrease TNF- α expression, spiral artery remodeling, and placenta apoptosis but in the group of 1/16 LD₅₀ of lead-exposed followed HSC treatment, apoptosis index is similar with those of control group.

In the first group of pregnant mice were exposed to a lead dose 1/12 LD₅₀ and 1/16 LD₅₀ occur early embryonic death characterized by reabsorption embryos compared with the group receiving therapy HSC. Congenital defects do not occur in all four treatment groups and control. Weight and length of the fetus in the group exposed to lead without giving HSC lower than the group exposed to lead and given HSC therapy.

Conflict of interest statement

The authors declare that they have no competing interest.

Acknowledgments

We would like to thank to Universitas Airlangga for funding the research by RKAT 2014 Grant.

References

- [1] Shariifi AM, Mousavi SH, Jorjani M. Effect of chronic lead exposure on pro-apoptotic Bax and anti-apoptotic Bcl-2 protein expression in rat hippocampus *in vivo*. *Cell Mol Neurobiol* 2010; **30**(5): 769-774. doi: 10.1007/s10571-010-9504-1.
- [2] Neeti K, Prakash T. Effects of heavy metal poisoning during pregnancy. *Int Res J Environ Sci* 2013; **2**(1): 88-92.
- [3] Gundacker C, Hengstschlager M. The role of the placenta in fetal exposure to heavy metals. *Wien Med Wochenschr* 2012; **162**(9-10): 201-206. doi: 10.1007/s10354-012-0074-3.
- [4] Mohsen V, Hiroyuki S, Shin-ichi S. Lead exposure in female workers who are pregnant or of childbearing age. *Indust Health* 2011; **49**: 255-261.
- [5] Jamur MC, Grodzki ACG, Moreno AN, de Mello LFC, Pastor MVD, Berenstein EH, et al. Identification and isolation of rat bone marrow-derived mast cells using the mast cell-specific monoclonal antibody AA4. *J Histochem Cytochem* 2001; **49**(2): 219-228.
- [6] Wognum AW, Szilvassy SJ. Hematopoietic stem and progenitor cells. *Stem Cell Technol* 2013. [Online] Available from: <https://www.stemcell.com/hematopoietic-stem-and-progenitor-cells-lp.html>.
- [7] Remmele W, Stegner HE. Recommendation for uniform definition of an immunoreactive score (IRS) for immunohistochemical estrogen receptor detection (ER-ICA) in breast cancer tissue. *Pathol* 1987; **8**: 138-140.
- [8] Aisha MF, Samya ES, Koratem KH. Effect of dietary calcium on maternal and fetal lead toxicity and teratogenicity in rats Egypt. *J Comp Path Clin Path* 2008; **21**(4): 283-305.
- [9] Kim JJ, Lee SB, Park JK, Yoo YD. TNF α -induced ROS production triggering apoptosis is directly linked to room 1 and Bcl-XL. *J Nat Cell Death and Diff* 2010; **17**: 1420-1434. doi: 10.1038/cdd.2010.19.
- [10] Wani MY, Hashim MA, Nabi F, Malik MA. Nanotoxicity: Dimensional and morphological concern. *Adv Phy Chem* 2011; **8**: 1-15. doi: 10.1155/2011/450912.
- [11] Halim D, Murti H, Sandra F, Boediono A, Djuwantono T, Setiawan B. *Stem cell: Theory basic and clinical application. Edisi ke-1*. Jakarta: Erlangga Press; 2010.

Effect of hematopoietic stem cell on tumor necrosis factor- α expression, spiral artery remodeling and laceral apoptosis in lead-exposed pregnant mice

ORIGINALITY REPORT

25%

SIMILARITY INDEX

21%

INTERNET SOURCES

11%

PUBLICATIONS

0%

STUDENT PAPERS

PRIMARY SOURCES

1

impactfactor.org

Internet Source

5%

2

Heti Ira Ayue. "Effect of bovine pellucid zone 3 monoclonal antibodies on B cell lymphoma 2 expressions of granulosa cell and mice (*Mus musculus*) follicle diameter", *Asian Pacific Journal of Reproduction*, 2017

Publication

4%

3

www.apjr.net

Internet Source

2%

4

www.apjtm.org

Internet Source

2%

5

Dian Aby Restanty, Setyawati Soeharto, I Wayan Agung Indrawan. "The effect of oral lead acetate exposure on bax expression and apoptosis index granulosa cells antral follicle in female wistar rat (*Rattus norvegicus*)", *Asian Pacific Journal of Reproduction*, 2017

2%

6	media.neliti.com Internet Source	1%
7	www.omicsonline.org Internet Source	1%
8	Dwikora N. Utomo, Ferdiansyah Mahyudin, Kukuh D. Hernugrahanto, Heri Suroto, Muhammad Zaim Chilmi, Fedik Abdul Rantam. "Implantation of platelet rich fibrin and allogenic mesenchymal stem cells facilitate the healing of muscle injury: An experimental study on animal", International Journal of Surgery Open, 2018 Publication	1%
9	www.fws.gov Internet Source	1%
10	ppjpi.unair.ac.id Internet Source	1%
11	aoki2.si.gunma-u.ac.jp Internet Source	1%
12	www.rjpbcs.com Internet Source	<1%
13	www.clevelandclinic.org Internet Source	<1%

Shu-yun Liu, Qin Huang, Xue Gu, Bin Zhang,

14

Wei Shen, Ping Tian, Yun Zeng, Ling-zhi Qin, Lin-xiang Ye, Ze-min Ni, Qi Wang. "Association of Bone Turnover Levels with MTHFR Gene Polymorphisms among Pregnant Women in Wuhan, China", Current Medical Science, 2018

Publication

<1%

15

citeseerx.ist.psu.edu

Internet Source

<1%

16

neuroscience.mahidol.ac.th

Internet Source

<1%

17

www.jove.com

Internet Source

<1%

18

ir.nul.nagoya-u.ac.jp

Internet Source

<1%

19

www.irog.net

Internet Source

<1%

20

docs.di.fc.ul.pt

Internet Source

<1%

21

www.hnykdxxb.com

Internet Source

<1%

22

www.trevigen.com

Internet Source

<1%

23

silvafennica.fi

Internet Source

<1%

24	www.ajol.info Internet Source	<1%
25	www.advms.pl Internet Source	<1%
26	Alexander Patera Nugraha, Ida Bagus Narmada, Diah Savitri Ernawati, Aristika Dinaryanti et al. "Osteogenic potential of gingival stromal progenitor cells cultured in platelet rich fibrin is predicted by core-binding factor subunit- α 1/Sox9 expression ratio (in vitro)", F1000Research, 2018 Publication	<1%
27	www.spandidos-publications.com Internet Source	<1%
28	eeer.org Internet Source	<1%
29	"OS04: Lung Cancer 2 : Oral Sessions", Respirology, 2013. Publication	<1%
30	Zhang, Shenwei, Yilin Zhao, Ming Xu, Li Yu, Yujie Zhao, Jianghong Chen, Yiqiang Yuan, Qiangsun Zheng, and Xiaolin Niu. "FoxO3a Modulates Hypoxia Stress Induced Oxidative Stress and Apoptosis in Cardiac Microvascular Endothelial Cells", PLoS ONE, 2013. Publication	<1%

31

Korkmaz-Icöz, Sevil, Samer Al Said, Tamás Radovits, Shiliang Li, Maik Brune, Péter Hegedűs, Ayhan Atmanli, Mihály Ruppert, Paige Brlecic, Lorenz Heyne Lehmann, Bernd Lahrmann, Niels Grabe, Yutaka Yoshikawa, Hiroyuki Yasui, Patrick Most, Matthias Karck, and Gábor Szabó. "Oral treatment with a zinc complex of acetylsalicylic acid prevents diabetic cardiomyopathy in a rat model of type-2 diabetes: activation of the Akt pathway", *Cardiovascular Diabetology*, 2016.

<1%

Publication

Exclude quotes On

Exclude matches Off

Exclude bibliography On

Effect of hematopoietic stem cell on tumor necrosis factor- α expression, spiral artery remodeling and lacental apoptosis in lead-exposed pregnant mice

GRADEMARK REPORT

FINAL GRADE

/100

GENERAL COMMENTS

Instructor

PAGE 1

PAGE 2

PAGE 3

PAGE 4

PAGE 5

PAGE 6
