
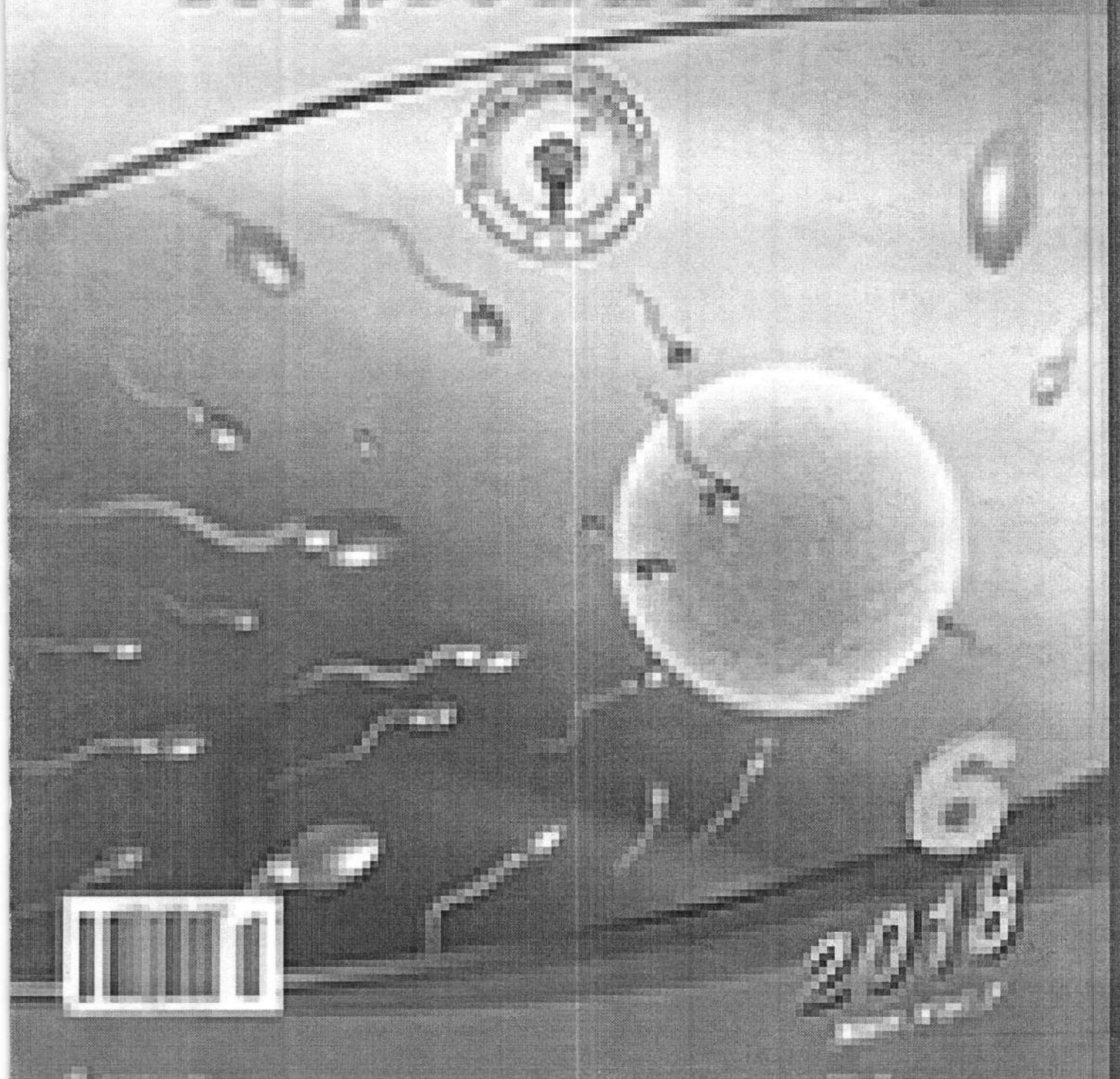


ISSN 1442-2007

Volume 45 Number 6
December 2019
Pages 1-100

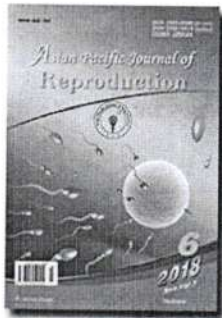
Asian Pacific Journal of Reproduction



6
2019



Table of Contents



July 2017

Volume 6 | Issue 4

Page Nos. 145-192

Online since Tuesday, September 26, 2017

Accessed 8,501 times.

PDF access policy

Journal allows immediate open access to content in HTML + PDF

View issue as eBook

Issue statistics

RSS

[Next Issue](#)

[Previous Issue](#)

[SUBMIT ARTICLE](#)

[POPULAR ARTICLES](#)

[JOIN AS REVIEWER](#)

[GET EMAIL ALERTS](#)

[RECOMMEND](#)

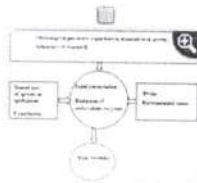
[Show all abstracts](#)

[Show selected abstracts](#)

[Export selected to ▾](#)

[Add to my list](#)

REVIEW



Effects of dietary vitamin E on male reproductive system POPULAR


p. 145

Muhammad Zubair

DOI:10.12980/apjr.6.20170401

[ABSTRACT] [HTML Full text] [PDF] [Mobile Full text] [EPub] [Sword Plugin for Repository]^{Beta}

ORIGINAL ARTICLE




Morphological and functional alterations of female reproduction after regular exposure of bamboo shoots of North East India

p. 151

Deotima Sarkar, Arijit Chakraborty, Dakshayani Mahapatra, Amar K Chandra

DOI:10.12980/apjr.6.20170402

[ABSTRACT] [HTML Full text] [PDF] [Mobile Full text] [EPub] [Sword Plugin for Repository]^{Beta}



Effect of hematopoietic stem cell on tumor necrosis factor- α expression, spiral artery remodeling and placental apoptosis in lead-exposed pregnant mice

p. 158

Widjiati, Suryo Kuncorojakti, Hendy Hendarto, Viski Fitri Hendrawan, Aulanni'am Aulanni'am

DOI:10.12980/apjr.6.20170403

[ABSTRACT] [HTML Full text] [PDF] [Mobile Full text] [EPub] [Sword Plugin for Repository]^{Beta}



Effects of long-term exposure to radiofrequency radiations emitted by mobile Jammers on reproduction parameters in rats

p. 164

Maryam Owjifard, Manzarbanoo Shojaei Fard

DOI:10.12980/apjr.6.20170404

[ABSTRACT] [HTML Full text] [PDF] [Mobile Full text] [EPub] [Sword Plugin for Repository]^{Beta}



Relationship between pre-pubertal nutrition plane with reproduction performance and milk quality in Kurdish female kids

p. 172

Sedigheh Menatian, Mostafa Nemati, Mehdi Rashnavadi, Ali Salimi, Mohammad Rashid Taheri, Farshad Yasemi

DOI:10.12980/apjr.6.20170405

[ABSTRACT] [HTML Full text] [PDF] [Mobile Full text] [EPub] [Sword Plugin for Repository]^{Beta}



Effect of melatonin and/or cysteamine on development and vitrification of buffalo embryos

p. 176

Mohamed MM El-Sokary, Mohamed El-Raey, Karima GhM Mahmoud, Mahmoud EA Abou El-Roos, Gamal MS Sosa


DOI:10.12980/apjr.6.20170406

[ABSTRACT] [HTML Full text] [PDF] [Mobile Full text] [EPub] [Sword Plugin for Repository]^{Beta}



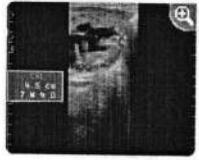Comparison of serum reproductive hormones, antioxidants, PGE2 and PGF2- α between primary and secondary infertile women in Calabar

p. 181



Idongesit K Isong, Chinyere AO Usoro, Zibril A Okhormhe, Dorothy C Okpokam, Christopher EJ Udiong
 DOI:10.12980/apjr.6.20170407

[ABSTRACT] [HTML Full text] [PDF] [Mobile Full text] [EPub] [Sword Plugin for Repository]^{Beta}

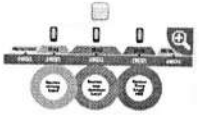


Establishment of fetal age equations based on ultrasound measurements in cross-bred Holstein cows p. 186

Kanoknan Somnuk, Pim Wannapakorn, Waraporn Raksapol, Bunlue Kommatitsuk, Sudsaijai Kommatitsuk
 DOI:10.12980/apjr.6.20170408

[ABSTRACT] [HTML Full text] [PDF] [Mobile Full text] [EPub] [Sword Plugin for Repository]^{Beta}

CASE REPORT



Male masturbation device for the treatment of delayed ejaculation: A case report p. 191

JE Rodriguez, JA Picazo, E Lopez
 DOI:10.12980/apjr.6.20170409

[ABSTRACT] [HTML Full text] [PDF] [Mobile Full text] [EPub] [Sword Plugin for Repository]^{Beta}



Editorial Board

Editor-in-Chief

Yuan-hua Huang

Professor

Hainan Provincial Reproduction Medical Center, Affiliated Hospital of Hainan Medical University, Haikou, China.

Executive Editor-In-Chief

Shunhai Qu

Professor

Hainan Medical University Journal Publisher, Hainan Medical University, Haikou, China.

Editorial Director

Viroj Wiwanitkit, MD.

Professor

Department of Laboratory Medicine, Faculty of Medicine, Chulalongkorn University, Bangkok, Thailand.

Members of Editorial Board

Puttaswamy Manjunath, Ph.D.

Professor

Department of Medicine, Faculty of Medicine, University of Montreal, Montreal, Canada.

Daniel G. Cyr

Professor

Canada Research Chair in Reproductive Toxicology, INRS-Institut Armand-Frappier, Université du Québec, Canada.

Gian Mario Tiboni

Associate Professor

Obstetrics and Gynecology, Department of Medicine and Aging Sciences University "G.d'Annunzio" Chieti Pescara, Italy.

Stefan du Plessis

Professor

Division of Medical Physiology, Department of Biomedical Sciences, Faculty of Medicine and Health Sciences, Stellenbosch University, Tygerberg, South Africa.

Gaffari Turk

Professor

Department of Reproduction and Artificial Insemination, Faculty of Veterinary Medicine, Firat University, Elazığ, Turkey.

Maria de Lourdes Gomes Pereira, Ph.D.

Professor

Department of Medical Sciences, University of Aveiro, Campus Santiago, 3810-193 Aveiro, Portugal.

Fangxiang Shi, Ph.D.

Professor

Department of Animal Reproduction and Breeding, College of Animal Science and Technology, Nanjing Agricultural University, Weigan 1, Nanjing, 210095 China.

Kristian Almstrup, Ph.D.

Senior Scientist

Department of Growth and Reproduction, Copenhagen University Hospital, Rigshospitalet, Section GR-5064, 9 Blegdamsvej, DK-2100 Copenhagen, Denmark.

Rafiqul Islam, Ph.D.

Principal Scientist

Animal Reproduction & Gynaecology, ICAR-National Organic Farming Research Institute, Tadong, Gangtok - 737102, Sikkim, India.

Pedro Alejandro Orihuela Diaz, Ph.D.

Associate Professor

Laboratory of Immunology of Reproduction, Faculty of Chemistry and Biology, University of Santiago, Chile.

Guilherme de Paula Nogueira, Ph.D.

Full Professor

Animal Physiology at the Department of Basic Science, Production and Animal Health (DAPSA), at the Aracatuba Veterinary Faculty (FMVA), linked to the Sao Paulo State University (UNESP), Brazil.

Luc J Martin, Ph.D.

Associate Professor

Department of Biology, Faculty of science, University of Moncton, 18, avenue Antonine Maillet, Moncton, (Nouveau-Brunswick), Canada E1A 3E9.

Luciana Bordin, Ph.D.

Department of Molecular Medicine-Biological Chemistry, University of Padova, Viale G. Colombo 3, 35131 Padua, Italy.

Hossein Mozdarani, Ph.D.

Professor

Department of Medical Genetics, Faculty of Medical Sciences, Tarbiat Modares University, Tehran, Iran.

Brent M. Bany, Ph.D.

Associate Professor

Department of Physiology, Southern Illinois University School of Medicine, Carbondale, Illinois, USA.

Asmaa Gaber Abdou

Professor

Pathology Department, Faculty of Medicine, Menoufiya University, Egypt.

Pasquale De Franciscis, Ph.D.

Professor

Department of Woman, Child and of General and Specialized Surgery Largo Madonna Delle Grazie 180138 Napoli, Italy.

Mostafa A. Borahay, Ph.D.

Associate Professor

Department of Gynecology and Obstetrics, Johns Hopkins School of Medicine, Johns Hopkins Bayview Medical Center, Baltimore, USA.

Jun-qing Wu, Ph.D.

Professor

Department of Epidemiology and Social Science on Reproduction of Shanghai Institute of Planned Parenthood Research, Shanghai, China;
Fudan University, Shanghai, China.**Kampon Kaeoket, Ph.D.**

Associate Professor

Department of Clinical Sciences and Public Health, Faculty of Veterinary Science, Mahidol University, Nakhon Pathom, Thailand.

Eric Chung

Professor

AndroUrology Centre for Sexual, Urinary and Reproductive Excellence; Department of Urology, Princess Alexandra Hospital, Brisbane, Australia.

Jens Fedder, Ph.D.

Professor

Centre of Andrology & Fertility Clinic, Dept. D, Odense University Hospital, Odense, Denmark.

Da-jin Li, Ph.D

Professor

Lab for Reproductive Immunology, Institute of Obstetrics & Gynecology, Fudan University Shanghai Medical College, Shanghai, China.

Liselotte Mettler

Professor

Department of Obstetrics and Gynecology, University Clinics of Schleswig-Holstein, Kiel, Germany.

Sae Chul Kim, Ph.D.

Professor

Director General, Myongji Medical Center, Goyang, Gyeonggi-do, Korea;

Emeritus Professor, Department of Urology College of Medicine, Chung-Ang University, Seoul, Korea;

Chairman, Korean Prostate Health Council;

Life member, Korean Academy of Science and Technology, National Academy of Medicine of Korea.

Juan F. Aller, Ph.D.

Researcher

National Institute of Agricultural Technology, Experimental Station of Balcarce, Department of Animal Production, Animal Reproductive Biotechnology, Buenos Aires Province, Argentina.

Giulia Ricci, Ph.D.

Aggregate Professor

Department of Experimental Medicine, Università della Campania "Luigi Vanvitelli", Via Luigi de Crecchio 7, 80138- Naples, Italy.

Premendu Prakash Mathur, Ph.D.

Professor

Department of Biochemistry & Molecular Biology, School of Life Sciences, Pondicherry University, Pondicherry-605014, India.

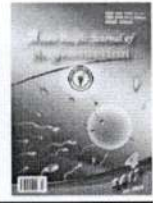Marcel Leppée, Ph.D.

Senior Researcher

Institute for Healthy Ageing, Zagreb, Croatia.

Asian Pacific Journal of Reproduction

Journal homepage: www.apjr.net



doi: 10.12980/apjr.6.20170403

©2017 by the Asian Pacific Journal of Reproduction. All rights reserved.

Effect of hematopoietic stem cell on tumor necrosis factor- α expression, spiral artery remodeling and placental apoptosis in lead-exposed pregnant mice

Widjiati¹✉, Suryo Kuncorojakti¹, Hendy Hendarto², Viski Fitri Hendrawan³, Aulanni'am Aulanni'am³

¹Faculty of Veterinary Medicine, Universitas Airlangga, Surabaya, Indonesia

²Faculty of Medicine, Universitas Airlangga, Surabaya, Indonesia

³Faculty of Veterinary Medicine, Universitas Brawijaya, Malang, Indonesia

ARTICLE INFO

Article history:

Received 4 March 2017

Revision 10 June 2017

Accepted 12 June 2017

Available online 1 July 2017

Keywords:

Pregnancy

Hematopoietic stem cell

Spiral artery remodeling

Apoptosis

ABSTRACT

Objective: To evaluate the effectiveness of hematopoietic stem cell (HSC) on TNF- α expression, spiral artery remodeling, and placental apoptosis. **Methods:** The study used pregnant mice divided to five groups of treatment: Group 1, without treatment; Group 2, 1/12 LD₅₀ of lead and Aquadest; Group 3, 1/16 LD₅₀ of lead and Aquadest, Group 4, 1/12 LD₅₀ of lead and 1×10^7 HSC; and group 5, 1/16 LD₅₀ of lead and 1×10^7 HSC. Histopathology examination was performed to identify spiral artery remodeling. Immunohistochemistry analysis was conducted to characterize TNF- α expression and the apoptosis index. The data from all five groups were compared using the ANOVA test. **Results:** TNF- α expression differed significantly among the groups that were not exposed to lead, exposed to lead and exposed to lead after HSC treatment ($P < 0.01$). There was also a significant difference of spiral artery remodeling between groups without lead-exposed, lead exposed and lead exposed followed HSC treatment ($P < 0.05$). In apoptosis index evaluation there was a significant difference between groups without lead-exposed, lead exposed and lead exposed followed HSC treatment, but not in the groups of 1/16 LD₅₀ of lead followed HSC ($P > 0.05$). **Conclusions:** In lead-exposed pregnant mice, the administration of hematopoietic stem cell may decrease TNF- α expression, spiral artery remodeling, and placental apoptosis index but in the group of 1/16 LD₅₀ of lead and HSC treatment, apoptosis index has no differences with those of control group.

1. Introduction

Lead, plumbum (Pb), one of the smoke's particle which causes various adverse effects as pollutant on human health through inhalation, also results in nucleus damage and cell apoptosis by its accumulation effect[1]. Pb toxicity can attack humans on various ages, however, young people, pregnant women, and workers in certain industries have a higher risk than other groups. Lead as pollutant source has negative effect on pregnancy by entering

placenta and plays a role in inflammation problem, spiral artery remodeling, and placental apoptosis. However, lead disturbs embryo cleavage and implantation as well[2-4].

Hematopoietic stem cell (HSC) is multipotent cell isolated from blood and bone marrow which can differentiate become variant of

This is an open access article distributed under the terms of the Creative Commons Attribution-Non Commercial-Share Alike 3.0 License, which allows others to remix, tweak and build upon the work non-commercially, as long as the author is credited and the new creations are licensed under the identical terms.

For reprints contact: reprints@medknow.com

©2017 Asian Pacific Journal of Reproduction Produced by Wolters Kluwer- Medknow

How to cite this article: Widjiati, Suryo Kuncorojakti, Hendy Hendarto, Viski Fitri Hendrawan, Aulanni'am Aulanni'am. Effect of hematopoietic stem cell on tumor necrosis factor- α expression, spiral artery remodeling and placental apoptosis in lead-exposed pregnant mice. Asian Pac J Reprod 2017; 6(4): 158-163.

✉Corresponding author: Widjiati, Faculty of Veterinary Medicine, Universitas Airlangga, Surabaya, Indonesia
E-mail: widjiati1962@gmail.com

the cell. Nowadays the utilization of hematopoietic stem cell for therapy is widely used. It is used for treatment due to its ability to express gene or certain cells in the body[5,6].

In the present study, a pregnant mice model was established to determine the effect of lead and hematopoietic stem cell treatment. The objectives of the study were to evaluate the effectiveness of hematopoietic stem cell on TNF- α expression, spiral artery remodeling and placental apoptosis of Pb-exposed pregnant mice.

2. Materials and methods

This study was an experimental laboratory study using 35 pregnant mice with complete random sampling design. Female mice (*Mus musculus*) were injected using pregnant mare serum gonadotropin (PMSG) (Foligon) with the dose of 5 IU and human chorionic gonadotropin (hCG) (Chorulon) 48 h after PMSG. After injection, they were monogamously mated to fertile male mice, and the examination of vaginal plugged was carried out 17 h after mated. Pregnancy age and vaginal plugged were counted from day 0 of pregnancy.

2.1. Lead and hematopoietic stem cell treatment

Thirty-five pregnant mice were divided into five groups. Group 1: without treatment. Group 2: lead with a dose of 1/12 50% lethal dose (LD₅₀) was injected from day 9 to day 15 and aquadest orally was given on day 16. Group 3: lead with a dose of 1/16 LD₅₀ was injected from day 9 to 15 and aquadest orally was given on day 16. Group 4: lead with a dose of 1/12 LD₅₀ was injected from day 9 to 15 and 1 × 10⁷ hematopoietic stem cell was given on day 9 intravenous. Group 5: lead with a dose of 1/16 LD₅₀ was injected from day 9 to 15 and 1 × 10⁷ hematopoietic stem cell was given on day 9 intravenous.

2.2. Hematopoietic stem cell method

Intracardiac blood of female mice was taken and its peripheral blood mononuclear cells (PBMCs) was filled-in 15 mL tubes, followed by adding sterile phosphate buffer saline (PBS). A 0.177 density of isopaque ficol was prepared and poured on the tube containing the PBMCs and PBS, centrifuged at the temperature of 20 °C for 5 min with 1 600 r/min speed. Mononuclear cells were taken into 15 mL tube and sterile medium was added for centrifuging process. The supernatant was taken out, then slowly resuspended the pellet using growing medium without damaging the cell membrane. After that, the suspension was taken and entered into 10 mL sterile disposable Petri dish and evaluated under an inverted microscope for cell quantification. Furthermore, the cells obtained, incubated to develop into a monolayer and these cells will be injected in the animal model of lead intoxication. Before the injection, the cells were checked and labeled by CD 45 and CD 105 marker (Figure 1).




Figure 1. Characterisation of hematopoietic stem cell.

The HSC labeled by CD 45 marker as a positive control (A) and CD 105 marker as a negative control (B). The arrow showed the cells labeled by CD 45 marker.

2.3. Removal of placenta and uterus organs

The mice were decapitated on pregnancy day 17. The placenta and uterus microslices were prepared, and placenta sample was taken for TNF- α expression and apoptosis index examinations, then uterine sample was taken for spiral arteries remodeling evaluation.

2.4. Examination of tumor necrosis factor (TNF)- α expression

Placenta microslices made on the object glasses were dipped in xylol, alcohol and distilled water respectively. Then they were washed 3 times for 5 min each in PBS at pH 7.4. After that they were soaked in hydrogen peroxide (H₂O₂) 3% for 5-10 min, immersed in 1% BSA in PBS for 10-30 min at room temperature, followed by adding TNF- α antibody for 1 hour at room temperature. Then they were washed in PBS with pH 7.4 for 3 min × 5 min, added with SA-HRP (Strep Avidin-Horse Radish Peroxidase) for 30-60 min at room temperature, washed in PBS with pH 7.4 for 3 min × 5 min, added with Chromogen DAB (3,3-diaminbenzidine tetrahydrochloride) for 10-20 min, washed in distilled water for 3 min × 5 min at room temperature, then added with methyl green counterstain for 3 min. The examination was performed using a microscope at a magnification of 40, 100 and 400 times. TNF- α expression in placenta was determined by observing brownish discoloration on syncytiotrophoblast cells compared to the control.

2.5. Histopathology examination to assess spiral artery remodeling

Uterus was fixed with 10% buffered formalin, then histopathologically processed by dehydration, rehydration, embedding and uterine tissue cutting. Staining process was performed using hematoxylin-eosin. The microslices were evaluated under 400 times of microscope magnification.

2.6. Examination of apoptosis index

Stages TACS 2 TdT-DAB in situ Apoptosis Detection kit. Microslides were deparaffinized in xylol and alcohol series. Put PBS on the slide for 10 min, absorbed the liquid with a tissue. Covered the sample with 50 dsf mL proteinase K for 15-30 min, washed twice with deionized water (dH₂O) each for 2 min. Put drops on the samples with sequencing solution for 5 min, washed the slides by using PBS for 1 min. Put drops of TdT labeling buffer to the samples for 5 min, covered the sample with 50 mL of labeling reaction mix for 2 reactions: TdT dNTP Mix (Cat # 4828-30-04) 2 mL, TdT Enzyme (Cat # 4810-30-05) 2 mL, 50 × Cation Stock 2 mL, 1 × TdT labeling Buffer 100 mL, incubated for 60 min at 37 °C in a humid place. Washed slides with 1xTdT stop buffer for 5 min, washed slides every 5 min with dH₂O. Put drops on sample with 50 mL srep-HRP solution and incubated for 10 min at 37 °C in a humid place to prevent evaporation. Washed slides with PBS twice each for 2 min. Dropped with DAB solution for 2-7 min, washed slides with dH₂O each 2 min. Put drops of 1% methyl green on the slides for 30 s to 5 min, soaked and washed slides 10 times with dH₂O. Dried the microslides overnight and covered with entelan.

2.7. Assessing index apoptosis and expression TNF- α

Histopathological examination is intended to determine the index apoptosis and expression of TNF- α in the placenta. Data of each sample assessed semiquantitatively according to the modified method Remmele[7], where the index scale Remmele immuno reactive score (IRS) is the result of multiplying the cells percentage scores immunoreactive with the color intensity scores immunoreactive cells (Table 1). Data of each sample is the average value of IRS are observed in different 10 Field of view at 400 × magnification.

Table 1

Semiquantitative scale of IRS .

A	B
Score 0: No positive cells	Score 0: No reaction color
Score 1: Positive Cells less than 10%	Score 1: The color intensity mild
Score 2: Positive cells between from 11% - 50%	Score 2: The color intensity moderate
Score 3: Positive cells between from 51% - 80%	Score 3: The color intensity Strong
Score 4: Positive cells between from more than 80%	-

Positive cells (A) intensity of tubes Score color reaction (B), so the IRS= (A × B).

2.8. Data analysis

The data about the expression of TNF- α , the number of spiral artery remodeling and apoptosis index were analyzed using statistical SPSS program for windows. All five group data were compared using the ANOVA test. The differences were considered to be statistically significant if *P*<0.05.

3. Results

3.1. TNF- α expression

Immunohistochemistry examination of TNF- α expression was showed by the colors of light to dark brown in immunoreactive cells (Figure 2). There were significant differences between five groups above (*P*=0.00) (Figure 3).

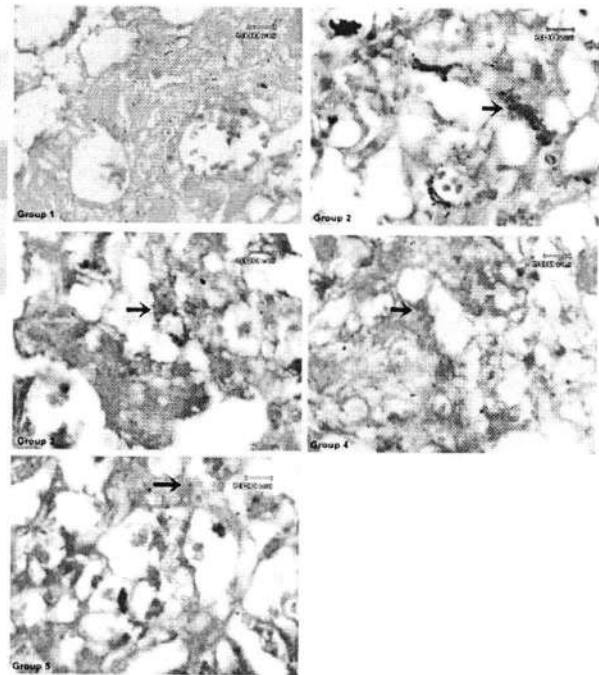


Figure 2. TNF- α expression shown by the colors of light to dark brown in immunoreactive cells.

Group 1 did not show the presence of immunoreactive cells. Group 2 group showed high intensity dark brown color of TNF- α immunoreactive cells than Group 3 on cytotrophoblast (black arrow) and endothelial cells (yellow arrow). Group 4 and Group 5 showed TNF- α immunoreactive cells less than Group 2 and Group 3.

Coloring immunohistochemistry; magnification 1 000×; Olympus BX-50. Pentax optio 230; Digital Camera of 2.0 megapixel.

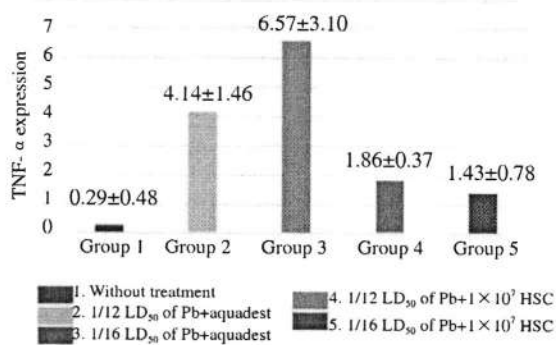


Figure 3. TNF-α expressions of pregnant mice group without treatment, with Pb treatment and Pb + hematopoietic stem cell treatment.

Thus TNF-α expression in normal pregnant mice without treatment, lead-exposed mice and mice exposed to lead after intravenous 1×10^7 HSC treatment were significantly different. By using Mann-Whitney test the difference of each groups were analyzed. There was no statistical difference of TNF-α expression between pregnant mice with of $1/12$ LD₅₀ of lead exposed and those with $1/16$ LD₅₀ of lead exposed, but significant difference was found between lead exposed treatment with and without 1×10^7 HSC treatment. There was no difference in TNF-α expression between pregnant mice with $1/12$ LD₅₀ of lead followed 1×10^7 HSC and those with $1/16$ LD₅₀ of lead exposed followed 1×10^7 HSC ($P=0.227$).

3.2. Spiral artery remodeling

Hematoxylin-eosin staining of spiral artery remodeling showed the difference of vascular response in the uterus (Figure 4).

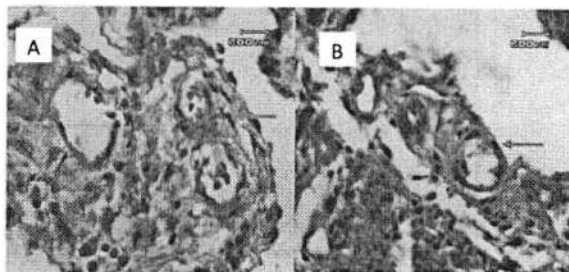


Figure 4. The difference of vascular response in uterus.

Slide A showed gradual blood stream vasoconstriction (arrow) and slide B showed normal vasodilatation (arrow). Coloring haematoxylin eosin; magnification 1 000 ×; Olympus CX41; DP12 olympus micro digital camera 2 megapixel.

Spiral artery remodeling was analyzed by assessing the contraction status of blood vessel in endometrium and myometrium of pregnant mice uterine. There was a significant difference in the five groups above ($P=0.00$). It meant that spiral artery remodeling of normal pregnant mice group without treatment, lead exposed treatment and lead-exposed followed 1×10^7 HSC intravenous were significantly different (Figure 5).

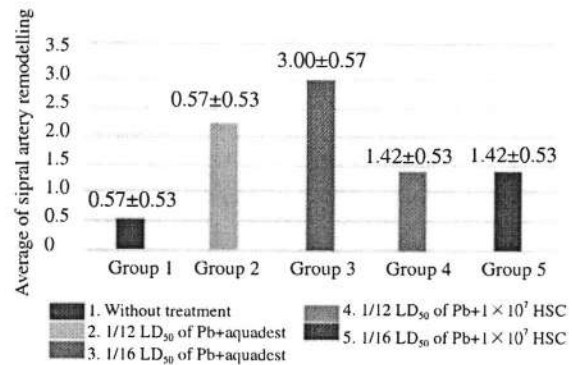


Figure 5. Spiral artery remodeling of pregnant mice group without treatment, with Pb treatment and Pb + hematopoietic stem cell treatment.

The difference between each group was analyzed using Mann-Whitney test. There was a significant difference of spiral artery remodeling between Group 2 ($1/12$ LD₅₀ of lead and Aquadest) and Group 3 ($1/16$ LD₅₀ of lead and Aquadest). There was also a significant difference of spiral artery remodeling between Group 2 and Group 4 ($1/12$ LD₅₀ of lead followed 1×10^7 HSC treatment) and Group 5 ($1/16$ LD₅₀ of lead followed 1×10^7 HSC treatment), but no difference was found between Group 4 and Group 5.

3.3. Apoptosis index

The immunohistochemistry examination of apoptosis involved light to dark brown staining of immunoreactive cells (Figure 6). There was a significant difference among the five groups above ($P=0.00$). It is meant that apoptosis index of normal pregnant mice group without treatment, lead-exposed treatment and lead-exposed followed 1×10^7 HSC intravenous were significantly different (Figure 7).

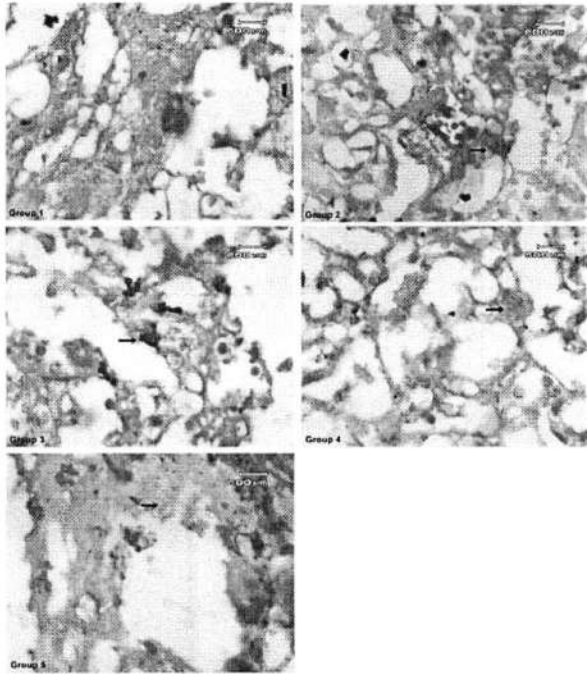


Figure 6. Apoptotic index was shown by colors of light brown to dark brown in immunoreactive cells.

Group 1 did not show the presence apoptotic cells in cytotrophoblast. Group 2 showed high intensity of dark Brown in apoptotic cells than Group 3, expressed in cytotrophoblast (black arrow) and endothelial cells (yellow arrow). Group 4 and group 5 showed apoptotic cells less than Group 2 and Group 3.

Coloring immunohistochemistry; magnification 1 000 ×; Olympus BX-50. Pentax optio 230; Digital Camera of 2.0.

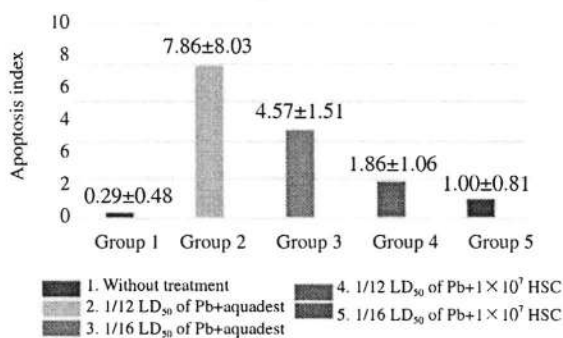


Figure 7. Apoptosis index of pregnant mice group without treatment, with Pb treatment and Pb + Hematopoietic stem cell treatment.

Differences among groups were assessed using the Mann-Whitney

test. The apoptosis index of pregnant mice group without lead-exposed treatment (Group 1) was significantly different between those groups with lead-exposed (Group 2 and 3) and HSC (Group 4), but no difference was found in Group 5. There was significant difference of apoptosis index between group of lead-exposed treatment (Group 2 and 3), and lead-exposed followed HSC treatment (Group 4 and 5) but no difference was found between Group 4 and 5 (Table 2).

Table 2
The significant comparison of apoptosis index in five groups.

Groups	Group 1	Group 2	Group 3	Group 4	Group 5
Group 1	-	0.001*	0.001*	0.004*	0.080
Group 2	-	-	0.013*	0.002*	0.001*
Group 3	-	-	-	0.007*	0.002*
Group 4	-	-	-	-	0.133
Group 5	-	-	-	-	-

Pregnant mice without treatment (Group 1), Pb treatment (Group 2 and 3) and Pb + Hematopoietic stem cell treatment (Group 4 and 5) (Mann-Whitney test). *P<0.05.

4. Discussion

Characterization was done to confirm the HSC growth by labeled with CD 45 antibody. The HSC stained by FITC and CD 45 antibody and observed under fluorescent microscope. Our result showed that the cells labeled by CD 45 antibody have a light green color, so we can conclude that our culture is truly HSC. As a comparison the HSC also was labeled by CD 105 antibody as a negative control, after observed under fluorescent microscope our result showed no positive reaction. CD 105 is a specific marker to identify the mesenchymal stem cell.

Lead is a deleterious environmental pollutant and causes a range of physiological and biochemical dysfunctions. Repeated exposure of lead during organogenesis can cause teratogenicity, embryotoxicity, and abortion[8]. The amount of lead entering body will activate nuclear factor kappa beta and mitogen-protein kinase; both can change the function of mitochondria and increase cytokine proinflammation such as TNF- α [9]. Lead penetrating placenta and entering cells will lead to the formation of reactive oxygen species (ROS). ROS formed in trophoblast cells will cause mitochondrial damage, therefore it causes loose of cytochrome caught by apaf-1, then it will activate caspase-3 as the executor of apoptosis[10]. In this study TNF- α expression, spiral artery remodeling and apoptosis index in lead-exposed treatment group (Group 2 and 3) are higher than control group without treatment (Group 1). It is meant that

exposure of lead may cause negative effect on placenta and uterine of pregnant mice.

The administration of HSC intravenously through the coccygealis vein allowed cells to home to damaged placental tissues. Hematopoietic stem cell entering placental cells, proliferated and differentiated in order to change the damaged placental tissue because HSC was multipotent and can differentiate to all cell types including the formation of placenta and umbilical cords. The ability of stem cell for self-renewal enables it to replicate and form cells which have same characteristic with the parent cell, therefore, stem cell administration as therapy is aimed to replace damaged cells^[11].

Hematopoietic stem cell therapy decreased trophoblast cells experiencing apoptosis and regenerate damaged trophoblast cells due to lead administration. In this study TNF- α expression, spiral artery remodeling and apoptosis index in group of lead-exposed followed HSC treatment (Group 4 and 5) is lower than those without HSC treatment. It is meant that HSC treatment has positive effect on placenta and uterine of pregnant mice.

HSC administration decreased the expression of TNF- α which is a factor initiating apoptosis, therefore, apoptosis index was also decrease. The decrease of TNF- α expression alleviated inflammation process, therefore it may decrease vasoconstriction of blood vessel in spiral artery as an explanation of the presence of spiral artery remodeling, and may suppressed uterus contraction as well.

Hematopoietic stem cells require time for homing in order to differentiate and regenerate damaged cells. In this study nine days administration of HSC was enough for homing which was seen by the decrease of TNF- α expression, spiral artery remodeling, and apoptosis index.

The conclusion of this study is in lead-exposed pregnant mice, the administration of hematopoietic stem cell may decrease TNF- α expression, spiral artery remodeling, and placenta apoptosis but in the group of 1/16 LD₅₀ of lead-exposed followed HSC treatment, apoptosis index is similar with those of control group.

In the first group of pregnant mice were exposed to a lead dose 1/12 LD₅₀ and 1/16 LD₅₀ occur early embryonic death characterized by reabsorption embryos compared with the group receiving therapy HSC. Congenital defects do not occur in all four treatment groups and control. Weight and length of the fetus in the group exposed to lead without giving HSC lower than the group exposed to lead and given HSC therapy.

Conflict of interest statement

The authors declare that they have no competing interest.

Acknowledgments

We would like to thank to Universitas Airlangga for funding the research by RKAT 2014 Grant.

References

- [1] Sharifi AM, Mousavi SH, Jorjani M. Effect of chronic lead exposure on pro-apoptotic Bax and anti-apoptotic Bcl-2 protein expression in rat hippocampus *in vivo*. *Cell Mol Neurobiol* 2010; **30**(5): 769-774. doi: 10.1007/s10571-010-9504-1.
- [2] Neeti K, Prakash T. Effects of heavy metal poisoning during pregnancy. *Int Res J Environ Sci* 2013; **2**(1): 88-92.
- [3] Gundacker C, Hengstschlager M. The role of the placenta in fetal exposure to heavy metals. *Wien Med Wochenschr* 2012; **162**(9-10): 201-206. doi: 10.1007/s10354-012-0074-3.
- [4] Mohsen V, Hiroyuki S, Shin-ichi S. Lead exposure in female workers who are pregnant or of childbearing age. *Indust Health* 2011; **49**: 255-261.
- [5] Jamur MC, Grodzki ACG, Moreno AN, de Mello LFC, Pastor MVD, Berenstein EH, et al. Identification and isolation of rat bone marrow-derived mast cells using the mast cell-specific monoclonal antibody AA4. *J Histochem Cytochem* 2001; **49**(2): 219-228.
- [6] Wognum AW, Szilvassy SJ. Hematopoietic stem and progenitor cells. *Stem Cell Technol* 2013. [Online] Available from: <https://www.stemcell.com/hematopoietic-stem-and-progenitor-cells-lp.html>.
- [7] Remmele W, Stegner HE. Recommendation for uniform definition of an immunoreactive score (IRS) for immunohistochemical estrogen receptor detection (ER-ICA) in breast cancer tissue. *Pathol* 1987; **8**: 138-140.
- [8] Aisha MF, Samya ES, Koratem KH. Effect of dietary calcium on maternal and fetal lead toxicity and teratogenicity in rats Egypt. *J Comp Path Clin Path* 2008; **21**(4): 283-305.
- [9] Kim JJ, Lee SB, Park JK, Yoo YD. TNF α -induced ROS production triggering apoptosis is directly linked to room 1 and Bcl-XL. *J Nat Cell Death and Diff* 2010; **17**: 1420-1434. doi: 10.1038/cdd.2010.19.
- [10] Wani MY, Hashim MA, Nabi F, Malik MA. Nanotoxicity: Dimensional and morphological concern. *Adv Phy Chem* 2011; **8**: 1-15. doi: 10.1155/2011/450912.
- [11] Halim D, Murti H, Sandra F, Boediono A, Djuwantono T, Setiawan B. *Stem cell: Teory basic and clinical application. Edisi ke-1*. Jakarta: Erlangga Press; 2010.