

Matrix Metalloproteinase-9 Expression and Status of Cervical

by Muhtarum Yusuf

Submission date: 29-Jun-2022 03:04PM (UTC+0800)

Submission ID: 1864503474

File name: Matrix_Metalloproteinase-9_Expression_and_Status_of_Cervical.pdf (291.88K)

Word count: 3877

Character count: 21020

Matrix Metalloproteinase-9 Expression and Status of Cervical Lymph Nodes in Patients with Nasopharyngeal Carcinoma

Muhtarum Yusuf¹ · Yuan Ariawan Kusuma¹ · Dwi Reno Pawarti¹

12

Received: 20 February 2018 / Accepted: 9 July 2018 / Published online: 18 July 2018

© Association of Otolaryngologists of India 2018

Abstract Tumor growth and metastasis in nasopharyngeal carcinoma (NPC) patients was suspected as a role of several molecular biomarkers that have been identified in tumor specimens of patients with NPC. Invasion and metastasis process was a complex mechanism which involved some proteolytic enzymes, such as matrix metalloproteinase-9 (MMP-9). To analyze the association of MMP-9 expression of NPC patients with cervical lymph node metastasis. The study was conducted in oncology unit of ORL-HNS at Dr. Soetomo General Hospital Surabaya from May to July 2015. Formalin-fixed paraffin-embedded biopsy specimens from NPC patients with WHO type II and III of histopathology and clinically were divided into four state of cervical enlargement (N0, N1, N2 and N3). The expression of MMP-9 was obtained with immunohistochemistry using rabbit polyclonal antibody Anti-MMP9 ab7299 from abcam[®], Cambridge-UK. Thirty-two NPC patients were enrolled in this study. The study found a negative expression of MMP-9 in 3.12% of samples. Spearman rho test result was $p = 0.001$ with correlation coefficient of 0.754. Spearman test resulted p value of 0.001 with a correlation coefficient of 0.754. Correlation of matrix metalloproteinase-9 expression with cervical lymph node metastasis (N0, N1, N2, and N3) in patients with NPC showed a significant result ($p < 0.05$). There was a strong positive correlation between MMP-9 expressions with cervical lymph node status in NPC patients.

Keywords Nasopharyngeal carcinoma · Progressivity · Matrix metalloproteinase-9 · Cervical lymph node metastasis

21

Introduction

Nasopharyngeal carcinoma (NPC) is a malignant disease in the head-neck that many encountered in Indonesia and also the countries in Southeast Asia with the highest incidence rate in southern China [1]. Nasopharyngeal carcinoma has a potential for proliferation. Invasion and metastasis are higher than other head and neck cancers. NPC progression has been determined based on clinical staging assessments, i.e., the primary tumor (T), cervical lymph node metastasis (N) and distant metastasis (M). Many NPC patients with similar clinical stages provide different therapeutic responses and prognoses. This suggests that TNM assessments cannot yet be used to predict the progressiveness or response to therapy (prognosis) in NPC patients.

Therefore, it is necessary to develop molecular biomarkers on NPCs that can assist clinicians in predicting the progression and prognosis of NPC patients. About 90% of NPC patients are encountered cervical lymph node enlargement [2]. The biological properties of NPC are determined by cervical lymph node status. Patients with large cervical lymph node enlargement have a tendency of poor prognosis. This indicates the NPC's progressivity is determined by the status of cervical lymph node [3].

Matrix metalloproteinase-9 was reported to degrade the extracellular matrix and basal membrane with the main component of type IV collagen as a result of triggering angiogenesis and resulting in increased tumor growth (proliferation), invasion and metastasis both lymphogenic and hematogenous [4].

✉ Muhtarum Yusuf
yusufmuhtarum@gmail.com

¹ Department of Otorhinolaryngology, Head and Neck Surgery, Faculty of Medicine, Universitas Airlangga - Dr. Soetomo General Hospital, Jalan Mayjen Prof. Dr. Moestopo No. 47, Surabaya 60131, Indonesia

Several researchers reported the association of MMP-9 expression with growth and metastasis in NPC through immunohistochemical examination of NPC tissue [2, 4–6]. The research in 28 patients with NPC had a significant increased of MMP-9 expression in NPC group with advanced metastasis compared to NPC group of initial metastasis and NPC without metastasis ($p < 0.05$) [5].

Nasopharyngeal carcinoma is a neoplasm derived from the nasopharynx epithelial mucosa and is suspected to be closely related to VEB infection, diet and genetic factors [4]. Latent membrane protein-1 is suggested to have a role in the pathogenesis of NPC. Latent membrane protein-1 is required for B lymphocyte transformation, meanwhile, LMP-1 expression is found in 70% NPC and in all pre-invasive lesions of VEB [2].

Latent membrane protein-1 from VEB plays a role in MMP-9 synthesis in the nucleus through activation of Extracellular signal regulating kinase-Mitogen-Activated Protein Kinases (ERK-MAPK) that activates protein-1 activator (AP-1). Latent membrane protein-1 also plays a role in the regulation of MMP-9 expression through the nuclear factor- κ B (NF- κ B) transcription factor.

Matrix metalloproteinase-9 is a gelatinase produced and secreted by various cancer cells, stromal cells, fibroblasts, and inflammatory cells. This enzyme is secreted and retained as an inactive zymogen (pro MMP) in the cytoplasm of cancer cells. Then, they are activated in the extracellular space. Matrix metalloproteinase-9 has the ability to degrade the components of MES and basal membranes. On the other hand, MMP-9 also stimulates growth factors thus the process of tumor invasion becomes easier. Matrix metalloproteinase-9 triggers an angiogenesis process that will increase tumor growth (proliferation), invasion, and metastasis with clinical manifestations of primary tumor enlargement in the nasopharynx and cervical lymph node (status) extension. MMP-9 activity can be inhibited by endogenous inhibitors of tissue inhibitor of metalloproteinase (TIMP) and synthetic inhibitors such as bathymastat, ilomastat, and marimastat [7].

27

Methods

This research was an analytic observational with cross-sectional approach from May to July 2015 in Oncology Unit, Installation of Anatomical Pathology at Dr. Soetomo General Hospital Surabaya, and Laboratory of Anatomical Pathology at Dr. Sardjito Yogyakarta, Indonesia.

The sample used in this study was NPC patients, either without cervical lymph node enlargement (N0) or with cervical lymph node enlargement (N1 N2 N3), nasopharyngeal biopsy of a WHO type II and III carcinoma, and never received definitive treatment (radiotherapy,

chemotherapy or a combination of both). Sampling technique used was consecutive sampling.

The inclusion criteria were; NPC patients who have sufficient paraffin blocks of nasopharyngeal biopsy to conduct an immuno-histochemistry examination and MMP-9 expression assessment, and patients willing to participate in the informed consent. The exclusion criteria were; the preparation of paraffin block was damaged or not eligible thus the immunohistochemical examination cannot be performed to assess MMP-9 expression.

Immunohistochemical examination to determine MMP-9 expression was using rabbit polyclonal antibody Anti-MMP9 ab7299 (abcam® Cambridge-UK). Furthermore, the reading and assessment of MMP-9 expression were conducted by PA specialist doctor (consultant) in PA Laboratory of Dr. Sardjito Hospital Yogyakarta. The researchers performed a neck examination to assess the status of the cervical lymph node. If nodules/lymph node enlargement in the neck was found, then, the measurement was performed using vernier callipers of AMC-WP017 (in centimetre).

Data obtained in this study were analyzed by Spearman's rho test to determine the relationship between MMP-9 expressions with cervical lymph node status (N0 N1, N2, N3) in NPC patients. The level of significance was (α) = 0.05. The research protocol was approved by the ethic committee of Dr. Soetomo Teaching Hospital Surabaya Indonesia.

Results

We obtained that the most age group was 50–59 years of 14 patients (43.75%), meanwhile, 20–29 years age group found one patient (3.12%). The youngest was 22 years old and the oldest was 68 years old. The result of data analysis based on sex obtained 20 males (62.50%) and 12 females (37.50%). Comparison of men and women was 1.6:1. The most common occupation in this study was farmer of 14 patients (43.75%) and eight patients (25.00%) did not work (housewives). Based on data analysis, the most histopathology type was WHO type III of 28 patients (87.50%) then followed by WHO type II of 4 patients (12.50%). WHO type I was excluded because the MMP-9 expression occurred due to its association with VEB.

Association of MMP-9 Expression with Cervical Lymph Node Status in NPC Patients

We found an increase in the number of cells that provided MMP-9 expressions of weak, medium, strong and very strong on the status of cervical lymph node (N0, N1, N2, and N3). There was a negative MMP-9 expression of

3.12%, weak positive MMP-9 expression of 21.87%, and a very strong positive MMP-9 expression of 34.37%. N0 group obtained a negative MMP-9 expression in one sample.

Groups N1, N2, and N3 did not obtain negative MMP-9 expression. The result of MMP-9 expression was weak positive by 21.87% of all samples. Group N0 obtained a weak positive MMP-9 expression in three samples. Groups of N1 and N2 obtained two samples in each group and no positive MMP-9 expression was found in N3. Moderate positive MMP-9 expression was found in 25.00% of all samples. Group N1 obtained moderate positive expression in three sample and group of N2 found in five samples. There was no positive MMP-9 expression in the N0 and N3 groups. Positive MMP-9 expression was found in 15.62% of all samples. Group N2 obtained a strong positive expression in three samples and group of N3 found two samples. Positive MMP-9 expression was not found in the group of N0 and N1. The result of positive MMP-9 expression was very strong at 34.37% of all samples. Group N2 obtained a very strong expression in five samples and group of N3 found six samples. Positive MMP-9 expression was not found in the N0 and N1 groups.

Spearman's rho test of MMP-9 expression with cervical lymph node status (N0 N1, N2, N3) in NPC patients obtained $p = 0.001$ and correlation coefficient (r) 0.754. It means that there was a significant relationship ($p < 0.05$) of MMP-9 expression with cervical lymph node status. Correlation strength of 0.754 means a stronger MMP-9 expression, the higher the status of a cervical lymph node in patients with NPC. There was a positive correlation between MMP-9 expression with cervical lymph node status (N0 N1, N2 and N3) in NPC patients.

Immunohistochemical results of MMP-9 in NPC tissue were identified by the presence of dark brown color in the cell nucleus and cytoplasm of tumor cells. The observation and analysis of MMP-9 expression were performed by a binocular microscope with $400 \times$ magnification. Immunohistochemical staining results were shown in Figs. 1, 2, 3, 4 and 5.

Discussion

The most common NPC patients in the 40–49 years group of 35.8% followed by the 30–39 years group of 21.4% [8]. Nasopharyngeal carcinoma can be found at all ages. Although some researchers reported a number of cases of NPC in children, however, it was rare to found at age under 20 years [1]. The distribution of NPC patients based on the age of incidence increased at age of 45–54 years then it decreased. Most NPC patients were found at the productive age of 30–59 years (about 80%) then peaked at the age of

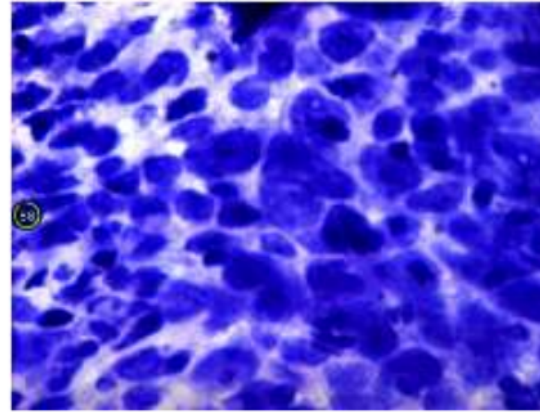


Fig. 1 MMP-9 staining results on KNF tissue with Immunohistochemical techniques. There was no apparent brown color in the cell nucleus and cytoplasm; showed a negative MMP-9 (–) expression

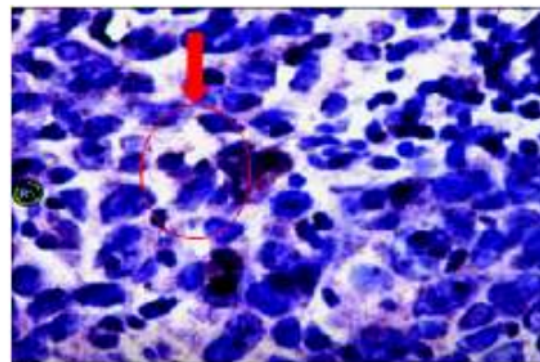


Fig. 2 MMP-9 staining results in KNF tissue with Immunohistochemical techniques. Dark brown color in the cell nucleus and cytoplasm (yellow arrow) appears. The colored cell $\leq 25\%$, indicates a weak positive MMP-9 (+) expression

40–49 years. The highest incidence was at the age of 40–60 years. The workers at the productive age were often going out of the house thus the possibility of exposure to carcinogenic substances or pollution was higher [1, 9].

Cancer cells emerged from normal cells who undergone a malignant transformation as a result of spontaneous mutations or carcinogen induction. The presence of contact with carcinogens until the onset of cancer cells took a long induction time up to 15–30 years [10]. VEB infection as a risk factor NPC has a latent period in the infected nasopharyngeal cells about 20–25 years without symptoms of primary VEB infection in childhood and asymptomatic. The process of malignancy in NPC occurred after latent infection. This might have caused a high incidence to be found at the age of 40–60 years [11].

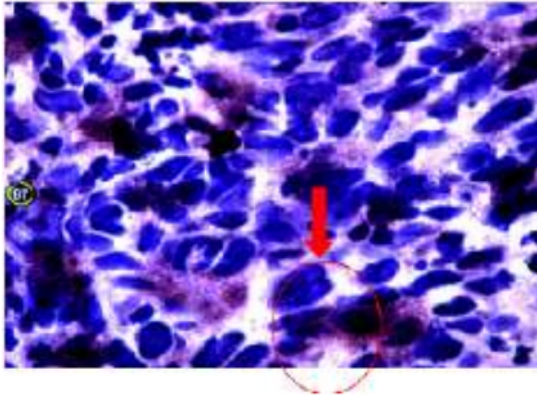


Fig. 3 MMP-9 results on KNF tissue with Immunohistochemical techniques. Dark brown color in the cell nucleus and cytoplasm (yellow arrow) appears. Tinted cells $> 25- \leq 50\%$ shows a moderate positive MP-9 expression (++)

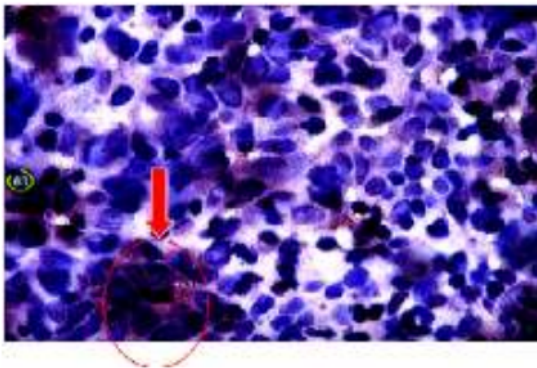


Fig. 4 MMP-9 staining results on KNF tissue with Immunohistochemical techniques, dark brown color in the cell nucleus and cytoplasm (yellow arrow) appears. Tinted cells $> 50- \leq 75\%$ shows a strong positive MMP-9 (++) expression

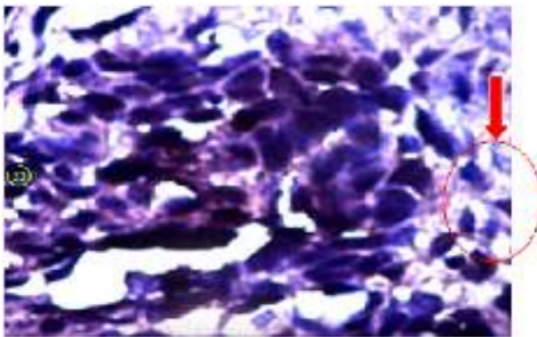


Fig. 5 MMP-9 staining results in KNF tissue with Immunohistochemical techniques. Dark brown color appears on the cell nucleus and cytoplasm (yellow arrow) appears. Tinted cells $> 75\%$ shows a very strong positive MMP-9 (+++++) expression

The high incidence in male patients compared to female was reported in almost all studies. It was suspected to be related to habits and occupations that cause men to be exposed more frequently to carcinogens of NPCs. Exposure to steam, smoke dust, and chemical gas at work increased the risk of NPC by 2–6 times. Meanwhile, the exposure to formaldehyde in the workplace increased the risk of NPC by 2–4 times. Increased risk also occurred in workers who inhale firewood smoke and the risk increased by 2 times in workers who exposed to industrial heat and combustion products [12].

There was a difference in the distribution of ethnic groups due to the largest population of the population in the city of Surabaya as the location of research was the Javanese. Based on immunogenic studies in Jakarta (1997) reported that 20 NPC patients (15 males and 5 females) obtained HLA-A24 (RR: 5.43) and HLA-B63 (RR: 5.96). These two class I antigen phenotypes was suspected to be the cause of NPC for indigenous Indonesians [1].

Based on the literature, carcinogenic associated with NPC incidences were dust or particles of moderate size (5–10 μm). It was due to particles of that size was easily absorbed by the nasopharyngeal mucosa. Several epidemiological studies have shown increased NPC risk factors in workers that exposed to wood dust with specific time periods and doses. Other studies have also found an increased risk of NPC's incidences in people who work in environments with pollution from burning (charcoal). The ratio of exposure to workers cannot be determined precisely because it is determined by frequencies and areas that are endemic [13].

Particles in smoke derived from burning coal, wood and other materials were mostly stored in the nasopharynx. There were several major chemicals known as a cause of NPC's based on occupational exposure, such as bleach, acid and base, sulfuric acid, inks, formaldehyde and pesticides. The risk of exposure for 10–20 years as a latent effect had a significant association with NPC13 events [14].

The most common histopathology type of NPC in Indonesia was WHO type III. Results of research in other big cities in Indonesia also showed a different distribution of histopathology type [15]. The Spearman's rho test of the association of MMP-9 expression with cervical lymph node status (N0, N1, N2, and N3) in NPC patients showed a result of $p = 0.001$ and $r = 0.754$. MMP-9 expression with cervical lymph node status was found to be significant with $r = 0.754$. Thus, the hypothesis of this study was evident. We found a positive correlation between MMP-9 expression and cervical lymph node status (N0, N1, N2, and N3). This could be interpreted as the stronger the MMP-9 expression, the higher the status of a cervical lymph node in patients with NPC.

10 There was a positive correlation between increased MMP-9 expression and cervical lymph node status (N0, N1, N2 and N3) in NPC patients. It suggested that tumor progression could be predicted from the level of MMP-9 expression. The higher the MMP-9 expression in NPC tumor cells, the higher the cervical lymph node status of NPC patients. The results of this study were in accordance with other studies that obtained a significant increased of MMP-9 expression in patients with advanced stage NPC ($p < 0.05$) [4]. The increased of MMP-9 expression was associated with a classification of T (large tumors), classification N (metastasis in the lymph node), and clinical of NPC patients.

Other research in Department of Pathology Anatomy, Faculty of Medicine, Universitas Airlangga, Dr. Soetomo General Surabaya Surabaya on 28 patients with NPC showed a significant increase of MMP-9 expression in the NPC group with advanced metastasis than in the initial NPC metastasis group and NPC without metastasis [5]. It was concluded that there was an association between MMP-9 expression with tumor progression or degree of lymph node metastasis in NPC ($p < 0.05$). It means that the stronger the MMP-9 expression, the higher the degree of metastasis in the NPC. Other studies on 146 patients with NPC and 110 invidu as control resulted that an increase in MMP-9 expression was associated with clinical characters, i.e., stadium ($p < 0.001$), primary tumor in the nasopharynx ($p = 0.016$), metastasis in cervical lymph node ($p = 0.002$), histology ($p = 0.002$) and poor overall survival ($p = 0.049$) [6]. Other studies suggested that MMP-9 expression was not correlated to histology, gender, age, T classification or staging classification, however, it related to metastasis in cervical lymph node ($p = 0.004$) [2].⁴⁴

32 Matrix metalloproteinase-9 is a proteolytic enzyme that plays an important role in the process of metastasis. After tumor cells are released from each other due to E-cadherin activity, then the invasion of tumor cells into surrounding tissues involving catalytic enzymes is proceed. Matrix metalloproteinase-9 plays an important role in tumor and metastatic progression in both regional and remote [16].

Matrix metalloproteinase-9 is part of the Zn^{2+} dependent endopeptidase family, working at neutral pH, is secreted in an inactive zymogen, and require proteolytic activation [17]. MMP-9 expression will increase in malignancy; furthermore, tumor cells also produce MMP-9 and play an active role in the proliferation process. Matrix metalloproteinase-9 acts as a mediator on the activation of growth factors, bioavailability of receptors and signaling, adhesion and cell motility, apoptosis, survival and angiogenesis [18].

31 The most important part of the metastasis process is the degradation of the basal membrane and the extracellular

matrix. Basal membrane is an important barrier. Basal membrane damage is a major predictor of tumor invasion. Type IV collagen is a major component of basal membrane components. Matrix metalloproteinase-2 and MMP-9 are type IV collagenases that are closely related to tumor metastasis [17]. Nasopharyngeal carcinoma is a neoplasm derived from the nasopharynx epithelial mucosa and is thought to be closely related to VEB infection, diet, and genetic factors [4].

Several studies described different methods has been used to examine Matrix metalloproteinase-9. Immunohistochemical expression and western blot analysis can be used to revealed any expression of Matrix metalloproteinase-9 in tissue. Murawski et al. [19], previous study examine Matrix metalloproteinase-9 in breast cancer, revealed that the standard routine histopatological analysis misclassified almost 42% of patients as negative for axillary node metastasis.

Conclusion

There was a strong positive association between Matrix metalloproteinase-9 expression and cervical lymph node status in patients with nasopharyngeal carcinoma, and therefore immunohistochemical expression of this marker should be considered as a useful method to predict the progressiveness or response to therapy in nasopharyngeal cancer patients. Additional studies including western blot analysis could be use to confirm the Matrix metalloproteinase-9 expression.

References

1. Kentjono WA (2010) Karsinoma nasofaring: etiologi, gejala, diagnosis, deteksi dini, terapi dan pencegahan. In: Kentjono WA (ed) Pelatihan deteksi dini kanker nasofaring untuk dokter umum di puskesmas. Dept/SMF Ilmu Kesehatan THT-KL FK Unair/RSUD Dr. Soetomo, Surabaya, pp 13–41
2. Horikawa T, Yoshizaki T, Sheen TS, Lee SY, Furukawa M, et al (2000) Association of LMP 1 and MMP 9 with metastasis in NPC. In: Japan-Taiwan conference. Japan: American Cancer Society. vol 89, pp 715–23
3. Wakisaka N, Wen Q, Yoshizaki T, Furukawa M, Kawahara M, Nakanishi I et al (1999) Association of vascular endothelial growth factor expression with angiogenesis and lymph node metastasis in nasopharyngeal carcinoma. The Laryngoscope 109:810–814
4. Liu ZLL, Yang Z, Luo W, Li X, Yang H et al (2010) Increased expression of MMP 9 is correlated with poor prognosis of nasopharyngeal carcinoma. BMC Cancer J 10:1–7
5. Astuti AY (2014) Ekspresi E-Cadherin dan MMP-9 pada karsinoma nasofaring tanpa metastasis, dengan metastasis awal dan metastasis lanjut kelenjar getah bening. Dalam Karya Akhir untuk memperoleh ijazah keahlian Ilmu Patologi Anatomi.

- Departemen/SMF Patologi Anatomi FKUA/RSUD Dr. Soetomo Surabaya
6. He JR, Qin H, Ren ZF et al (2011) MMP-9 expression in peripheral blood mononuclear cells and the association with clinicopathological features and prognosis of nasopharyngeal carcinoma. *Clin Chem Lab Med* 49:705–710
 7. Vilen ST, Salo T, Sorsa T, Nyberg P (2013) Fluctuating roles of matrix metalloproteinase-9 in oral squamous cell carcinoma. *Sci World J*. <https://doi.org/10.1155/2013/920595>
 8. Harahap MPH (2009) Ekspresi vascular endothelial growth factor pada karsinoma nasofaring. Universitas Sumatra Utara Repository, Medan
 9. Mulyarjo (2002) Diagnosis dan penatalaksanaan karsinoma nasofaring. In: Mulyarjo D, Soedjak S, Wisnubroto W, Harmadji S, Hasanusi S, Artono R (eds) *Naskah Lengkap Pendidikan Kedokteran Berkelanjutan III Ilmu Kesehatan THT-KL*. Laboratorium/SMF Ilmu Penyakit THT-KL FK Unair/RSUD Dr. Soetomo, Surabaya, pp 38–48
 10. Sukardja IDG (2000) *Onkologi klinik*. 2nd edn. Airlangga University Press, Surabaya, pp 239–256
 11. Zeng MS (2010) Pathogenesis and etiology of nasopharyngeal carcinoma. In: Cooper JS, Lu JJ, LeeAWM (eds) *Nasopharyngeal cancer multidisciplinary management*. Springer, Berlin, pp 12–20
 12. Chang ET, Adami HO (2006) The enigmatic epidemiology of nasopharyngeal carcinoma. *Cancer Epidemiol Biomark Prev Publ Am Assoc Cancer Res Cosponsored Am Soc Prev Oncol* 15:1765–1777
 13. Ma JCS (2010) The epidemiology of nasopharyngeal cancer. In: Cooper JS, Lu JJ, Lee AWM (eds) *Nasopharyngeal cancer multidisciplinary management*. Springer, Berlin, pp 2–6
 14. Li WRR, Gao DL, Fitzgibbons ED, Seixos NS, Camp JE, Wernli KJ, Astrakianakis G, Feng Z, Thomas DB, Checkoway H (2005) Occupational risk factors for nasopharyngeal cancer among female textile workers in Shanghai China. *Occup Environ Med* 63:39–44
 15. Soetjipto D (1989) Karsinoma nasofaring. Balai Penerbit Fakultas Kedokteran Universitas Indonesia, Jakarta, pp 71–84
 16. Petruzelli GJ (2000) The biology of tumor invasion, angiogenesis and lymph node metastasis. *J Otorhinolaryngol Relat Spec* 64:178–185
 17. Yoon SOPS, Yun CH, Chung AS et al (2003) Roles of matrix metalloproteinase in tumor metastasis and angiogenesis. *J Biochem Mol Biol* 36:128–137
 18. Rundhaug JE (2003) Matrix metalloproteinases, angiogenesis, and cancer: commentary re: A. C. Lockhart, Reduction of wound angiogenesis in patients treated with BMS-275291, a broad spectrum matrix metalloproteinase inhibitor. *Clin. Cancer Res.*, 9: 00–00. *Clin Cancer Res Off J Am Assoc Cancer Res* 2003(9):551–554
 19. Murawski M, Wozniak M, Dus-Szachniewicz K, Kolodziej P, Rzeszutko M, Ziolkowski P (2016) Significance of matrix metalloproteinase 9 expression as supporting marker to cytokeratin 19 mRNA in sentinel lymph nodes in breast cancer patients. *Int J Mol Sci* 17:1–13

Matrix Metalloproteinase-9 Expression and Status of Cervical

ORIGINALITY REPORT

19%

SIMILARITY INDEX

7%

INTERNET SOURCES

19%

PUBLICATIONS

0%

STUDENT PAPERS

PRIMARY SOURCES

- 1** Riza Aswarin, Muhtarum Yusuf, M. S. Wiyadi. "Association of Protein Expression p53 Mutants with Regional Lymph Gland Status on type III Carcinoma Nasofaring Patients", Indian Journal of Otolaryngology and Head & Neck Surgery, 2018 1%
Publication

- 2** Steward Keneddy Mengko, Roestiniadi Djoko Soemantri, Sri Herawati Juniati. "Correlation Between Objective Evaluation Result of Nasal Congestion and Life Quality in Patients with Acute Rhinosinusitis", Indian Journal of Otolaryngology and Head & Neck Surgery, 2018 1%
Publication

- 3** Zhang, Sheng. "Imbalance between expression of matrix metalloproteinase-9 and tissue inhibitor of metalloproteinase-1 in invasiveness and metastasis of human gastric carcinoma", World Journal of Gastroenterology, 2003. 1%
Publication

4

Barbara Mroczko. "Expression of matrix metalloproteinase-9 in the neoplastic and interstitial inflammatory infiltrate cells in the different histopathological types of esophageal cancer", *Folia Histochemica et Cytobiologica*, 01/01/2008

Publication

1 %

5

Taiming Dai. "Studies on the expression of MMP-9 and significance of a macrophage assay in oral squamous cell carcinoma", *Chinese Journal of Clinical Oncology*, 10/2007

Publication

1 %

6

D Schveigert, S Cicenias, S Bruzas, NE Samalavicius, Z Gudleviciene, J Didziapetriene. "The value of MMP-9 for breast and non-small cell lung cancer patients' survival", *Advances in Medical Sciences*, 2013

Publication

1 %

7

Yang, Bo, Fuqiu Tang, Bicheng Zhang, Yong Zhao, Junming Feng, and Zhiguo Rao. "Matrix metalloproteinase-9 overexpression is closely related to poor prognosis in patients with colon cancer", *World Journal of Surgical Oncology*, 2014.

Publication

1 %

8

Imam Muslih, Sri Herawati, Dwi Retno Pawarti. "Association Between Voice Handicap Index and Praat Voice Analysis in Patients with

1 %

Benign Vocal Cord Lesion Before and After
Microscopic Laryngeal Surgery", Indian
Journal of Otolaryngology and Head & Neck
Surgery, 2018

Publication

9	ijop.net Internet Source	1 %
10	Youssef, Nermeen, and Sarah Hakim. "Association of Fascin and matrix metalloproteinase-9 expression with poor prognostic parameters in breast carcinoma of Egyptian women", Diagnostic Pathology, 2014. Publication	1 %
11	core.ac.uk Internet Source	1 %
12	Laksmi Kusuma Wardhani, Widodo Ario Kentjono, Achmad Chusnu Romdhoni. "Association Between Dose and Duration of Cisplatin Exposure with Cytotoxicity Effect on Nasopharyngeal Carcinoma Stem Cell", Indian Journal of Otolaryngology and Head & Neck Surgery, 2018 Publication	1 %
13	bmccancer.biomedcentral.com Internet Source	1 %
14	Riyad Bendardaf, Abdelbaset Buhmeida, Marja Hilska, Matti Laato, Stina Syrjänen, Kari	<1 %

Syrjänen, Yrjö Collan, Seppo Pyrhönen. "MMP-9 (Gelatinase B) Expression is Associated With Disease-Free Survival and Disease-Specific Survival in Colorectal Cancer Patients", Cancer Investigation, 2009

Publication

15

Yasuaki Harabuchi, Hiroshi Tsubota, Shinji Ohguro, Tetsuo Himi et al. "Prognostic Factors and Treatment Outcome in Non-Hodgkin's Lymphoma of Waldeyer's Ring", Acta Oncologica, 2009

Publication

16

"Nasopharyngeal Cancer", Springer Science and Business Media LLC, 2010

Publication

17

"Occupational Cancers", Springer Science and Business Media LLC, 2020

Publication

18

Farhat, R A Asnir, A Yudhistira, E R Daulay, D Puspitasari, S Yulius. "Evaluation of matrix metalloproteinase-9 expressions in nasopharyngeal carcinoma patients", IOP Conference Series: Earth and Environmental Science, 2018

Publication

19

Naveed Basheeth, Naishadh Patil. "Biomarkers in Head and Neck Cancer an

<1 %

<1 %

<1 %

<1 %

<1 %

Update", Indian Journal of Otolaryngology and Head & Neck Surgery, 2019

Publication

20

repozitorij.mef.unizg.hr

Internet Source

<1 %

21

bmcproc.biomedcentral.com

Internet Source

<1 %

22

Baiq Ratna Kumaladewi, Willy Sandhika, Heryawati Heryawati. "Role of CD44 and CD8 in Colorectal Adenocarcinoma metastatic", Medical Laboratory Technology Journal, 2020

Publication

<1 %

23

Jin-Gu Lee, Sun-Hye Lee, Dae-Weon Park, Yoe-Sik Bae, Sung-Su Yun, Jae-Ryong Kim, Suk-Hwan Baek. "Phosphatidic acid as a regulator of matrix metalloproteinase-9 expression via the TNF- α signaling pathway", FEBS Letters, 2007

Publication

<1 %

24

Qing Zhang, Xinguo Chen, Jun Zhou, Li Zhang, Qingchuan Zhao, Guangsheng Chen, Jing Xu, Qiang Feng, Zhinan Chen. "CD147, MMP-2, MMP-9 and MVD-CD34 are significant predictors of recurrence after liver transplantation in hepatocellular carcinoma patients", Cancer Biology & Therapy, 2014

Publication

<1 %

25

"Abstracts", Virchows Archiv, 2008

Publication

<1 %

26

Dake Chu, Zhengwei Zhao, Yi Zhou, Yunming Li, Jipeng Li, Jianyong Zheng, Qingchuan Zhao, Weizhong Wang. "Matrix Metalloproteinase-9 Is Associated with Relapse and Prognosis of Patients with Colorectal Cancer", Annals of Surgical Oncology, 2011

Publication

<1 %

27

Emmy Pramesthi Dyah Soelistijani, Nyilo Purnami, M. S. Wiyadi. "The Association Between Cochlear and Retrocochlear Disorders with Tinnitus with Normal Hearing Thresholds", Indian Journal of Otolaryngology and Head & Neck Surgery, 2018

Publication

<1 %

28

Slamet Suwondo, Bakti Surarso, Iwan Kristyono. "Biopsy Examination Validity Based on Narrow Band Imaging Guidance of Nasopharyngeal Carcinoma Suspected Patients", Indian Journal of Otolaryngology and Head & Neck Surgery, 2018

Publication

<1 %

29

Sullu, Y.. "Matrix metalloproteinase-2 (MMP-2) and MMP-9 expression in invasive ductal carcinoma of the breast", Pathology - Research and Practice, 20111215

Publication

<1 %

30

Tian Huang, Mao-Huai Chen, Ming-Yao Wu, Xian-Ying Wu. "Correlation between Expression of Extracellular Matrix Metalloproteinase Inducer and Matrix Metalloproteinase-2 and Cervical Lymph Node Metastasis of Nasopharyngeal Carcinoma", *Annals of Otolaryngology & Laryngology*, 2013

Publication

<1 %

31

Yi-Yu Tsai, Chun-Chi Chiang, Kun-Tu Yeh, Huei Lee, Ya-Wen Cheng. "Effect of TIMP-1 and MMP in Pterygium Invasion", *Investigative Ophthalmology & Visual Science*, 2010

Publication

<1 %

32

ir.unimas.my

Internet Source

<1 %

33

ndltd.ncl.edu.tw

Internet Source

<1 %

34

Chen, Su-Zuan, Huai-Qi Yao, Sen-Zhi Zhu, Qiu-Yuan Li, Guang-Hua Guo, and Jing Yu. "Expression levels of matrix metalloproteinase-9 in human gastric carcinoma", *Oncology Letters*, 2014.

Publication

<1 %

35

H. Yamamoto. "Association of matrilysin-2 (MMP-26) expression with tumor progression and activation of MMP-9 in esophageal

<1 %

squamous cell carcinoma", Carcinogenesis,

06/24/2004

Publication

36

Inuzuka, K.. "Significance of Coexpression of Urokinase-type Plasminogen Activator, and Matrix Metalloproteinase 3 (Stromelysin) and 9 (Gelatinase B) in Colorectal Carcinoma", Journal of Surgical Research, 200010

Publication

37

academic.oup.com

Internet Source

<1 %

38

hdl.handle.net

Internet Source

<1 %

39

ouci.dntb.gov.ua

Internet Source

<1 %

40

runa.sergas.es

Internet Source

<1 %

41

www.mdpi.com

Internet Source

<1 %

42

www.thieme-connect.com

Internet Source

<1 %

43

Dake Chu, Zixi Zhang, Yunming Li, Jianyong Zheng, Guanglong Dong, Weizhong Wang, Gang Ji. "Matrix metalloproteinase-9 is associated with disease-free survival and

<1 %

overall survival in patients with gastric cancer", International Journal of Cancer, 2011

Publication

44

Nikhil I. Khushalani. "Matrix Metalloproteinases in Gastric Cancer", Proteases In Biology and Disease, 2006

Publication

<1 %

45

OZDEMIR, E.. "ROLE OF MATRIX METALLOPROTEINASE-9 IN THE BASEMENT MEMBRANE DESTRUCTION OF SUPERFICIAL UROTHELIAL CARCINOMAS", The Journal of Urology, 199904

Publication

<1 %

46

Diana Schveigert, Konstantinas Povilas Valuckas, Viktorija Kovalcis, Albertas Ulys, Genovefa Chvatovic, Janina Didziapetriene. "Significance of MMP-9 expression and MMP-9 polymorphism in prostate cancer", Tumori Journal, 2018

Publication

<1 %

47

Hui Li, Kun Zhang, Li-hong Liu, Yurong Ouyang, Jie Bu, Hong-bin Guo, Tao Xiao. "A systematic review of matrix metalloproteinase 9 as a biomarker of survival in patients with osteosarcoma", Tumor Biology, 2014

Publication

<1 %

Exclude quotes On

Exclude matches Off

Exclude bibliography On

Matrix Metalloproteinase-9 Expression and Status of Cervical

GRADEMARK REPORT

FINAL GRADE

/100

GENERAL COMMENTS

Instructor

PAGE 1

PAGE 2

PAGE 3

PAGE 4

PAGE 5

PAGE 6
