

# Nasoethmoid-nasoorbital encephalocele presenting with orbital pulsation

*by* Muhammad Parenrengi

---

**Submission date:** 29-Nov-2018 11:26AM (UTC+0800)


**Submission ID:** 1046843849

**File name:** -nasoorbital\_encephalocele\_presenting\_with\_orbital\_pulsation.pdf (2.2M)

**Word count:** 1102

**Character count:** 6172

## Nasoethmoid-nasoorbital encephalocele presenting with orbital pulsation

Wihasto Suryaningtyas<sup>1</sup>  · Muhammad Arifin<sup>2</sup> · Abdul Hafid Bajamal<sup>1</sup>

Received: 26 May 2017 / Accepted: 8 June 2017 / Published online: 22 June 2017  
© Springer-Verlag GmbH Germany 2017

Dear Editor,

Encephalocele, a herniation of cranial contents beyond the normal confines of the skull, is usually classified according to the location of the skull defect [1]. Suwanwela and Suwanwela classified encephaloceles into four types, which are divided further into subtypes. Frontoethmoidal encephaloceles (FEE) type has subtypes of nasofrontal (NF), nasoethmoidal (NE), and nasoorbital (NO) [2]. Mahatumarat added “combined” subtype, defined as combination of nasoethmoidal and nasoorbital subtype [3]. Nasoorbital type is of the most infrequent type among others. The content may comprised of meninges and cerebrospinal fluid (CSF), meninges and brain parenchyma, combination of both, or involving part of the ventricle. The clinical presentation of NO FEE includes mass in the orbit, displacement of the eye, and interorbital hypertelorism. Anophthalmia or microphthalmia may occur. The authors describe cases of NE-NO, presenting with clinical sign of pulsating orbits.

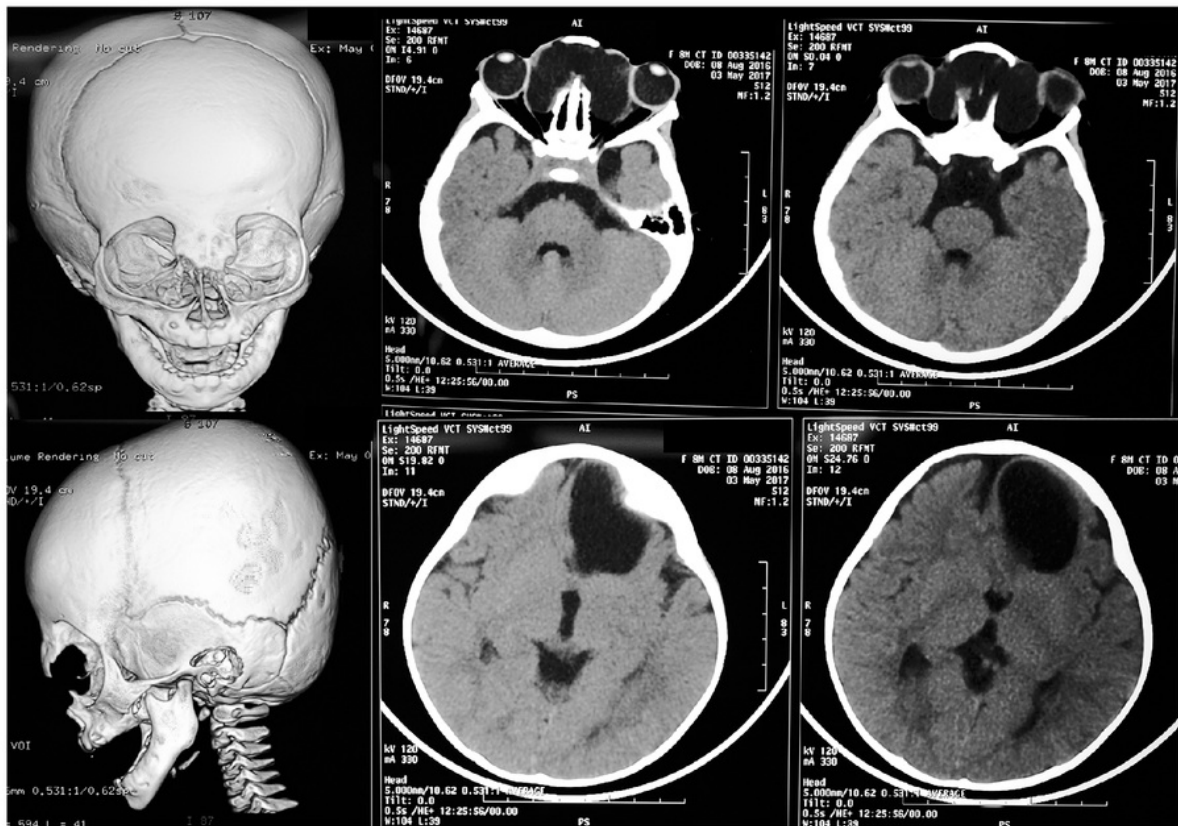
A 10-month-old girl came to our attention because of small sessile mass on the nose, laterally displaced eyeballs, strabismus, and pulsating orbits. The skin was intact with pale red wine stain. No sign of infection or epiphora was found. We had difficulty on assessing the visual acuity. The finding that she still followed when we moved object in front of her eyes gave us impression that she had normal vision at least on one eye. A computed tomography (CT) scan of the head study

showed a nasoethmoidal and bilateral nasoorbital meningoceles with the presence of CSF-containing sac protruding through defect of ethmoid bone and medial orbital wall (Fig. 1). The CSF sac was connected to a medium-sized temporal-frontal arachnoid cyst. The temporal arachnoid cyst was at close contact with the prepontine cistern. Three-dimension bony reconstruction of CT scan showed a bone defect on the anterior part of both medial orbital bones and a widened nasal bone causing interorbital hypertelorism (Fig. 1). A magnetic resonance imaging was not performed due to financial reason from charity foundation. She underwent surgery to remove the meningoceles, dura closure, and nasal reconstruction. We employed a transfacial approach with an inverted Y incision over the mass. During the procedure, we found a 3-cm-wide nasal bone with laterally displaced anterior canthal ligaments. The dural sac was dissected from adjacent tissue. Subfrontal osteotomy was performed as a standard technique in our institution. After carefully opening the dural sac, we found a CSF-containing sac with subarachnoid lining. On opening the subarachnoid, no brain parenchyma was identified. The dura was then closed in a watertight fashion. Nasal reconstruction took place with reduction of the nasal width to 2 cm. The one-stage operation was done uneventful. Postoperatively, the strabismus of the right eye still persisted, the movement of the other eye was unaltered, and the orbital pulsation was hardly seen.

Being one of Southeast Asian countries, we enjoyed treating enormous amount of frontoethmoidal encephaloceles. In the last 7 years, 350 cases were treated that consisted of NE in 86% cases, NF in 9.4% cases, NO in 3.4%, and combined NE-NO in 1.2%. Surgical procedures, using Chula and modified Chula techniques, was comprised of encephalocele excision, closure of the dura and bony defect, and nasal reconstruction. Sixty of our cases had intracranial abnormalities including ventricular malformation (50%), hydrocephalus

✉ Wihasto Suryaningtyas  
w\_hasto@yahoo.co.uk

<sup>2</sup> Department of Neurosurgery, Airlangga University Faculty of Medicine – Dr. Soetomo General Hospital, Gedung Pusat Diagnostik Terpadu (GDC) Lantai 5, RSUD Dr. Soetomo, Jl. Mayjen, Prof Moestopo 6-8, Surabaya, Indonesia



**Fig. 1** Pre-operative CT scan with 3D reconstruction: external bony defect in NE and NO (upper and lower left) and CSF-containing sac in NE-NO encephaloceles (middle and right)

(8%), porencephalic cyst (20%), arachnoid cyst (12%), and others (10%). This is the second case of orbital pulsation due to NO encephaloceles with arachnoid cyst connected to the external sac. Both encephaloceles with orbital pulsations showed a medium- to large-sized CSF-containing sac connected to intracranial cyst and had a large-bore exit pathways containing mostly CSF. Other 12 cases of NO type FEE in our series that contained gliotic mass or brain parenchyma showed very weak or no pulsation on their orbit. These recent findings of orbital pulsation may be explained by the nature of CSF pulsatile circulation and different displacement magnitude from different intracranial entities. The connection between the extracranial sac and the intracranial subarachnoid space (SAS) allows the theory of the pulsatile nature of CSF to be applied. Greitz and colleagues concluded that SAS could be divided into five compartments depending on the magnitude of the pulsatile CSF flows: a high-velocity compartment in the area of the brain stem and spinal cord, two slow ones at the upper and lower extremes of the SAS, and two intermediate-velocity compartments in between [4]. The interconnection of meningoceles sac-arachnoid cyst-prepontine cistern obviously played a role in the high pulsatility as the waveform from

high-velocity compartment was easily transmitted via watery fluid. In gliotic brain or brain parenchyma, the transmission of pulsatile CSF depends on the distance from the ventricular system. The tissue surrounding the lateral ventricle has the most displacement while those near the skull experience almost zero displacement [5]. The density of the cortex is higher than the white matter. High-density tissue, such as gliotic brain, will be less affected by the pulsation and has a higher impedance to transmit a pulsatile waveform.

In conclusion, the pulsatile orbit can be utilized to assess the type, content, and extra-intracranial nature of FEE.

## 2 Compliance with ethical standards

**Conflict of interest** No conflict of interests.

## References

1. Hoving EW (2000) Nasal encephaloceles. *Childs Nerv Syst* 16:702–706
2. Suwanwela C, Suwanwela N (1972) A morphological classification of sincipital encephalomeningoceles. *J Neurosurg* 36:201–211

3. Mahatumarat C, Rojvachiranonda N, Taecholarn C (2003) Frontoethmoidal encephalomeningocele: surgical correction by the Chula technique. *Plast Reconstr Surg* 111:556–567. doi:[10.1097/01.PRS.0000040523.57406.94](https://doi.org/10.1097/01.PRS.0000040523.57406.94)
4. Greitz D, Franck A, Nordell B (1993) On the pulsatile nature of intracranial and spinal CSF-circulation demonstrated by MR imaging. *Acta Radiol* 34:321–328. doi:[10.1080/02841859309173251](https://doi.org/10.1080/02841859309173251)
5. Masoumi N, Framanzad F, Zamanian B et al (2013) 2D computational fluid dynamic modeling of human ventricle system based on fluid-solid interaction and pulsatile flow. *Basic Clin Neurosci* 4:64–75

# Nasoethmoid-nasoorbital encephalocele presenting with orbital pulsation

## ORIGINALITY REPORT

15%

SIMILARITY INDEX

8%

INTERNET SOURCES

15%

PUBLICATIONS

0%

STUDENT PAPERS

## PRIMARY SOURCES

- 1** D. Greitz. "On the Pulsatile Nature of Intracranial and Spinal CSF-Circulation Demonstrated by MR Imaging", Acta Radiologica, 07/01/1993 **4%**

Publication
- 2** Wihasto Suryaningtyas, Muhammad Arifin, Agus Turchan, Abdul Hafid Bajamal. "Development of pediatric neurosurgical service at Dr. Soetomo Hospital, Surabaya, Indonesia", Child's Nervous System, 2017 **4%**

Publication
- 3** Eelco W. Hoving. "Nasal encephaloceles", Child's Nervous System, 11/21/2000 **2%**

Publication
- 4** Secci, Francesca, Alessandro Consales, Paolo Meriadri, Giuseppe Marcello Ravegnani, Gianluca Piatelli, Marco Pavanello, and Armando Cama. "Naso-ethmoidal encephalocele with bilateral orbital extension: report of a case in a western country", Child's **2%**

# Nervous System, 2013.

Publication

5

"Contents", British Journal of Plastic Surgery, 1996

Publication

1%

6

Min-Kyo Chun, Tae-Hoon Eom, Gye-Yeon Lim, Jung-Min Kim. "Secondary trigeminal neuralgia attributed to paranasal sinusitis in a pediatric patient", Child's Nervous System, 2017

Publication

1%

7

Ailing Guo, Vigneyshwar Suresh, Xianzhi Liu, Fuyou Guo. "Clinicopathological features and microsurgical outcomes for giant pediatric intracranial tumor in 60 consecutive cases", Child's Nervous System, 2017

Publication

<1%

Exclude quotes On

Exclude matches Off

Exclude bibliography On

# Nasoethmoid-nasoorbital encephalocele presenting with orbital pulsation

---

## GRADEMARK REPORT

---

FINAL GRADE

**/100**

GENERAL COMMENTS

**Instructor**

---

PAGE 1

---

PAGE 2

---

PAGE 3

---