

# Emphysematous Pyelonephritis In Patient With Diabetes And Renal Cell Carcinoma, A Case Report

*by* Wahjoe Djatisoesanto

---

**Submission date:** 12-Sep-2019 02:01PM (UTC+0800)

**Submission ID:** 1171288735

**File name:** atient\_With\_Diabetes\_And\_Renal\_Cell\_Carcinoma,\_A\_Case\_Report.pdf (2.09M)

**Word count:** 2397

**Character count:** 13237

# EMPHYSEMATOUS PYELONEPHRITIS IN PATIENT WITH DIABETES AND RENAL CELL CARCINOMA, A CASE REPORT

Bambang Soeprijanto<sup>1</sup>, Wahjoe Djatisoesanto<sup>2</sup> and Ety Hary Kusumastuti<sup>3</sup>

<sup>1</sup>Department of Radiology, Faculty of Medicine, University of Airlangga - Sutomo Hospital. Surabaya.

<sup>2</sup>Department of Urology, Faculty of Medicine, University of Airlangga - Sutomo Hospital. Surabaya.

<sup>3</sup>Department of Pathology, Faculty of Medicine, University of Airlangga - Sutomo Hospital. Surabaya.

## ABSTRACT

Emphysematous pyelonephritis (EPN) usually happens in diabetes. It is reported a correlation between the Renal Cell Carcinoma (RCC) with diabetes. This is a rare case of PEN and RCC in diabetes which occur simultaneously. We present a case of 51 year old male referred with right flank mass and medical history of diabetic disease. Renal ultrasound revealed a solid tumor at the upper pole of the right kidney. Plain abdominal X-ray showed a lot of gas, fecal material, and patches of calcification in the right upper abdomen. On abdominal computed tomography found a collection of gas located in the upper right abdomen. An irregular solid tumor detected at the upper pole of the right kidney. The tumors was obtained at surgery and emphysematous pyelonephritis was found and then nephrectomy performed. Histopathological examination revealed a Renal Cell Carcinoma besides emphysematous pyelonephritis. The patient had no postoperative serious complications during his hospital stay and his symptoms resolved completely. We report the rare case with an occurrence of EPN and RCC simultaneously in diabetes.

**Keywords:** Emphysematous pyelonephritis, diabetes, renal cell carcinoma, escheria coli, Fuhrman grading system.

## INTRODUCTION

Emphysematous pyelonephritis (EPN) is necrotizing infection of the renal parenchyma, collecting system and perirenal space, as a result of the presence microorganism that produce gas, and is usually found in diabetic patient. This condition is supported by decreasing of immune response, the presence of high blood glucose levels in diabetic patient and ischemia in the area of infection. This is severe potentially fatal disease, can result in renal damage and has a high mortality rate.<sup>1,2,3</sup> EPN was associated with a mortality rate of up to 78% until the late 1970s and primarily attributable to septic complications.<sup>3</sup>

Renal cell carcinoma (RCC) also known as hypernephroma, Grawitz tumor, renal

adenocarcinoma is a kidney cancer that originates in the lining of the proximal convoluted tubule. The risk factors for RCC are lifestyle-related; smoking, obesity and hypertension.<sup>4</sup> Genetically linked conditions also increase the risk of RCC, including hereditary papillary renal carcinoma, hereditary leiomyomatosis, Birt-Hogg-Dube syndrome, hyperparathyroidism-jaw tumor syndrome, familial papillary thyroid carcinoma, von Hippel-Lindau disease and sickle cell disease.<sup>5</sup>

Diabetes mellitus (DM), commonly referred to as diabetes, is a group of metabolic diseases in which there are high blood sugar levels over a prolonged period. It is reported a positive association between diabetic patient and risk of RCC. There is also a correlation between the severity and duration of diabetes with the risk of developing RCC.<sup>6</sup>

27

We present a rare case of EPN in patient with uncontrolled diabetes and suffered RCC, that was treated with antibiotic, open drainage, and right nephrectomy.

29

## CASE PRESENTATION.

A 51 year old man was referred from a small town hospital, with a mass in the right flank area, with general condition was worsened. The patient had main complaint of right abdominal discomfort since two years ago. He experienced symptom of right low back pain, decreased of weight, and constipation since 8 month ago. He suffered from diabetes for some year, with uncontrolled medical treatment. Before referred, the patient had been given antibiotic and treated for diabetic regulation.

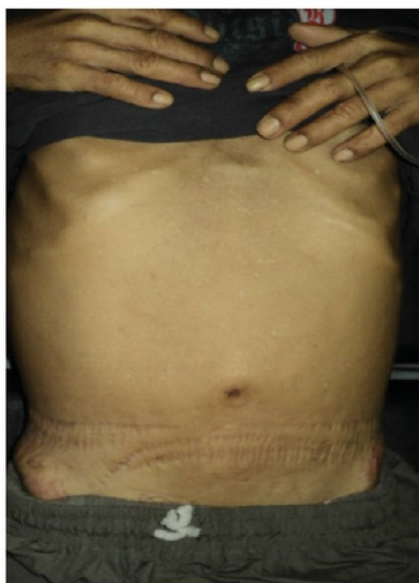

Figure 1. A slightly underweight man with slight distension of the upper abdomen.

Physical examination on admission revealed a man who appears sick, slightly underweight, with slight distension of the upper abdomen. Body weight is 50 kilograms and height is 157cm, and looks somewhat anemic patients. A mobile and lobulated mass was palpable in the right upper abdomen, approximately 10x8cm in size.

Vital signs showed signs of temperature (axillary) of 37.2°C, heart rate 96 beats per minute, blood pressure 110/60 mmHg, and respiratory rate 22 breaths per minute. Urine production was 1,600 ml per 24 hours.

Laboratory test revealed hemoglobin was 9.42 g/dl, a white blood cell count 5,250/mm<sup>3</sup>, platelet count 382,000/mm<sup>3</sup>, creatinine level 0.5 mg/dl, urea 10 mg/dl and albumin serum 2.59 g/dl. Fasting blood glucose level was 115 mg/dl and 2 hours postprandial blood sugar test was 149 mg/dl. Urine test showed pH of 7, red blood cells was 250 ul, white blood cells 500 ul and negative bacterial cultures.

Abdominal ultrasound (US) examination showed a hyperechoic, lobulated, unhomogenous tumor (95x67x45 mm) in the upper pole of the right kidney. Some hyperechoic patches lesions with acoustic shadow found and calcification was suspected. Plain abdominal X-ray (AXR) showed many fecal material mixed with air which covered right nephrogram. There were patches calcification of the right upper quadrant, the largest is 1cm. Abdominal computed tomography (CT) with contrast medium administration in the gastrointestinal system showed air collection overlaps with the upper pole of the right kidney. A lobulated solid tumors, approximately 10x8x5 cm in size, with patches of calcification was found in the right kidney.

After the regulation of blood sugar levels and improve general condition, surgical intervention performed. Upper pole of the right kidney appeared large, approximately 10x10x9 cm in size, with pus 300cc inside. There was a fragile tumor in the upper pole of the right kidney and attached to the posterior abdominal wall. The lower pole of the right kidney appeared normal. Radical nephrectomy was performed and the tumor was taken out. Drainage maintenance and blood and urine cultures was done.

On gross pathology examination found a mass with 9x8x7 cm in size, on the upper pole of right kidney. Histopathology examination revealed RCC, stage I and Fuhrman grade I. Cultures from the blood and urine sample showed colony of Escherichia Coli. The patient had no postoperative

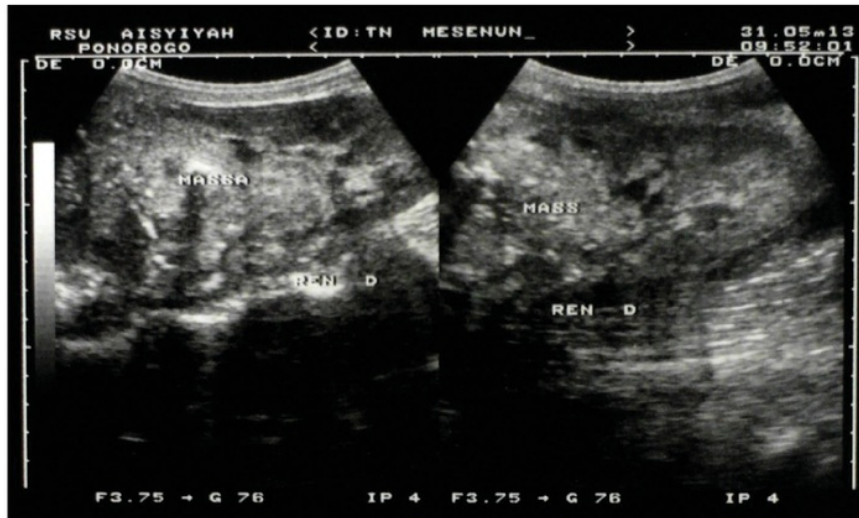


Figure 2. Longitudinal scan of the right kidney showing an heterogenic solid mass with irregular borders.

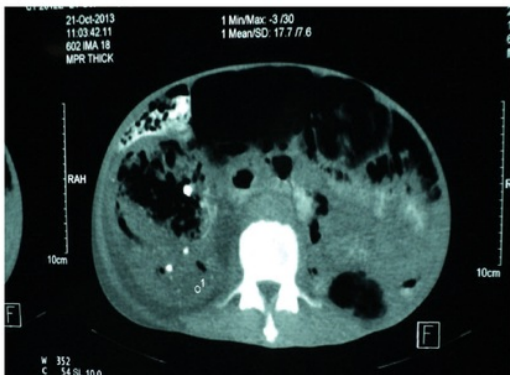


Figure 3. Gas with some fecal material and multiple calcification detected on Abdominal CT-Scan at upper right quadrant area.

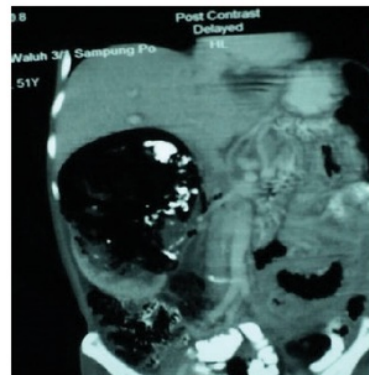


Figure 5. Reformatted coronal CT showing gas and calcification in the right renal parenchyma extending into perinephric space.

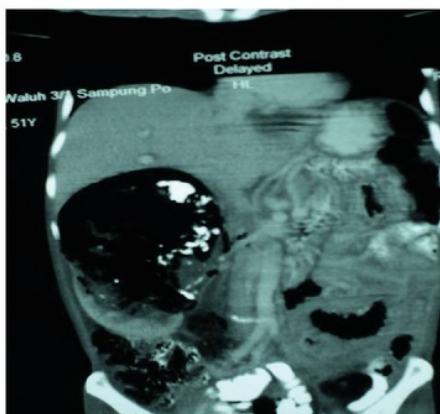


Figure 4. Computed tomographic scan showing right renal enlargement and presence of air in the renal parenchyma with some calcifications.

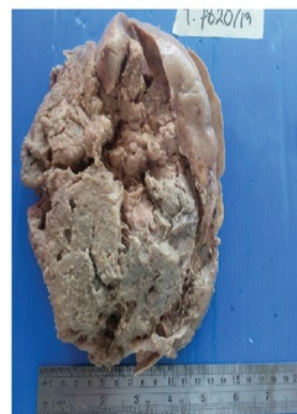

Figure 6. A resected right kidney with tumor inside and invade to the renal parenchyma.

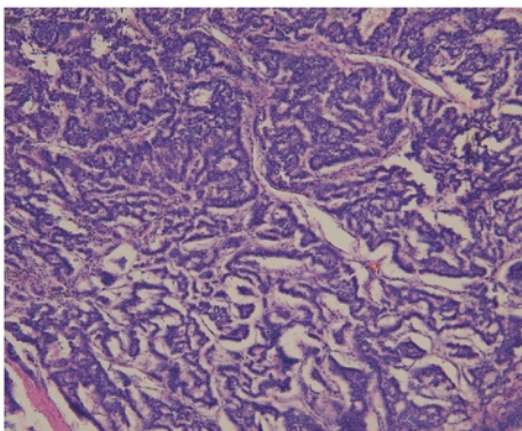


Figure 7. Histologic appearance of a RCC of the right kidney: the neoplastic cells have clear cytoplasm and are arranged in nests with intervening blood vessels.

serious complications during his hospital stay and his symptoms resolved completely.

## DISCUSSION

The first case of emphysematous pyelonephritis (EPN) was reported by Kelly and MacCullum in 1898. In 1962 Schultz and Klorfein proposed name emphysematous pyelonephritis, because it emphasizes the relationship between acute kidney infection and the formation of gases. The most frequent pathogens were *Escherichia coli* (70%), followed by *Klebsiella pneumoniae* (29%) and *Proteus*. These bacteria ferment the sugar in the urine and produces gases, including nitrogen, hydrogen, carbon dioxide, and oxygen. EPN is almost occurred in 90% people with diabetes.<sup>2,3,7</sup> Findings of the type of bacteria and the presence of diabetes in this case report is in agreement with previous literature reports.

Many factors have been implicated at the pathogenesis of EPN, including gas-forming bacteria, high tissue glucose level (favoring rapid bacterial growth), impaired tissue perfusion (diabetic nephropathy leads to further compromise regional oxygen delivery in the kidney resulting in tissue ischemia and necrosis; nitrogen released during tissue necrosis) and a defective immune response due to impaired vascular supply. Intrarenal thrombi and renal infarctions have been

claimed to be predisposing factors in non-diabetic patients.<sup>8</sup> The presence of space occupying lesions due to tumor in the right kidney and a risk of the presence of a tumor thrombus in this case will further increase the possibility of EPN.

There is a relationship between diabetes with RCC, with regard to age, gender, ethnicity, HaemoglobineA1c (HgA1C), glucose levels and renal function. There are several mechanisms of kidney cancer in diabetic among other growth factors or their receptors and hyperinsulinemia and high glucose levels. Severity and duration of diabetes correlated with the risk of RCC. HgA1C can be used as a marker for early detection of diabetic RCC prior to clinical manifestation. In the majority of RCC associated with somatic mutations of tumor suppressor gene Von Hippel-Lindau (VHL) syndrome. This will activate hypoxia-inducible factor-1 (HIF-1), which causes an increase in transcription of pro-angiogenic factors including Platelet-derived growth factor (PDGF) and Vascular endothelial growth factor (VEGF), which plays a role in renal cell tumorigenesis.

Other pathogenetic mechanisms that explain the occurrence of RCC in diabetes is the presence of prolonged exposure to the pro-insulin product with some homology to insulin-like growth factor-1 (IGF-1), increasing the growth factors and growth factor receptors, as well as increased levels of endogenous estrogen, resulting in end-stage renal disease due to diabetic nephropathy.<sup>4</sup> In this case, the patient suffered with diabetes for long time ago and at the physical examination was suspected of right kidney tumor.

Abdominal US is limited if the patient is obese or has an excessive amount of air in the intestinal loops. Renal US can confirm the presence of EPN in approximately 80% of cases, whereas CT is more sensitive.<sup>7</sup> In this case, Renal US was not able to demonstrate the accumulation of gas, because US is not good in the depiction the presence of gas. Thus, a CT scan is mandatory to diagnose EPN if suspicion of EPN is high.<sup>2,3,9</sup>

Two staging systems, based on CT findings, have been proposed for prognostic and therapeutic reasons. The first staging system classified in two types, the type I is included patients showing

4 parenchymal destruction with streaky or mottled gas but with no fluid collection. These patients had a mortality rate of 69%. Type II patients had renal or perirenal fluid collections that contained bubbly or loculated gas or gas within the collecting system. The mortality rate in this group was 18%. Another classification is in four classes. In class 1 gas was limited in the collecting system. In class 2, gas was in the renal parenchyma without extension to the extrarenal space. In class 3A, gas extended to the perinephric space, in class 3B, to the pararenal space. Class 4, was referred to bilateral emphysematous pyelonephritis or a solitary kidney with emphysematous pyelonephritis.<sup>2,3,7</sup> Some researchers also reported that the mortality rate increased markedly (92% vs 53%) in patients with a serum creatinine level >1.4 mg/dL and thrombocytopenia platelets <60,000/mm<sup>3</sup> (2). The finding of pus in the kidney, collecting system and accompanied with perirenal abscess in this case is in accordance with the class 3A.

3 The class 1 and class 2 EPN could be managed with percutaneous drainage and antibiotics. In class 3 and class 4 EPN, the presence of fewer with two risk factors (thrombocytopenia, acute renal failure, stupor/coma and shock) indicated that percutaneous drainage and antibiotics could be used (successful in less than 64% of cases). However, in the presence of three or more of the above risk factors, nephrectomy yielded better results.<sup>2,3,10</sup> In this case, nephrectomy performed because of the presence of a large tumor which resulted in extensive damage to the right kidney and a lot of pus was found. Nephrectomy was done to prevent the occurrence of septic shock, severe sepsis or multi-organ dysfunction syndrome.

## CONCLUSION

EPN is a condition which carries major morbidity and significant mortality. Early diagnosis and immediate therapy are imperative for positive outcome. Even though imaging is the most reliable diagnostic modality, the initial management of any patient with emphysematous pyelonephritis is resuscitation. When conservative treatment fails, surgery should be considered without delay.

Another advantage of the surgery is that the diagnosis of malignancy could be detected after performed nephrectomy and histopathologic examination.

## Acknowledgement:

Authors are thankful to Dr. Soetomo Hospital, Surabaya, Indonesia, for providing any facilities.

## REFERENCES

1. Stofilas A, Manouras A, Lagoudianakis EE, Kotzadimitriou A, Pappas A, Chyrisikos I, Menenakos E. Emphysematous Pyelonephritis, a rare cause of pneumoperitoneum: a case report and review of literature. *Cases Journal*. 2008;1:91. Doi:10.1186/1757-1626-1-91.
2. Adli OEY, Ammari JEE, Elfassi MJ, Farih MH. Extensive emphysematous pyelonephritis leading to renal destruction. *African Journal of Urology*. 2012, 18(2): 87–89.
3. Ubee SS, McGlynn L, and Fordham M. Emphysematous pyelonephritis. *BJU International*. 2010; 107: 1474-1478.
4. Häggström C, Kilian R; Stocks T; Manjer J, Børge T, ; Ulmer H et al. Metabolic Factors Associated with Risk of Renal Cell Carcinoma. *Plos ONE* 8(2): e57475. Bibcode 2013PLoS. 857475H doi 10.1371/journal.pone.0057475. PMC 3585341. PMID 23468995.
5. Pavlovich PC.; Schmidt LS. Searching for the hereditary causes of renal-cell carcinoma.. *Nature Reviews Cancer*. 2004;4 (5): 381–93. doi:10.1038/nrc1364.PMID 15122209
6. Habib SL, Prihoda TJ, Luna M, Werner SA. Diabetes and risk of Renal Cell Carcinoma. *J Cancer*, 2011; 3: 42-48.
7. Tanagho YS, Mobley JM, Benway BM, and Desai AC. Gas-Producing Renal Infection Presenting as Pneumatouria: A Case Report. *Case Reports in Medicine*, 2013: 2013- 2016. Article ID 730549.
8. Huang JJ, Tseng CC: Emphysematous pyelonephritis: clinicroadiological

classification, management, prognosis, and pathogenesis. Arch Intern Med, 2000;160 (6):797-805.

9. Hui SY, Cheung CW, Hui KT, She HL. Sonographic diagnosis of emphysematous pyelonephritis in a clinically stable patient. Hong Kong Med J, 2010;16 (4) www.hkmj.org
10. Fatima R, Jha R, Muthukrishnan J, Gude D, Nath V, Shekhar S, Narayan G, Shina S, Mandal SN, Srinivas Rao B, and Ramsubbarayudu B. Emphysematous pyelonephritis: A single center study. Indian J Nephrol, 2013 : 23(2): 119-124.

# Emphysematous Pyelonephritis In Patient With Diabetes And Renal Cell Carcinoma, A Case Report

---

## ORIGINALITY REPORT

---

**25%**

SIMILARITY INDEX

**18%**

INTERNET SOURCES

**22%**

PUBLICATIONS

**1%**

STUDENT PAPERS

---

## PRIMARY SOURCES

---

- 1** Mahesh Eswarappa, Sarita Suryadevara, Manns Manohar John, Mahesh Kumar, Sujeeth Bande Reddy, Mohammed Suhail. "Emphysematous Pyelonephritis Case Series From South India", *Kidney International Reports*, 2018  
Publication **2%**
  - 2** Ahmed Alansari, Manuel Duran Borrás, Noella Boma. "'I have chicken fat in my urine!' A case of *Candida tropicalis* induced emphysematous pyelitis", *Medical Mycology Case Reports*, 2015  
Publication **2%**
  - 3** [www.emedicine.com](http://www.emedicine.com)  
Internet Source **2%**
  - 4** Badar , Farheen | Azfar , Shah Farhan | Akhtar , Nishat. "Diabetic Women with Fever and Right Flank Pain \ \ *Oman Medical Journal* .- 2011 , Vol. 26 , No. 2 , pp. 141 - 142.", *Oman Medical Journal*, 2011  
Publication **2%**
-



5	Alper Otunctemur, Emin Ozbek, Suleyman Sahin, Murat Dursun et al. "Diabetes Mellitus as a Risk Factor for High Grade Renal Cell Carcinoma", Asian Pacific Journal of Cancer Prevention, 2014	2%
Publication		
6	us.wow.com	2%
Internet Source		
7	Bernadette Dian Novita, Endang Isbandiati Soediono, Jusak Nugraha. "Metformin Associated Inflammation Levels Regulation In Type 2 Diabetes Mellitus-Tuberculosis Coinfection Patients – A Case Report", Indian Journal of Tuberculosis, 2018	1%
Publication		
8	Bjurlin, M.A.. "Clinical Outcomes of Nonoperative Management in Emphysematous Urinary Tract Infections", Urology, 201206	1%
Publication		
9	www.qqct.jp	1%
Internet Source		
10	link.springer.com	1%
Internet Source		
11	O. El Yazami Adli, J.E. El Ammari, M.J. Elfassi, M.H. Farih. "Extensive emphysematous pyelonephritis leading to renal destruction",	1%

# African Journal of Urology, 2012

Publication

---

12 [www.binglixue.com](http://www.binglixue.com) 1%

Internet Source

---

13 "WORLD TRANSPLANT CONGRESS 2006  
POSTER ABSTRACTS", American Journal of  
Transplantation, 8/2006 1%

Publication

---

14 [www.revoptom.com](http://www.revoptom.com) 1%

Internet Source

---

15 [my.onexamination.com](http://my.onexamination.com) 1%

Internet Source

---

16 [emedicine.medscape.com](http://emedicine.medscape.com) 1%

Internet Source

---

17 M. MALLET. "Emphysematous pyelonephritis:  
no longer a surgical disease?", European  
Journal of Emergency Medicine, 09/2002 1%

Publication

---

18 P. Adithya Malolan, B.S. Shivaswamy, G.  
Rajashekara Babu, C.S. Santhosh. 1%

"Emphysematous pyelonephritis masquerading  
as hollow viscus perforation", African Journal of  
Emergency Medicine, 2014

Publication

---

19 EAPCCT Scientific Committee, . "Abstracts of  
the European Association of Poisons Centres 1%

and Clinical Toxicologists XXII International Congress\*", Journal of Toxicology Clinical Toxicology, 2002.

Publication

20

[profiles.uthscsa.edu](http://profiles.uthscsa.edu)

Internet Source

<1%

21

[journalmc.org](http://journalmc.org)

Internet Source

<1%

22

[www.balimedicaljournal.org](http://www.balimedicaljournal.org)

Internet Source

<1%

23

[www.aacr.org](http://www.aacr.org)

Internet Source

<1%

24

[uthscsa.influent.utsystem.edu](http://uthscsa.influent.utsystem.edu)

Internet Source

<1%

25

[asiassam.org](http://asiassam.org)

Internet Source

<1%

26

Tzung-Hai Yen, Yu Chen, Ja-Liang Lin, Kwai-Fong Ng. "Renal Oncocytoma in Taiwan", Renal Failure, 2009

Publication

<1%

27

Kiran Kumar Singal, Neerja Singal, Bhaskar Gupta, Karun Puran Bhatti, Abhinav Gupta. "Emphysematous pyelonephritis: non surgical treatment approach", Bangladesh Journal of Medical Science, 2015

Publication

<1%

---

28

[mjpath.org.my](http://mjpath.org.my)

Internet Source

<1%

---

29

"Poster : Poster", Journal of Gastroenterology and Hepatology, 2014.

Publication

<1%

---

30

Tanagho, Youssef S., Jonathan M. Mobley, Brian M. Benway, and Alana C. Desai. "Gas-Producing Renal Infection Presenting as Pneumaturia: A Case Report", Case Reports in Medicine, 2013.

Publication

---

<1%

---

Exclude quotes      On

Exclude matches      Off

Exclude bibliography      On

# Emphysematous Pyelonephritis In Patient With Diabetes And Renal Cell Carcinoma, A Case Report

---

## GRADEMARK REPORT

---

FINAL GRADE

**/100**

GENERAL COMMENTS

**Instructor**

---

PAGE 1

---

PAGE 2

---

PAGE 3

---

PAGE 4

---

PAGE 5

---

PAGE 6

---