

# ETV in tuberculous meningitis with hydrocephalus and allergic reaction to VP shunt a case report

*by* Muhammad Arifin Parenrengi

---

**Submission date:** 02-Jan-2020 05:43PM (UTC+0800)

**Submission ID:** 1238999403

**File name:** 2019\_-\_5125-22683-1-PB.pdf (424.29K)

**Word count:** 2422

**Character count:** 13283

## Case Report

# ETV in tuberculous meningitis with hydrocephalus and allergic reaction to VP shunt: a case report

Rohadi M. Rosyidi<sup>1\*</sup>, Bambang Priyanto<sup>1</sup>, Muhammad Arifin Parenrengi<sup>2</sup>

<sup>1</sup>Department of Neurosurgery Medical Faculty of Mataram University, West Nusa Tenggara General Hospital, Mataram Indonesia

<sup>2</sup>Department of Neurosurgery, Medical Faculty of Airlangga University, Dr Sutomo General Hospital, Surabaya, Indonesia

**Received:** 04 June 2018

**Revised:** 04 December 2018

**Accepted:** 08 December 2018

### \*Correspondence:

Dr. Rohadi M. Rosyidi,

E-mail: rha.ns2010@gmail.com

**Copyright:** © the author(s), publisher and licensee Medip Academy. This is an open-access article distributed under the terms of the Creative Commons Attribution Non-Commercial License, which permits unrestricted non-commercial use, distribution, and reproduction in any medium, provided the original work is properly cited.

## ABSTRACT

Hydrocephalus is one of the most common complications of tuberculous meningitis (TBM) occurring in up to 85% of patients with the disease. The placement of a ventriculoperitoneal (VP) shunt is the most common form of treatment for hydrocephalus in tuberculous meningitis (TBM). Although allergic reactions to the silicone in shunt device are very rare, the authors describe a case of silicone allergy causing multiple VP shunt revisions. Alternative choice is endoscopic third ventriculostomy (ETV), but it is debatable. ETV has variable success in these patients and is generally not advisable in patients in the acute stages of the disease. A 19-year-old woman with hydrocephalus in tuberculous meningitis, who had undergone multiple VP shunt revisions, presented with shunt malfunction caused by allergic reaction of the tissue surrounding the shunt tubing. Laboratory examination demonstrated high level IgE, high level ESR, and PCR-TBC Positive, related to the allergic reaction. Patient with ETV success score of 50. Patients received ETV and release VSS Shunt. ETV has success in these patients. VP Shunts complications remain a difficult problem in neurosurgical clinical practice. The most typical complications are mechanical obstruction and infection. Allergy to the silicone shunt tubing is quite rare. Silicone allergy is an even more rare occurrence because of its high biocompatibility and low biological reactivity. It is a challenge for ETV when TBM has difficulty to recognize anatomical landmarks on this patient. It could also consider in patients who have shunt failure and might be a better option than shunt revision.

**Keywords:** Allergic reactions, ETV, hydrocephalus, Tuberculous meningitis, VP Shunt

## INTRODUCTION

Tuberculous meningitis (TBM) is still a very common problem in children and adults in Indonesia. Hydrocephalus is one of the commonest complications of tuberculous meningitis (TBM) occurring in up to 85% of children with the disease.<sup>1,2</sup> It is more severe in children than in adults. It could be either of the communicating type or the obstructive type with the former being more

frequently seen.<sup>1-3</sup> The management of hydrocephalus can include medical therapy with dehydrating agents and steroids for patients in good grades and those with communicating hydrocephalus.<sup>1,4</sup> However, surgery is required for patients with obstructive hydrocephalus and those in poor grades. Surgery can involve either a ventriculo-peritoneal shunt or endoscopic third ventriculostomy (ETV).<sup>1,5</sup>

The placement of a VP shunt is the most common means of treating hydrocephalus. Complications of shunt surgery in patients with TBM and hydrocephalus are high with frequent shunt obstructions and shunt infections requiring repeated revisions.<sup>5</sup> Given the rare incidence of silicone allergy in the general population, complications involving an allergic reaction to the silicone material within the shunt tubing are quite rare.<sup>6</sup> Nevertheless, we report on a case with just such a complication. Alternative choice is endoscopic third ventriculostomy (ETV), but it is debatable. ETV has variable success in these patients and is generally not advisable in patients in the acute stages of the disease.<sup>7</sup>

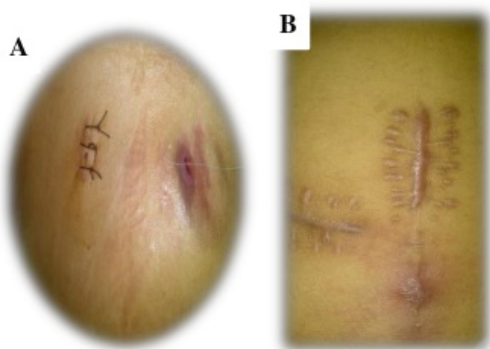
**CASE REPORT**

A 19-year-old woman with hydrocephalus in tuberculous meningitis, who had undergone multiple VP shunt revisions, presented with shunt malfunction caused by allergic reaction of the tissue surrounding the shunt tubing. During the 5 years previous to his presentation, the patient had been hospitalized and undergone surgery five times for shunt malfunction. The patient had undergone VP shunt revision 4 times and Ventriculosinus Sagitalis (VSS) shunt as much as 1 times, but all show an allergic reaction (Table 1).

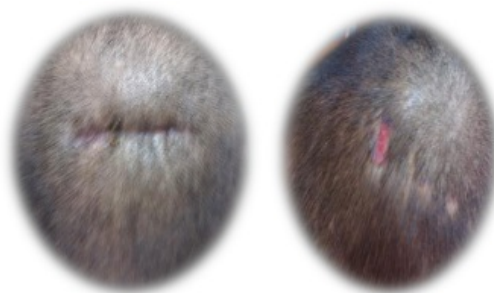**Table: Shunt revisions undertaken the patients from 2009 to 2013.**

Date	Presenting Symptom	Diagnosis	Procedure
06/27/2009	Headache and lethargy	Hydrocephalus communicans-MTB Distal Obstruction	Shunt extraction VP shunt in right keen point
03/23/2013	Headache and Abdominal pain Expose Shunt	Distal Obstruction and Expose Shunt	Shunt Extraction VP Shunt in Left Kocher Point
06/24/2013	Headache and Abdominal pain Expose Shunt	Expose Shunt	Shunt Ligation- Shunt Extraction
06/29/2013	Headache and Abdominal pain Expose Shunt	Expose Shunt	Shunt Extraction VP Shunt in Left Kocher Point
07/23/2013	Headache and Abdominal pain Expose Shunt	Distal Obstruction and Expose Shunt	Shunt Extraction Ventriculosinus sagitalis Shunt (VSS Shunt)

Physical examination: General condition enough, BLOOD pressure 120/80mmHg, HR 96x/minute, RR 20x/minute, afebris, status neurologis: GCS 15, pupil round equal 3/3 light reflex +/+, without hemipareses. status Lokalis in shunt tract: wound eritema, dehiscence (+) (Figure 1), in scalp after VSS shunt: wound eritema, dehiscence (+) (Figure 2).



**Figure 1: A) Thorax region: dehiscence and eritema; B) Abdomen region: eritema.**



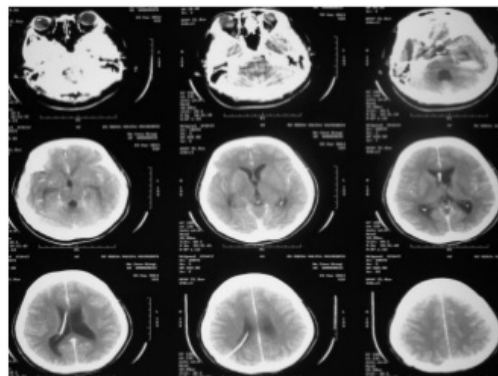
**Figure 2: After VSS shunt: scalp eritema and dehiscence.**

Head CT Scan with contrast related to hydrocephalus and meningoencephalitis TBC (Figure 3).

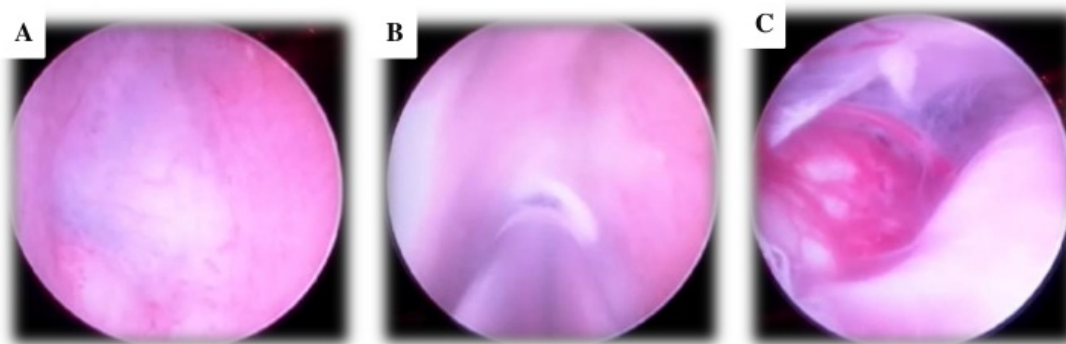
Laboratory examination demonstrated high level IgE (324.7), high level ESR (51), and PCR-TBC Positive, related to the allergic reaction. On each admission, the patient's CSF culture as well as those from the ventricular and peritoneal catheter tips had been negative for infection. A Workup prior to two of her operations on June, 29, 2013 and July, 25, 2013, included detailed

investigations of blood, urine, sputum, and CSF culture for aerobic and anaerobic microbes; all results were negative. Patient with ETV success score of 50. Alternative choice is endoscopic third ventriculostomy (ETV). Patients received ETV and release VSS shunt, During ETV procedure. A. Floor 3<sup>rd</sup> ventricle become thick and difficult to ventriculostomy (Figure 4).

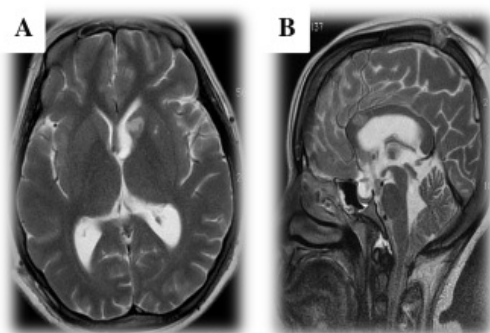
ETV has success in these patients. She tolerated the procedure well, the erythema along the old shunt track also resolved, and quickly improved clinical condition. Post operative head magnetic resonance imaging demonstrated ventricular size diminished in a case but did not reach normal size, and transependymal cerebrospinal fluid absorption disappeared where previously present. MRI demonstration of the CSF flow through the third ventricle floor (Figure 5). The patient was discharged home in stable condition.



**Figure 3: Head CT scan with contrast: enhancing in basal region, related to meningoencephalitis TBC.**



**Figure 4: During ETV procedure. A) Floor 3<sup>rd</sup> ventricle become thick, B) Ventriculostomy, C) The Lilquist membrane, basilar artery and its branches be visible.**



**Figure 5: Head MRI post ETV procedure. A) Axial T2 demonstrated ventricular size diminished in a case but did not reach normal size, B) Sagittal T2 MRI demonstration of the CSF flow through the third ventricle floor.**

### DISCUSSION

Complication of VP Shunts and VSS shunts remain a difficult problem in neurosurgical clinical practice. The most typical complications are mechanical obstruction and infection. Allergy to the silicone shunt tubing is quite rare. Silicone allergy is an even more rare occurrence because of its high biocompatibility and low biological reactivity. The first cases of silicone allergy were encountered with the use of silicone stents, which involved local inflammation and granuloma formation. Although the underlying cause of a silicone allergy is still not well understood, patients who have either undergone multiple surgical procedures or been exposed to silicone on a long-term basis may have higher level of risk, sequelae of silicone allergy include gastrointestinal perforation and skin breakdown over the shunt tubing due to tissue irritation and inflammation.<sup>1,5-7</sup>

Alternative choice is endoscopic third ventriculostomy (ETV), but it is debatable. ETV has variable success in these patients and is generally not advisable in patients in the acute stages of the disease. Since the popularization of endoscopic third ventriculostomy (ETV) in the mid 1990s, there has been an interest in avoiding shunts in patients with hydrocephalus with the hope that if a foreign body insertion could be avoided, the accompanying complications of a shunt (infection, blockage, extrusion, abdominal pseudocysts, skin erosion over shunt components) could also be avoided. Singh et al, reported a success rate of ETV in 77% of 35 patients with TBM and hydrocephalus.

Also, 60% had early and 17% had delayed recovery. The success rates were not related to the type of hydrocephalus (obstructive or communicating). However, the presence of a thin and transparent floor of the third ventricle seemed to be associated with a higher success rate of 87%.<sup>1,7-9</sup>

Hussain et al, determined that 68% of the patients with TBM and hydrocephalus benefited from various endoscopic procedures including ETV. In a more recent study by the same group they found that 19 of 26 (73%) patients with TBM and hydrocephalus responded to ETV. They found that patients with longer duration of symptoms and ATT were more likely to benefit from the ETV. In contrast Figaji et al, reported a successful outcome following attempted ETV in only seven of 17 (41%) patients with TBM and hydrocephalus. In five patients, the ETV was performed but failed, whereas in another five the procedure had to be abandoned due to abnormal anatomy. They concluded that although ETV was technically possible in patients with TBM, only a surgeon experienced in endoscopic procedures should perform the surgery as the procedure is more demanding than in other situations.<sup>1,7-9</sup>

The patients performed ETV. In patients with TBM, the floor of the third ventricle is frequently thick, and the subarachnoid space is also likely to be obliterated by exudates making it difficult to recognize anatomical landmarks. In this situation it might be prudent to abandon the procedure than risk injury to the basilar artery and its branches. It could also be considered in patients who have shunt failure, as it might be a better option than shunt revision in these patients.<sup>1,10</sup>

Failure of the ETV with CSF leak and bleeding during the surgery are the most commonly reported complications of ETV. Husain et al, had complications in three of 28 patients undergoing ETV for TBM related hydrocephalus. In a more recent series, the same authors have reported ETV failures in seven of 26 patients. They did not report any other complications in this series of patients. Risk of injury to the basilar artery and its branches is theoretically higher in patients with TBM due to the thickened and opaque third ventricular floor.<sup>1,10</sup>

## CONCLUSION

The placement of a ventriculoperitoneal (VP) shunt is the most common form of treatment for hydrocephalus in tuberculous meningitis (TBM). Although allergic reactions to the silicone in shunt device are very rare, the authors describe a case of silicone allergy causing multiple VP shunt revisions. VP Shunts complications remain a difficult problem in neurosurgical clinical practice. The most typical complications are mechanical obstruction and infection. Allergy to the silicone shunt tubing is quite rare. Silicone allergy is an even more rare occurrence because of its high biocompatibility and low biological reactivity. Alternative choice is endoscopic third ventriculostomy (ETV), but it is debatable. ETV has variable success in these patients and is generally not advisable in patients in the acute stages of the disease. Patients in this case received ETV and release VSS Shunt. ETV has success in these patients. It is a challenge for ETV when TBM has difficulty to recognize anatomical landmarks on this patient. It could also consider in patients who have shunt failure, and might be a better option than shunt revision.

*Funding: No funding sources*

*Conflict of interest: None declared*

*Ethical approval: Not required*

## REFERENCES

1. Rajshekhar V. Management of hydrocephalus in patients with tuberculous meningitis. *Neurology India.* 2009 Jul 1;57(4):368.
2. Patir R, Bhatia R. Management of tuberculous infections of the nervous system. In: Schmidek and Sweet Operative neurosurgical Techniques: Indications, Method, and Results. 6th ed. 2012:1679-1690.
3. Dastur DK, Manghani DK, Udani PM. Pathology and pathogenetic mechanisms in neurotuberculosis. *Radiol Clin North Am.* 1995;33:733-52.
4. Palur R, Rajshekhar V, Chandy MJ, Joseph T, Abraham J. Shunt surgery for hydrocephalus in tubercular meningitis: A long-term follow-up study. *J Neurosurg.* 1991;74:64-9.
5. Chakraborty A, Drake JM, Warf BC. Methods for cerebrospinal fluid diversion in pediatric hydrocephalus: from shunt to scope. In: Schmidek and Sweet Operative neurosurgical Techniques: Indications, Method, and Results. 6th ed. 2012:631-653.
6. Hussain NS, Wang PP, James C, Carson BS, Avellino AM. Distal ventriculoperitoneal shunt failure caused by silicone allergy: Case report. *J Neurosurg.* 2005 Mar;102(3):536-9.
7. Kulkarni AV, Riva-Cambrin J, Browd SR. Use of the ETV Success Score to explain the variation in reported endoscopic third ventriculostomy success rates among published case series of childhood

- hydrocephalus. *J Neurosurg: Pedia.* 2011 Feb;7(2):143-6.
8. Kulkarni AV, Drake JM, Kestle JR, Mallucci CL, Sgouros S, Constantini S. Predicting who will benefit from endoscopic third ventriculostomy compared with shunt insertion in childhood hydrocephalus using the ETV Success Score. *J Neurosurg: Pedia.* 2010 Oct;6(4):310-5.
  9. Jallo GI, Kothbauer KF, Abbott IR. Endoscopic third ventriculostomy. *Neurosurg Focus.* 2005 Dec;19(6):1-4.
  10. Bouras T, Sgouros S. Complications of endoscopic third ventriculostomy: a review. *J Neurosurg: Pedia.* 2011 Jun;7(6):643-9.

**Cite this article as:** Rosyidi RM, Priyanto B, Parenrengi MA. ETV in tuberculous meningitis with hydrocephalus and allergic reaction to VP shunt: a case report. *Int J Res Med Sci* 2019;7:305-9.

# ETV in tuberculous meningitis with hydrocephalus and allergic reaction to VP shunt a case report

## ORIGINALITY REPORT

23%

SIMILARITY INDEX

12%

INTERNET SOURCES

20%

PUBLICATIONS

0%

STUDENT PAPERS

## PRIMARY SOURCES

- 1** Hernando Alvis-Miranda, Gabriel Alcala-Cerra, Sandra Milena Castellar-Leones, Hector Farid Escorcia et al. "Latex and silicon allergy related to cerebrospinal shunt hardware: a review", **Romanian Neurosurgery**, 2013  
Publication 2%
- 2** [theplus-health.blogspot.com](http://theplus-health.blogspot.com)  
Internet Source 2%
- 3** Wu, Xiao-Jun, Chun Luo, Zhengyang Liu, Guo-Han Hu, Ju-Xiang Chen, and Yi-Cheng Lu. "Complications following ventriculo-peritoneal and subsequent ventriculo-atrial shunting resolved by third ventriculostomy", **British Journal of Neurosurgery**, 2011.  
Publication 2%
- 4** [tsukuba.repo.nii.ac.jp](http://tsukuba.repo.nii.ac.jp)  
Internet Source 2%
- 5** [healthdocbox.com](http://healthdocbox.com)  
Internet Source 2%

6

diabetestalk.net

Internet Source

1%

7

J Burtscher, L Bartha, K Twerdy, W Eisner, T Benke. "Effect of endoscopic third ventriculostomy on neuropsychological outcome in late onset idiopathic aqueduct stenosis: a prospective study", Journal of Neurology, Neurosurgery & Psychiatry, 2003

Publication

1%

8

Rohadi Muhammad Rosyidi, Bambang Priyanto, Asra Al Fauzi, Agung Budi Sutiono. "Toward zero mortality in acute epidural hematoma: A review in 268 cases problems and challenges in the developing country", Interdisciplinary Neurosurgery, 2019

Publication

1%

9

Pawan Goyal, Chhitij Srivastava, Bal Krishna Ojha, Sunil K Singh, Anil Chandra, R. K. Garg, Swati Srivastava. "A randomized study of ventriculoperitoneal shunt versus endoscopic third ventriculostomy for the management of tubercular meningitis with hydrocephalus", Child's Nervous System, 2014

Publication

1%

10

Dattatraya Muzumdar, Rajshekhar Vedantam, Deopujari Chandrashekhar. "Tuberculosis of the central nervous system in children", Child's

1%



## Nervous System, 2018

Publication

11

Chandrashekhar E. Deopujari, Llewelyn Padayachy, Alias Azmi, Anthony Figaji, Saurav K. Samantray. "Neuroendoscopy for post-infective hydrocephalus in children", Child's Nervous System, 2018

Publication

1%

12

Eric M. Thompson. "Successful ventricle to direct heart shunt placement as a salvage cerebrospinal fluid diversion technique", Journal of Neurosurgery Pediatrics, 06/2009

Publication

1%

13

[scholar.sun.ac.za](http://scholar.sun.ac.za)

Internet Source

1%

14

Ramsha Akhund, Fatima Jamshed, Hassam A Jaffry, Hamza Hanif, Sundus Fareed. "Knowledge and Attitude of General Pakistani Population Towards Antibiotic Resistance", Cureus, 2019

Publication

1%

15

"55 Surgical Considerations in Tuberculosis, Fungal, and Parasitic Infections of CNS in Children", Georg Thieme Verlag KG, 2018

Publication

1%

16

Pawel Tabakow, Marcin Czyz, Pawel Szewczyk, Artur Weiser, Wlodzimierz Jarmundowicz.

1%

# "Usefulness of Intraoperative Magnetic Resonance Ventriculography During Endoscopic Third Ventriculostomy", Neurosurgery, 2013

Publication

17

[thejns.org](http://thejns.org)

Internet Source

1%

18

Chakraborty, Aabir, James M. Drake, and Benjamin C. Warf. "Methods for Cerebrospinal Fluid Diversion in Pediatric Hydrocephalus", Schmidek and Sweet's Operative Neurosurgical Techniques, 2012.

Publication

<1%

19

Giuseppe Cinalli, Giuliana Di Martino, Pietro Spennato, Giuseppe Mirone et al. "Chapter 25 Endoscopic Third Ventriculostomy", Springer Science and Business Media LLC, 2019

Publication

<1%

20

"Cerebrospinal Fluid Disorders", Springer Nature America, Inc, 2019

Publication

<1%

21

[www.em-consulte.com](http://www.em-consulte.com)

Internet Source

<1%

22

D. Singh, V. Sachdev, A. K. Singh, S. Sinha. "Endoscopic Third Ventriculostomy in Post-Tubercular Meningitic Hydrocephalus: A Preliminary Report", min - Minimally Invasive Neurosurgery, 2005

<1%

## Publication

---

Exclude quotes      On

Exclude matches      Off

Exclude bibliography      On

# ETV in tuberculous meningitis with hydrocephalus and allergic reaction to VP shunt a case report

---

## GRADEMARK REPORT

---

FINAL GRADE

**/100**

GENERAL COMMENTS

**Instructor**

---

PAGE 1

---

PAGE 2

---

PAGE 3

---

PAGE 4

---

PAGE 5

---