

A rare case of repeated migration and transurethral extrusion of ventriculoperitoneal shunt

by Agus Turchan

Submission date: 03-Jul-2019 12:38PM (UTC+0800)

Submission ID: 1148878994

File name: on_and_transurethral_extrusion_of_ventriculoperitoneal_shunt.pdf (919.8K)

Word count: 151

Character count: 11819

Case Report

A Rare Case of Repeated Migration and Transurethral Extrusion of Ventriculoperitoneal Shunt

Asra Al Fauzi, Wahjoe Djatisoesanto¹, Joni Wahyuhadi, Muhammad Arifin Parenrengi, Agus Turchan

Departments of Neurosurgery and ¹Urology, Universitas Airlangga, Dr. Soetomo General Hospital, Surabaya Neuroscience Institute, Surabaya, Indonesia

ABSTRACT

Bladder migration and transurethral extrusion is an extremely rare complication of ventriculoperitoneal (VP) shunt. Only eight cases have been reported in the English literature since 1995. We report a case of a 4-year-old boy with cerebral palsy, hydrocephalus, and VP shunted on both sides who presented with a protruded distal VP shunt from his urethral orifice. The patient was reported for having previous shunt extrusion through the anus. The patient was treated on by a multidisciplinary approach, involving a neurosurgeon and urologist. Shunt removal with simple procedure was smoothly achieved without morbidities. He was discharged home in satisfactory condition.

KEYWORDS: Bladder, repeated migration, transurethral extrusion, ventriculoperitoneal shunt

INTRODUCTION

Ventriculoperitoneal (VP) shunting for hydrocephalus is a common neurosurgical procedure in our daily practice.^[1-3] Common complications include malfunction, infection, and overdrainage.^[4] Migration of distal part of VP shunt into the adjacent organs including bowel tract, thoracic cavity, heart, scrotum, umbilicus, abdominal wall, and urinary bladder is reported.^[3-5] A case of repeated shunt migration in different organs is extremely rare. This is the first case of bowel perforation with transanal extrusion continued with bladder migration and urethral extrusion of peritoneal shunt. We report our case of a child with these unusual complications; treatment was done by a team involving neurosurgeons and urologists.

CASE REPORT

A 4-year-old boy was admitted to the hospital because of abdominal discomfort. On further examination, he had a history of cerebral palsy and difficulty of walking. He also underwent several VP shunt operations when he was younger. The first operation was undertaken when he was 2 months old because of his congenital hydrocephalus.

The patient went back to the hospital when he was 1 year old because of severe headache. Computed tomography (CT) scan confirmed a large right

porencephaly. An additional shunt was inserted on the right side. Postoperatively, the patient's condition was remarkable and he was discharged uneventfully.

Three months later, the patient had complained of abdominal pain. On hospitalization, further physical examination revealed an exposure of shunt on his anus which extruded spontaneously. Revision of shunt catheter was undertaken.

The patient presented again complaining of abdominal discomfort 2 months later. During hospitalization, there was a shunt extruded through his urethra [Figure 1]. His abdominal X-ray revealed that the extruded shunt was the right peritoneal catheter [Figure 2]. Urinary bladder was strongly suspected as the site of migration. The patient underwent emergency surgery. The shunt was removed by a team comprising neurosurgeons and urologists. The shunt was cut at the abdomen site and exteriorized. The peritoneal end was gently pulled through the urethral opening. Cerebrospinal fluid (CSF) analysis showed an infection. The result was showing 200 cells found with

Address for correspondence: Dr. Asra Al Fauzi, Department of Neurosurgery, Universitas Airlangga, Dr. Soetomo General Hospital, Surabaya Neuroscience Institute, Surabaya, Indonesia.
E-mail: asrafauzi@yahoo.com

This is an open access article distributed under the terms of the Creative Commons Attribution-NonCommercial-ShareAlike 3.0 License, which allows others to remix, tweak, and build upon the work non-commercially, as long as the author is credited and the new creations are licensed under the identical terms.

For reprints contact: reprints@medknow.com

How to cite this article: Al Fauzi A, Djatisoesanto W, Wahyuhadi J, Parenrengi MA, Turchan A. A rare case of repeated migration and transurethral extrusion of ventriculoperitoneal shunt. *J Pediatr Neurosci* 2017;12:96-8.

Access this article online	
Quick Response Code: 	Website: www.pediatricneurosciences.com
	DOI: 10.4103/jpn.JPN_189_16

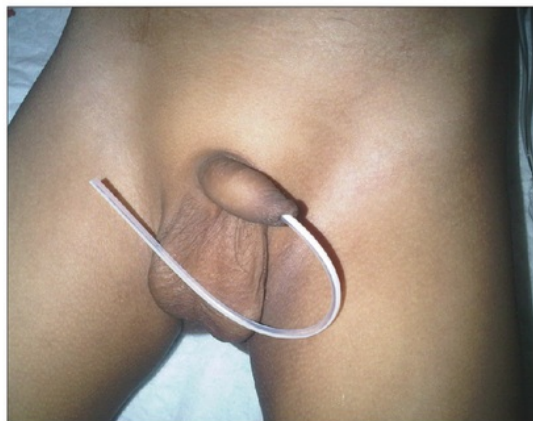

Figure 1: Extruded shunt was exposed through the external urethral orificium

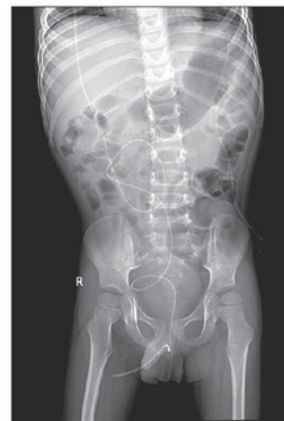

Figure 2: Abdominal X-ray shows the extruded ventriculoperitoneal shunt catheter through the urethral orificium

protein 100 mg/dl, glucose 13 mg/dl, and the culture showed *Micrococcus* sp. growth. Urological procedure was performed endoscopically through the urethra to explore the site of migration and potential of leakage. It was found that the shunt was penetrated through the bladder wall just above the trigonal area [Figure 3]. We decided to treat conservatively by inserting an urethral catheter to keep the bladder decompressed for optimal healing process.

Thereafter, intraventricular antibiotic was administered according to the culture results. One month later, culture of CSF was performed and it showed a sterile result. CT scan was done afterward and VP shunt was reinserted. The patient showed gradual improvement and discharged from the hospital in a good condition. He was doing well at the 2-year follow-up appointment.

DISCUSSION

VP shunt is a well-established modality of treatment for hydrocephalus.^[1,3] Organ perforation by distal catheter is relatively unusual.^[6,7] Bowel perforation was present in 0.1%–0.7% of cases in which colon was the most involved organ,^[8] and the most common site of extrusion is anus (68.9%), followed by scrotum (22%), umbilicus (6.9%), and vagina (3.2%).^[7] A case of urinary bladder migration as well as urethral extrusion of VP shunt is extremely rare.^[4-6] There were only eight cases reported in the English literature since 1995.^[1-7,9]

The exact mechanism of the bladder perforation is not fully understood yet.^[3,7,8] There have been various theories proposed such as bioreactivity, local inflammation, infection, and surgical error.^[3,7-9] The contribution of host factors includes young age and malnutrition. The location of the bladder makes it highly unlikely site of perforation, as the catheter must pass

through the peritoneum into the extraperitoneal space and subsequently perforate the bladder.^[3] In this present case, the first migration of the catheter was into the anus, and this is considered as a frequent event of migration. The second migration into the bladder is a rare case. Symptom was only abdominal discomfort and it became obvious after the expose through the urethral orifice. Repeated case of shunt migration is an interesting case regarding the pathophysiology and management of this patient. With the history of prior bowel perforation by shunt catheter, and cultures of specimens indicating an infection, we postulated that there is a silent subclinical infection. There is a condition of local inflammation and adhesions in the peritoneal cavity. Fixation of the tip catheter at the specific site of the peritoneum is facilitated and then, continuous erosion and perforation of the peritoneum into the bladder was done. The trigonal area, which comprises less muscle layer, was the site of migration in this case. Bladder perforation by shunt catheter is a surgical emergency. There are three main procedures of shunt removal: gentle pulling, endoscopic surgery, and major open surgery.^[10] As per earlier reports, catheter removal is mostly done by open abdominal surgery,^[3-5,9] but in author's opinion, removal of the catheter could be done with a less invasive method. In our case presenting per-urethraly, the catheter was gently pulled out through the urethral orifice. The surgery was then followed by urological endoscopic exploration through the urethra to view the size and location of the perforation. Collaboration with urologist is very important in this case to determine the optimal treatment. It is believed that the perforation site seals off due to the presence of a chronic fibrous sheath around the shunt tract and requires no aggressive surgical intervention.^[10] We found the pitfall of this case to be the lack of detailed history of the previous

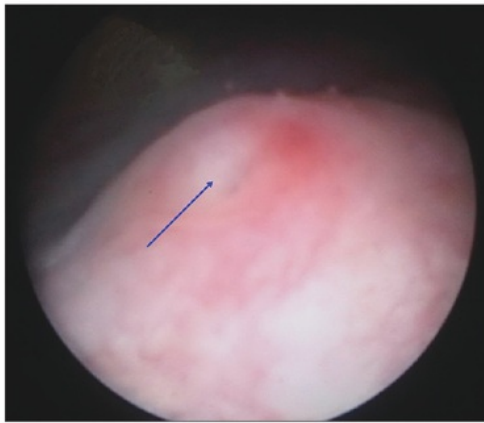


Figure 3: During endoscopic urological surgery, migration site just above the trigonal area of the urinary bladder was identified (blue arrow)

operation because the patient underwent the surgery in another hospital. The repeated migrations also give us some thought of another option of shunting, for example, ventriculo-atrial shunt.

CONCLUSION

Bladder migration and transurethral extrusion is an extremely rare complication of VP shunt. To our knowledge, this is the ninth case reported. Early diagnosis, early shunt removal, and appropriate antibiotic use should be considered. The presence of previous abdominal complication and repeated organ perforation indicates predisposition factors which must be sought and handled before any further treatment. The multidisciplinary and minimally invasive approach is advisable to prevent further complications.

Financial support and sponsorship

Nil.

Conflicts of interest

There are no conflicts of interest.

REFERENCES

1. Mutlu M, Kader S, Aslan Y, Yazar U, Imamoglu M. An acute complication of ventriculoperitoneal shunt with bladder perforation and extrusion through the urethra in a newborn: Case report and review of the literature. *Pediatr Neurosurg* 2015;50:264-9.
2. Prasad VS, Krishna AM, Gupta PK. Extrusion of peritoneal catheter of ventriculoperitoneal shunt through the urethra. *Br J Neurosurg* 1995;9:209-10.
3. Pohlman GD, Wilcox DT, Hankinson TC. Erosive bladder perforation as a complication of ventriculoperitoneal shunt with extrusion from the urethral meatus: Case report and literature review. *Pediatr Neurosurg* 2011;47:223-6.
4. Yazar U, Kanat A, Akca N, Gazioglu G, Arda IS, Kazdal H. Urethral protrusion of the abdominal catheter of ventriculoperitoneal shunt: Case report of extremely rare complication. *J Pediatr Neurosci* 2012;7:111-3.
5. IV MS, Chua M, Dy J. A rare cause of pediatric urinary incontinence: Ventriculoperitoneal shunt with bladder perforation. *Pediatric* 2016;3:76-83. Available from: <http://www.pediatricurologycasereports.com/ojs/index.php/pucr/article/view/135>. [Last cited on 2016 Nov 22].
6. Surchev J, Georgiev K, Enchev Y, Avramov R. Extremely rare complications in cerebrospinal fluid shunt operations. *J Neurosurg Sci* 2002;46:100-2.
7. Vivek K, Tarun G, Gaurav J. Urinary bladder perforation and per-urethral extrusion of lumbo-peritoneal shunt in a patient: Case report and review literature. *J Spine Neurosurg* 2015;4:1-3.
8. Murthy KR, Reddy SJ. Perforation of the distal end of the ventriculoperitoneal shunt into the bladder with calculus formation. *Pediatric* 2009;45:53-5. Available from: <http://www.karger.com/Article/Fulltext/204904>. [Last cited on 2016 Nov 22].
9. Chen TH, Lin MS, Kung WM, Hung KS, Chiang YH, Chen CH. Combined ventriculoperitoneal shunt blockage, viscus perforation and migration into urethra, presenting with repeated urinary tract infection. *Ann R Coll Surg Engl* 2011;93:e151-3.
10. Agarwal M, Adhana R, Namdev H, Yadav YR, Agrawal T. Transoral extrusion of the ventriculo-peritoneal shunt: A case report and review of literature. *J Pediatr Neurosci* 2011;6:149-51.

A rare case of repeated migration and transurethral extrusion of ventriculoperitoneal shunt

ORIGINALITY REPORT

24%

SIMILARITY INDEX

23%

INTERNET SOURCES

16%

PUBLICATIONS

0%

STUDENT PAPERS

PRIMARY SOURCES

- 1** Adrian Kelly, Steven Setati, P. Lekgwara. "Urethral migration of a ventriculoperitoneal shunt in an adult immunocompromised patient", *Interdisciplinary Neurosurgery*, 2018
Publication **9%**
- 2** ijcrcps.com
Internet Source **8%**
- 3** openneurologyjournal.com
Internet Source **7%**

Exclude quotes On

Exclude matches Off

Exclude bibliography On

A rare case of repeated migration and transurethral extrusion of ventriculoperitoneal shunt

GRADEMARK REPORT

FINAL GRADE

/100

GENERAL COMMENTS

Instructor

PAGE 1

PAGE 2

PAGE 3
