

# Hyperdense Appearance in Active Epidural and Subdural Hematoma : Serial Case Report

*by Agus Turchan*

---

**Submission date:** 03-Jul-2019 12:56PM (UTC+0800)

**Submission ID:** 1148882932

**File name:** ppearance\_in\_active...\_Indonesian\_Journal\_of\_Neurosurgery.pdf (941.86K)

**Word count:** 1695

**Character count:** 8527



## Hyperdense Appearance in Active Epidural and Subdural Hematoma: Serial Case Report



CrossMark

Krisna Tsaniadi Prihastomo,<sup>1\*</sup> Tedy Apriawan,<sup>2</sup> Agus Turchan<sup>3</sup>

### ABSTRACT

**Background:** Many of traumatic brain injured patients come to the emergency department with active intracranial bleeding, either Epidural Hematoma (EDH) or Subdural Hematoma (SDH). The most common source of bleeding in EDH cases might be either from the oozed bleeding from fracture of adjacent bone or tear of medial meningeal vessel branches.

**Aim:** This study aims to report some cases about hyperdense appearance both in the active EDH and SDH. Method: The classic appearance usually found in non-contrast head CT, which formed a biconvex lesion. The active bleeding, usually from blood vessels tearing origin, could also be observed in CT imaging.

**Result:** There is hypodense mixed within the hyperdense lesion, sometimes formed a whirlpool-like appearance, which later known as "Swirl sign". The acute subdural hematoma, by its process, is different with EDH. It is usually caused by clot accumulation of adjacent cortical laceration or tearing of bridging veins. The crescent-like appearance is the classical CT image shown in acute SDH. However, up to now, the active bleeding in SDH is not widely explained. The authors report 12 cases of EDH and SDH which indicate active bleeding from an imaging study. All of the cases revealed the active bleeding during the surgery.

**Conclusion:** Hypodense lesion in acute TBI imaging should be considered as active bleeding not only for EDH but also for SDH cases.

**Keyword:** Swirl sign, SDH, active bleeding

**Cite This Article:** Prihastomo, K.T., Apriawan, T., Turchan, A. 2018. Hyperdense Appearance in Active Epidural and Subdural Hematoma: Serial Case Report. *Indonesian Journal of Neurosurgery* 1(2): 45-47. DOI:10.15562/ijn.v1i2.41

<sup>1</sup>Department of Neurosurgery, Dr. Kariadi General Hospital Medical Center <sup>2</sup>  
<sup>2,3</sup>Department of Neurosurgery, Faculty of Medicine, Universitas Airlangga, Dr. Soetomo General Hospital Surabaya

### INTRODUCTION

Traumatic Brain Injury (TBI) is still being a big problem in our society. The mortality case is about 17.8 per 100,000 population in the US.<sup>4</sup> Many of the traumatic brain injured patients come to the emergency department with active intracranial bleeding, either Epidural Hematoma (EDH) or Subdural Hematoma (SDH). The most common source of bleeding in EDH cases might be either from the oozed bleeding from fracture of adjacent bone or tear of medial meningeal vessel branches.<sup>2,3,4</sup> The classic appearance usually found in non-contrast head CT, which formed a biconvex lesion. The active bleeding, usually from blood vessels tearing origin, could also be observed in CT imaging. There is hypodense mixed within

the hyperdense lesion, sometimes formed a whirlpool-like appearance which is later known as "Swirl sign".<sup>3</sup> The pathogenesis of acute SDH is different from EDH. It is related with a clot accumulation of adjacent cortical laceration or tearing of bridging veins. The crescent-like appearance is the classical CT image shown in acute SDH. However, up to now, the active bleeding in SDH is not widely explained.

### CASE REPORT

The study reported 12 cases of traumatic intracranial hemorrhages which consist of 7 EDH cases and five SDH cases. The characteristic of the patient was shown in Table 1.

**Table 1** The characteristic of the patient with active intracranial bleeding

n (%)		EDH	SDH
		7 (58.3%)	5 (41.7%)
Sex, n (%)	Male	4 (57.1%)	4 (80%)
	Female	3 (42.%)	1 (20%)
Age (years old)	Mean	13.42	40.6
	Minimum	3	13
	Maximum	20	68
Thickness (Mean, cm)		2.35	1.21
Midline Shift (Mean, cm)		0.55	1.28

EDH : Epidural Hematoma ; SDH: Subdural Hematoma

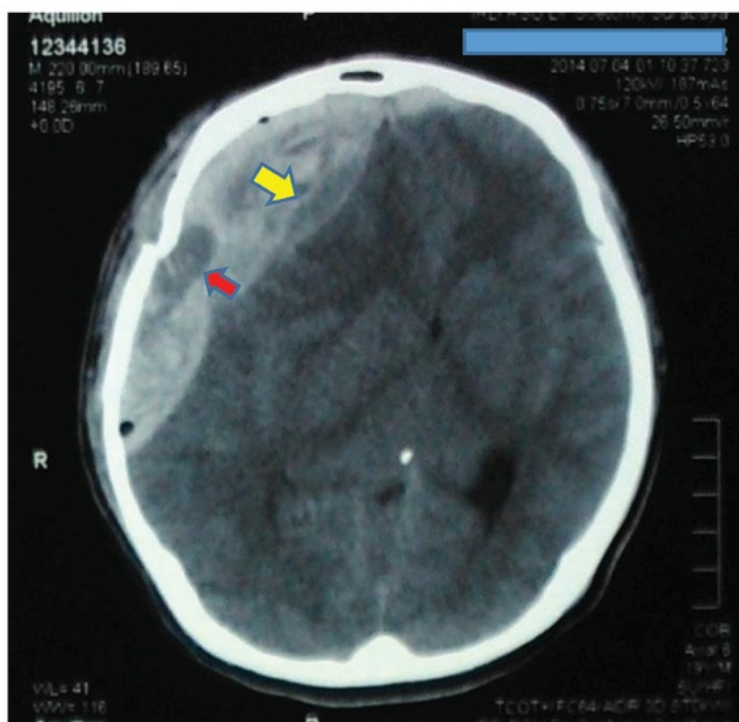
\*Correspondence to:  
Krisna Tsaniadi Prihastomo,  
Department of Neurosurgery,  
Dr. Kariadi General Hospital Medical  
Center  
tsaniadi@gmail.com

Received: 2018-12-10  
Accepted: 2018-12-30  
Published: 2018-12-31

**Table 2** Detail characteristic of each patient with an active EDH and SDH

Patient no.	Sex	Age	Lesion	Region	Thickness (cm)	Time to surgery	Suspected source of bleeding
1	Male	15	EDH	Frontal	2.4	7 hrs 45 min	Fracture site
2	Male	19	EDH	Frontal	3.5	5 hrs	Fracture site and meningeal branch
3	Female	3	EDH	Frontal	1.9	5 hrs 30 min	Fracture site
4	Female	14	EDH	Parietal	2.4	18 hrs	Fracture site
5	Male	14	EDH	Parietal	2.1	4 hrs	Fracture site
6	Male	20	EDH	Temporoparietal	1.9	5 hrs	Fracture site
7	Female	9	EDH	Temporoparietal	2.3	7 hrs 30 min	Fracture site
8	Female	60	SDH	Frontotemporoparietal	1.4	4 hrs	Bridging vein
9	Male	68	SDH	Frontotemporoparietal	1.7	7 hrs	Cortical lesion
10	Male	32	SDH	Frontotemporoparietal	1.2	3 hrs	Cortical lesion
11	Male	30	SDH	Frontotemporoparietal	1.07	9 hrs	Bridging vein
12	Male	13	SDH	Frontotemporoparietal	0.7	6 hrs	Cortical lesion

Note: Time to surgery is defined as the time from accident to the incision in the operating room  
The neurosurgeon determined the suspected source of bleeding during the surgery



**Figure 1** An axial view of non-contrast head CT. Note the hypodense lesion within the hyperdense. A red arrow indicates the active bleeding from the fracture site. The yellow arrow indicates the active bleeding from meningeal branch vessels

Of the twelve cases with active intracranial bleeding (ICB), about 41.7% were SDH. Male was the

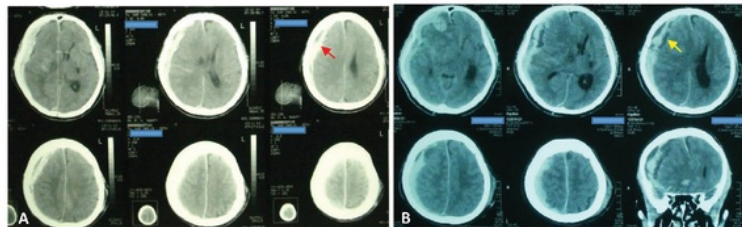
most dominant sex found in both EDH and SDH cases (57.1%, and 80%, respectively). The average age was 13.42 years-old in EDH and 40.6 years-old in SDH. The youngest was three years old who suffered EDH, where the oldest was 68 years old in SDH. The particular characteristic of each patient was shown in Table 2.

This study found that most of the EDH patient had a source of bleeding from the fracture site, which supported from the imaging that shows hypodense lesion adjacent to the fracture site.

**CASE 1**

A 19 years old rider was admitted to the emergency room with a decrease of consciousness after crashed by another motorcycle. He came after 4 hours of an accident, referred from district health center (*Puskesmas*). He was unconscious since the crash. The prior GCS was 6 with the unequal pupil, mydriatic on the right side. Clinically, motor function was normal, no sign of suspected hemiparesis. A non-contrast head CT was taken immediately in Figure 1.

Figure 1 revealed an acute EDH with 3.5 cm in the thickness; the volume was about 60 cc. There was a fracture in the right frontal bone. Beneath, a massive blood clot was formed. Interestingly, the features of blood clot revealed in head CT was not homogenous. It built a mixed density between hyper and hypodense. The hyperattenuated lesion was located adjacent to the fracture and the dura. During the surgery, the proven source of bleeding was from the fracture site and the tearing of the meningeal artery branch.



**Figure 2** A serial non-contrast head CT of 68 years old man. A. CT Scan was taken 2 hours after the accident. Note the hyperdense lesion outside the SDH (red arrow) which indicated the bleeding was still ongoing. B. CT evaluation was taken 8 hours after admission (or 6 hours after the first CT Scan). It showed a progression of the size of the clot

## CASE 2

A 68 years-old pedestrian was brought to the emergency department because of the gradual decrease of consciousness. This patient was walked by himself to the district hospital because of a headache after crashed by motorcycle. He was fully conscious at the first time. Unfortunately, during the observation, the GCS was dropped to 11. An immediate head CT was taken and revealed an SDH in the right frontotemporoparietal region. Patient was then referred to the Dr. Soetomo hospital to undergo neurosurgery. The GCS after arriving in Dr. Soetomo hospital is 7; the attending neurosurgery resident was taking head CT evaluation.

A craniotomy was immediately performed. The source of bleeding of this patient came from the cortical lesion in the frontal region. The SDH was then evacuated along with the frontal burst lobe.

## DISCUSSION

EDH and SDH are emergency cases which require quick and appropriate diagnosis and treatment. CT Scan is currently the most sophisticated tools to diagnose intracerebral hemorrhage.<sup>4</sup> A hyperdense lesion, as a sign of blood clot, is seen in CT

Scan which differs by its shape to determine EDH or SDH. A biconvex blood clot is the characteristic for EDH whereas crescent is for SDH. Hypodense lesion within the hyperdense sometimes can be seen in the CT imaging. The previously described "Swirl sign" is commonly found in acute bleeding of EDH.<sup>3</sup> However, in SDH, the sign of active bleeding in CT imaging is not well explained. Based on our cases, we found that hypodense lesion within the SDH in CT imaging indicates active bleeding, proven during the surgery. It either originated from the bridging vein or the cortical laceration. This finding is useful for a neurosurgeon to take more care of bleeding control.

## CONCLUSION

Hypodense appearance within the hyperdense lesion in head CT scan shows active bleeding not only for Epidural Hematoma (EDH) but also Subdural Hematoma (SDH). A neurosurgeon must take more attention for the source of bleeding control during the surgery.

## REFERENCES

1. Pouraghaei, M., Moharamzadeh, P., Dibazar, S., Taghizadieh, A., Ala, A., Maroufi, P., Ghiasi, R.R. Hypodense area within epidural hematoma in brain CT scan; Prediction of active bleeding in epidural hematoma. *Life Science Journal*, 2013; 10 (1).
2. Le, T.H., Gean, A.D. Imaging of Head Trauma. *Seminars in Roentgenology*. California: Elsevier, pp. 177-189
3. Al-Nakshabandi, N.A. The Swirl Sign. *Radiology*, 2001; pp. 218-413.
4. Kim, T.A., Kalnins, A.U., Prost, R.W. Computed Tomography and Magnetic Resonance Imaging of the Brain. In: Winn, R.H. Eds. *Youmans Neurological Surgery*. 6<sup>th</sup> Ed. Philadelphia: Elsevier, pp. 277-310.



This work is licensed under a Creative Commons Attribution

# Hyperdense Appearance in Active Epidural and Subdural Hematoma : Serial Case Report

## ORIGINALITY REPORT

3%

SIMILARITY INDEX

3%

INTERNET SOURCES

2%

PUBLICATIONS

0%

STUDENT PAPERS

## PRIMARY SOURCES

1

[arylan.com](http://arylan.com)

Internet Source

1%

2

[nsmc.balijournals.org](http://nsmc.balijournals.org)

Internet Source

1%

3

[unsri.portalgaruda.org](http://unsri.portalgaruda.org)

Internet Source

1%

Exclude quotes On

Exclude matches Off

Exclude bibliography On

# Hyperdense Appearance in Active Epidural and Subdural Hematoma : Serial Case Report

---

## GRADEMARK REPORT

---

FINAL GRADE

**/100**

GENERAL COMMENTS

**Instructor**

---

PAGE 1

---

PAGE 2

---

PAGE 3

---