



INTERNATIONAL SCIENTIFIC MEETING (TINI IV) & IKORGI NATIONAL CONGRESS XI

*Revolutionary Paradigm for the Future Vision
of Endodontics & Restorative Dentistry*

November 3rd-5th, 2017
Shangri-La Hotel
May. Jend. Sungkono 120 Surabaya

**BUKU
PROSIDING**

Panitia Temu Ilmiah International IV & Konggres IKORGI XI
Sekretariat Dep. Konservasi Gigi FKG UNAIR
Jl. Mayjend Prof. Dr. Moestopo 47 Surabaya – 60132
Telp : 031-5030255 ext.117, Fax : 031-5039478
Email : konservasiunair@yahoo.com

PROCEEDING

International Scientific Meeting (TINI IV) & National Congress IKORGI XI

Theme :

Revolutionary Paradigm for the Future Vision of Endodontics and Restorative Dentistry

Surabaya, November 3rd – 5th, 2017

Steering Committee:

- M.Rulianto,drg.,MS.,SpKG(K)
- Prof.Dr.Latief Mooduto,drg.MS.Sp.KG(K)
- Karlina Samadi,drg.MS.Sp.KG(K)

Organizing Committee:

- Ari Subiyanto, drg.MS.Sp.KG (K)
- Karlina Samadi,drg.MS.Sp.KG(K)
- Dr.Dian Agustin W.,drg.,SpKG(K)
- Eric Priyo Prasetyo,drg.,M.Kes.,SpKG(K)
- Dr.Tamara Yuanita, drg.MS.Sp.KG(K)
- Dr. Ira Widjastuti,drg.,M.Kes.,SpKG(K)
- Dr. Widya Saraswati,drg.,M.Kes.,Sp.KG
- Galih Sampoerno,drg.M.Kes.,SpKG(K)
- Devi Eka Yuniarti,drg.,M.Kes.,SpKG(K)

Editor:

- M. Rulianto,drg.,MS.,SpKG(K)

Reviewer:

- Prof. Dr. Latief Mooduto,drg.,MS.,SpKG(K)
- Dr. Ira Widjastuti,drg.,M.Kes.,SpKG(K)
- Dr. Dian Agustin Wahyuningrum,drg.,SpKG(K)
- Eric Priyo Prasetyo,drg.,M.Kes.,SpKG(K)



Published by:

PENGURUS PUSAT IKATAN KONSERVASI GIGI INDONESIA (PP IKORGI)

Jl. Mayjend. Prof. Dr. Moestopo No. 47 Surabaya 60132

Telp. (031) 5030255; Fax. (031) 5020256

ISBN 978-602-19108-6-3

ENDODONTIC RETREATMENT OF MAXILLARY SECOND PREMOLAR WITH ROOT CANAL CONFIGURATION VERTUCCI CLASS II	
Mettasari Puspa Wardoyo ¹ , Dewa Ayu Nyoman Putri Artiningsih ²	569
ROOT CANAL TREATMENT OF UPPER FIRST MOLAR WITH TWO-THIRD APICAL OBLITERATION	
Celine Marissa ¹ , Munyati Usman ²	579
MANAGEMENT ON APICAL THIRD FRACTURE OF CENTRAL INCISOR : A CASE REPORT	
Putu Ferbika ¹ , Latief Mooduto ²	587
SMILE MAKEOVER IN THE PATIENT WITH MULTIPLE CARIES, FRACTURE AND LABIOVERSION	
Ratih Elisa Nandarani ¹ , Kun Ismiyatin ²	593
ROOT CANAL TREATMENT IN FIRST LOWER LEFT MOLAR WITH MIDDLE MESIAL AND RADIX ENTOMOLARIS : CASE REPORT	
Raymond Kandou*, Nirawati Pribadi**	599
ROOT CANAL TREATMENT WITH COMPOSITE RESIN RESTORATION AND POLYETHYLENE FIBER AS REINFORCEMENT IN MANDIBULAR RIGHT SECOND MOLAR TOOTH WITH A SINGLE ROOT CANAL	
Reni Nofika*, Tunjung Nugraheni**	607
THE CONSERVATIVE MANAGEMENT OF EXTERNAL ROOT RESORPTION OF PERMANENT INCISIVE CENTRAL CAUSED BY A TRAUMA : A CASE REPORT	
Ruth Sarah Wibisono ¹ , Tamara Yuanita ²	617
ROOT CANAL RETREATMENT OF PERIAPICAL ABSCESS ON MAXILLARY LATERAL INCISOR	
Sasi Suci Ramadhani ¹ , Ratna Meidyawati ²	623
APEXIFICATION AND ESTHETIC MANAGEMENT OF DISCOLORED AND FRACTURED NECROTIC TOOTH WITH IMMATURE ROOT: A CASE REPORT	
Sinta Puspitadewi ¹ , Adioro Soetojo ²	629

CASE REPORT

ROOT CANAL TREATMENT IN FIRST LOWER LEFT MOLAR WITH MIDDLE MESIAL AND RADIX ENTOMOLARIS : CASE REPORT

Raymond Kandou*, Nirawati Pribadi**

*Resident, Departement of Conservative Dentistry

** Staff Department of Conservative Dentistry

Faculty of Dental Medicine, Universitas Airlangga Surabaya, Indonesia

ABSTRACT

Background: Root canal treatment aims to eliminate bacteria, infected pulp, necrotic tissues, and debris which located inside the pulp chamber and root canal. **Aims:** To perform root canal treatment on first lower left molar with middle mesial and radix entomolaris case in order to maintain the teeth in the oral cavity for a long period of time. **Case:** A 25 year-old female patient came to RSGMP UNAIR clinic with a complaints of feel pain when chewing food and when being exposed to hot water since a week ago, and the patient wants to save her tooth. After being examined, it shows a negative in cold thermal test, and positive in percussion and palpation test, with mobility of one degree. The Radiographic shows an indication of radiolucent in 1/3 apical of the mesial and distal root. Hence, the patient is **diagnosed** with the presence of pulp necrosis with symptomatic apical periodontitis in tooth 36. **Case management :** Root canal preparation was then performed by crown down technique using manual k file 8 and 10 for scouting, pathfiles for glidepath and shaping with protaper next x1- x2. Then, irrigation is done by using Naocl 5,25%, EDTA 17%, Chlorhexidine 2% and Aquadest, accompanied by the use of endoactivator in the irrigation activation. A calcium hydroxide tooth canal dressing was applied for one week, obturation was then performed using single cone with warm vertical compaction technique, and restoration was done by using prefabricated fibre post placement and porcelain fused to metal crown.

Conclusion: Operator requires the knowledge of the anatomy of the root canal and the experience to perform a proper access opening techniques in order to avoid missed canal in endodontic treatment

Keywords: middle mesial, radix entomolaris, root canal treatment

Correspondence : Raymond Kandou, Resident of Conservative Dentistry, Faculty of Dental Medicine, Airlangga University. Email: raymondkandou@hotmail.com

INTRODUCTION

The final objective of endodontic procedures should be the total obturation of the root canal space. Biologic necessity requires the elimination of the protein degradation products, bacteria and bacterial toxins which produced from necrotic and gangrenous root canals. These can be achieved by thorough mechanical and chemical cleansing of the entire pulp cavity and its complete obturation with an inert filling material and a coronal filling preventing ingress of microorganisms.

However, variation in root and root canal systems anatomy may represent an additional difficulty to the final outcome. Endodontic failure may be associated with persistence of infection because of a missed canal or inefficient elimination of microorganisms and necrotic pulp remnants during chemomechanical instrumentation.

In the permanent dentition, the mandibular first molar has been considered to assume maximum bite force and possess the most important masticatory function. The majority of mandibular first molars are two-rooted with two mesial and one distal canal (Barker et al. 1974, Vertucci 1984). Carabelli was the first to mention the presence of a supernumerary third root as a frequent variation in this tooth group, located either lingually (radix entomolaris) or buccally (radix paramolaris) (Wang et al. 2011).

During the growth of the root, the connective pulp tissue is compressed by the

accumulation of secondary dentin, which would form vertical dentinal partitions inside the root canal activity, thus creating 3 mesial root canals. Some authors support the view that middle mesial canal can be easily located in patients of a younger age group, but progressively decrease its incidence with age (Gulabivala K. et al, 2001). This case report is about a patient who presented with pain and swelling in relation to 36. The initial treatment was started with removal old filling, removal caries, and pre-endodontic therapy (rewalling). Root canal treatment was planned in tooth 36. After all the symptoms disappear, fixed prosthesis was given in.

CASE

A 25 year old female patient reported to the Department Conservative Clinic with a complaints of feel pain when chewing food and when being exposed to hot water in lower left posterior tooth since a week ago, and the patient wants to save her tooth. After being examined, it got a negative in cold thermal test, positive in percussion and palpation test, with mobility of one degree. (figure 1)

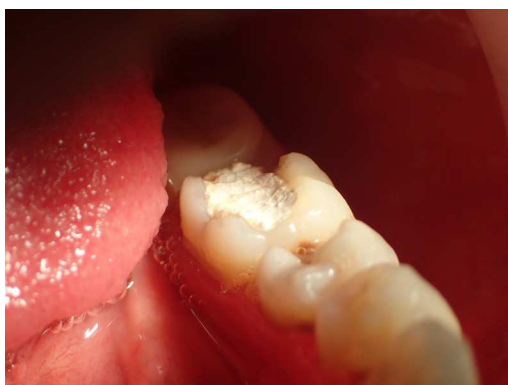

Figure 1. Pre-operative intra oral

In radiograph examination, There is a lesion found in tooth 36, described with radiolucent in 1/3 apical of the mesial and distal root (figure 2)

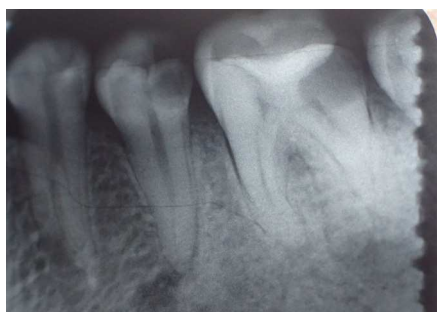

Figure 2. Pre-operative radiography

CASE MANAGEMENT

After going through the explanation of the treatment plan, the patient agreed to do the root canal treatment. The initial treatment was started with removal old filling (figure 3), rewalling (figure 4), and access opening (figure 5), followed by root canal treatment in tooth 36. Access to the pulp chamber was achieved. Working length was estimated by an apex locator (Root ZX: Morita, Japan)

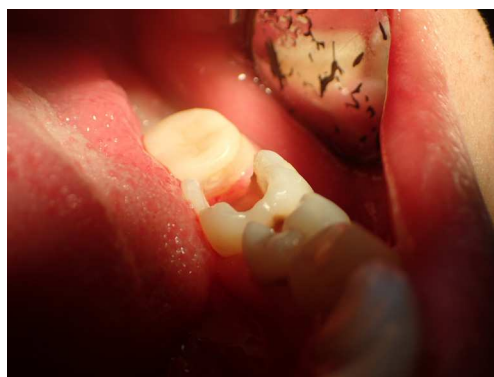


Figure 3. Removal old filling

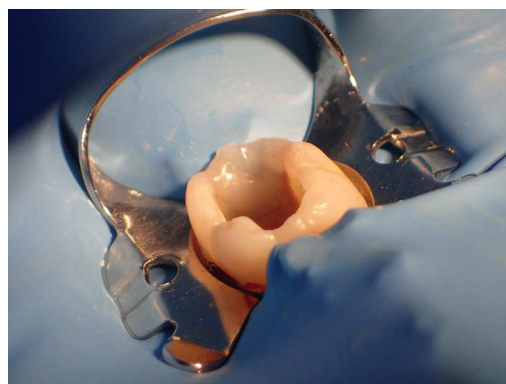


Figure 4. Rewalling

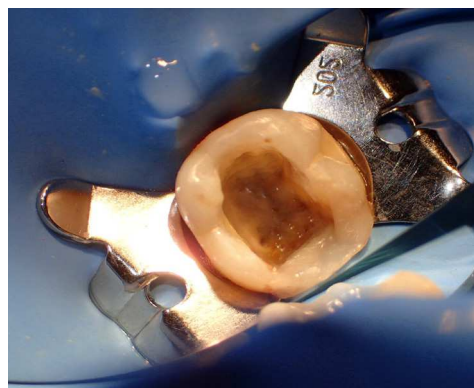


Figure 5. Access opening

Root canal preparation was then performed by crown down technique using manual k file 8 and 10 for scouting, pathfiles for glidepath and shaping with protaper next x1- x2 (figure 6). Then, irrigation

is done by using Naocl 5,25%, EDTA 17%, Chlorhexidine 2% and Aquadest, accompanied by the use of endoactivator in the irrigation activation.

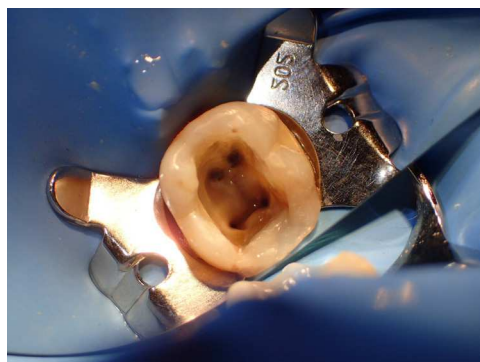


Figure 6. Root canal preparation

After all the main root canals have been prepared, re-examination was done on the mesial aspect, and an additional canal was found in the middle mesial canal (figure 7). It was then shaped using manual k file 8 and 10 for scouting, pathfiles for glidepath and shaping with protaper next x1- x2 (figure 8).

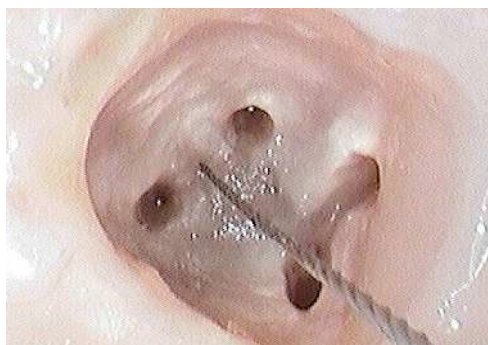

Figure 7. Middle mesial canal

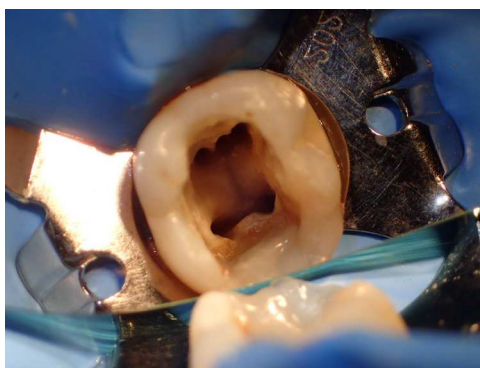

Figure 8. Middle mesial canal shaped

A calcium hydroxide tooth canal dressing was applied for one week (figure 9). One week later patient came with no symptoms. Trial guttaper and working length confirmed (figure 10a and 10b), obturation was then performed using single cone with warm vertical compaction technique (figure 11 a and 11 b). Final restoration was done by using prefabricated fibre post placement and fluorocore for core build up (figure 12a and 12b). Fibre post placement confirmed by radiograph (figure 13). Followed by placement of porcelain fused to metal crown (figure 14).

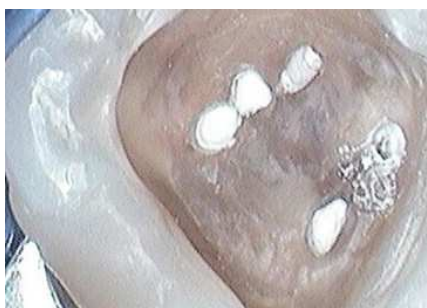

Figure 9. Calcium hydroxide dressing

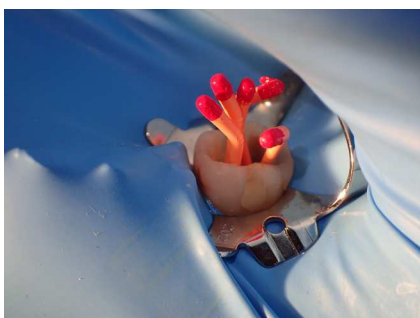


Figure 10 a. Trial gutta percha

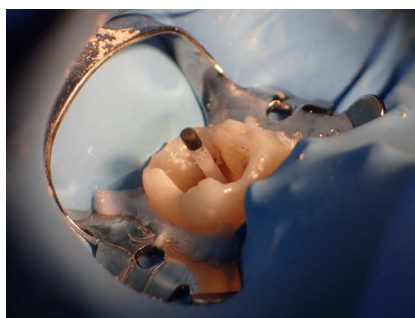


Figure 12 a. fibre post placement

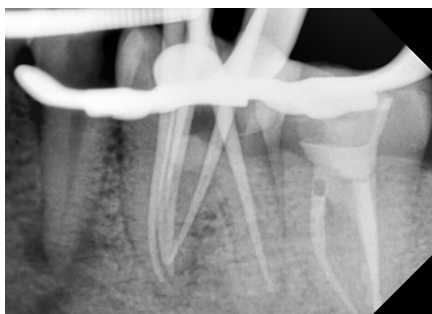

Figure 10 b. Working length confirmation

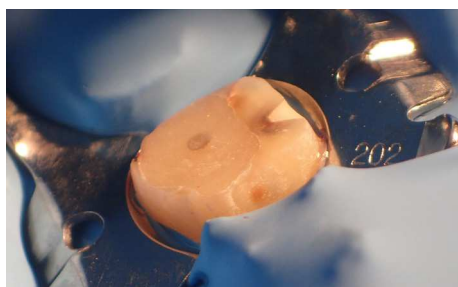


Figure 12 b. Core build up

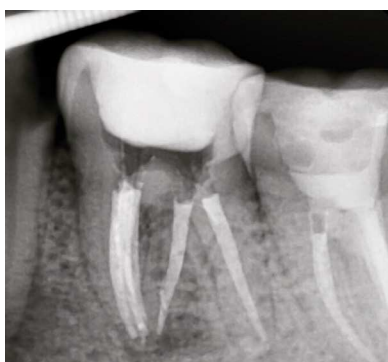

Figure 11 a. Obturation

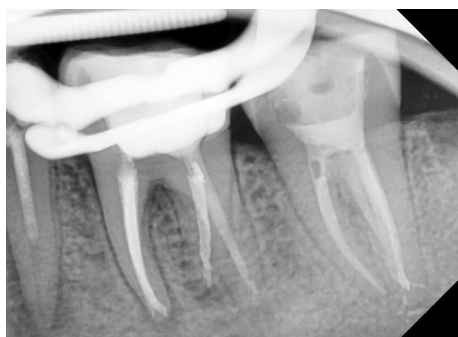

Figure 13. Fibre post in radiograph

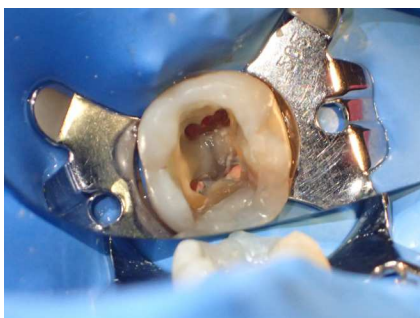

Figure 11 b. Obturation

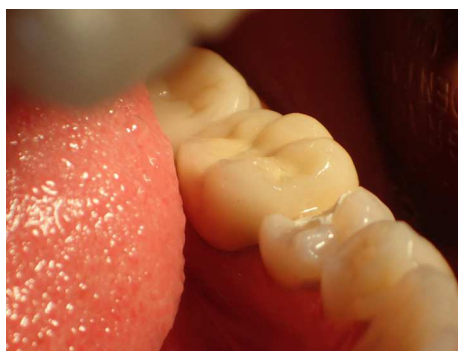


Figure 14. Crown placement

DISCUSSION

The mandibular molars usually have two roots with two canals in mesial roots and one canal in distal root. When an additional mesial canal is present, it is located between the two main canals and its orifice is often hidden by a dentinal projection of the pulp chamber wall. The presence of a third canal (middle mesial) in the mesial root of the mandibular molars has been reported to have an incidence of 0.95%-15%. This additional canal may be independent with a separate foramen, or the additional canal may have a separate foramen and join apically with either the mesiobuccal or mesiolingual canal.

Extra roots as the radix entomolaris in mandibular molars, are an additional challenge, which begins at case assessment and involves all operative stages; that's why an early detection of the presence of any anatomical variations is essential to let the clinician choose the best operative strategy in terms of access cavity design, root canal opening localization, canal shaping, filling and restorative techniques (Cardinali F. et al, 2009). Thus, an awareness and understanding of root canal anatomy is essential to carry out a safe shaping respectful of the original endodontic anatomy for improving the predictability of root canal treatment.

Radiograph is necessary to identify radix entomolaris cases. Periapical preoperative radiograph need to be taken for confirming radix entomolaris cases. But, sometimes single angle of periapical

radiograph is not enough to identify, and different angles need to be taken using SLOB (same lingual opposite buccal) technique. The prevalence of radix entomolaris on mandibular first molar has been reported by many literatures. Wang et al, 2011 reported that it has been found in a population of 95 patients in a total of 350 cases (27,14%) and (60,13%) cases (95 of 158) had the fourth canal arising from radix entomolaris, and the dimension of the radix entomolaris can vary from a short conical extension to a mature root with normal length and root canal, which are curved buccolingually. Basically, there are two classifications on radix entomolaris. One is a classification that has been classified by Ribeiro & Consolaro (1997) based on the curvature of the root, there are 3 types of radix entomolaris according to its curvature : (1) a straight root / root canal, (2) initially curved entrance of the root canal and the continuation as a straight root or root canals, (3) initial curve in the coronal third of the root canal and a second buccally orientated curve starting from the middle third (the radix entomolaris may also have a pronounced 90 degree buccal curve in the apical part of the root).

Reference

1. De Moor RJ, Deroose CA, Calberson FL. The Radix Entomolaris in Mandibular First Molars: An Endodontic Challenge. *International Endodontic Journal*; 37 : 789-799, 2004

2. Calberson FL, De Moor RJ, Deroose CA. The Radix Entomolaris and Paramolaris : Clinical Approach in Endodontics. *Journal of Endodontic*; 33: 58-63, 2007
3. Gulabivala K, Aung TH, Alavi A, Ng YL. Root and canal morphology of Burmese mandibular molars. *Int Endod J* 2013; 34: 359-70
4. Wang Q, Yu G, Zhou XD, Peters OA, Zheng QH, Huang DM. Evaluation of X-Ray Projection Angulation for Successful Radix Entomolaris Diagnosis in Mandibular First Molars in Vitro. *Journal of Endodontic*; 37: 1063-1068, 2011
5. Cardinali F, Cerutti F, Cerutti A, Tosco E. Preoperative diagnosis of a third root canal in first and second maxillary premolars: a challenge for the clinician. *ENDO (Lond Engl)* 2009; 3 (1): 51-57