

East Java Extract Propolis as Potential Intracanal Medicament in Experimentally Induced Chronic Apical Periodontitis

by Sri Kunarti

Submission date: 18-Dec-2019 12:08PM (UTC+0800)

Submission ID: 1236356592

File name: 2_IndianJDentRes_2019_30_3_342_264112.pdf (5.86M)

Word count: 3738

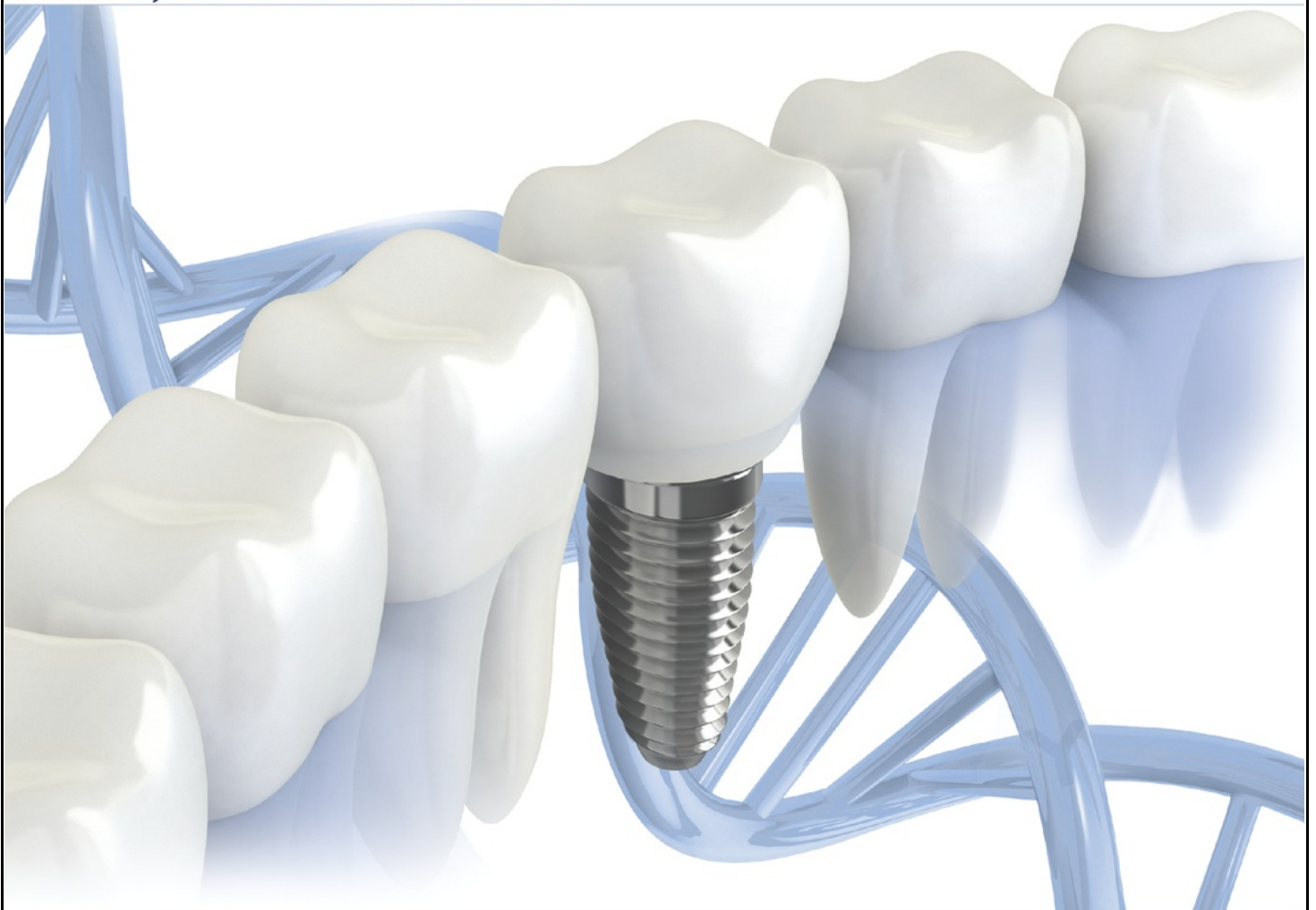Character count: 20440



IJDR

Indian Journal of Dental Research

www.ijdr.in



Official Publication of

Indian Society for Dental Research
www.isdrindia.com

International Association for Dental Research - Indian Division
www.iadr.com

East Java Extract Propolis as Potential Intracanal Medicament in Experimentally Induced Chronic Apical Periodontitis

Abstract

Introduction: A persistent infection after cleaning and shaping root canal is the main etiology of root canal treatment failure. *Enterococcus faecalis* has been considered as one of the most resistant species in root canal treatment. *E. faecalis* can stimulate receptor activator of nuclear factor- κ B ligand (RANKL) which can increase nuclear factor of activated T-cell (NFATc1) in chronic apical periodontitis. East Java propolis has antibacterial effects and is biocompatible with *in vitro* effects. **Aim:** This study is aimed to analyze the East Java propolis extract as potential intracanal medicament in chronic apical periodontitis caused by *E. faecalis* bacterial infection. **Materials and Methods:** This study used 30 Wistar rats divided into three groups. In Group I, the first upper right molar tooth as healthy tooth was used for negative control group. In Group II, the first upper right molar tooth was used for a prepared root canal, and 10 ml brain heart infusion broth containing *E. faecalis* ATCC29212 10^6 CFU was injected into the canal and restored with glass-ionomer cement (GIC) for the experimentally induced chronic apical periodontitis group. In Group III, after root canal preparation, *E. faecalis* ATCC 29212 10^6 CFU was injected, and then, 10 μ l propolis applied and tooth restored with GIC. It took 21 days for the periapical lesions to develop after pulp infection. The rats were then sacrificed to conduct immunohistochemical examinations in order to measure the expressions of RANKL and NFATc1. **Results:** The average of RANKL and NFATc1 expression in Group III was significantly lower than those in the experimentally induced chronic apical periodontitis group ($P < 0.05$). **Conclusion:** It can be concluded that East Java propolis extract is a potential intracanal medicament through the study of experimentally induced chronic apical periodontitis caused by *E. faecalis* infection in Wistar rats.

Keywords: *Enterococcus faecalis*, East Java propolis, nuclear factor of activated T-cell, Receptor activator of nuclear factor- κ B ligand

Introduction

Persistent infection after cleaning and shaping root canal is the primary etiology of root canal treatment failure. *Enterococcus faecalis* is the most common species found in root canal treatment failure. The prevalence of *E. faecalis* in re-treatment is 89.9%.^[1,2]

Chronic inflammation in the periapical area of the teeth is known as chronic apical periodontitis, an active host defense against invasion of bacteria and their toxins. It is felt that if chronic apical periodontitis can be prevented, the failure of root canal treatment will be overcome.

Propolis is a popular drug in many Asian countries and has broad spectrum of biological activity, including antibiotics, antifungal, anti-inflammatory, and anticancer effects. Caffeic acid

phenethyl ester (CAPE) is the active component (over 50%) contained in propolis. CAPE is a potent inhibitor for activation of nuclear factor- κ B (NF- κ B) that can inhibit NF- κ B and reduce COX-2 expression, a gene derived from the regulation of NF- κ B. Propolis is also considered as anti-inflammatory and an immunomodulator.^[3]

Receptor activator of NF- κ B ligand (RANKL) is a family of tumor necrosis factor (TNF)-related activation-induced cytokine, osteoprotegerin ligand, and osteoclast differentiation factor. RANKL is a Type II membrane protein, which has RANK receptor, is a key of essential bone remodeling in the development and activation of osteoclasts.^[4]

RANKL prevents osteoclastogenesis, which will cause bone resorption. RANKL plays a very dominant role over the setting of bone resorption, so none could replace it in the

This is an open access journal, and articles are distributed under the terms of the Creative Commons Attribution-NonCommercial-ShareAlike 4.0 license, which allows others to remix, tweak, and build upon the work non-commercially, as long as appropriate credit is given and the new creations are licensed under the identical terms.

For reprints contact: reprints@medknow.com

How to cite this article: Yuanita T, Kunarti S, Zubaidah N. East java extract propolis as potential intracanal medicament in experimentally induced chronic apical periodontitis. Indian J Dent Res 2019;30:342-6.

Tamara Yuanita,
Sri Kunarti,
Nanik Zubaidah

Department of Conservative
Dentistry, Faculty of Dental
Medicine Airlangga University,
Surabaya, East Java, Indonesia

Address for correspondence:

Sri Kunarti,
Department of Conservative
Dentistry, Faculty of Dental
Medicine Airlangga University,
Surabaya, East Java, Indonesia.
E-mail: atty.prijambodo@gmail.com

Access this article online

Website: www.ijdr.in

DOI: 10.4103/ijdr.IJDR_236_17

Quick Response Code:



process of bone resorption when there is no RANKL.^[5] The optimal RANKL expression in the 3rd week is periapical lesion formation, which then decreases at week 4 followed by periapical bone destruction.

Nuclear factor of activated T-cell (NFATc1) is a key regulator in bone because NFAT signaling is an important factor for osteoclast differentiation and bone resorption. Is an osteoclastogenesis controller because it coordinates bone resorption by recruiting osteoclast precursor to multinucleus.^[6]

NFAT, a key regulator in bone, is a group of transcription factors that have been identified in T-cells, having four isoforms, c1-c4. Activated NFAT will result in translocation to the nucleus and binding to specific regions on the target gene. Activation of NFATc1 can control osteoclast differentiation.^[7] NFATc1 activated by TRAF6 plays an important role in osteoclastogenesis.^[8,9] NFATc1 forms complex transcriptions of specific osteoclasts.^[8,10]

NFATc1 activation induces TRAP + osteoclast formation, resulting in multinucleated osteoclasts (mature osteoclasts) which then triggers formation of active osteoclasts (ruffled border osteoclasts). The higher the production of active osteoclasts, the more bone resorption will occur.^[11] For those reasons, this research aimed to analyze the effectiveness of East Java propolis extract as intracanal medicaments against RANKL and NFATc1 for experimentally induced chronic apical periodontitis caused by *E. faecalis* bacteria.

Materials and Methods

This study used thirty Wistar rats divided into three groups, namely, negative control group, *E. faecalis* group, and treatment group with East Java propolis. The samples taken were homogeneous in gender, age, and weight. To obtain internal validity, those samples were randomly divided into three groups. Data obtained then was examined by statistical analysis to achieve the objectives of the study.

Next, those Wistar rats aged 12 weeks were anesthetized 80 mg/kg of ketamine and 10 mg/kg of xylazine with intraperitoneal technique in sterile phosphate buffered saline. Those rats then were fixed on retraction board, and later, the pulp of their right maxillary molar was opened using a low-speed electric handpiece with a round bur sized ¼. Group I was as the negative control group that has healthy pulp. Then, in Group II, which was the *E. faecalis* group, the pulps opened were immediately induced with 10 ul of BHI-b containing 10⁶ CFU of *E. faecalis* ATCC29212 bacteria and filled with glass-ionomer cement (GIC) to prevent contamination with oral microorganisms. Meanwhile, in Group III, as the treatment group, the pulps opened were immediately induced with 10 ul BHI-b containing 10⁶ CFU of *E. faecalis* ATCC29212 bacteria, and then, 10 µL of propolis was applied and filled with GIC. It took 21 days to manifest the chronic apical periodontitis after pulp infection.^[12] The Wistar rats

were sacrificed for immunohistochemical examination to measure the expression of RANKL and NFATc1.

Results

ANOVA test [Table 1] was conducted to know whether there were differences of RANKL expression among the groups after the application of East Java propolis extract.

To know the significance of the differences of RANKL among the groups, Tukey’s Honest Significant Difference (HSD) test was conducted as shown in Table 2.

The results [Figure 1] showed that there were significant differences of RANKL between the negative control group and the *E. faecalis* group within the propolis group.

Next, to know whether there were differences of NFATc1 among the groups, ANOVA test was conducted as shown in Table 3.

To know the significance of the differences of NFATc1 among the groups, Tukey HSD Test was conducted as shown in Table 4.

The results [Figure 2] showed that there were significant differences of NFATc1 between the negative control group and the *E. faecalis* group within the propolis group.

Table 1: The results of ANOVA test for receptor activator of nuclear factor-kappa B ligand variables

Research groups	n	S positive RANKL cells		
		Mean	SD	P
Negative control	10	8.20	1.92	0.000*
<i>E. faecalis</i>	10	14.80	3.11	
Propolis	10	8.00	1.41	

*Significance (P<0.05). n=Number of samples SD=Standard deviation, RANKL=Receptor activator of nuclear factor-kappa B ligand, *E. faecalis*=*Enterococcus faecalis*

Table 2: The results of Tukey’s honestly significant difference test on receptor activator of nuclear factor-kappa B

	Negative control	<i>E. faecalis</i>
Negative control		P=0.02*
<i>E. faecalis</i>	P=0.02*	
Propolis	P=0.98	P=0.02*

*Significance (P<0.05). *E. faecalis*=*Enterococcus faecalis*

Table 3: The results of ANOVA test on nuclear factor of activated Tc1 variables

Research group	n	Σ positive NFATc1 cells		
		Mean	SD	P
Negative control	10	7.7	1.49	0.000*
<i>E. faecalis</i>	10	19	2.16	
Propolis	10	7.6	1.34	

*Significance (P<0.05). n=Number of samples, *E. faecalis*=*Enterococcus faecalis*, SD=Standard deviation, NFAT=Nuclear factor of activated T

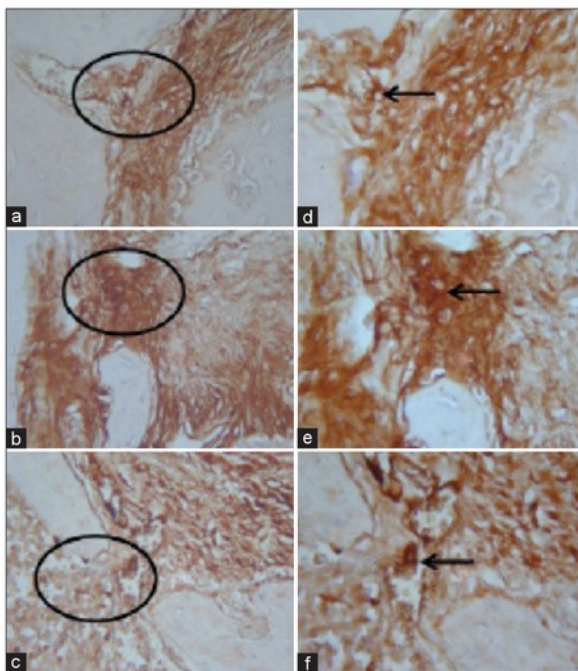


Figure 1: Expression of receptor activator of nuclear factor-kappa B ligand in periapical region. (a and d) is a negative control group, (b and e) is a *Enterococcus faecalis* group, and (c and f) is propolis group

Table 4: The results of Tukey's honestly significant difference test on nuclear factor of activated Tc1

	Negative control	<i>E. faecalis</i>
Negative control		$P=0.991$
<i>E. faecalis</i>	$P=0.000^*$	
Propolis	$P=0.991$	$P=0.000^*$

*Significance ($P<0.05$). *E. faecalis*=*Enterococcus faecalis*

Discussion

Pulp necrosis lead to the emergence of chronic apical periodontitis. Chronic apical periodontitis usually is a continuation of acute apical periodontitis. Chronic apical periodontitis can also be considered as a long inflammatory process and enlarged lesions are seen without subjective signs or symptoms. Apical periodontitis consequently can be an indicator of root canal treatment failure often without clinical symptoms. It is only through radiographic imaging that chronic apical periodontitis can be detected.

Chronic apical periodontitis moreover is closely related to local factors such as bacteria. The complex anatomical shape of the root canal makes complete removal of infectious sources impossible. Cleaning and shaping phases of root canal can cause bacteria to enter into the apical region thus resulting in reinfection.^[13] Chronic apical periodontitis can thus be known as an asymptomatic condition originating in the pulp caused by bacteria, associated with inflammation and periapical tissue destruction.^[14]

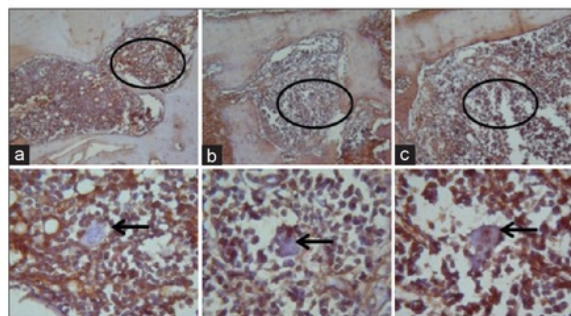


Figure 2: The expression of nuclear factor of activated T-cell in periapical Wistar rats. (a) Negative control, (b) Propolis, (c) *Enterococcus faecalis*

E. faecalis bacteria have been identified as a species that can survive the root canal treatment and also persist as pathogens in dentin tubules since they have the nature of genetic polymorphisms and can bind to dentin because of their serine protease, gelatinase, and gelatin-binding protein.^[15] *In vitro* research has shown that *E. faecalis* can survive for even 12 months post obturation.^[16] Since *E. faecalis* bacteria can survive in the apical region of root canal treated teeth thus leading to failure of the root canal treatment itself, it is important to look for natural and potential medicament materials. These medicament materials must have antibacterial and antibiofilm properties against *E. faecalis* as well as reduce the formation of RANKL and NFATc1 as a transcription factor controlling osteoclasts causing periapical bone resorption.

Propolis as a potential natural medicament is a yellow-brown to dark brown resin, the substance that the honeybee, *Apis mellifera*, collects from tree buds, sap, shrubs, and other vegetable sources. In other words, propolis is a generic name given to a resin material collected by honeybees from various plants. The bees mix the resin material with an enzyme secreted from their mandibular glands. Nonetheless, components found in propolis are unchanged.

In addition, propolis is composed of resin (50%), wax (30%), essential oils (10%), pollen (5%), and organic components (5%).^[17] The resin contains flavonoids, phenols, and various forms of acid.^[18] One of the phenols found in propolis is CAPE. CAPE is a phenolic compound, structurally related to flavonoids, and considered as one of the main components of propolis. CAPE, based on *in vitro* and *in vivo* researches, is also considered to have both anti-inflammatory properties that are potent inhibitors of NF- κ B and anti-inflammatory effects. NF- κ B activation then is induced by mitogen and cytokines. Next, CAPE inhibits the synthesis of DNA, which binds to NF- κ B suppressing the induction of gene expression in pro-inflammatory cytokines. CAPE also directly inhibits both COX-1 and COX-2 enzymes and COX-2 gene expression activation (prostaglandin) as well as acts as an immunostimulant.^[19]

In recent years, *in vitro* research on East Java propolis extract in the field of dental conservation has shown that propolis has antibacterial and antibiofilm properties against *E. faecalis* at a concentration of 12%. In addition, propolis is safely used at a concentration of 25%.^[20] However, *in vivo* researchers still cannot clearly explain how periapical lesions can be prevented. Thus, this research aimed to utilize East Java propolis extract as biocompatible and potential intracanal medicaments for chronic apical periodontitis caused by *E. faecalis* bacterial resistance.

Based on the results of this research, it is known that East Java propolis extract could reduce apical periodontitis ($P < 0.05$) induced by *E. faecalis* bacteria since propolis can inhibit NF- κ B and pro-inflammatory cytokines, such as IL-1 and TNF- α . Propolis extract significantly suppresses inflammation by blocking the activation of NF- κ B as a transcription factor, so that it does not penetrate into the cell nucleus.^[21] Osteoclast formation and bone resorption are induced by RANKL and TNF. Those cytokine inductions require NF- κ B p50 and p52 as well as c-Fos and NFATc1 expressed on osteoclast precursors. Similarly, a research conducted by Yamashita et al.^[22] shows that RANKL and TNF directly induce osteoclast formation derived from NF- κ B p50/p52 when c-Fos or NFATc1 is expressed. RANKL and TNF induced c-Fos expressions, which require RANKL to induce the activation of NFATc1, so the number and capacity of osteoclasts will increase.

Moreover, based on the results of this research, it is also known that East Java propolis could significantly lower NFATc1 ($P < 0.05$). NFATc1 is a key regulator in bone because NFAT signaling is an important factor for osteoclast differentiation and bone resorption. It is an osteoclastogenesis controller because it coordinates bone resorption by recruiting osteoclast precursors to become multinuclear.^[6]

CAPE in East Java propolis extract, furthermore, is known to be able to inhibit NF- κ B, NFAT, and activator protein-1 transcription. CAPE can also inhibit dependent transcriptional activity of NF- κ B without causing degradation of cytoplasmic NF- κ B inhibitor protein, iB κ B (CAPE can inhibit NF- κ B dependent transcriptional activity without caused degradation of NF- κ B cytoplasmic protein inhibitor, iB κ B). It means that NF- κ B can bind to DNA and Gal4-p65 transcriptional activity of the hybrid protein if there is CAPE. In addition, CAPE can also inhibit DNA binding and transcriptional activity of NFAT dephosphorylation. Next, NFATc1 activation induces TRAP + osteoclast formation, resulting in multinucleated osteoclast (mature osteoclasts) then triggering formation of active osteoclasts (ruffled border osteoclasts). Therefore, the higher the production of active osteoclasts is, the more bone resorption will occur.^[11]

Propolis as a natural product is known also as an antimicrobial agent.^[20] On the other hand, root canal

treatment failure caused by *E. faecalis* bacterial resistance is a challenge. Therefore, East Java propolis extract can reduce the number of osteoclasts. This is in line with a research conducted by Pileggi et al. proving that propolis can prevent osteoclast maturation.^[23] Propolis can also inhibit the final stage of osteoclast maturation, including fusion of osteoclast precursors to form giant cells and actin rings. These support the hypothesis that propolis can be used as a medicament to reduce resorption and as an antibacterial against oral pathogens, including *E. faecalis*.

In addition, Pileggi et al. studied the direct inhibitory effect of propolis in the final stages of osteoclast maturation. Meanwhile, Ang et al. reported that propolis inhibits osteoclast differentiation through increased OPG binding to RANKL preventing bone resorption.^[24] Besides that, CAPE is also known as an active component of propolis that can reduce osteoclastogenesis and bone resorption by pressing RANKL.^[25] In conclusion, East Java propolis extract can be considered as an effective intracanal medicament for experimental chronic apical periodontitis caused by *E. faecalis* bacterial resistance by decreasing RANKL and NFATc1 expressions in periapical tissues of Wistar rats.

Conclusion

The east java extract propolis is potential intracanal medicament in experimentally chronic apical periodontitis cause by *E. faecalis*, bacterial resistance by decreasing RANKL and NFATc1 expression in periapical tissue of wistar rats.

Acknowledgment

Thank's to Tony Hapsoro for statistical analyses of the experimental data.

Financial support and sponsorship

This work was financially supported by the Government of Indonesia through Institution of Research and Technology Airlangga University.

Conflicts of interest

There are no conflicts of interest.

References

1. Sedgley C, Nagel A, Dahlén G, Reit C, Molander A. Real-time quantitative polymerase chain reaction and culture analyses of *Enterococcus faecalis* in root canals. *J Endod* 2006;32:173-7.
2. Sedgley CM. Virulence of endodontic bacterial patogen. In: Fouad AF, editor. *Endodontic Microbiology*. 1st ed. Baltimore USA: Wiley-Blackwell; 2009. p. 130-51.
3. Marcio AR, Silvana AL, Rosana NM, Maria NS, Flavia RF. Mechanism of action underlying the antiinflammatory and immunomodulatory effect of propolis: A brief review. *Braz J of Pharm* 2012;22:208-19.
4. Teitelbaum SL, Ross FP. Genetic regulation of osteoclast development and function. *Nat Rev Genet* 2003;4:638-49.
5. Kearns AE, Khosla S, Kostenuik PJ. Receptor activator of nuclear factor kappaB ligand and osteoprotegerin regulation of bone

- remodeling in health and disease. *Endocr Rev* 2008;29:155-92.
6. Winslow MM, Pan M, Starbuck M, Gallo EM, Deng L, Karsenty G, *et al.* Calcineurin/NFAT signaling in osteoblasts regulates bone mass. *Dev Cell* 2006;10:771-82.
 7. Lambertini E, Penolazzi E, Tavanti B, Pecaterra B. Modulation of expression of specific transcription factors involved in the bone microenvironment. *Minerva Biotechnol* 2008;20:69-77.
 8. Ikeda F, Nishimura R, Matsubara T, Tanaka S, Inoue J, Reddy SV, *et al.* Critical roles of c-jun signaling in regulation of NFAT family and RANKL-regulated osteoclast differentiation. *J Clin Invest* 2004;114:475-84.
 9. Takayanagi H. The role of NFAT in osteoclast formation. *Ann N Y Acad Sci* 2007;1116:227-37.
 10. Kim K, Kim JH, Lee J, Jin HM, Lee SH, Fisher DE, *et al.* Nuclear factor of activated T cells c1 induces osteoclast-associated receptor gene expression during tumor necrosis factor-related activation-induced cytokine-mediated osteoclastogenesis. *J Biol Chem* 2005;280:35209-16.
 11. Asagiri M, Takayanagi H. The molecular understanding of osteoclast differentiation. *Bone* 2007;40:251-64.
 12. Fukada SY, Silva TA, Saconato IF, Garlet GP, Avila-Campos MJ, Silva JS, *et al.* INOS-derived Nitric Oxide modulates infection-stimulated bone loss. *J Dent Res* 2008;87:1155-9.
 13. Bergenholtz G, Preben HB, Reit C. Apical periodontitis. In: *Textbook of Endodontology*. 2nd ed. UK: Blackwell Publ. Ltd.; 2010. p. 113-27.
 14. Metzger ZV, Tzhak I, Bramovitz A. Periapical lesion of endodontic origin. In: Ingle JI, Bakland LK, Baumgartner JC, editors. *Ingle's Endodontic*. 6th ed. Shelton USA: Mc Graw-Hill; 2008. p. 494-519.
 15. Stuart CH, Schwartz SA, Beeson TJ, Owatz CB. *Enterococcus faecalis*: Its role in root canal treatment failure and current concepts in retreatment. *J Endod* 2006;32:93-8.
 16. Sedgley CM. The influence of root canal sealer on extended intracanal survival of *Enterococcus faecalis* with and without gelatinase production ability in obturated root canals. *J Endod* 2007;33:561-6.
 17. Gómez-Caravaca AM, Gómez-Romero M, Arráez-Román D, Segura-Carretero A, Fernández-Gutiérrez A. Advances in the analysis of phenolic compounds in products derived from bees. *J Pharm Biomed Anal* 2006;41:1220-34.
 18. Borrelli F, Maffia P, Pinto L, Ianaro A, Russo A, Capasso F, *et al.* Phytochemical compounds involved in the anti-inflammatory effect of propolis extract. *Fitoterapia* 2002;73 Suppl 1:S53-63.
 19. Williams GT. Managing Chronic Inflammation – Natural Solutions. The Standart Concise Update of Important Issues Concerning Natural Health Ingredients. 2006;7:1-7.
 20. Yuanita T, Hutagalung J, Widjiastuti I, Rulianto M, Mooduto L. Minimum bacterial concentration of east java propolis to biofilm of *Enterococcus faecalis*. *E J Apimondia Kiev-Ukraine*. 2013.
 21. Wang KH, Liang C, Lin JL, Chiang BL. Caffeic acid phenethyl ester inhibits nuclear factor-κB and protein kinase B signalling pathways and induces caspase-3 expression in primary human CD4⁺ T cells. *Clin Exp Immunol* 2010;160:223-32.
 22. Yamashita T, Yao Z, Li F, Zhang Q, Badell IR, Schwarz EM, *et al.* NF-κappaB p50 and p52 regulate receptor activator of NF-κappaB ligand (RANKL) and tumor necrosis factor-induced osteoclast precursor differentiation by activating c-Fos and NFATc1. *J Biol Chem* 2007;282:18245-53.
 23. Pileggi R, Antony K, Johnson K, Zuo J, Shannon Holliday L. Propolis inhibits osteoclast maturation. *Dent Traumatol* 2009;25:584-8.
 24. Ang ES, Pavlos NJ, Chai LY, Qi M, Cheng TS, Steer JH, *et al.* Caffeic acid phenethyl ester, an active component of honeybee propolis attenuates osteoclastogenesis and bone resorption via the suppression of RANKL-induced NF-κappaB and NFAT activity. *J Cell Physiol* 2009;221:642-9.
 25. Ha J, Choi HS, Lee Y, Lee ZH, Kim HH. Caffeic acid phenethyl ester inhibits osteoclastogenesis by suppressing NF κappaB and downregulating NFATc1 and c-Fos. *Int Immunopharmacol* 2009;9:774-80.

East Java Extract Propolis as Potential Intracanal Medicament in Experimentally Induced Chronic Apical Periodontitis

ORIGINALITY REPORT

25%

SIMILARITY INDEX

22%

INTERNET SOURCES

14%

PUBLICATIONS

%

STUDENT PAPERS

MATCH ALL SOURCES (ONLY SELECTED SOURCE PRINTED)

8%

★ www.apimondia2015.com

Internet Source

Exclude quotes Off

Exclude matches Off

Exclude bibliography On