

East Java propolis effect on toll-like receptor 2 and nuclear factor-kappa B expression in chronic apical periodontitis

by Sri Kunarti

Submission date: 18-Dec-2019 12:11PM (UTC+0800)

Submission ID: 1236358223

File name: 6_SaudiEndodJ83212-7280238_020120.pdf (1.12M)

Word count: 3652

Character count: 19306

Original Article

East Java propolis effect on toll-like receptor 2 and nuclear factor-kappa B expression in chronic apical periodontitis

Tamara Yuanita, Nanik Zubaidah, Sri Kunarti¹

Departments of Conservative Dentistry and ¹Endodontics, Faculty of Dental Medicine, Airlangga University, Surabaya, Indonesia

Abstract

A persistent infection after cleaning and shaping a root canal is the main etiology of root canal treatment (RCT) failure. *Enterococcus faecalis* has been considered as one of the most resistant species post-RCT. *E. faecalis* can stimulate toll-like receptor 2 (TLR-2) which can increase nuclear factor-kappa B (NF-κB) in chronic apical periodontitis. East Java propolis has *in vitro* antibacterial and biocompatible effects.

Aim: This study aimed to analyze the effectiveness of East Java propolis extract as a potential intracanal medicament in chronic apical periodontitis caused by *E. faecalis* bacterial infection by the decrease of TLR-2 and NF-κB.

Materials and Methods: Maceration method was conducted for propolis extract. This study used thirty Wistar rats which were divided into three groups, a negative control (Group I); a positive control that the first upper right molar root canal induced with *E. faecalis* ATCC29212 and filled using glass ionomer cement (GIC) (Group II) and treatment group that the first upper right molar root canal induced with *E. faecalis* ATCC29212 and 10 μl propolis was applied and filled using GIC (Group III). After 21 days, those rats were sacrificed, and then immunohistochemical examination was conducted to investigate the expressions of TLR-2 and NF-κB.

Results: The mean of TLR-2 and NF-κB expressions on Group III was significantly lower than that of the positive control group ($P < 0.05$).

Conclusion: It can be concluded that East Java propolis extract is a potential intracanal medicament in chronic apical periodontitis caused by *E. faecalis* infection by decreasing the expression of TLR2 and NF-κB.

Keywords: Chronic apical periodontitis, East Java propolis, nuclear factor-kappa B, toll-like receptor 2

Address for correspondence: Dr. Tamara Yuanita, Mayjen, Prof. Dr. Moestopo 47, Surabaya - 60132, Indonesia.
E-mail: tamara-y@fkg.unair.ac.id

INTRODUCTION

Chronic inflammation in periapical area is a defense of an active host against bacteria and toxins. Complex anatomy of the root canal system often leads to imperfect cleaning during cleaning and shaping procedure of the root canal treatment (RCT). The bacteria cannot totally be

eliminated, especially in the apical area of the root canal. *Enterococcus faecalis* has been considered as one of the most resistant species post-RCT. These bacteria can lead to the re-infection of RCT.^[1-3]

Toll-like receptor (TLR) is a membrane-signaling receptor. TLR plays an important role in the body's natural defenses

This is an open access journal, and articles are distributed under the terms of the Creative Commons Attribution-NonCommercial-ShareAlike 4.0 License, which allows others to remix, tweak, and build upon the work non-commercially, as long as appropriate credit is given and the new creations are licensed under the identical terms.

For reprints contact: reprints@medknow.com

How to cite this article: Yuanita T, Zubaidah N, Kunarti S. East Java propolis effect on toll-like receptor 2 and nuclear factor-kappa B expression in chronic apical periodontitis. Saudi Endod J 2018;8:212-6.

Access this article online	
Quick Response Code:	Website: www.saudiendodj.com
	DOI: 10.4103/sej.sej_104_17

against microbes. *E. faecalis* is a Gram-positive bacterium that has lipoteichoic acid (LTA) and peptidoglycan components which can be recognized by specific signaling molecules on the surface of the host cells. TLR can lead to stimulation of innate and adaptive immunity. LTA is a unique polymer that affects cellular processes, including virulence, biofilm formation, defense homeostasis, autolysis activity regulation, sensitivity to ultraviolet radiation, acid tolerance, and resistance to antibiotics.^[4]

Nuclear factor kappa B (NF- κ B), furthermore, is a complex protein that controls DNA transcription. NF- κ B is also a transcription factor that regulates many genes such as interleukin-1 (IL-1), IL-6, IL-8, intercellular adhesion molecule-1, and interferon- γ .^[5] In the unstimulated cells, NF- κ B is in the cytoplasm and binds to inhibitor of NF- κ B (I κ B) that prevents NF- κ B to move into the nucleus.^[6] Meanwhile, when cells are stimulated, specific kinases will phosphorylate I κ B, leading to I κ B degradation by proteasome. NF- κ B gets transferred into the nucleus and binds to specific targeted genes that will stimulate gene transcription.^[7,8] NF- κ B activation will result in its translocation into the cell nucleus so that NF- κ B will be increased within the cell. Transcription factor of NF- κ B can be considered as a regulator of a variety of pro-inflammatory mediators.^[9]

East Java propolis is a yellow-brown or dark brown resin which is the substance of a honey bee, *Apis mellifera*, collected from tree buds, sap, shrub, or other plants in Lawang, East Java.^[10,11] Propolis has a broad spectrum of biological and pharmacological activities, including antibacterial, antibiofilm, anti-inflammatory, antibiotic, antifungal, and antioxidants.^[12]

The results of the recent studies, however, show that the differences of TLR-2 and NF- κ B expressions after the application of propolis on periapical lesions induced with *E. faecalis* bacteria still cannot be explained.^[13,14] Thus, it is necessary to study how East Java propolis affects the decrease of TLR-2 and NF- κ B expression in the periapical tissues of Wistar rats. The purpose of this study was to analyze the effectiveness of East Java propolis extract as a potential intracanal medicament by decrease of TLR-2 and NF- κ B expression in chronic apical periodontitis caused by *E. faecalis*.

MATERIALS AND METHODS

This study used thirty Wistar rats (σ , aged 12 weeks, 130–150 g) divided into three groups, namely negative control group, positive control group, and treatment

group. To obtain internal validity, those samples were randomly chosen into three groups. Ethical clearance was obtained from the Health Research Ethics Committee of the Faculty of Dental Medicine, Universitas Airlangga No. 28/KKEPK.FKG/III/2015.

Propolis extract was used by maceration method; briefly, 350 g of raw East Java propolis was macerated with 650 ml of 70% ethanol and shaken using a shaker in 80 rpm. After 7 days, the maceration process was stopped and filtered. The solution was evaporated until the substance was free from ethanol and was diluted with aquadest to obtain 12% of propolis extract. Wistar rats were anesthetized using 80 mg/kg of ketamine (Ketalar, Warner-Lambert, Irlandia) and 10 mg/kg of xylazine (Xyla, Warner-Lambert, Irlandia) with intraperitoneal technique in sterile phosphate-buffered saline (PBS) (Merck, USA). Those rats then were fixed on retraction board, and later the pulp of their right maxillary molar was opened by using a low-speed electric handpiece (W and H, Zalsburg, Austria) with a round bur sized 1/4 (SS White burs Inc., Lakewood, NY, USA). Group I served as the negative control group with healthy teeth. Group II served as the *E. faecalis* group, the pulp was opened and then immediately induced with 10 μ l of BHI-b (Merck, USA) containing 10⁶ colony-forming unit (CFU) of *E. faecalis* ATCC29212 bacteria and filled with glass ionomer cement (GIC, Fuji, Japan) to prevent contamination with oral microorganisms. Meanwhile, in Group III, the treatment group (propolis group), the pulp was opened and was immediately induced with 10 μ l BHI-b containing 10⁶ CFU of *E. faecalis* ATCC29212 bacteria, and then 10 μ l of propolis was applied and filled with GIC. It took 21 days to get chronic apical periodontitis after pulp infection. Rats were terminated, and the specimen was taken. The specimen was then immersed into embedded paraffin and cut into 4 μ m thickness (1 section for each sample with 10 viewing fields that describe the condition of periapical tissue) for immunohistochemistry evaluation using monoclonal antibody TLR2 (Novus Biological, USA) and monoclonal antibody NF- κ B (Abcam, UK).

The specimen cut was then placed on the polysine microscope slides and then deparaffinization using xylol was performed. Retrieval antigen was performed in a microwave oven with citrate buffer at pH 6. Furthermore, it was immersed in PBS 2 times for 5 min and then in spilled endogenous peroxidase for 15 min. The specimen was washed with water for 5 min and then serum blocking was spilled for 5 min, drained, then immunohistochemically evaluated using monoclonal antibody anti rat against TLR-2 and NF- κ B.

Microscopic evaluation of the specimen was conducted using light microscope (Nikon HL600, Japan) by the $\times 400$ magnification in ten field of view. All data were described as mean value \pm standard deviation and then analyzed using one-way ANOVA.

RESULTS

The expression of TLR-2 in Group III on microscopic evaluation is shown in Figure 1. The chromatic color indicated the positive expression of TLR-2. ANOVA test was conducted to know whether there were differences of TLR-2 expression among the groups after the application of East Java propolis extract [Table 1]. To know the significance of the differences of TLR-2 among the groups, Tukey's honestly significant difference (HSD) test was conducted as shown in Table 2.

The results showed that there were significant differences of TLR-2 between both the *E. faecalis* group and the East Java propolis group. Next, to know whether there were differences of NF- κ B among the groups, ANOVA test was conducted as shown in Table 3.

The expression of NF- κ B in Group III on microscopic evaluation is shown in Figure 2. The chromatic color indicated the positive expression of NF- κ B. To know the significance of the differences of NF- κ B among the groups, Tukey's HSD test was conducted as shown in Table 4.

The results showed that there were significant differences of NF- κ B between the *E. faecalis* group and the East Java propolis group.

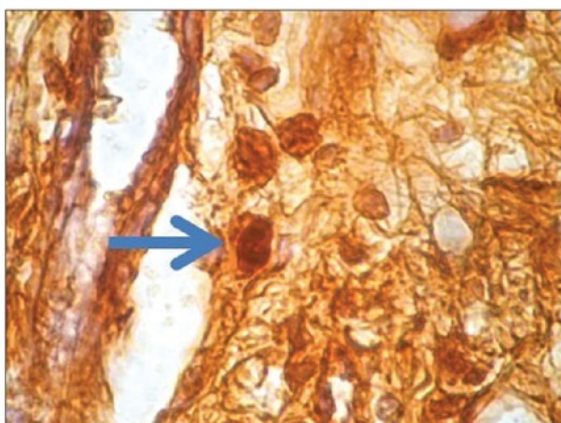


Figure 1: The expression of toll-like receptor-2 in periapical teeth of the Wistar rats in Group III with $\times 400$. The expression of the positive toll-like receptor-2 is marked by the blue arrow sign

DISCUSSION

Indonesia is also the world community, and especially East Java now is beginning to prioritize the use of drugs from natural materials (back to nature). In East Java, *Apis mellifera* propolis is collected from beehives located in Lawang area located on the plateau which is dominated by the silk cotton tree (*Ceiba pelandra* L).^[11] The chemical composition of propolis is very complex, highly variable, and is directly related to existing flora around the apiary, which may vary from region to region in the same territory. Polyphenols are one of the most important groups of compounds that occur in propolis. Flavonoids and phenolic acids constitute a significant class of polyphenols and consequently the most important class of pharmacologically active compounds which appear as the main components responsible for their biological activities.^[15]

Regarding the therapeutic properties of propolis, inflammatory processes have played a critical role in many diseases. Several studies have been associated with the anti-inflammatory activity of caffeic acid that

Table 1: ANOVA test for toll-like receptor-2 expression

Research groups	n	Σ positive TLR-2 cells	
		Mean \pm SD	P
Group I	10	5.80 \pm 0.83	0.000*
Group II	10	19.60 \pm 1.51	
Group III	10	8.00 \pm 1.00	

*Significance ($P < 0.05$), n: Number of samples. SD: Standard deviation, TLR: Toll-like receptor

Table 2: The result of Tukey HSD analysis for the expression of TLR-2

	Group I	Group II
Group I		$P=0.000^*$
Group II	$P=0.000^*$	
Group III	$P=0.009$	$P=0.000^*$

*Significance ($P < 0.05$)

Table 3: The results of ANOVA test on nuclear factor- κ B variables

Research group	n	Σ positive NF- κ B cells	
		Mean \pm SD	P
Group I	10	8.80 \pm 1.30	0.01*
Group II	10	14.00 \pm 2.44	
Group III	10	10.40 \pm 3.13	

*Significance ($P < 0.05$), n: Number of samples. SD: Standard deviation, NF- κ B: Nuclear factor- κ B

Table 4: The result of Tukey HSD analysis for the expression of NF- κ B

	Group I	Group II
Group I		$P=0.01^*$
Group II	$P=0.01^*$	
Group III	$P=0.056$	$P=0.03^*$

*Significance ($P < 0.05$)

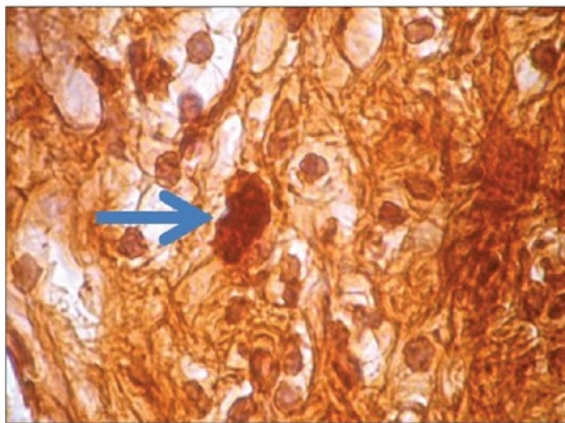


Figure 2: The expression of nuclear factor-kappa B in periapical teeth of the Wistar rats in Group III with x400. The expression of the positive nuclear factor kappa B is marked by the blue arrow sign

inhibits TLR-2 expression as well as tumor necrosis factor-alpha (TNF- α) and IL-10 production. Propolis has a positive effect on innate and adaptive immunity in mice. This role should be mainly attributed to flavonoids contained in propolis. It is arguable that caffeic acid synergistically exerts anti-inflammatory action with propolis flavonoids.^[12]

The results showed that *E. faecalis* could increase the number of TLR-2 cells in the periapical tissues. The number of TLR-2 cells in the inflammatory periapical tissue was higher than healthy periapical tissue in negative control. In the treatment group, East Java propolis decreased the number of TLR-2.

E. faecalis is a Gram-positive bacterium that can survive in limited nutrient condition in a long term.^[16] LTA is the outer envelope of Gram-positive bacteria that can stimulate macrophages. *E. faecalis* induces signaling through TLR2. TLR stimulation by microbial components can cause the activation of signaling pathways; as a result, the expression of several genes involved in the immune response will be induced. TLR2 receptor is a molecule that activates the immune system against microbial infection. Interaction between LTA and TLR results in signaling that activates the natural immune response. This signaling leads to activation and transcription of NF- κ B, which is the primary regulator of inflammatory responses. NF- κ B transcription is followed by the release of pro-inflammatory cytokines.^[14,15]

East Java propolis can decrease the number of NF- κ B in chronic apical periodontitis caused by *E. faecalis* infection. A previous study has shown that propolis has an antibacterial effect on *E. faecalis* biofilm.^[17] The main active components of propolis are flavonoids, phenols, and other aromatic

compounds. Anti-inflammatory effects were demonstrated through inhibition of prostaglandin synthesis. In addition, flavonoids and caffeic acid phenylethyl ester (CAPE), which implies 50% of all components, can inhibit the pathway of arachidonic acid lipoxygenase.^[12] CAPE is a potent inhibitor of NF- κ B which has anti-inflammatory effect. A previous report showed that CAPE has an immunostimulant effect.^[18]

Moreover, NF- κ B is a complex protein that controls DNA transcription. NF- κ B is found in almost all kinds of animal cells and involves cellular responses to stimulation including bacteria. The presence of *E. faecalis* in periapical tissue acts as an antigen that triggers cellular and humoral immunologic response. *E. faecalis* may be the main cause of chronic apical periodontitis after RCT because these bacteria can survive in periapical root canal area and invade periapical tissues, causing inflammation and tissue damage.^[19] The immune response is a complex cellular interaction for the presence of a lesion triggering the body to maintain homeostasis and conditions in extreme circumstances that can lead to a pathological state.^[6,18,20]

NF- κ B regulates the expression of cytokines, and the activation of NF- κ B leads to inflammatory maintenance reaction after initial stimulation. NF- κ B plays an important role in osteoclast and osteoblast functions. In osteoclasts, NF- κ B has a negative regulation of bone formation.^[20,21] The activation of NF- κ B depends on two pathways, namely canonical and non-canonical signaling pathways. Canonical pathway includes the activation of complex I κ B kinase (IKK) and leads to the phosphorylation and degradation of I κ B. The targeting genes of this pathway are p50 Rel A and p50 cRel dimers. At the complex IKK, IKK β plays an important role to activate canonical pathways (MYD88-dependent pathways). East Java propolis extract significantly suppresses inflammation with reduced activation of the transcription factor NF- κ B.^[6,18,20]

Some components present in propolis extract such as flavonoids (quercetin, galangin, and pinocembrin), caffeic acids, benzoic acid, and cinnamic acid probably act on the microbial membrane or cell wall site, causing functional and structural damages. The antimicrobial action of propolis is considered to be due to flavonoids and esters of phenolic acids. Other compounds such as steroids and salicylic acid found in propolis may also act synergistically on the final antimicrobial and anti-inflammatory activities.^[10-12,15,17,19] Low concentration of CAPE (<1 μ M) suppresses osteoclastogenesis and bone resorption through the inhibition of NF- κ B action. Propolis also blocks NF- κ B-mediated expression of TNF- α , suggesting the

synergistic effect of compounds present in propolis.^[18] Propolis-activated DCs in the presence of LTA induce NF- κ B production. Propolis modulated the maturation and functional properties of DCs and may be useful in the initial steps of the immune response, providing a novel approach to the development of DC-based strategies and for the discovery of new immunomodulators.^[12]

CONCLUSION

From the results of this study, it can be concluded that East Java propolis extract is a potential intracanal medicament in chronic apical periodontitis in rats induced by *E. faecalis* infection by decreasing the expression of TLR2 and NF- κ B.

Financial support and sponsorship

This work was financially supported by the Government of Indonesia through Institution of Research and Technology, Airlangga University.

Conflicts of interest

There are no conflicts of interest.

REFERENCES

1. Vineet RV, Nayak M, Kotigadde S. Association of endodontic signs and symptoms with root canal pathogens: A clinical comparative study. *Saudi Endod J* 2016;6:82-6.
2. Metzger Z, Abramovitz I, Bergenholz G. Apical periodontitis. In: Bergenholz G, Preben HB, Reit C, editors. *Textbook of Endodontology*. 2nd ed. UK: Blackwell Publishing Ltd.; 2010. p. 113-27.
3. Pecora CN, Baskaradoss JK, Al-Sharif A, Al-Rejaie M, Mokhlis H, Al-Fouzan K, et al. Histological evaluation of the root apices of failed endodontic cases. *Saudi Endod J* 2015;5:120-4.
4. Neuhaus FC, Baddiley J. A continuum of anionic charge: Structures and functions of D-alanyl-teichoic acids in gram-positive bacteria. *Microbiol Mol Biol Rev* 2003;67:686-723.
5. Boyce BF, Yao Z, Xing L. Functions of nuclear factor kappaB in bone. *Ann N Y Acad Sci* 2010;1192:367-75.
6. Baldwin AS Jr. Series introduction: The transcription factor NF-kappaB and human disease. *J Clin Invest* 2001;107:3-6.
7. Wang Q, McLoughlin RM, Cobb BA, Charrel-Dennis M, Zaleski KJ, Golenbock D, et al. A bacterial carbohydrate links innate and adaptive responses through toll-like receptor 2. *J Exp Med* 2006;203:2853-63.
8. Basier AR. The NF- κ B regulatory network. *Cardiovasc Toxicol* 2006;6:111-30.
9. Lawrence T. The nuclear factor NF-kappaB pathway in inflammation. *Cold Spring Harb Perspect Biol* 2009;1:a001651.
10. Sabir A. Aktivitas antibakteri flavonoid propolis *Trigona* Sp terhadap bakteri *Streptococcus mutans* (*in vitro*). *Dent J (Maj Ked Gigi)* 2005;38:135-41.
11. Yuanita T, Hutagalung J, Widjastuti I, Rulianto M, Mooduto L. Minimum bacterial concentration of East Java propolis to biofilm of *Enterococcus faecalis*. *E J Apimondia Kiev Ukraina* 2013. Available from: <http://apimondia2013.org.ua/en/congress-program/apitherapy.html>. [Last cited 2018 Jan 10].
12. Parolia A, Thomas MS, Kundabala M, Mohan M. Propolis and its potential uses in oral health. *Int J Med Med Sci* 2010;2:210-5.
13. Fukada SY, Silva TA, Saconato IF, Gadet GP, Avila-Campos MJ, Silva JS, et al. INOS-derived nitric oxide modulates infection-stimulated bone loss. *J Dent Res* 2008;87:1155-9.
14. Guiliams TG. *Managing Chronic Inflammation: Natural Solution*. Vol. 7. The Standart; 2006. p. 1-7.
15. Ramos AF, Miranda JL. Propolis: A review of its anti inflammatory and healing actions. *J Venom Anim Toxin Incl Trop Dis* 2007;13:702-22.
16. Metzger Z, Abramovitz I. Periapical lesion of endodontic origin. In: Ingle JI, Bakland LK, Baumgartner J, editors. *Ingle's Endodontics*. 6th ed. Hamilton, Ontario: BC Decker, Inc.; 2008. p. 494-519.
17. Garg P, Tyagi SP, Sinha DJ, Singh UP, Malik V, Maccune ER. Comparison of antimicrobial efficacy of propolis, *Morinda citrifolia*, *Azadirachta indica*, *Triphala*, green tea polyphenols and 5,25% sodium hypochlorite against *Enterococcus faecalis* biofilm. *Saudi Endod J* 2014;4:122-7.
18. Nieves M, Rocio S, Antonio M. Caffeic acid phenethyl ester inhibits t-cell activation by targeting both nuclear factor of activated t-cell and NF- κ B transcription factor. *J Pharmacol Exp Ther* 2004;308:993-1001.
19. Dale JL, Cagnazzo J, Phan CQ, Barnes AM, Dunny GM. Multiple roles for *Enterococcus faecalis* glycosyltransferases in biofilm-associated antibiotic resistance, cell envelope integrity, and conjugative transfer. *Antimicrob Agents Chemother* 2015;59:4094-105.
20. Oeckinghaus A, Ghosh S. The NF-kappaB family of transcription factors and its regulation. *Cold Spring Harb Perspect Biol* 2009;1:a000034.
21. Faccio R, Choi Y, Teitelbaum SL, Takayanagi H. The osteoclast: The pioneer of osteoimmunology. In: Lorenzo J, Horowitz M, Choi Y, Takayanagi H, editors. *Osteoimmunology*. London, UK: Academic Press; 2011. p. 142-75.

East Java propolis effect on toll-like receptor 2 and nuclear factor-kappa B expression in chronic apical periodontitis

ORIGINALITY REPORT

33%

SIMILARITY INDEX

24%

INTERNET SOURCES

23%

PUBLICATIONS

%

STUDENT PAPERS

MATCH ALL SOURCES (ONLY SELECTED SOURCE PRINTED)

6%

★ www.apimondia2015.com

Internet Source

Exclude quotes Off

Exclude matches Off

Exclude bibliography On